

Received: 2020.11.16

Accepted: 2021.02.18

Available online: 2021.03.19

Published: 2021.04.24

# Plummer-Vinson Syndrome: A Rare Cause of Dysphagia in an Octogenarian

## Authors' Contribution:

Study Design A  
Data Collection B  
Statistical Analysis C  
Data Interpretation D  
Manuscript Preparation E  
Literature Search F  
Funds Collection G

BCE 1 **Farah Harmouch**  
BCD 2 **Hammad Liaquat**  
DEF 2 **Kimberly J. Chaput**  
AEF 2 **Berhanu Geme**

1 Department of Internal Medicine, St. Luke's University Hospital Health Network, Bethlehem, PA, U.S.A.

2 Department of Gastroenterology, St. Luke's University Hospital Health Network, Bethlehem, PA, U.S.A.

**Corresponding Author:** Hammad Liaquat, e-mail: [liaquathammad@gmail.com](mailto:liaquathammad@gmail.com)

**Conflict of interest:** None declared

**Patient:** Female, 88-year-old  
**Final Diagnosis:** Esophageal web • iron deficiency • Plummer-Vinson syndrome  
**Symptoms:** Dysphagia  
**Medication:** —  
**Clinical Procedure:** Esophagogastroduodenoscopy  
**Specialty:** Gastroenterology and Hepatology

**Objective:** Rare co-existence of disease or pathology

**Background:** Plummer-Vinson syndrome is a rare disease that presents with iron-deficiency anemia, dysphagia, and esophageal webs. It usually occurs in middle-aged White women, and it increases the risk for esophageal cancer. The prevalence of Plummer-Vinson syndrome has decreased due to early detection of iron deficiency and repletion of iron stores. Although Plummer-Vinson syndrome has also been commonly described in children and adolescents, it is seldom reported in the elderly population.

**Case Report:** An 88-year-old woman with a history of mild cognitive impairment, allergic rhinitis, and gastroesophageal reflux disease presented with difficulty in swallowing solid foods. She had a decreased appetite, along with a 4.5-kg weight loss in the last 1 year. She was also found to have severe iron deficiency and mild anemia. Her dysphagia continued to progress even after starting iron supplementation for her iron deficiency. She eventually had a food bolus trapped in her cervical esophagus that required removal via esophagogastroduodenoscopy. A barium swallow revealed a narrowing in the upper esophagus. A repeat esophagogastroduodenoscopy revealed an esophageal web that was dilated, resulting in relief of symptoms.

**Conclusions:** Dysphagia is reported in up to 10% of the elderly population. It commonly causes malnutrition and is associated with increased mortality. The usual etiologies include cognitive dysfunction, neurological disorders, and/or esophageal dysmotility or narrowing. Although the incidence of Plummer-Vinson syndrome has decreased over time, the possibility of its presence should not be overlooked. To our knowledge, the current case is the third case of dysphagia related to Plummer-Vinson syndrome reported in an octogenarian in the literature so far. Iron replacement can help resolve dysphagia in Plummer-Vinson syndrome but dilation of esophageal webs may sometimes be required.

**Keywords:** Anemia, Iron-Deficiency • Deglutition Disorders • Plummer-Vinson Syndrome

Full-text PDF: <https://www.amjcaserep.com/abstract/index/idArt/929899>



1094



—



4



12

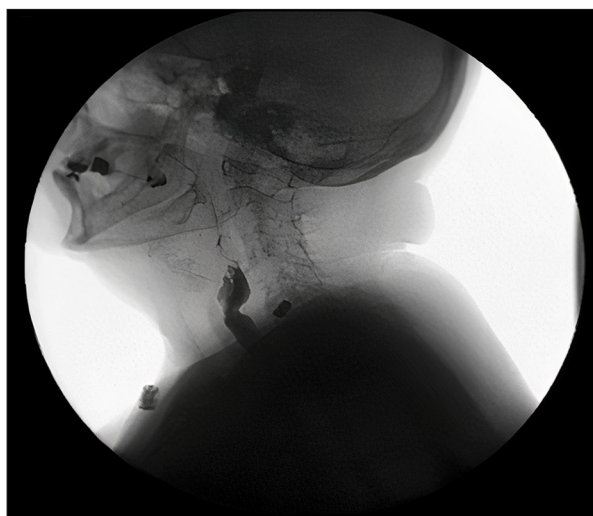


## Background

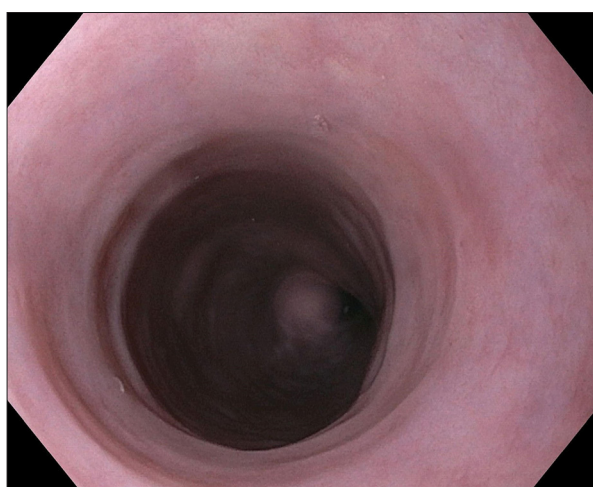
Plummer-Vinson syndrome (PVS) or Paterson-Brown-Kelly syndrome is a rare triad that is diagnosed when all 3 of the following are present in a patient: iron-deficiency anemia, esophageal webs, and progressive dysphagia. Due to its rarity, descriptions of the disease and management have mostly been gathered from small case series and retrospective and prospective studies, with the largest including only 30 patients with a diagnosis of PVS. PVS has also been described as sideropenic dysphagia due to the syndrome occurring with iron deficiency in the absence of anemia [1]. It has mostly been seen in middle-aged White women (fourth to seventh decade of life), particularly in northern countries. The prevalence of PVS has likely decreased due to a decreased prevalence of iron deficiency and improved nutritional status in this population, as evidenced by the decrease in global anemia in women from 1990 to 2011 [2]. The dysphagia is progressive, typically beginning as a dysphagia for solids that advances to liquids. The dysphagia is attributable to the cervical esophageal web [3]. Treatment options include iron supplementation, esophageal dilation, or both. Although few studies have compared treatment modalities, one prospective study using esophageal dilation showed that 94% of patients had complete response after the first session [4].

## Case Report

An 88-year-old woman presented to our Emergency Department with food impaction. Her past medical history was significant for iron-deficiency anemia, gastroesophageal reflux disease, allergic rhinitis, and cognitive impairment [5]. She was taken for an urgent esophagogastroduodenoscopy (EGD), and the food bolus was removed from the cervical esophagus. Further questioning revealed that she was experiencing dysphagia and had adapted her diet to compensate for it over the course of years. She was noted to prefer softer foods that were high in carbohydrates and had been avoiding foods with a tougher consistency such as various meats. She had also experienced an unintentional weight loss of 4.5 kg in the last year. A complete blood count and iron panel performed 5 months prior revealed hemoglobin 11.9 g/dL, hematocrit 40.0%, mean corpuscular volume 84 fL, elevated red cell distribution width 15.7%, ferritin 8 ng/mL, iron saturation 11%, and methylmalonic acid 145 nmol/L. At that time, ferrous gluconate 324 mg every other day was added to her medical regimen. An EGD performed 2 years ago for dyspepsia was grossly normal. Physical examination was remarkable for bilateral mild erythema of the angles of the mouth, but within normal limits otherwise. The following day, a video fluoroscopic barium swallow was performed and revealed normal oropharyngeal function. However, a bulge was noted in the distal cervical esophagus,

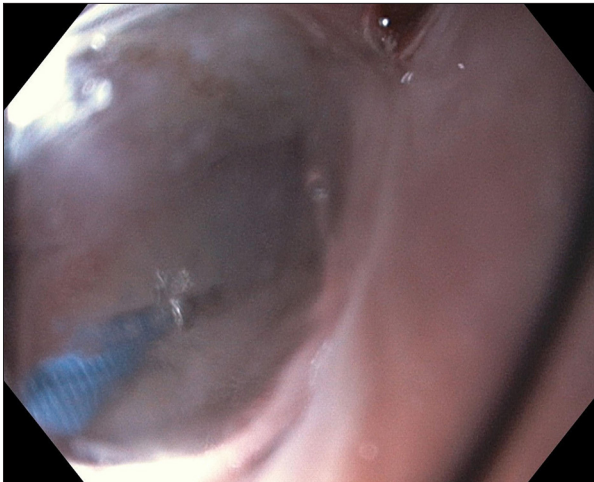


**Figure 1.** Video fluoroscopic barium swallow revealing distal cervical narrowing.

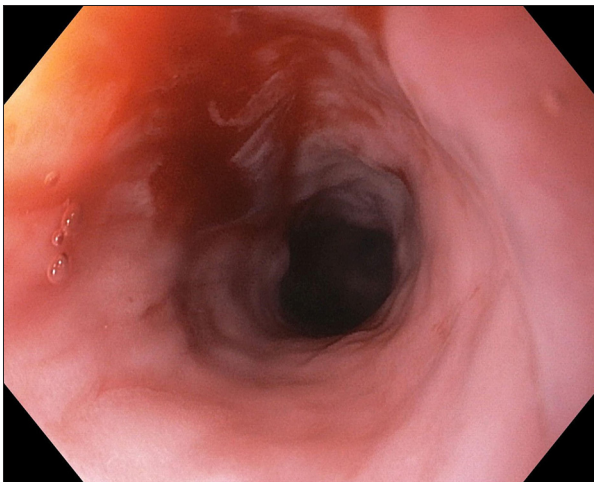


**Figure 2.** Esophageal web located 18 cm from the incisors.

and localized narrowing was present (**Figure 1**), which led to transient pill retention requiring multiple additional swallows to clear the pill. A noncontrast computed tomography scan of the chest, abdomen, and pelvis did not reveal any abnormalities. An EGD was repeated and demonstrated normal appearance of the pharynx and upper esophageal sphincter. An upper esophageal web (18 cm from the incisors) (**Figure 2**), which was not seen on a normal EGD performed 2 years prior, was found and successfully treated with controlled radial expansion (CRE) dilation (**Figures 3, 4**). Biopsies taken from the upper and lower esophagus revealed normal mucosa, excluding eosinophilic esophagitis. The patient reported resolution of dysphagia after the EGD. After being discharged from the hospital, frequency of the gluconate 324 mg was increased to daily. She continued to report complete resolution of symptoms and ability to swallow solid foods. One month later, laboratory work revealed a ferritin of 26 ng/mL, iron saturation 23%,



**Figure 3.** Controlled radial expansion balloon dilation of esophageal web.



**Figure 4.** Esophagus after controlled radial expansion balloon dilation revealing resolution of the cervical esophageal web.

total iron-binding capacity 280  $\mu\text{g}/\text{dL}$ , and iron 63  $\mu\text{g}/\text{dL}$ , while a complete blood count continued to be within normal limits.

## Discussion

To our knowledge, our patient is the eldest to have PVS diagnosed and represents the third case of PVS-related dysphagia reported in an octogenarian in the literature so far. The 3 octogenarians experienced different treatment modalities. While our patient was treated with iron supplementation as well as CRE dilation, the other 2 were treated with either balloon dilation or iron repletion with complete resolution of symptoms [6,7]. A case series reviewed 28 patients with PVS and found that most patients ( $n=22$ ) were treated with esophageal web disruption. Of those patients, 20 were treated with

balloon dilation of the esophagus, 1 had the esophageal web disrupted endoscopically with biopsy forceps, and 1 patient had web resection performed under microlaryngosurgery [8]. It is unknown whether these patients underwent a trial of iron therapy first. A prospective study performed from 2011 to 2013 in 37 participants with PVS revealed that 94% of symptomatic patients were completely relieved of dysphagia after 1 session of endoscopic dilation. Only 10% of participants had a recurrence after being followed up for a median of 10 months [4]. Another study of 153 patients, of which 132 had concomitant PVS, 1 session of Savary-Gilliard bougie dilation relieved dysphagia in 90.7% of patients. These patients were then treated with oral iron and folic acid for at least the next 3 months and followed up at that time [9]. Since many patients are treated with web dilation prior to iron supplementation, it is difficult to assess whether iron supplementation alone is enough.

It has been hypothesized that iron deficiency causes esophageal web formation by loss of iron-dependent enzymes, leading to mucosal degeneration [8]. However, a study of 1000 radiographic images of the proximal esophagus were reviewed, and 5.5% revealed 1 or more esophageal webs. None of the patients met diagnostic requirements of PVS in that study. The incidence of iron deficiency in these patients was similar to controls [10]. A second study revealed that only 10% of patients with iron deficiency anemia developed esophageal webs [11]. In another study of 135 patients with PVS and esophageal webs confirmed via EGD, only 38.5% had iron-deficiency anemia confirmed and 0.7% were found to have low serum ferritin level without anemia [12]. These studies suggest that iron deficiency alone may not explain esophageal web formation and PVS.

## Conclusions

PVS is a rare triad that is diagnosed when all 3 of the following are present in a patient: iron-deficiency anemia, esophageal webs, and progressive dysphagia. The decrease in incidence is thought to be caused by improvement in nutritional status of the general population. The effects of iron replacement therapy on dysphagia in PVS varies greatly. In severe cases, balloon dilation may be considered prior to iron supplementation. In the case of our patient, her dysphagia evolved while on iron supplementation and intervention with CRE balloon dilatation was required.

## Site of Research Project

Gastroenterology Department, St. Luke's University Hospital Health Network, Bethlehem, PA.

## Conflict of Interest

None.

## References:

1. Waldenstrom J, Kjellberg SR. The roentgenological diagnosis of sideropenic dysphagia. *Acta Radiologica*. 1939;20(6):618-38
2. Stevens GA, Finucane MM, De-Regil LM, et al. Nutrition Impact Model Study Group (Anaemia). Global, regional, and national trends in haemoglobin concentration and prevalence of total and severe anaemia in children and pregnant and non-pregnant women for 1995-2011: A systematic analysis of population-representative data. *Lancet Glob Health*. 2013;1(1):e16-25
3. Ergun G, Kahrilas P. Esophageal rings and webs. *Acta Endoscopica*. 2006;36(4):589-91
4. Goel A, Lakshmi CP, Bakshi SS, et al. Single-center prospective study of Plummer-Vinson syndrome. *Dis Esophagus*. 2016;29(7):837-41
5. Harmouch F, Liaquat H, Jerome B, et al. Plummer-Vinson syndrome: A rare cause of dysphagia in an octogenarian. ACG2020 Esophagus ePoster Session. American College of Gastroenterology Annual Scientific Meeting & Postgraduate Course; 2020 Oct 23-28; online virtual meeting
6. Nagai T, Susami E, Ebihara T. Plummer-Vinson syndrome complicated by gastric cancer: A case report. *Keio J Med*. 1990;39(2):106-11
7. Tahara T, Shibata T, Okubo M, et al. A case of Plummer-Vinson syndrome showing rapid improvement of dysphagia and esophageal web after two weeks of iron therapy. *Case Rep Gastroenterol*. 2014;8(2):211-15
8. Novacek G. Plummer-Vinson syndrome. *Orphanet J Rare Dis*. 2006;1:36
9. Patil M, Malipatel R, Devarbhavi H. Plummer-Vinson syndrome: A decade's experience of 132 cases from a single center. *J Gastroenterol Hepatol*. 2021;36(1):181-85
10. Noshier JL, Campbell WL, Seaman WB. The clinical significance of cervical esophageal and hypopharyngeal webs. *Radiology*. 1975;117(1):45-47
11. Chisholm M. The association between webs, iron and post-cricoid carcinoma. *Postgrad Med J*. 1974;50(582):215-19
12. Bakari G, Benelbarhdadi I, Bahije L, et al. Endoscopic treatment of 135 cases of Plummer-Vinson web: A pilot experience. *Gastrointest Endosc*. 2014;80(4):738-41