

Clinical Implication of Aortic Wall Biopsy in Aortic Valve Disease with Bicuspid Valve Pathology

Yong Han Kim, M.D.¹, Ji Seong Kim, M.D.¹, Jae-Woong Choi, M.D.¹,
Hyoung Woo Chang, M.D.², Kwon Joong Na, M.D.¹, Jun Sung Kim, M.D., Ph.D.³,
Kyung-Hwan Kim, M.D., Ph.D.¹

¹Department of Thoracic and Cardiovascular Surgery, Seoul National University Hospital, Seoul National University College of Medicine, ²Department of Thoracic and Cardiovascular Surgery, Samsung Medical Center, Sungkyunkwan University School of Medicine, ³Department of Thoracic and Cardiovascular Surgery, Seoul National University Bundang Hospital, Seoul National University College of Medicine

Background: Although unique aortic pathology related to bicuspid aortic valve (BAV) has been previously reported, clinical implications of BAV to aortopathy risk have yet to be investigated. We looked for potential differences in matrix protein expressions in the aortic wall in BAV patients. **Methods:** Aorta specimens were obtained from 31 patients: BAV group (n=27), tricuspid aortic valve (TAV) group (n=4). The BAV group was categorized into three subgroups: left coronary sinus-right coronary sinus (R+L group; n=13, 42%), right coronary sinus-non-coronary sinus (R+N group; n=8, 26%), and anteroposterior (AP group; n=6, 19%). We analyzed the expression of endothelial nitric oxide synthase (eNOS), matrix metalloproteinase (MMP)-9, and tissue inhibitor of matrix metalloproteinase (TIMP)-2. **Results:** Based on the mean value of the control group, BAV group showed decreased expression of eNOS in 72.7% of patients, increased MMP-9 in 82.3%, and decreased TIMP in 79.2%. There was a higher tendency for aortopathy in the BAV group: eNOS (BAV:TAV)=53%±7%:57%±11%, MMP-9 (BAV:TAV)=48%±10%:38%±1%. The AP group showed lower expression of eNOS than the fusion (R+L, R+N) group did; 48%±5% vs. 55%±7% (p=0.081). **Conclusion:** Not all patients with BAV had expression of aortopathy; however, for patients who had a suspicious form of bicuspid valve, aortic wall biopsy could be valuable to signify the presence of aortopathy.

Key words: 1. Aortic valve
2. Bicuspid aortic valve
3. Matrix metalloproteinase 9
4. Tissue inhibitor of metalloproteinase-2
5. Endothelial nitric oxide synthase

Introduction

Bicuspid aortic valve (BAV) disease is the most common congenital heart anomaly, with an estimated prevalence of 0.5% to 2% [1-3]. Male predominance

with a ratio of approximately 3:1 has been reported, and recent clinical studies show a high genetic heritability, with a 9% prevalence of the disease in first-degree relatives of patients with BAV disease [4]. Though patients with BAV disease can live with-

Received: January 4, 2016, Revised: March 21, 2016, Accepted: March 23, 2016, Published online: December 5, 2016

Corresponding author: Kyung-Hwan Kim, Department of Thoracic and Cardiovascular Surgery, Seoul National University Hospital, Seoul National University College of Medicine, 101 Daehak-ro, Seoul 03080, Korea
(Tel) 82-2-2072-3971 (Fax) 82-2-765-7117 (E-mail) kkh726@snu.ac.kr

© The Korean Society for Thoracic and Cardiovascular Surgery. 2016. All right reserved.

© This is an open access article distributed under the terms of the Creative Commons Attribution Non-Commercial License (<http://creativecommons.org/licenses/by-nc/4.0>) which permits unrestricted non-commercial use, distribution, and reproduction in any medium, provided the original work is properly cited.

out clinical significance, complications by BAV disease are relatively common in adulthood. Therefore, BAV disease accounts for higher morbidity and mortality than other congenital heart diseases.

BAV disease is associated with significant valvular disease such as aortic stenosis or regurgitation. Patients with BAV disease are also at increased risk of aortopathy such as aortic dilatation, aneurysmal change, or dissection. Previous studies have demon-

strated that aortopathy could occur without valve dysfunction [5,6]. In BAV, the connective tissue of the aortic media has abnormal properties and the collagen metabolism is disturbed. Extracellular matrix proteins or enzymes associated with aortopathy have been identified: an increased level of matrix metalloproteinases (MMPs), decreased level of endothelial nitric oxide synthase (eNOS), and decreased level of tissue inhibitor of matrix metalloproteinase (TIMP) [7-9].

The objective of this study was to evaluate potential differences in matrix protein expression in the aortic wall according to various types of BAV disease.

Table 1. Baseline characteristics of all study patients

Characteristic	Tricuspid aortic valve	Bicuspid aortic valve	p-value
Total no.	4 (12.9)	27 (87.1)	
Sex (male:female)	2:2	19:8	0.433
Age (yr)	64±10	63±10	0.941
Hypertension	4 (75.0)	13 (48.1)	0.332
Diabetes mellitus	0	4 (14.8)	0.426
Marfan	0	0	-
Ex-smoker	0	3 (11.1)	0.499
Current smoker	0	4 (14.8)	0.426
Predominant AS	2 (50.0)	21 (77.8)	0.439
More than moderate AS	2	21	
Predominant AR	2 (50.0)	6 (22.2)	0.685
More than moderate AR	2	4	
Ascending aorta diameter (mm)	48±6	43±5	0.153

Values are presented as number (%), mean±standard deviation, or number.

AS, aortic stenosis; AR, aortic regurgitation.

Methods

1) Patient characteristics

From January 2009 to December 2012, samples of the aortic wall were obtained from 31 patients who underwent open heart surgery for aortic stenosis or regurgitation and associated ascending aorta dilatation. Intraoperative assessment of the aortic valve was performed to identify whether the patients had BAV disease. Four patients (12.9%) were identified with tricuspid aortic valve (TAV) disease, and 27 patients (87.1%) were identified with BAV disease. Patients in the BAV group were categorized into three subgroups according to the classification proposed by Sievers and Schmidtke [10]: left coronary sinus-right

Table 2. Baseline characteristics of each BAV subgroup

Characteristic	BAV (R+L) ^{a)}	BAV (R+N) ^{b)}	BAV (anteroposterior)	p-value
Total no.	13 (18.2)	8 (81.8)	6 (81.8)	
Sex (male:female)	8:5	6:2	5:1	0.591
Age (yr)	65±10	61±9	62±13	0.663
Hypertension	5 (38.5)	5 (62.5)	3 (50.0)	0.561
Diabetes mellitus	1 (7.7)	2 (25.0)	1 (16.7)	0.550
Marfan	0	0	0	-
Ex-smoker	2 (15.4)	0	1 (16.7)	0.490
Current smoker	1 (7.7)	3 (37.5)	0	0.089
Predominant AS	11 (84.6)	5 (62.5)	5 (83.3)	0.463
More than moderate AS	11	5	5	
Predominant AR	2 (15.4)	3 (37.5)	1 (16.7)	0.463
More than moderate AR	2	2	0	
Ascending aorta diameter (mm)	43±5	40±4	45±5	0.201

Values are presented as number (%), mean±standard deviation, or number.

BAV, bicuspid aortic valve; AS, aortic stenosis; AR, aortic regurgitation.

^{a)}Left coronary sinus-right coronary sinus. ^{b)}Right coronary sinus- non-coronary sinus.




Fig. 1. Typical findings of immunohistochemistry staining for target molecule expression. Direction of arrow means ‘increase’ or ‘decrease’. (A) Endothelial nitric oxide synthase. (B) Matrix metalloproteinase-9. (C) Tissue inhibitor of matrix metalloproteinase-2.

coronary sinus (R+L group; n=13, 42%), right coronary sinus-non-coronary sinus (R+N group; n=8, 26%), and anteroposterior (AP group; n=6, 19%). We considered the R+L and R+N groups to be non-AP groups. The R+L and R+N groups had a BAV with one raphe and two fused leaflets, and the AP group included true bicuspid valves in the AP orientation with no raphe.

Patients’ preoperative characteristics are described in Table 1. The characteristics of each subgroup of BAV are additionally described in Table 2. All patients with predominant aortic stenosis and associated ascending aorta dilatation had a degree of aortic stenosis being more than moderate.

Aortic tissue samples were approximately 3.0×3.0 mm². Samples were obtained from the proximal end of the resected ascending aorta or from the same site during aortotomy repair when the ascending aorta was not replaced.

2) Immunohistochemistry

Fresh samples were fixed with formalin and embedded in paraffin. The paraffin block containing the tissue sample was cut into thin sections of 4 to 5 μm.

These sections were stained with primary and secondary antibodies. The sections were mounted and examined with a optical microscope that could take digital images. The whole area of a single slice was scanned using a ×100 objective, and magnified (×400) as digital images. The digital images were quantitatively analyzed using ImageJ software (National Institutes of Health, Bethesda, MD, USA). The area of secondary antibody expression was calculated with color picking tools. Only the media layer of the ascending aorta was analyzed. The person who obtained and analyzed the images could not access patient characteristics.

3) Statistical analysis

All statistical analyses were performed using the PASW SPSS statistics software package ver. 18.0 (SPSS Inc., Chicago, IL, USA). Continuous data were presented as mean±standard deviation. Categorical data were presented as an absolute number or percentage. A p-value<0.05 was considered to be statistically significant. The comparisons of preoperative characteristics and percentage of expression of the target molecule between groups were performed us-

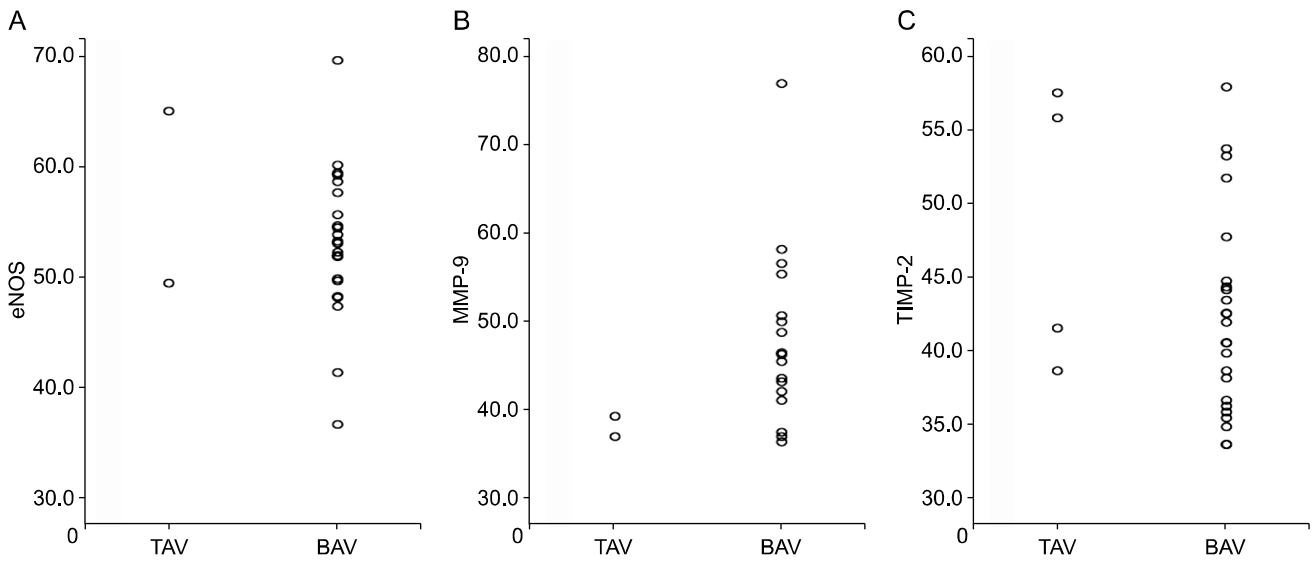


Fig. 2. (A-C) The scatter plot showing comparison of percentage of target molecule expression between TAV and BAV group. TAV, tricuspid aortic valve; BAV, bicuspid aortic valve; eNOS, endothelial nitric oxide synthase; MMP, matrix metalloproteinase; TIMP, tissue inhibitor of matrix metalloproteinase.

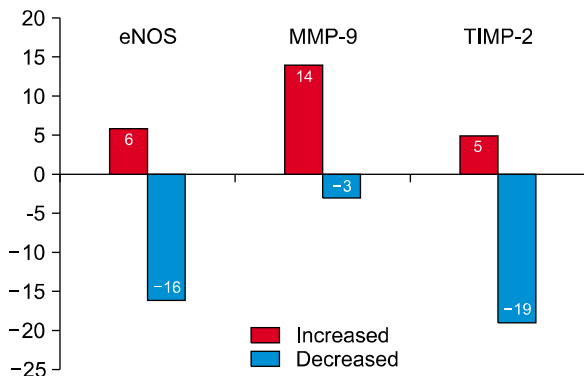


Fig. 3. Increased or decreased expression of eNOS, MMP-9, and TIMP-2. Reference: mean value of control group. eNOS, endothelial nitric oxide synthase; MMP, matrix metalloproteinase; TIMP, tissue inhibitor of matrix metalloproteinase.

ing univariate analysis. All parameters for this analysis were analyzed with non-parametric tests (Kruskal-Wallis test or Mann-Whitney U-test) as applicable.

4) Research ethics

The study protocol was reviewed by the institutional review board of Seoul National University Hospital (approval no. H-0907-052-287) and the Helsinki Declaration was adhered to throughout the study. Patients provided their informed consent to participate after having received a complete description of the study.

Results

Fig. 1 shows typical findings of immunohistochemistry staining for target protein expression. Fig. 2 shows the scatter plot that compares the percentage of target molecule expression between TAV and BAV groups. There were no significant statistical differences between the two groups; eNOS ($p=0.705$), MMP-9 ($p=0.111$), and TIMP-2 ($p=0.726$). We set the mean percentage of the target molecule expression of the TAV group as the reference, and analyzed whether the target molecule expression in the BAV group was increased or not in comparison.

We checked the increase or decrease of the target molecule level from the reference value (Fig. 3). The reference indicates the mean value of the control group. The expression of eNOS was decreased in the BAV group (16/22, 72.7%), MMP-9 was increased in the BAV group (14/17, 82.3%), and TIMP-2 was decreased in the BAV group (19/24, 79.2%).

Fig. 4 shows the scatter plot that compares the percentage of target molecule expression between TAV, non-AP, and AP groups. There were no significant statistical differences identified between the three groups; eNOS ($p=0.094$), MMP-9 ($p=0.377$), and TIMP-2 ($p=0.411$). Four patients (66.7%) from the AP group were available to undergo evaluation of eNOS expression, and all 4 patients (100%) showed

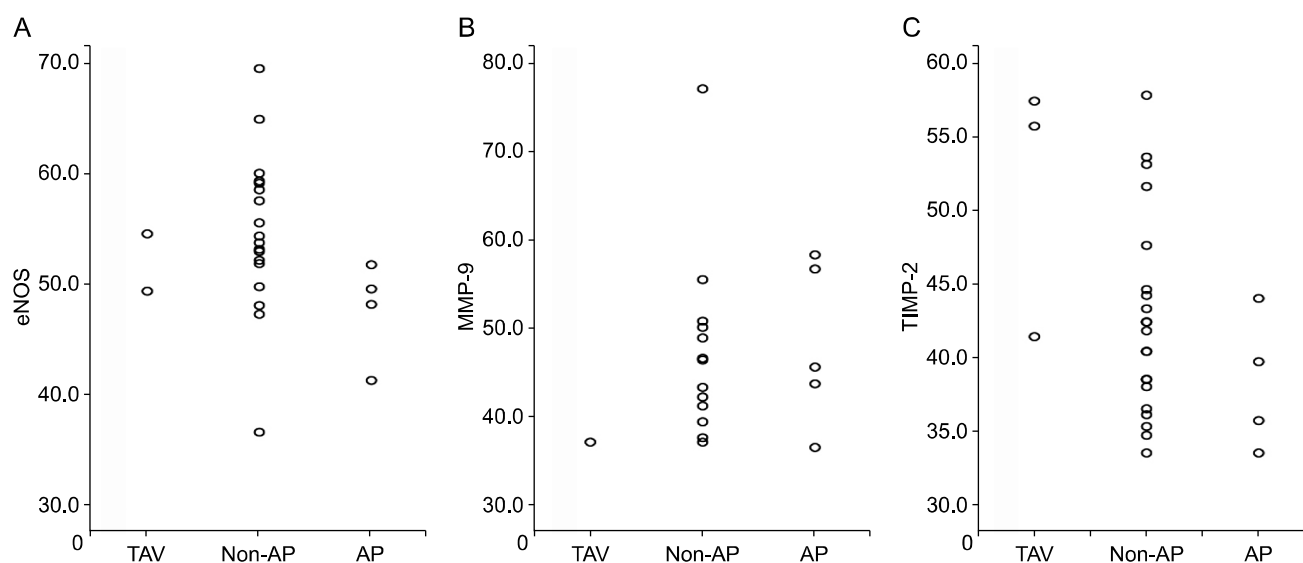


Fig. 4. (A–C) The scatter plot showing comparison of percentage of target molecule expression between TAV, non-AP, and AP group. TAV, tricuspid aortic valve; AP, anteroposterior; eNOS, endothelial nitric oxide synthase; MMP, matrix metalloproteinase; TIMP, tissue inhibitor of matrix metalloproteinase.

Table 3. Comparison of matrix protein expression in the media layer of AP and non-AP BAV

	Endothelial nitric oxide synthase (%)	Matrix metalloproteinase-9 (%)	Tissue inhibitor of matrix metalloproteinase-2 (%)
Non-AP BAV (n=21)	55±7	47±10	43±7
AP BAV (n=6)	48±5	48±9	38±5
p-value	0.081	0.889	0.234

AP, anteroposterior; BAV, bicuspid aortic valve.

a decreased level of eNOS compared to the TAV group. Five patients (83.3%) from the AP group were available to undergo evaluation of MMP-9 expression; 2 patients (40%) showed an increased level of MMP-9 and 3 patients (60%) showed a decreased level of MMP-9 compared to the TAV group.

Comparison of target molecule expressions in AP and non-AP groups in comparison to the BAV group showed decreased expression of eNOS in the AP group ($p=0.081$) (Table 3).

Fig. 5 shows the scatter plot that compares the percentage of target molecule expression among the TAV, R+L, R+N, and AP groups. There were no significant statistical differences among the four groups: eNOS ($p=0.115$), MMP-9 ($p=0.582$), and TIMP-2 ($p=0.212$) (Table 4).

Fig. 6 shows the scatter plot that demonstrates the correlation between the diameter of the ascending aorta and target molecule expression. There was no significant statistical correlation identified in any of

the molecules, meaning aorta dilatation is not correlated with target molecule expression.

Discussion

Our study demonstrates a decrease in eNOS/TIMP-2, and increase in MMP-9 in around 75% of patients in the BAV group (Fig. 2). Although we could not correlate BAV with aortopathy (Fig. 1), our data indicate the importance of aortic wall biopsy in aortic valve diseases. The prevalence of aortic dilatation in patients with BAV disease ranges from 33% to 80%, and is most frequently observed in the ascending aorta [11].

There was no significant difference in the percentage of target molecule expression of eNOS, MMP-9, and TIMP-2 between TAV, non-AP, and AP groups (Fig. 3). These findings indicate that the subtype of BAV disease does not influence the degree of target molecule expression. In contrast, Ikonomidis et al.

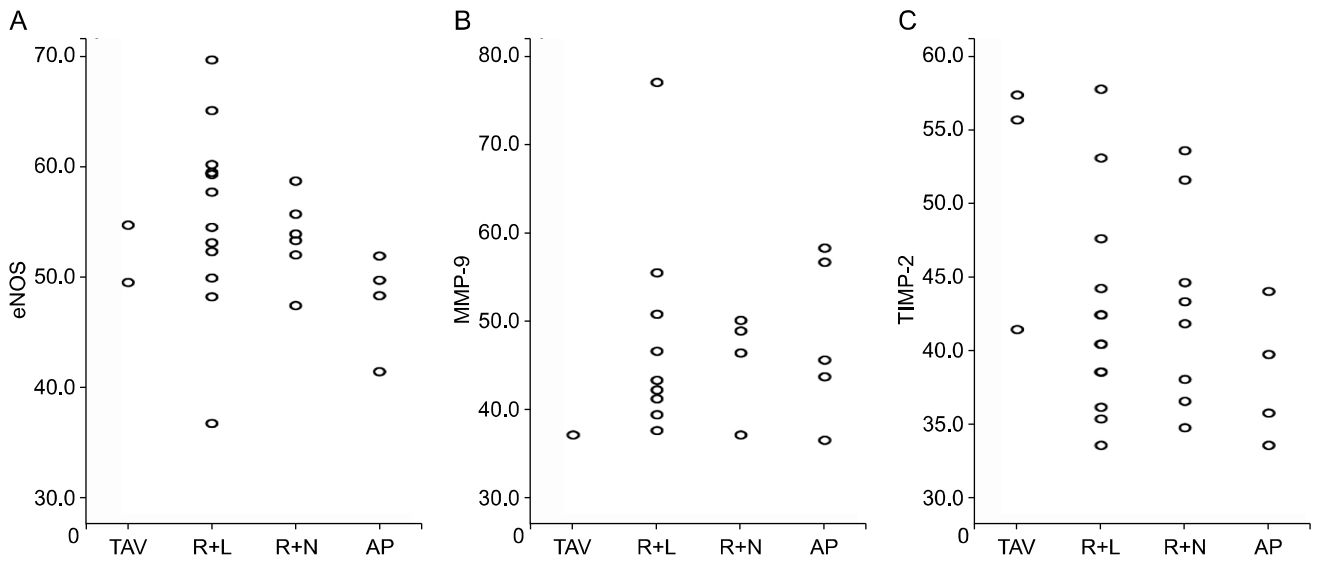


Fig. 5. (A-C) The scatter plot showing comparison of percentage of target molecule expression between TAV, R+L, R+N, and AP group. TAV, tricuspid aortic valve; AP, anteroposterior; eNOS, endothelial nitric oxide synthase; MMP, matrix metalloproteinase; TIMP, tissue inhibitor of matrix metalloproteinase; R+L, left coronary sinus-right coronary sinus; R+N, right coronary sinus-non-coronary sinus.

Table 4. Overall comparison of matrix protein expression in the media layer			
	Endothelial nitric oxide synthase (%)	Matrix metalloproteinase-9 (%)	Tissue inhibitor of matrix metalloproteinase-2 (%)
Bicuspid (R+L, N) ^{a)} (n=13)	56±9	48±12	42±7
Bicuspid (R+N, L) ^{b)} (n=8)	54±4	46±6	43±7
Bicuspid (anteroposterior) (n=6)	48±5	48±9	38±5
Control (n=4)	57±11	38±1	51±9
p-value	0.115	0.582	0.212

^{a)}Left coronary sinus-right coronary sinus. ^{b)}Right coronary sinus-non-coronary sinus.

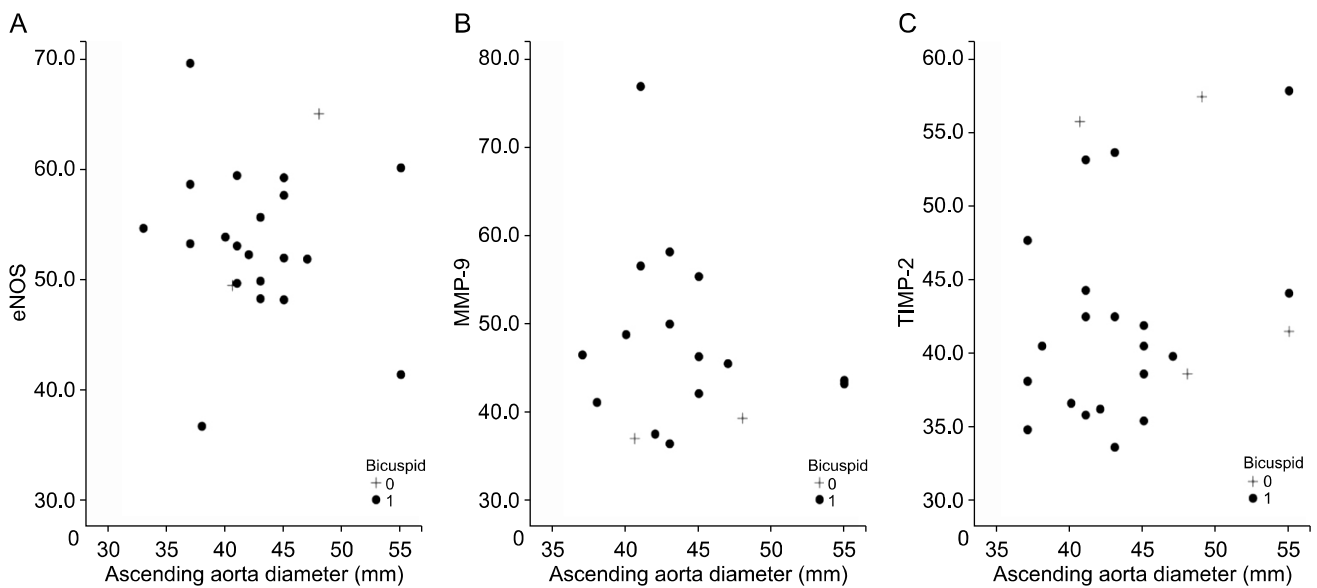


Fig. 6. (A-C) The scatter plot showing correlation between diameter of ascending aorta and target molecule expression. eNOS, endothelial nitric oxide synthase; MMP, matrix metalloproteinase; TIMP, tissue inhibitor of matrix metalloproteinase.

[12] hypothesized that each BAV configuration type has a unique signature of local MMPs and TIMPs, and also suggested that the R+L type may be more aggressive based on the MMP/TIMP score ratio.

We found a trend toward decreased expression of eNOS in the aortic wall of patients with BAVs, especially with AP relationship morphology. Inferring from the results of our study, eNOS might be a better marker for aortopathy than MMP-9 or TIMP-2 for BAV with AP relationship (without raphe) (Table 3). In a clinical setting, the diagnosis of AP relationship with BAV on the operative field is without debate. Based on our data, careful checking of the ascending aorta is necessary for patients with an AP relationship with a BAV. Schaefer et al. [13] suggested that differences in spatial distribution of blood flow through an AP leaflet orientation may lead to differential gene expression and alteration of the wall matrix, primarily in the aortic root and ascending aorta, causing dilatation or dissection.

There was no significant correlation between the diameter of the ascending aorta and target molecule expressions of eNOS, MMP-9, and TIMP-2 (Fig. 5). This finding demonstrates that dilatation of the ascending aorta does not mean that there are changes in expression of target molecules. This is very important in the clinical setting. When we perform aortic valve operation in aortic valve stenosis, we frequently encounter severely calcified or deformed valves, which we could not definitely diagnose as BAV. In cases of BAV, proactive ascending aorta replacement is recommended at 4 cm or larger in diameter. For the surgical indication of aorta replacement, Svensson et al. [14] recommended concurrent aortic valve repair with bicuspid valve if the aortic diameter is larger than 4.5 cm or an aortic cross-sectional area/height ratio greater than 8 to 10, because there is no added risk, and late survival is better.

Patients with BAV have an increased tendency to develop aneurysm or dissection of the thoracic aorta. Grewal et al. [15] reported a significant difference in the structure and maturation of the aortic wall in bicuspid valve, persisting in the dilated aortic wall, presenting with a thinner intima and lower expression of alpha smooth muscle actin. Patients with a non-dilated aorta and bicuspid valve did not show any difference in smooth muscle defects. Our results also suggested a tendency toward aortic wall defects

in a bicuspid valve patient; however, not all patients with a bicuspid valve showed a wall defect. Based on our data, individual examination of the aortic wall with BAV might be necessary for meticulous follow-up of the ascending aorta.

MMP is known to be associated with extracellular matrix degradation in the ascending aorta. Wilton et al. [16] analyzed MMPs in bicuspid and TAV patients. No differences exist in gene expression of MMPs in ascending aorta and aortic valve between patients with BAV and TAV. Instead, patients with larger aortic diameters have increased MMP-2/TIMP-1. Therefore, MMP might not be a specific marker of aortic wall defects in a BAV. Our data also supported this finding, and MMP-9 was not particularly specific to the ascending aorta with BAV. Rabkin [17] showed similar data in a meta-analysis of differential expression of MMP-2, MMP-9, and TIMP proteins.

The molecular pathophysiology of BAV and associated aortopathy is controversial and continues to be investigated. Fibrillin-1 and angiotensin-converting enzymes are examples of some target molecules currently studied in addition to eNOS, MMP, and TIMP [18,19].

Phillippi et al. [20] recently reported that aortopathy is mediated by a mechanism of altered matrix architecture and reduced collagen maturity, leading to remodeling of thoracic aortic aneurysms in BAV patients. Lee et al. [21] suggested that adverse aortic remodeling in BAV-associated thoracic aortic aneurysms is gender-dependent, and elevated levels of TIMP-2 could protect against collagen degradation in female BAV-associated thoracic aortic aneurysms.

The severity and risk of aortic disease could be reevaluated with different types of BAV. In our study, not all patients with BAV had expressions of aortopathy. For patients who have a suspicious form of bicuspid valve, an aortic wall biopsy could be valuable to determine bicuspid valve pathology.

There are several limitations that should be acknowledged in our study. First, the most important limitation of our study was the very small number of patients included in the control group. There was difficulty during the study process in getting informed consent, especially from patients without BAV pathology. Second, some specimens were missed, and we could not obtain all of the data from the study group. Third, the sample size of the study group may

be too small to attribute statistical significance. Although the number of patients in each subgroup was small, our results compared with the control group did show distinctive data with a trend toward statistical significance, which could be valuable in considering the role of suspicious aortopathy in BAV disease.

In conclusion, in case of severe aortic stenosis with calcified fused leaflets, the aortic valve usually cannot be diagnosed with certainty as BAV. In this situation, aortic wall biopsy could be valuable to evaluate the medial wall defect. For patients suspected of having a BAV disease, evaluation of aortic wall pathology might be a helpful tool for long-term follow-up.

Conflict of interest

No potential conflicts of interest relevant to this article are reported.

Acknowledgments

This study was supported by grant no. 0420090650 (2009-4681) from the Seoul National University Hospital Research Fund.

References

1. Roberts WC. *The congenitally bicuspid aortic valve: a study of 85 autopsy cases.* Am J Cardiol 1970;26:72-83.
2. Ward C. *Clinical significance of the bicuspid aortic valve.* Heart 2000;83:81-5.
3. Siu SC, Silversides CK. *Bicuspid aortic valve disease.* J Am Coll Cardiol 2010;55:2789-800.
4. Cripe L, Andelfinger G, Martin LJ, Shooner K, Benson DW. *Bicuspid aortic valve is heritable.* J Am Coll Cardiol 2004;44:138-43.
5. Keane MG, Wiegers SE, Plappert T, Pochettino A, Bavaria JE, Sutton MG. *Bicuspid aortic valves are associated with aortic dilatation out of proportion to coexistent valvular lesions.* Circulation 2000;102(19 Suppl 3):III35-9.
6. Nistri S, Sorbo MD, Marin M, Palisi M, Scognamiglio R, Thiene G. *Aortic root dilatation in young men with normally functioning bicuspid aortic valves.* Heart 1999;82:19-22.
7. Aicher D, Urbich C, Zeiher A, Dimmeler S, Schafers HJ. *Endothelial nitric oxide synthase in bicuspid aortic valve disease.* Ann Thorac Surg 2007;83:1290-4.
8. LeMaire SA, Wang X, Wilks JA, et al. *Matrix metalloproteinases in ascending aortic aneurysms: bicuspid versus trileaflet aortic valves.* J Surg Res 2005;123:40-8.
9. Ikonomidis JS, Jones JA, Barbour JR, et al. *Expression of matrix metalloproteinases and endogenous inhibitors within ascending aortic aneurysms of patients with bicuspid or tricuspid aortic valves.* J Thorac Cardiovasc Surg 2007;133:1028-36.
10. Sievers HH, Schmidtke C. *A classification system for the bicuspid aortic valve from 304 surgical specimens.* J Thorac Cardiovasc Surg 2007;133:1226-33.
11. Carro A, Teixido-Tura G, Evangelista A. *Aortic dilatation in bicuspid aortic valve disease.* Rev Esp Cardiol (Engl Ed) 2012;65:977-81.
12. Ikonomidis JS, Ruddy JM, Benton SM Jr, et al. *Aortic dilatation with bicuspid aortic valves: cusp fusion correlates to matrix metalloproteinases and inhibitors.* Ann Thorac Surg 2012;93:457-63.
13. Schaefer BM, Lewin MB, Stout KK, Byers PH, Otto CM. *Usefulness of bicuspid aortic valve phenotype to predict elastic properties of the ascending aorta.* Am J Cardiol 2007;99:686-90.
14. Svensson LG, Kim KH, Blackstone EH, et al. *Bicuspid aortic valve surgery with proactive ascending aorta repair.* J Thorac Cardiovasc Surg 2011;142:622-9.
15. Grewal N, Gittenberger-de Groot AC, Poelmann RE, et al. *Ascending aorta dilation in association with bicuspid aortic valve: a maturation defect of the aortic wall.* J Thorac Cardiovasc Surg 2014;148:1583-90.
16. Wilton E, Bland M, Thompson M, Jahangiri M. *Matrix metalloproteinase expression in the ascending aorta and aortic valve.* Interact Cardiovasc Thorac Surg 2008;7:37-40.
17. Rabkin SW. *Differential expression of MMP-2, MMP-9 and TIMP proteins in thoracic aortic aneurysm: comparison with and without bicuspid aortic valve: a meta-analysis.* Vasa 2014;43:433-42.
18. Fedak PW, de Sa MP, Verma S, et al. *Vascular matrix remodeling in patients with bicuspid aortic valve malformations: implications for aortic dilatation.* J Thorac Cardiovasc Surg 2003;126:797-806.
19. Foffa I, Murzi M, Mariani M, et al. *Angiotensin-converting enzyme insertion/deletion polymorphism is a risk factor for thoracic aortic aneurysm in patients with bicuspid or tricuspid aortic valves.* J Thorac Cardiovasc Surg 2012;144:390-5.
20. Phillippi JA, Green BR, Eskay MA, et al. *Mechanism of aortic medial matrix remodeling is distinct in patients with bicuspid aortic valve.* J Thorac Cardiovasc Surg 2014;147:1056-64.
21. Lee J, Shen M, Parajuli N, Oudit GY, McMurtry MS, Kassiri Z. *Gender-dependent aortic remodelling in patients with bicuspid aortic valve-associated thoracic aortic aneurysm.* J Mol Med (Berl) 2014;92:939-49.