



## Description of a transosseous approach to the L5-S1 disc and 2 clinical case reports

Michael MacMillan, MD \*, John McCormick, MD, James W. Rice, MD

*Department of Orthopaedics, University of Florida, Gainesville, FL*

### Abstract

**Background:** The lumbosacral disc with the adjacent iliac crest and its relationships to neurologic, visceral, and vascular structures is difficult to approach with cannula-based retractor systems. Previous, less invasive approaches have been described to access this space. Anterior, presacral, and transforaminal approaches each have approach-related complications that have prevented their widespread adoption. A laterally based approach to this disc between the exiting L5 nerve root and traversing S1 nerve root would theoretically eliminate visceral and vascular complications but would necessarily course through the adjacent iliac crest. Our objective was to determine the feasibility of placing an interbody device into the L5-S1 disc space through a lateral transosseous approach.

**Methods:** Six transosseous pathways were created from the iliac crest, laterally through the sacral ala, and entering the L5-S1 intervertebral disc space (3 cadavers). The positions of the portals in relation to the local anatomy were evaluated anatomically and with computed tomographic sagittal, coronal, and axial planes. We measured the lengths, heights, and widths of the pathways; distance between the L5 and S1 nerve roots; endplate diameters; and angles necessary to access the space. In addition, 2 clinical cases using the transosseous pathway are presented.

**Results:** Computed tomographic scans and anatomic evaluations showed that there was an average 22-mm distance between the L5 and S1 nerve roots available to enter the L5-S1 disc space. The mean length of the pathway was 69 mm, and the mean height was 27 mm. The mean angle of the approach was 45° off the posterior-anterior axis, and there was a 25° upward angle from true lateral in the frontal plane.

**Conclusions:** A lateral, transosseous approach to the L5-S1 disc space for placing an interbody device is feasible. A closed cannula-based technique may offer reduced approach-related complications. Further studies will be required to determine the reproducibility and utility of this pathway.

© 2012 ISASS - International Society for the Advancement of Spine Surgery. Published by Elsevier Inc. All rights reserved.

*Keywords:* Spine; Lumbosacral fusion; L5-S1; Sacral ala; Minimally invasive surgery

Surgical approaches to the L5-S1 disc for interbody fusion have been performed traditionally using open anterior and posterior approaches and, recently, minimally invasive techniques. Access routes to the intervertebral disc space of the lumbosacral junction have been described using a transforaminal interbody technique, posterior lumbar interbody technique, anterior lumbar interbody technique, and recently, a presacral technique. Complications of these surgeries that have been reported include vascular injury, sympathetic nerve dysfunction, nerve root retraction irritation, and bowel injuries.<sup>1–3</sup> These reports have stimulated research to improve outcomes and reduce morbidity for L5-S1 interbody fusion.

The ideal approach to the lumbosacral junction would allow adequate access to the intradiscal space to allow preparation for fusion; minimize the muscle retraction; preserve the integrity of the ligamentous attachments; and minimize visceral, neurologic, and vascular morbidity. This report is a description of a transosseous technique to the lumbosacral junction. Our hypothesis was that the intervertebral disc space could be accessed through a transosseous approach. The goal was to create a transosseous tunnel that begins at the outer cortex of the iliac crest, enters the sacral ala, and exits into the intervertebral disc space (Figs. 1 and 2). A transosseous portal to the L5-S1 intervertebral disc space would allow access to the disc area between the S1 nerve root within the spinal canal and the L5 nerve root, which lies under the L5 pedicle. Nerve root manipulation would not be necessary, there would be minimal muscular disruption, and visceral organs and vascular structures

\* Corresponding author: Michael MacMillan, MD, Department of Orthopaedics, University of Florida, 3450 Hull Rd, Gainesville, FL 32607; Tel: (352) 273 7002; Fax: (352) 273 7388.

E-mail address: [macmim@ortho.ufl.edu](mailto:macmim@ortho.ufl.edu)

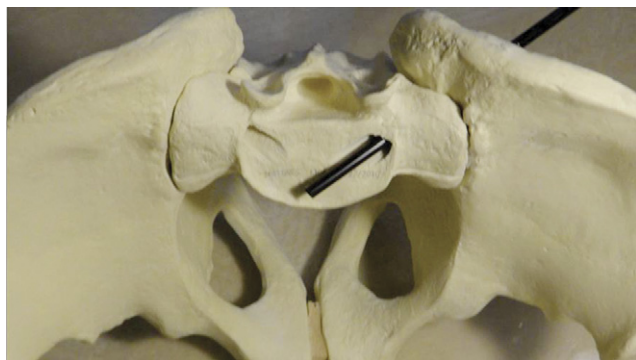


Fig. 1. Axial view of transosseous pathway.

would be avoided in this pathway. The delineation of the pathway is greatly facilitated by computer navigation of the bony anatomy. With the advent of intraoperative computed tomographic (CT) surgical navigation, access through complex bony anatomy is enabled.<sup>4–7</sup> We performed a preliminary cadaveric study to determine the feasibility of implanting an interbody device through this approach to the L5-S1 disc space. In addition, we describe 2 cases in which this technique was used to access the L5-S1 intradiscal space.

## Methods

Three cadaveric adult male torso specimens were obtained in accordance with institutional regulations for post-mortem human experiments. The project was approved ahead of time by the local institutional review board. All matters were conducted in accordance with ethical standards and with the Helsinki Declaration of 1975, as revised in 2000. The specimens were used to determine the feasibility of a transosseous approach to the L5-S1 disc space. In lieu of fluoroscopy, the posterior musculature of the torsos was removed to directly visualize the iliac crest, the sacral ala, and the L5-S1 foramen.

The technique was performed with each specimen in a prone position. A 13-mm reamer was used to drill a preliminary tunnel through the iliac crest, the sacral sulcus/

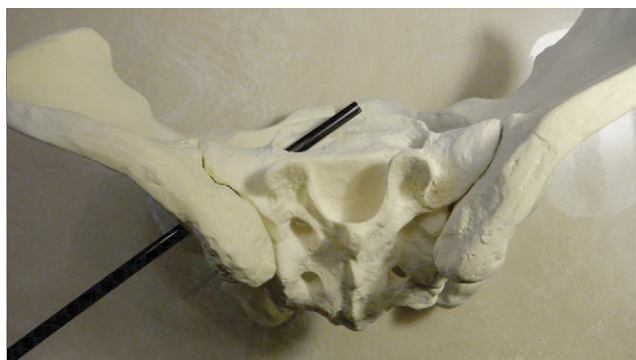

Fig. 2. Dorsal view of transosseous pathway.

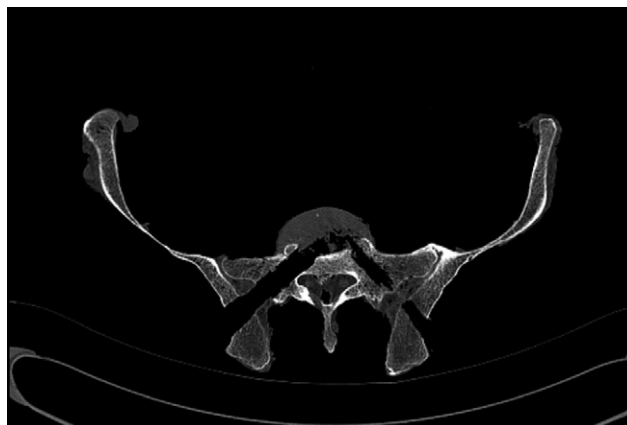

Fig. 3. CT scan visualizing transosseous tunnel at level of isthmus and disc space.

posterior sacroiliac recess, and the sacral ala and into the disc space. The technique was performed under direct visualization to confirm that there was not a gross breach within the cortex. Fibrocartilaginous material from the accessed L5-S1 disc was removed with straight and angled disc curettes and pituitary rongeurs. This technique was performed from both right and left iliac crests.

Specimens were scanned with the CT scanner to evaluate for any breach of the cortex (Fig. 3). Axial, sagittal, and coronal images were obtained. The specimens were then sectioned in the laboratory to evaluate the method of entrance to the L5-S1 disc space.

The consistency of the approach was evaluated, and measurements were obtained. The transosseous portal to the disc space was assessed. The distance from the outer table of the iliac crest to the disc space was recorded. Each specimen was then evaluated in the sagittal, axial, and coronal planes. With the CT images, we specifically targeted the pathway to the intervertebral disc space. The width of the cortex was then measured at the narrowest point of the pathway to determine the maximal allowable size of the pathway and which plane had the narrowest distance between cortices (Table 1). The angles of the transosseous portals were then described in the axial and sagittal planes in reference to a prone pelvis. The axial and coronal angles required to obtain a transosseous canal from the iliac crest to the intervertebral disc space were recorded (Table 2). The anteroposterior and lateral dimensions of the first sacral superior vertebral endplate, as well as the angles between the L5 and S1 vertebral endplates, were recorded (Table 3).

## Results

A transosseous tunnel was successfully created in all specimens from the right and left iliac crests. The CT scans and the anatomic evaluations confirmed that the portal was bound by cortical bone at all times until it entered the L5-S1 disc space (Fig. 4). Upon sectioning of the specimens, it was

Table 1  
Measures of canal length and intervertebral disc space

	Canal length (mm)	Axial width of isthmus (mm)	Coronal width of isthmus (mm)	Sagittal width of isthmus (mm)
Pelvis 1				
Right	70	21	27	22
Left	75	20	27	21
Pelvis 2				
Right	68	18	26	26
Left	68	19	26	19
Pelvis 3				
Right	68	18	25	21
Left	67	17	24	19

NOTE. Each isthmus was the narrowest point of the pathway and an indication of maximal pathway size.

determined that the isthmus of the approach was within the sacral ala. The sacral ala was not breached when we entered the L5-S1 disc space. The narrowest point was found within the axial and sagittal planes of all specimens within the sacral ala and averaged 19 mm in diameter. The mean angle of the approach was 45° from true posterior and 25° headed from inferiorly to superiorly toward the plane of the L5-S1 disc in the coronal plane. Between the L5-S1 endplates, the mean lordotic angle was 15°. Dimensions of the first sacral superior vertebral endplate were recorded (Table 3). Inspection of the cadaveric specimen showed that all tunnels were posterior to the sacroiliac joint and did not violate this joint.

This study confirmed that the intervertebral disc space could be accessed through a transosseous approach. We were able to perform this under direct visualization. A transosseous portal avoids the L5 nerve root as it drapes over the anterior aspect of the sacral ala. The portal is anterior to the S1 nerve root and the thecal sac. It avoids any retraction of the nerve roots or thecal sac that would be required in posterior and transforaminal approaches. The transosseous approach avoids the manipulation of the abdominal viscera and vascular structures that can be encountered with anterior approaches. A transosseous approach avoids the potential bowel complications that have been described in the presacral approaches.

Table 2  
Angles required to obtain transosseous canal from iliac crest to intervertebral disc space

	Axial angle (°)	Coronal angle (°)
Pelvis 1		
Right	45	25
Left	45	25
Pelvis 2		
Right	43	25
Left	45	23
Pelvis 3		
Right	43	22
Left	43	25

Table 3  
Dimensions of first sacral superior vertebral endplate and angle between L5 and S1

	S1 endplate dimensions (mm)	L5-S1 endplate angle (°)
Pelvis 1		15
AP	68	
Lateral	45	
Pelvis 2		10
AP	56	
Lateral	31	
Pelvis 3		18
AP	60	
Lateral	39	

Abbreviation: AP, anteroposterior.

### Case 1

#### History

A 69-year-old woman presented to our clinic for an evaluation of persistent lumbar pain. Approximately 3 years before presentation to our clinic, she received an L5-S1 transforaminal interbody fusion. Because of persistent low-back and left leg pain, the patient sought a second opinion

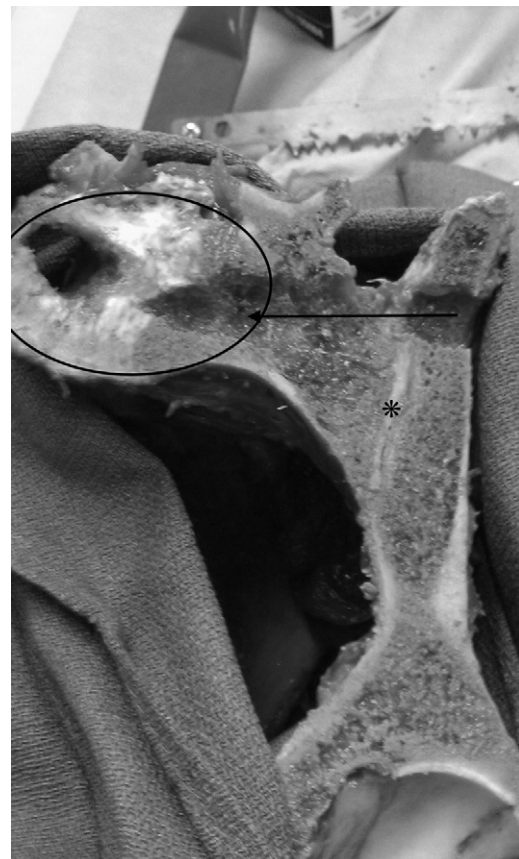

Fig. 4. The specimen has been sectioned perpendicular to the transosseous tunnel (arrow), indicating that the tunnel is within bone within its entirety. The S1 endplate is visualized (oval), and the tunnel can be seen posterior to the sacroiliac joint (asterisk).

from another surgeon. Evaluation showed migration of the implant and broken pedicle screws. The C-reactive protein level was 16 mg/L, and the erythrocyte sedimentation rate was 56 mm/h. The second surgeon attempted an anterior revision with implant removal at the L5-S1 level. However, despite the presence of an experienced vascular surgeon, access to the L5-S1 level was prohibited by vascular adhesions, causing severe, life-threatening blood loss. The procedure was then abandoned, and complications included an anterior wound dehiscence. The patient required a vacuum-assisted wound device for several months and intravenous antibiotics for infectious control. After completion of the antibiotic course and soft-tissue healing, the patient was referred to our clinic for evaluation and discussion of treatment options.

On discussion with the patient, she reported severe back and left leg pain. We obtained a CT scan, which showed erosive bony changes at the endplates at the L5-S1 level. The interbody spacer was visible in the soft tissues anterior to the L5-S1 disk space (Fig. 5). The patient was diagnosed as having an anteriorly extruded interbody device with persistent spinal infection.

#### *Surgical methods*

The patient was placed in the prone position on a Jackson table. Intraoperative 3-dimensional (3D) fluoroscopy was

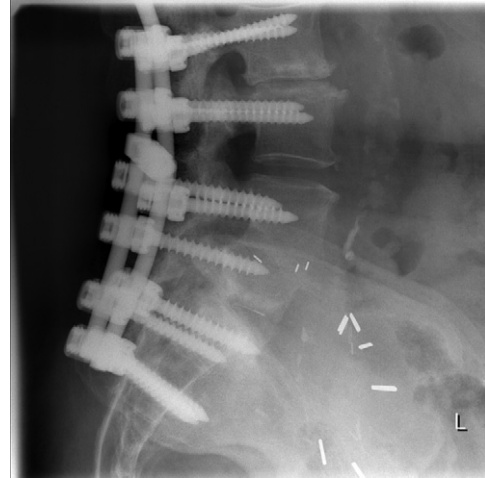


Fig. 6. Lateral X-ray showing infected hardware removed, clearance of infection, reinstrumentation, and fusion of spine.

performed with the O-arm imaging system (Medtronic, Memphis, Tennessee), and these images were transferred to the Medtronic StealthStation, which provided real-time, 3D guidance.

The 3D guidance was then used to locate the retained broken screw. The overlying bone was excised, and the

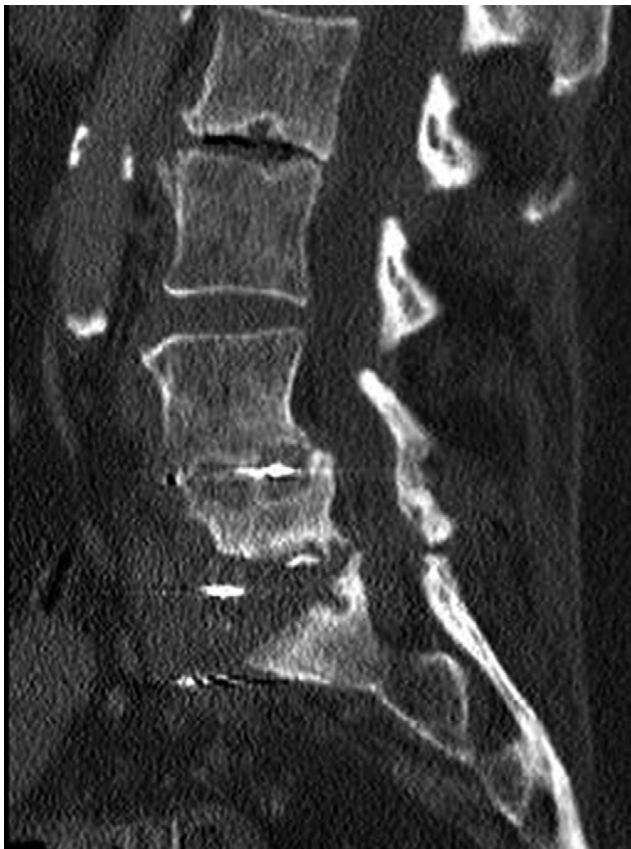

Fig. 5. CT scan, sagittal view, of patient presenting with dislodged interbody spacer and infection.

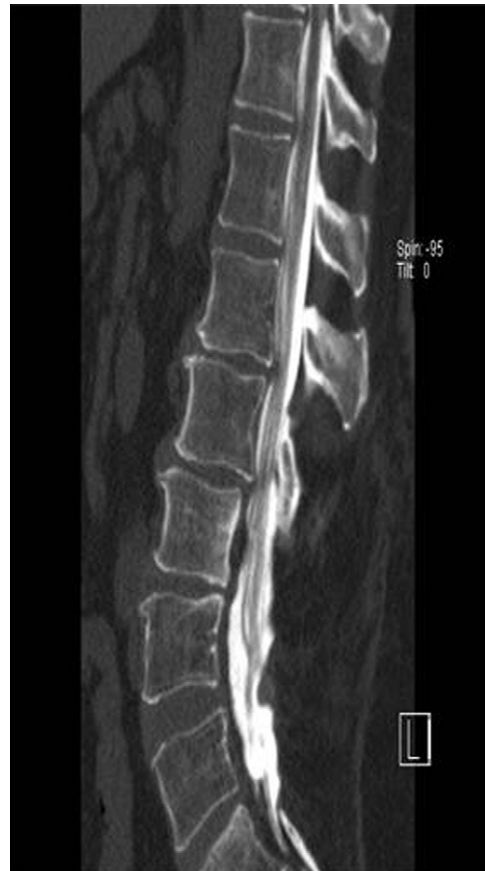

Fig. 7. Sagittal CT myelogram showing post-laminectomy spine.

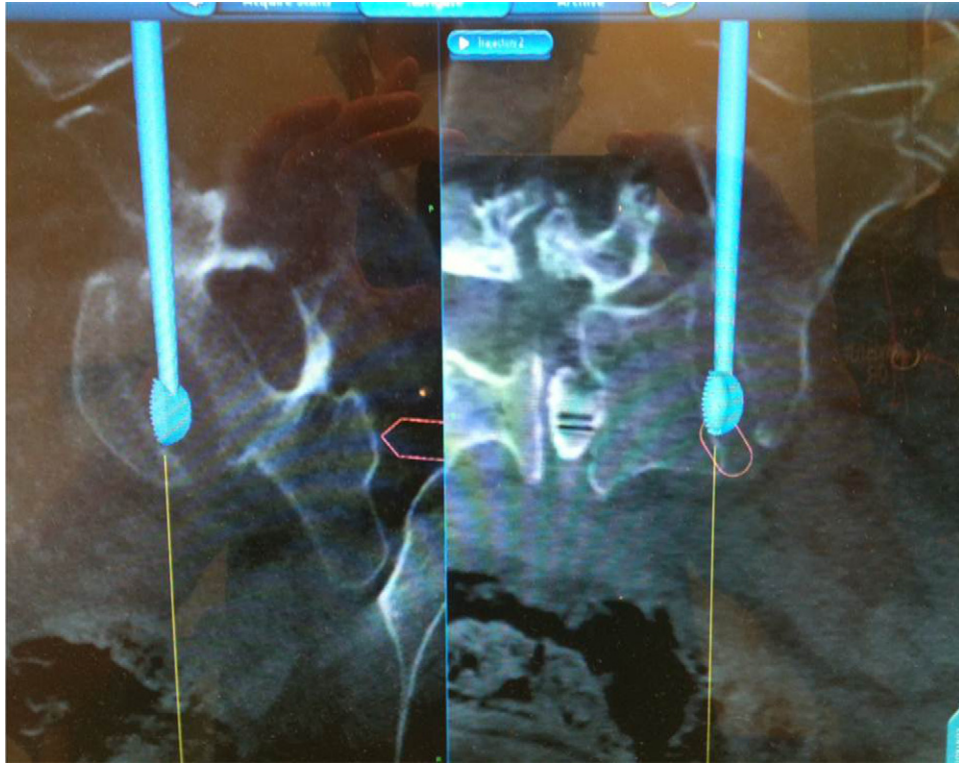


Fig. 8. StealthStation navigation image with curette in L5-S1 disc.

screw was removed. We then performed a transosseous path to the L5-S1 through the sacral ala. Using the 3D guidance, we were able to confirm our position in the L5-S1 disk space. After debridement of the soft tissue within the disc space and overlying the endplates, the device was palpated directly anterior to the L5-S1 disc space and removed (Fig. 6).

#### Case 2

Intractable back pain developed in a 65-year-old woman 7 years after a 4-level laminectomy (Fig. 7). As part of a 4-level fusion construct, it was elected to perform a transosseous approach to the L5-S1 disc for interbody fusion. After undergoing lateral fusion at L2-3, L3-4, and L4-5, the patient was turned prone for percutaneous pedicle fixation and interbody fusion at L5-S1. Continuous electromyographic monitoring of the L5 and S1 nerve roots was used in conjunction with O-arm 3D fluoroscopy and StealthStation computer navigation. The transosseous pathway was established on the patient's left side, and the disc was entered and debrided with navigated disc instruments (Fig. 8). A StaXx XD expandable device (Spine Wave, Shelton, Connecticut) was introduced into the L5-S1 disc. A postoperative lateral radiograph (Fig. 9) and CT scan (Fig. 10) show the final position of the implant.

#### Discussion

Obtaining fusion at the L5-S1 level remains a challenge for the spine surgeon. Posterior fusion procedures are the

easiest to perform technically; however, there is a high incidence of pseudarthrosis and hardware failure from a posterior-only approach. An anterior approach to L5-S1 is commonly performed to provide interbody fusion and sup-

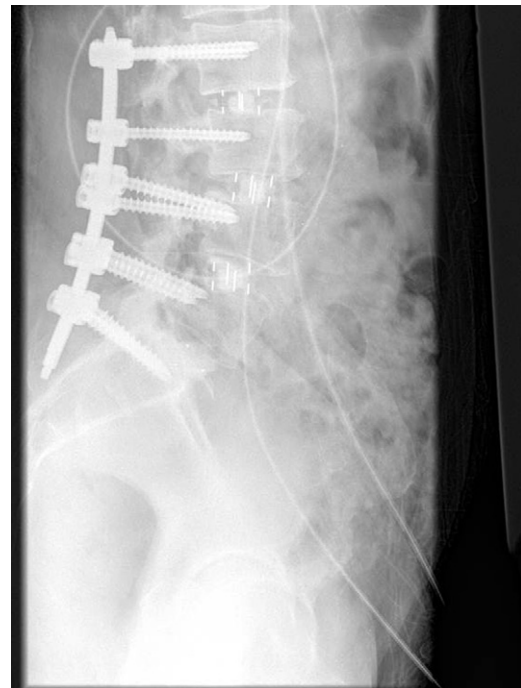

Fig. 9. Lateral postoperative radiograph.

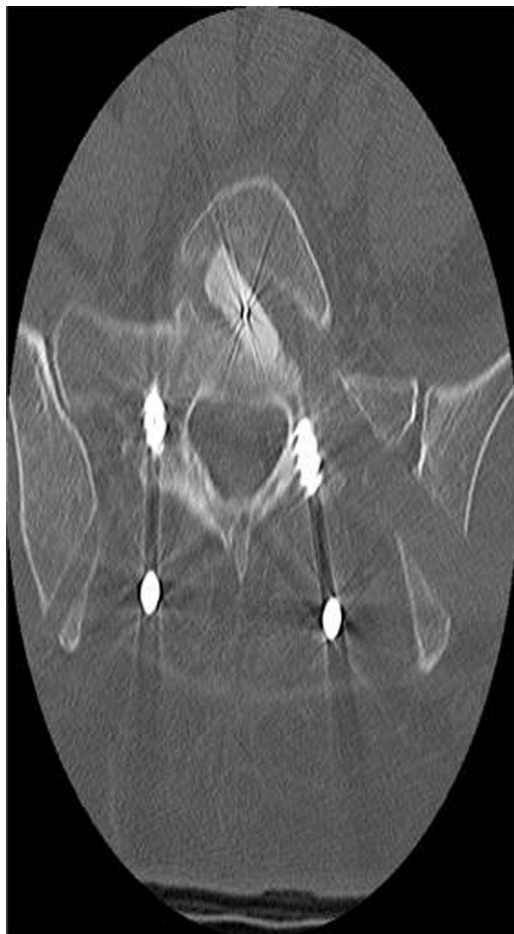

Fig. 10. Postoperative axial CT image of interbody device position.

port for a more reliable fusion. This, however, may be a more difficult approach with concerns of vascular or hypogastric plexus injury. A direct lateral approach would avoid these structures; however, unlike the higher lumbar levels, the iliac wing prevents access to the L5-S1 level. The development of a transosseous approach to reach L5-S1 avoids the risks seen with the anterior approach and will still give the surgeon an opportunity to provide a 360° fusion.

The first case presented earlier, though having been treated with a debridement procedure for infection, illustrates the utility of a bony tunnel through the sacral ala to reach the L5-S1 level for revision surgery. The second case illustrates the application for spinal reconstruction. The tunnel can be used to introduce interbody devices and bone graft for an anterior fusion at the L5-S1 level.

As this article was going to press, our attention was directed to a preprint of an article reporting on the feasibility of a similar procedure, which the authors called navigated percutaneous lumbosacral interbody fusion.<sup>8</sup> The surgical

approach used by Wang et al was essentially identical to the one we used. The primary difference was that they were using CT images on patients, whereas we used cadavers. Wang et al first examined CT data from 60 patients. With this information computerized, they built 3D models that allowed them to estimate the working space available and determine whether an S1 pedicle screw could be accommodated in the sacral ala without penetrating the spinal canal or the sacral wall. The space needed was verified in all 60 patients. In addition, the procedure was completed on 3 cadaveric specimens. A preoperative plan required 3 to 5 minutes on the navigation workstation and intraoperative CT scanning of approximately 30 seconds. Wang et al confirmed the feasibility of this approach and called for clinical studies to investigate its usefulness in clinical practice.

## Conclusion

The pelvic and lumbosacral articulations comprise a complex 3D structure that can be difficult to interpret with conventional 2-dimensional imaging. With the advent of computer guidance and intraoperative CT, one can gain a better understanding of the anatomy intraoperatively. Our study confirms the feasibility of performing a transosseous approach to the intervertebral disc space of the lumbosacral junction. Further studies will need to be conducted to evaluate instrumentation and perform biomechanical analysis of the interbody fusion technique.

## References

1. Papadoulas S, Konstantinou D, Kourea HP, Kritikos N, Haftouras N, Tzolakis JA. Vascular injury complicating lumbar disc surgery. A systematic review. *Eur J Vasc Endovasc Surg* 2002;24:189–95.
2. Rajaraman V, Vingan R, Roth P, Heary RF, Conklin L, Jacobs GB. Visceral and vascular complications resulting from anterior lumbar interbody fusion. *J Neurosurg* 1999;91(Suppl 1):60–4.
3. Botolin S, Agudelo J, Dwyer A, Patel V, Burger E. High rectal injury during trans-1 axial lumbar interbody fusion L5-S1 fixation: a case report. *Spine* 2010;35:E144–8.
4. Aryan HE, Newman CB, Gold JJ, Acosta FL Jr, Coover C, Ames CP. Percutaneous axial lumbar interbody fusion (AxiaLIF) of the L5-S1 segment: initial clinical and radiographic experience. *Minim Invasive Neurosurg* 2008;51:225–30.
5. Craig A, Carl A, Casteneda F, Dickman C, Guterman L, Oliveira C. New percutaneous access method for minimally invasive anterior lumbosacral surgery. *J Spinal Disord* 2004;17:21–8.
6. Dewald CJ, Millikan KW, Hammerberg KW, Doolas A, Dewald RL. An open, minimally invasive approach to the lumbar spine. *Am Surg* 1999;65:61–8.
7. Guiot BH, Khoo LT, Fessler RG. A minimally invasive technique for decompression of the lumbar spine. *Spine* 2002;27:432–8.
8. Wang Y, Le D, Li H, Wang M, Bunker E. Navigated percutaneous lumbosacral interbody fusion: a feasibility study with 3D surgical stimulation and cadaveric experiment. *Spine (Phila Pa 1976)* 2011;36:E1105–11.