



Infliximab recovers central cone dysfunction with normal fundus in a patient with ulcerative colitis

Miyako Chiba-Mayumi, Toshiaki Hirakata^{*}, Masahiro Yamaguchi, Akira Murakami

Department of Ophthalmology, Juntendo University Faculty of Medicine, Tokyo, Japan

ARTICLE INFO

Keywords:

Autoimmune retinopathy
Acute zonal occult outer retinopathy
Full-field electroretinogram
Cone dysfunction
Multifocal electroretinogram
Uveitis

ABSTRACT

Purpose: To report the efficacy of anti-tumor necrosis factor α (anti-TNF α) on autoimmune-mediated macular cone dysfunction in a Japanese woman with ulcerative colitis (UC).

Observations: A 41-year-old woman presented with bilateral visual acuity loss and photophobia. She suffered from UC, and had been treated with prednisolone and 5-aminosalicylate since age 37. Although fundus photographs and optic coherence tomography images were unremarkable, electroretinograms (ERGs) were abnormal. A full-field electroretinogram (full-field ERG) revealed mildly decreased cone responses and oscillatory potential responses bilaterally. Importantly, focal-macular ERG (fmERG) and a multifocal electroretinogram (mfERG) revealed severe macular cone dysfunction in both eyes. Infliximab, a chimeric monoclonal anti-TNF α antibody, was administered to treat recurrent abdominal symptoms and continued at 8-week intervals. Almost 6 months after infliximab therapy, the mfERG response (especially in the central retina), the fmERG response, and visual acuity recovered bilaterally. Abdominal symptoms also improved after infliximab therapy.

Conclusions and importance: Bilateral cone dysfunction with normal fundus were observed in a UC patient, resulting in loss of visual acuity and photophobia. This retinopathy may have been caused by an autoimmune mechanism, such as an autoimmune retinopathy or acute zonal occult outer retinopathy, which is most identifiable by ERG changes. This is the first report demonstrating the efficacy of infliximab in autoimmune retinal dysfunction.

1. Introduction

Common ocular pathologies of inflammatory bowel diseases (IBDs) such as ulcerative colitis (UC), Crohn's disease, and Behcet's disease include bilateral uveitis, scleritis, and optic neuropathy.¹ Ocular inflammation is usually controllable with corticosteroids.² On the other hand, systemic IBD symptoms are usually treated with oral 5-aminosalicylic acid, prednisolone, azathioprine, and/or intravenous administration of anti-tumor necrosis factor α (anti-TNF α) monoclonal antibodies.³

Sometimes, patients with autoimmune retinopathy (AIR) have a history of systemic autoimmune diseases, including IBDs.⁴ AIR causes various pathologies, including loss of visual acuity, photophobia, photopsia, and night blindness, despite normal fundus findings in most cases.^{5,6} However, no effective therapeutics have been identified for AIR.

Here, we report a rare case of cone dysfunction in a patient with UC that presented as visual acuity loss and photophobia, despite unremarkable fundus imaging and OCT images, and no evidence of ocular

inflammation. Steroid treatment did not control the retinopathy, but infliximab, a chimeric anti-TNF α monoclonal antibody, improved visual acuity and cone function.

2. Case report

A Japanese woman with UC developed bilateral loss of visual acuity and photophobia beginning at 41 years-of-age. The patient began treatment for UC (prednisolone and 5-aminosalicylate) at 37 years-of-age, but continued to suffer from recurrent abdominal symptoms. The patient also had a history of bronchial asthma, depression, and a benign adrenal tumor.

Initially, the patient was assessed at our clinic when she was 42 years-of-age. Upon initial assessment, best-corrected visual acuity (BCVA) was 20/70 (OD) and 20/50 (OS), and intraocular pressure was 19 mmHg (OS) and 14 mmHg (OD). Neither slit-lamp examination nor funduscopy revealed abnormalities associated with inflammation or uveitis in either eye. Funduscopy images (Fig. 1A), fundus

^{*} Corresponding author.

E-mail address: t-hirakata@juntendo.ac.jp (T. Hirakata).

<https://doi.org/10.1016/j.ajoc.2021.101244>

Received 8 October 2020; Received in revised form 30 May 2021; Accepted 13 December 2021

Available online 14 December 2021

2451-9936/© 2021 Published by Elsevier Inc. This is an open access article under the CC BY-NC-ND license (<http://creativecommons.org/licenses/by-nc-nd/4.0/>).

autofluorescence (Fig. 1B), and fluorescein angiography (Fig. 1C) did not reveal abnormalities in either eye. Optical coherence tomography (OCT) images of both eyes were unremarkable (Fig. 2A). Goldman perimetry and Humphrey visual field analysis only revealed slightly extended Mariotte blind spots in both eyes (Fig. 1D).

Electrophysiological examinations were performed according to International Society for Clinical Electrophysiology of Vision (ISCEV) standards.^{7,8} A full-field ERG revealed normal responses in dark-adapted 0.01 cd s m⁻² (DA 0.01), but slight bilateral reductions in oscillatory potential (OP) responses were observed on bright flash ERG (DA 10.0) (Fig. 3). However, light-adapted single cone-flash response (LA 3.0) with 8Hz stimulus interval revealed a bilateral decrease in both a- and b-wave responses, and LA 3.0 30 Hz flicker ERG revealed a bilateral decrease in amplitude and delayed implicit time (Fig. 3A, B and E). Although cone responses in the full-field ERG were mildly affected, a multifocal electroretinogram (mfERG) revealed widely reduced amplitude in both eyes (Fig. 4A). The foveal response in the right eye was lower than that in the left eye, corresponding with visual acuity.

During the observation period, the patient's visual acuity and UC symptoms (abdominal pain and diarrhea) gradually worsened. The physician then initiated infliximab therapy (300 mg at week 0, 2, 4, and 6, and then every 8 weeks) to treat recurrent abdominal symptoms. On the day of the first infliximab treatment the patient noticed an

immediate change in her subjective vision. The patient's visual acuity improved gradually as infliximab treatment progressed (Fig. 5B). At 6 months after infliximab treatment, BCVA in the left eye recovered completely (to 20/20) and to 20/22 in the right eye (Fig. 5B). Then, BCVA in the right eye reached 20/20 at 9 months after starting infliximab treatment (Fig. 5B). Good visual acuity in both eyes was preserved during second half of the follow-up period (6–12 months). OCT images revealed no abnormalities and did not differ from images taken before infliximab therapy (Fig. 2B).

Three months after infliximab administration, fmERG still showed continued a reduction of a-wave, b-wave, and OP responses (Fig. 6). Remarkably, fmERG revealed recovery of macular function in both eyes 6 months after infliximab therapy (Fig. 6). Additionally, mfERG responses improved significantly in both eyes after infliximab therapy. The mfERG revealed that central retinal response in the right eye reached the normal range at 9 months after infliximab therapy, and that in the left eye reached the normal range at 6 months post-therapy (Figs. 4B, 5A and 5C). On the other hand, pericentral retinal responses in the mfERG took longer to recover than central retinal responses; indeed, they tended better, but had not recovered completely 1 year after infliximab therapy (Figs. 4B, 5A and 5C-F). On the other hand, one year after initiation of infliximab therapy, the amplitude in the 30 Hz flicker full-field ERG also slightly improved in both eyes, but OP

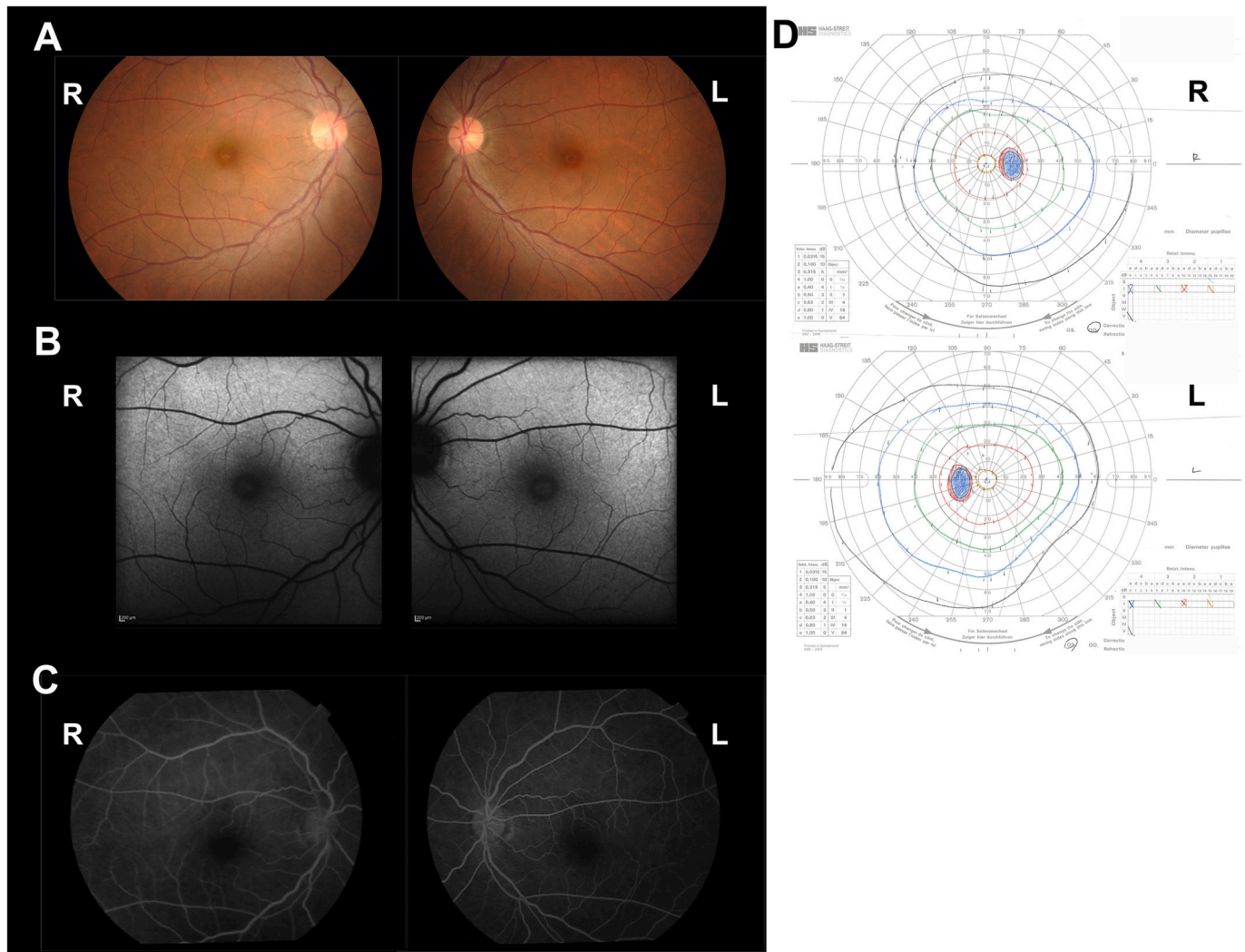


Fig. 1. Unremarkable fundus ophthalmoscopy images and visual field tests. (A) Fundus ophthalmoscopy, (B) fundus autofluorescence, and (C) fluorescein angiography images demonstrating no abnormalities in either eye. (D) Goldmann perimetry was normal in both eyes (except for extended Mariotte blind spots). R, right eye; L, left eye.

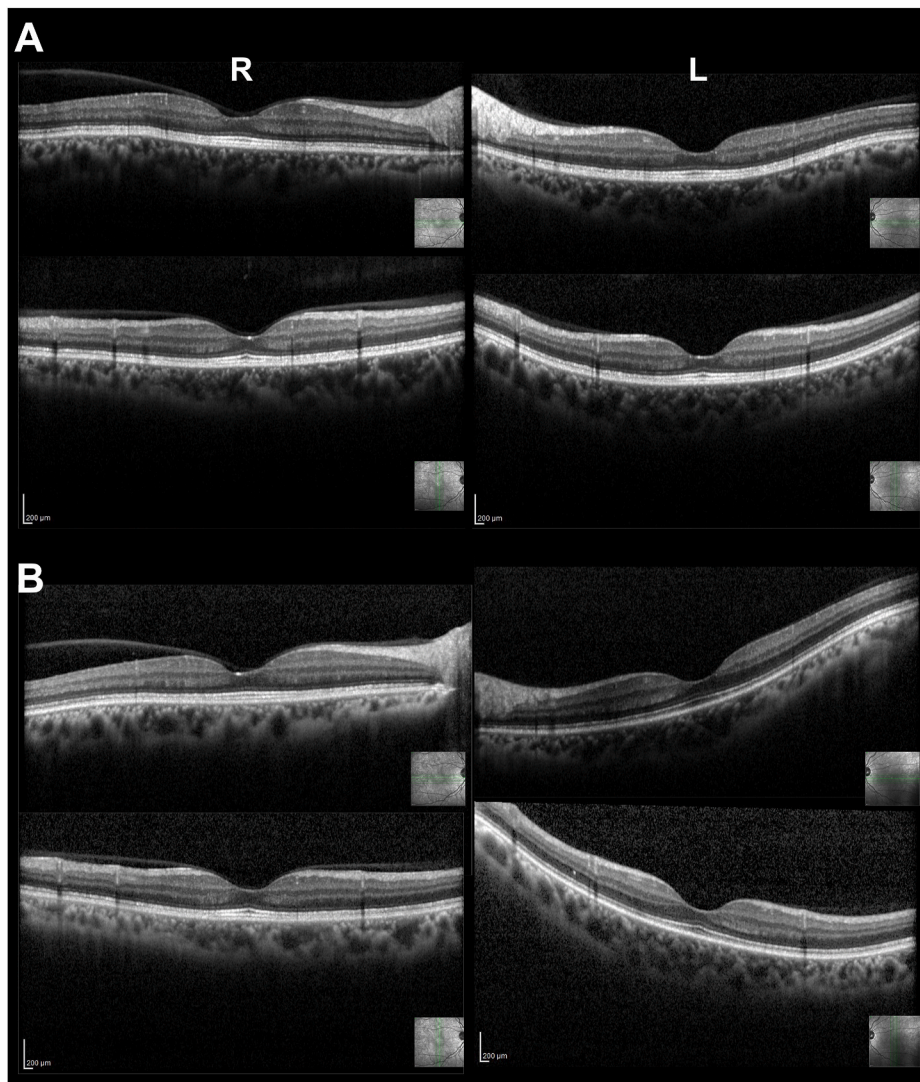


Fig. 2. Normal OCT findings in both eyes. (A) OCT images before infliximab, and (B) OCT images after infliximab. R, right eye; L, left eye.

responses (DA 10.0) and cone responses remained modestly decreased (Fig. 3).

Alongside improved visual function, infliximab therapy also alleviated the patient's abdominal symptoms. Infliximab (300 mg) was continued every 8 weeks for maintaining the visual function and systemic status. During follow-up after visual acuity reaching 20/20 in both eyes (6–12 months), mfERG responses were still unstable (Fig. 5B and C). Interestingly, approximately every 8th week after infliximab administration, the patient complained of worsening abdominal and visual symptoms, suggesting loss of the infliximab effect. Additionally, infliximab re-administration recovered again the subjective visual function, but it took 1–2 weeks after infliximab administration. Indeed, although visual acuity was preserved 1 year after starting infliximab therapy, the area 1 amplitude of the bilateral mfERG response at 12 months after infliximab treatment was lower than previous follow-up points (Fig. 5A and C). Continued infliximab therapy was required to maintain improvements in visual and systemic symptoms.

3. Discussion

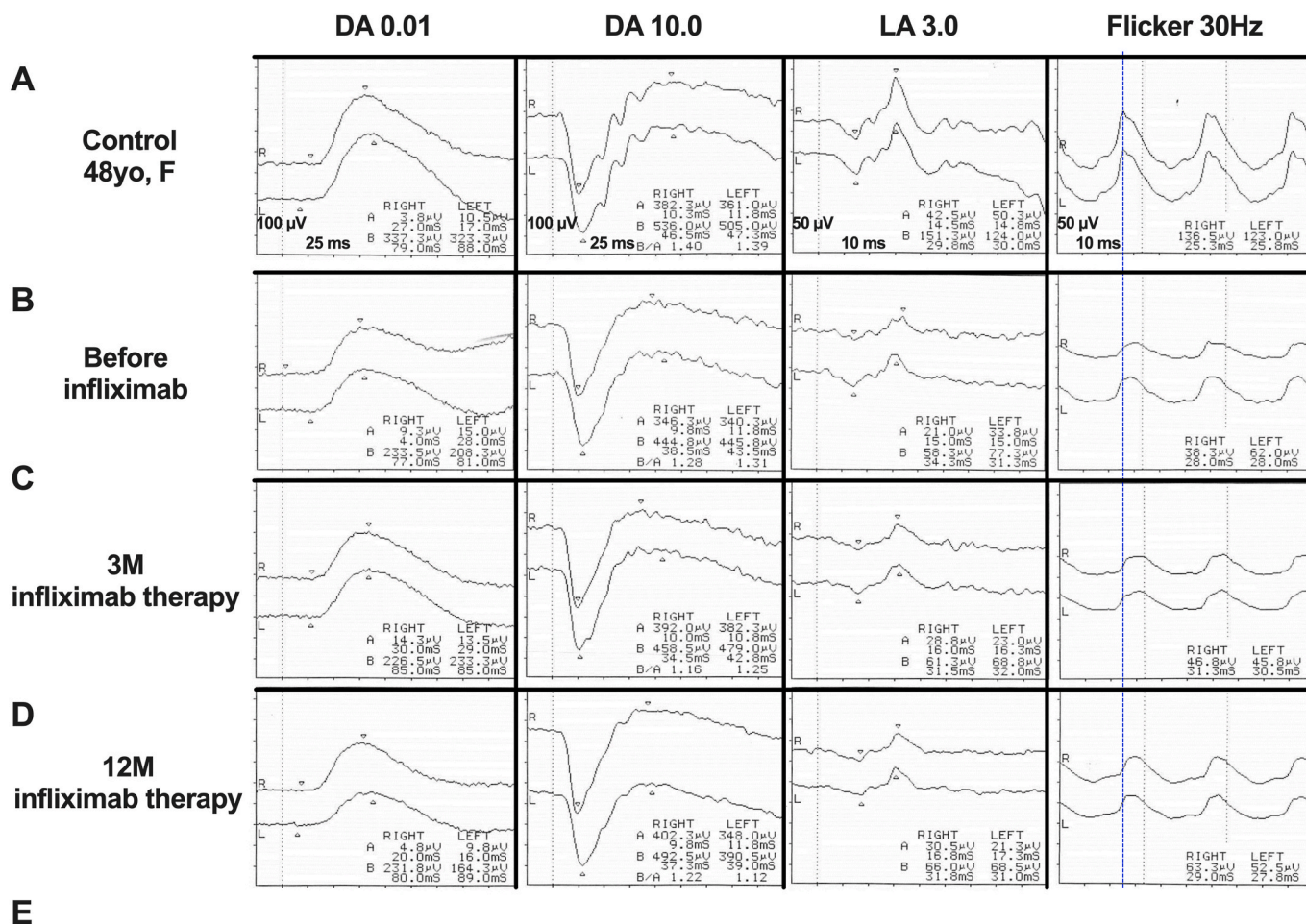
Although the patient had UC and loss of visual acuity, there were no clinically detectable inflammatory pathologies, and funduscopy was normal in both eyes. Electrophysiological examinations revealed cone dysfunction, especially in the macula, which was the likely cause of

visual acuity loss and photophobia. These findings were suggestive of an autoimmune retinal disorder such as acute zonal occult outer retinopathy (AZOOR) or AIR. Interestingly, the extent of visual acuity loss was associated with the severity of UC; anti-TNF α therapy alleviated both visual function and systemic symptoms in this case. This suggests that factors involved in the systemic pathology of UC could also drive associated retinal disorders.

Full-field ERG revealed mild cone dysfunction. By contrast, both mfERG and fmERG responses were reduced significantly. Moreover, the improvement after infliximab therapy was clearly observed on mfERG and fmERG. These results suggest that retinal damage was localized to the macula. The time to improved visual acuity and ERG responses suggests that more than 6 months were required to recover full visual function.

AZOOR and AIR cause various pathologies, including visual acuity loss, photophobia, photopsia, and night blindness, despite normal fundus.^{5,6} Often, AIR patients have a history of autoimmune disease.⁴ In the present case, the patient had UC and suffered bilateral loss of visual acuity and photophobia, despite the absence of fundus abnormalities. ERGs indicated cone dysfunction with normal rod function. These clinical features suggest AIR, but in the present case immunoblot analysis had not been performed yet.

The findings in this case, including normal fundus appearance, loss of visual acuity, and cone dysfunction are consistent with AZOOR.⁶



	DA 0.01		DA 10.0				LA 3.0				Flicker	
	b-wave		a-wave		b-wave		a-wave		b-wave			
	A (μV)	I (ms)	A (μV)	I (ms)	A (μV)	I (ms)	A (μV)	I (ms)	A (μV)	I (ms)	A (μV)	I (ms)
Control (45.3±3.8 yo)	319.8±62.5	89.7±11.1	375.8±6.2	11.4±2.0	531.8±50.4	49.4±2.1	45.8±2.3	15.3±0.7	123.1±19.8	31.2±1.3	118.2±14.6	26.3±0.3
Case (42 yo)												
Before Infliximab	R 233.5	77.0	346.3	9.8	444.8	38.5	21.0	15.0	58.3	34.3	38.3	28.0
	L 208.3	81.0	340.3	11.8	445.8	43.5	33.8	15.0	77.3	31.3	62.0	28.0
3M Infliximab therapy	R 226.5	85.0	392.0	10.0	458.5	34.5	28.8	16.0	61.3	31.5	46.8	31.3
	L 223.3	85.0	382.3	10.8	479.0	42.0	23.0	16.3	68.8	32.0	45.8	30.5
12M Infliximab therapy	R 231.8	80.0	402.3	9.8	492.5	37.3	30.5	16.8	66.0	31.8	63.3	29.0
	L 164.3	89.0	348.0	11.8	390.5	39.0	21.3	17.3	68.5	31.0	52.5	27.8

Fig. 3. Full-field ERGs showed mildly cone dysfunction. Full-field electroretinogram (full-field ERG) was recorded using a contact lens with a built-in LED stimulating system (LE4000; TOMEY, Nagoya, Japan). Full-field ERG was recorded under dark-adapted (DA) and light-adapted (LA) conditions, including dark-adapted 0.01 cd s m⁻² (DA 0.01) and mixed rod-cone DA 10.0 after 20 minutes of dark adaptation. A light-adapted single-flash cone response (LA 3.0) was recorded with an 8 Hz stimulus interval, and an LA 3.0 30 Hz flicker was recorded after 10 min light adaptation. Full-field ERG responses (A) in a normal control (48 years old, female), (B) in the UC patient before infliximab treatment, (C) in the UC patient 3 months after beginning infliximab treatment, and (D) in the UC patient 1 year after beginning infliximab treatment. (E) Each amplitude and implicit time of full-field ERG are shown. Age matched (40–49 years old) three Japanese female was recruited for normal control and recorded by full-field ERG with the same protocol in our institute. Normative value (mean and standard deviation) includes the (A) representative case. The mean age of normal control was 45.3 ± 3.8 years old. A, amplitude; DA, dark adapted; I, implicit time; LA, light adapted; OP, oscillatory potential; R, right eye; L, left eye; yo, years old.

However, the patient did not have photopsia, and visual field defects corresponded to the depressed response in the mfERG. Further OCT abnormalities in the photoreceptor layer (outer retinal line), which are characteristic of AZOOR, were not present. These findings did not match the typical phenotype of AZOOR complex,⁶ suggesting that AZOOR could be excluded in this case.

Full-field ERG revealed decreased OP responses in both eyes, which is sometimes observed in uveitis. Previously, Takeuchi et al. reported that disappearance or disruption of the outer retinal line in patients with uveitis associated with Behcet's disease was detectable in OCT,⁹ and that

this was alleviated by infliximab therapy. That report suggests the efficacy of infliximab for suppressing retinal inflammation. However, our case did not present with clinically detectable inflammation in either eye, and the OCT findings were unremarkable.

Interestingly, the severity of systemic and ocular symptoms was linked. These findings suggest that the pathology of UC could be associated with retinal disorders. IBD increases levels of TNFα, interleukin (IL)-1β, and IL-6.¹⁰ TNFα is a classic proinflammatory cytokine produced by antigen-presenting cells and macrophages; the cytokine promotes inflammation (in part) by increasing production of IL-1β and IL-6.^{11,12}

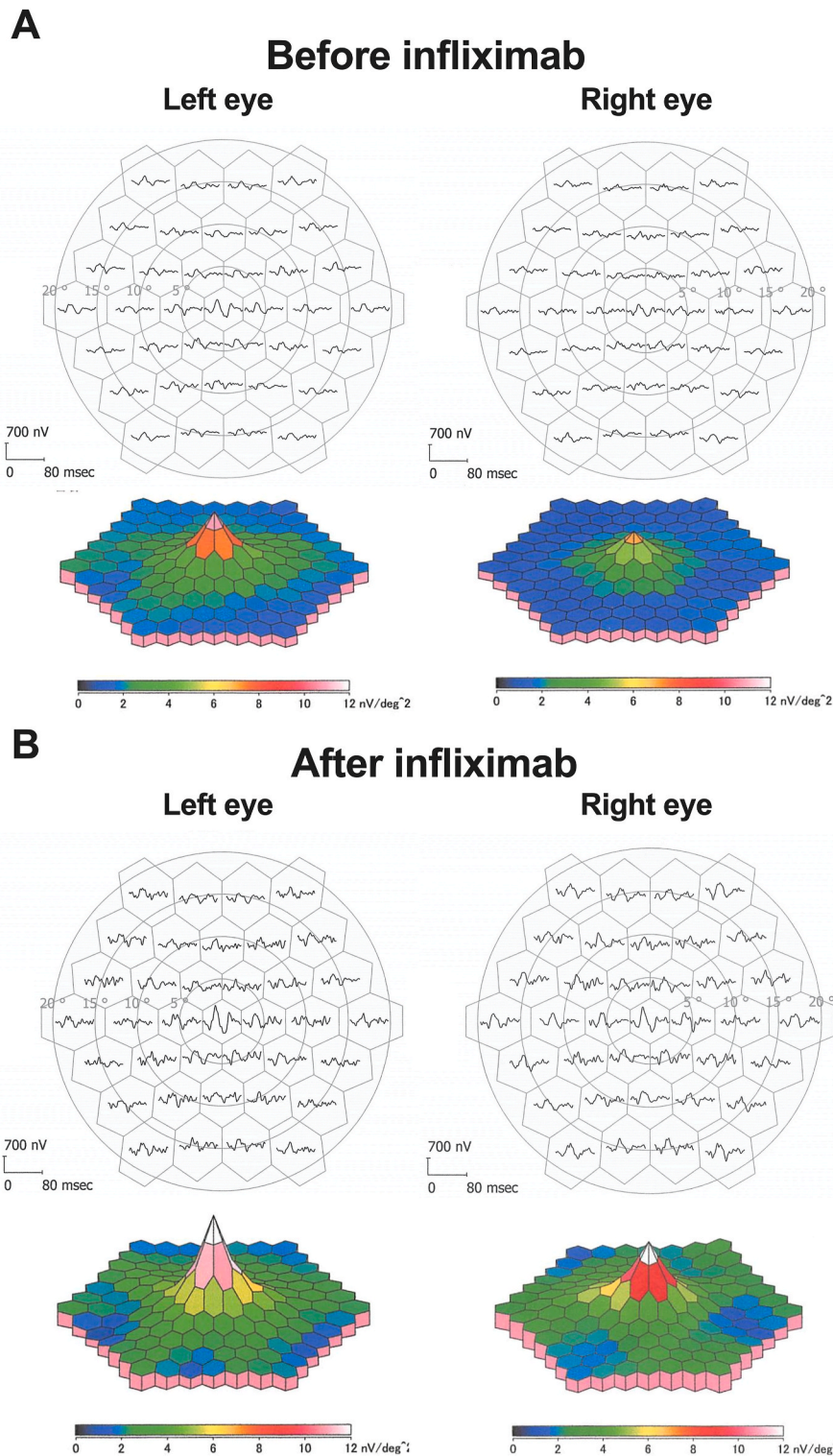


Fig. 4. Improvement of multifocal ERG during infliximab therapy. A multifocal electroretinogram (mfERG) was recorded using a commercial mfERG system (LE4100; TOMÉY, Nagoya, Japan). MfERG responses are shown (A) before infliximab treatment, and (B) 9 months after infliximab therapy in the right eye, and 6 months after infliximab therapy in the left eye.

Moreover, Detrick et al. reported significant elevation of IL-6 levels in sera from patients with AIR; indeed, IL-6 is currently being investigated as a novel therapeutic target for AIR.¹³ These findings suggest that the therapeutic effect of anti-TNF α therapy in AIR may be mediated via suppression of IL-6. In the present case, UC may work indirectly to develop AIR as a background factor, including the presence of TNF α , IL-6, and other cytokines and chemokines.

Although the patient recovered bilateral visual acuity and central cone responses, full-field cone and OP responses and pericentral retinal responses on mfERG remained slightly dysfunctional after treatment. The AIR in the present case could have complicated the pathology, not only by increasing TNF α levels but also through various additional factors such as anti-retinal antibodies and other proinflammatory mediators.

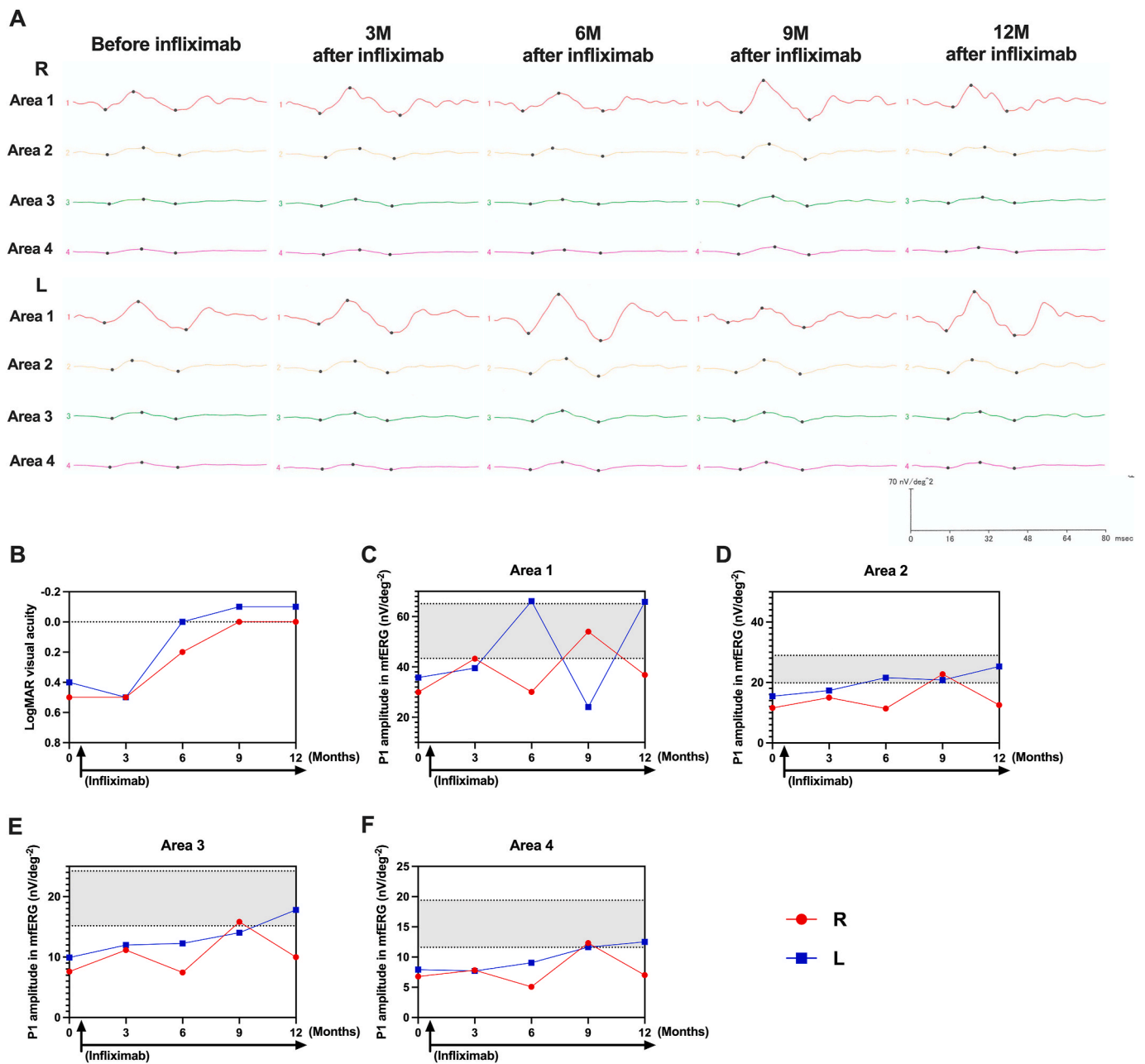


Fig. 5. Improved multifocal ERG response and visual acuity during infliximab therapy. (A) Averaged multifocal electroretinogram (mfERG) responses in areas 1–4 during follow-up. (B) One-year follow-up of the minimum angle of resolution logarithm (LogMAR) visual acuity. The dotted line reveals 0 in LogMAR visual acuity (decimal acuity 1.0). One-year follow-up of averaged mfERG P1 amplitude in (C) area 1, (D) area 2, (E) area 3, and (F) area 4. (C–F) The gray area surrounded by a dotted line in each graph denotes a normative range of the mean of normal control (44.0 ± 2.6 years old). Age matched (40–49 years old) six female was recruited for normal control and recorded by mfERG with the same protocol in our institute. The gray area showed the each are of the mean of P1 normative range with standard deviation: area 1, 54.3 ± 10.9 nV/deg²; area 2, 24.4 ± 4.6 nV/deg²; area 3, 19.7 ± 4.5 nV/deg²; area 4, 15.5 ± 3.9 nV/deg².

At 1 year after infliximab therapy, visual acuity was good, but mfERG responses had deteriorated, despite ongoing maintenance infliximab treatment. This phenomenon could be caused by the timing of mfERG recording. During the follow-up after visual acuity improvement (6–12 months), subjective visual symptoms worsened before and after infliximab re-administration. It strongly suggests infliximab effects on this retinopathy, while this retinopathy have not been completely improved. On the other hand, mfERG responses of each areas tended to improve gradually during one-year infliximab treatment (Fig. 5C–F). Although at 9 months, P1 amplitude in area 1 of mfERG in the left eye was seemingly decreased, but it might be caused by fixation shift (Fig. 5A and C).

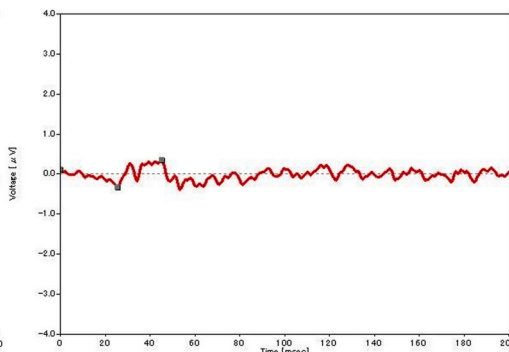
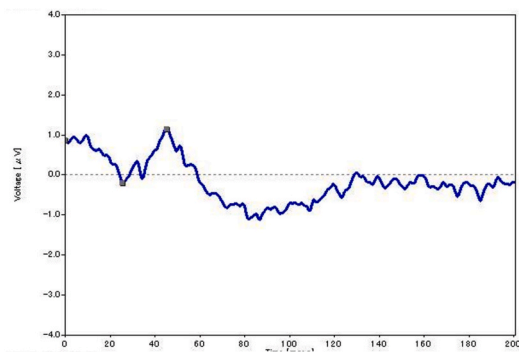
Continuation of infliximab treatment can have a better effect on retinal function. The mfERG results seemed to correspond with the patient’s visual symptoms. MfERG or fmERG could be more sensitive for evaluating retinal function. These findings suggest that in this case of AIR associated with UC, regular infliximab therapy is needed to maintain improvements in visual function. ERGs are key examinations for diagnosis of the autoimmune retinal disorder, as fundus images are typically normal in this type of retinopathy; in most cases, no clinically visible signs of ocular inflammation are present.

Right eye

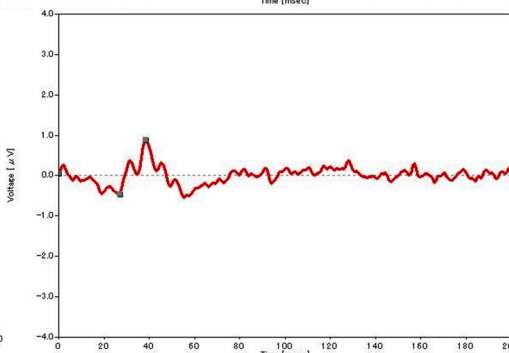
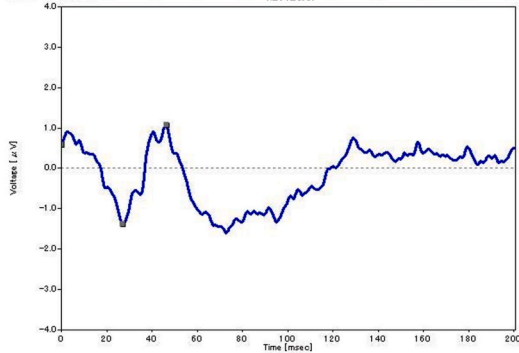
fmERG

OP

**3M
after infliximab**

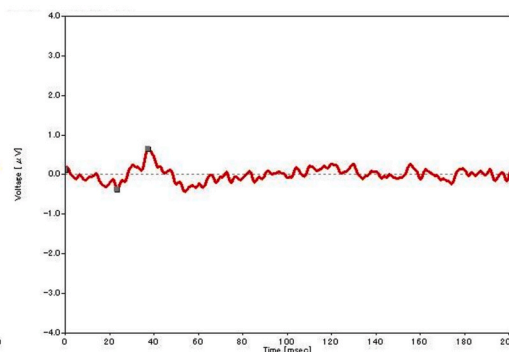
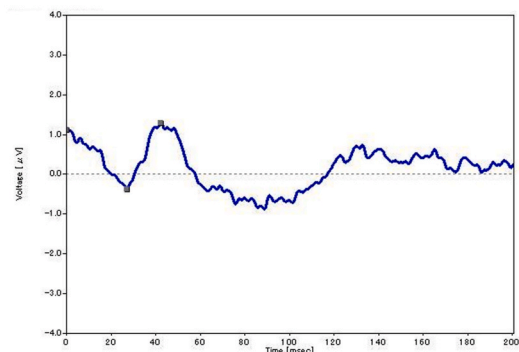


**6M
after infliximab**



Left eye

**3M
after infliximab**



**6M
after infliximab**

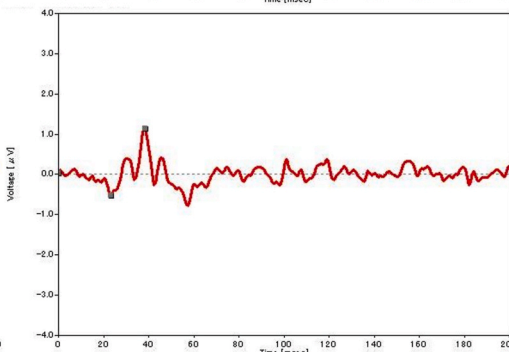
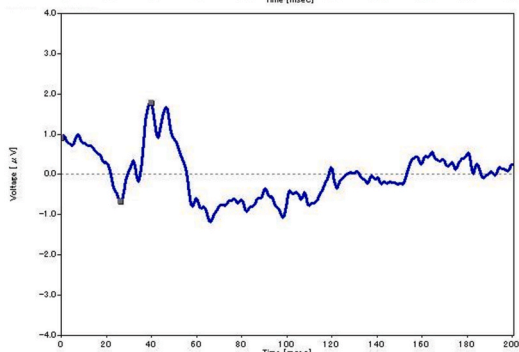


Fig. 6. Improved focal-macular ERG responses during infliximab therapy. A focal-macular ERG (fmERG) was recorded using an ER-80 apparatus (Kowa, Tokyo, Japan) at 3 months and 6 months after infliximab therapy. The luminance of white stimulus light and background illumination were 30 and 1.5 cd/m², respectively. A background field with a 45° visual angle was projected onto the eye from the fundus camera. Focal ERGs were elicited by 5 Hz rectangular stimuli (100 ms light on and 100 ms light off). The 15° circular stimulus was carefully and continuously centered on the fovea, as observed on an infrared camera monitor. Three-hundred ERGs were averaged by a signal processor (PuREC; Mayo, Aichi, Japan). Focal ERGs were digitized at 10 kHz, with a band-pass filter of 5–500 Hz for the a-wave and b-wave. The fmERG responses at 6 months after infliximab therapy were better than those at 3 months after infliximab therapy.

4. Conclusion

The present study documents a case of UC with macular cone dysfunction with normal fundus and absence of uveitis, which is

suggestive of autoimmune retinal diseases including AZOOR or AIR. This is the first report to identify the efficacy of the chimeric monoclonal anti-TNF α antibody infliximab for the autoimmune retinal dysfunction. Thus, infliximab may be a good treatment for autoimmune retinal

diseases.

Patient consent

Informed consent was obtained from the patient. This report does not contain any personal information that could lead to the patient's identification. This study was approved by the Ethics Committee of Juntendo University (JHS-19-017), and was conducted in accordance with the Tenets of the Declaration of Helsinki.

Author contributions

T.H. designed all of the experiments. M.C.-M., T.H., and M.Y. recruited and followed up the patient. M.C.-M., T.H., M.Y., and A.M. wrote the manuscript.

Declaration of competing interest

The authors declare no conflicts of interest.

Acknowledgments

This work was supported by the JSPS KAKENHI Grants (19K23851 and 20K18395 to T.H.).

References

- Mintz R, Feller ER, Bahr RL, Shah SA. Ocular manifestations of inflammatory bowel disease. *Inflamm Bowel Dis.* 2004;10:135–139.
- Soukiasian SH, Foster CS, Raizman MB. Treatment strategies for scleritis and uveitis associated with inflammatory bowel disease. *Am J Ophthalmol.* 1994;118:601–611.
- Greco A, De Virgilio A, Ralli M, et al. Behcet's disease: new insights into pathophysiology, clinical features and treatment options. *Autoimmun Rev.* 2018;17:567–575.
- Heckenlively JR, Ferreyra HA. Autoimmune retinopathy: a review and summary. *Semin Immunopathol.* 2008;30:127–134.
- Braithwaite T, Vugler A, Tufail A. Autoimmune retinopathy. *Ophthalmologica.* 2012;228:131–142.
- Gass JD, Agarwal A, Scott IU. Acute zonal occult outer retinopathy: a long-term follow-up study. *Am J Ophthalmol.* 2002;134:329–339.
- McCulloch DL, Marmor MF, Brigell MG, et al. ISCEV Standard for full-field clinical electroretinography (2015 update). *Doc Ophthalmol.* 2015;130:1–12.
- Hood DC, Bach M, Brigell M, et al. ISCEV standard for clinical multifocal electroretinography (mfERG) (2011 edition). *Doc Ophthalmol.* 2012;124:1–13.
- Takeuchi M, Harimoto K, Taguchi M, Sakurai Y. Reconstitution of disrupted photoreceptor layer in uveitis associated with Behcet's disease by infliximab treatment. *BMC Ophthalmol.* 2015;15:177.
- Stevens C, Walz G, Singaram C, et al. Tumor necrosis factor-alpha, interleukin-1 beta, and interleukin-6 expression in inflammatory bowel disease. *Dig Dis Sci.* 1992;37:818–826.
- Baumann H, Gaudie J. The acute phase response. *Immunol Today.* 1994;15:74–80.
- Begue B, Wajant H, Bambou JC, et al. Implication of TNF-related apoptosis-inducing ligand in inflammatory intestinal epithelial lesions. *Gastroenterology.* 2006;130:1962–1974.
- Detrick B, Gangaputra S, Palsgrove DN, Heaney CD, Hooks JJ, Nida Sen H. Elevated serum levels of IL-6 and CXCL9 in autoimmune retinopathy (AIR) patients. *J Neuroimmunol.* 2018;316:74–79.