



Contents lists available at ScienceDirect

International Journal of Surgery Case Reports

journal homepage: www.casereports.com

Endotracheal hamartoma case report: Two contrasting clinical presentations of a rare entity

Curtis Hon^a, Carl J. O'Hara^b, Virginia R. Litle^{c,*}^a Boston University School of Medicine, 72 East Concord St, Boston, MA, 02118, United States^b Department of Pathology, Boston University School of Medicine, 72 East Concord St, Boston, MA, 02118, United States^c Division of Thoracic Surgery, Department of Surgery, Boston University School of Medicine, 72 East Concord St, Boston, MA, 02118, United States

ARTICLE INFO

Article history:

Received 18 March 2017

Received in revised form 12 July 2017

Accepted 15 July 2017

Available online 20 July 2017

Keywords:

Endotracheal hamartoma

Histology

Lung pathology

ABSTRACT

INTRODUCTION: The majority of tracheal tumors in adults are malignant. The finding of a benign tumor in the trachea is uncommon and endotracheal hamartomas are rare.

PRESENTATION OF CASE: We report two cases presenting within six months at our institution. The first patient is a 67 year-old man who was found to have an asymptomatic endotracheal hamartoma on chest imaging for aortic valve replacement. The second patient is a 46 year-old man with an extensive continued tobacco use disorder and a known endotracheal lesion identified 8 years prior to intervention. Both patients were treated surgically and recovered without complications.

DISCUSSION: Identification of these lesions and timely management are necessary because without intervention, they can lead to fatal complications. Most symptoms of tracheal hamartoma result from mechanical obstruction with the earliest presenting symptom being dyspnea, but as evident in these two cases, they can have different presentations.

CONCLUSION: We have found that endotracheal hamartoma has a tendency to present in Caucasian, male patients with a comorbidity of respiratory disease and variable smoking history, but it can also present in asymptomatic patients with no significant smoking history.

© 2017 The Authors. Published by Elsevier Ltd on behalf of IJS Publishing Group Ltd. This is an open access article under the CC BY-NC-ND license (<http://creativecommons.org/licenses/by-nc-nd/4.0/>).

1. Introduction

Primary tracheal tumors are typically malignant with only 10% being benign. While hamartomas are the most common subtype of pulmonary tumors, localization to the trachea is exceptionally rare, especially in adults [1]. Tracheal hamartomas commonly manifest with varying degrees of respiratory distress, ranging from acute respiratory failure to cough, hemoptysis, and chest pain. Due to the slow-growing nature of these lesions, symptoms are often gradual and persistent, mimicking the presentation of chronic obstructive pulmonary disease (COPD) and further obscuring timely diagnosis and treatment [2]. Failure to detect tracheal hamartoma may cause fatal airway obstruction [3]. Of the few documented cases of tracheal hamartoma, the majority have been Caucasian males with variable histories of tobacco use and underlying respiratory condition masquerading the hamartoma. We report one case of endotracheal hamartoma with a more common presentation and a

second case that is inconsistent with previously documented cases. The work has been reported in line with the SCARE criteria [4].

2. Presentation of case

2.1. Case #1

A 67-year-old man with a history of hypertension, severe aortic regurgitation, and a remote less than two-pack year smoking history presented to clinic for evaluation of aortic valve replacement. On a chest computed tomography (CT) scan he was found to have an incidental endotracheal lesion (Fig. 1). The patient was asymptomatic, denying cough, hemoptysis, and shortness of breath.

The patient went to the operating room and on flexible bronchoscopy there was a polypoid lesion on a stalk obstructing 50% of the lumen on the lateral tracheal wall. There were no other endobronchial lesions. We removed the lesion via a rigid bronchoscope. A small amount of bleeding was easily controlled with the neodymium-doped yttrium aluminium garnet (Nd:YAG) laser. On frozen section, the lesion was consistent with a hamartoma. The patient then underwent open replacement of his aortic valve under the same general anesthesia.

* Corresponding author at: Division of Thoracic Surgery, Department of Surgery, Boston University, 88 East Newton Street, Collamore 7380, Boston, MA, 02118, United States.

E-mail address: virginia.little@bmc.org (V.R. Litle).

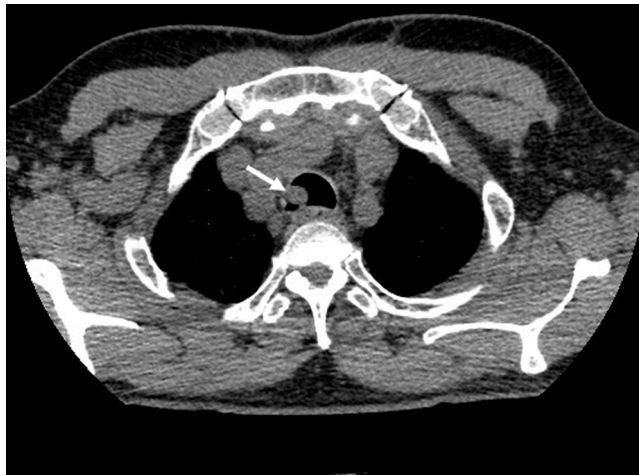

Fig. 1. Chest computed tomography scan without contrast showing polypoid endoluminal lesion in the proximal right trachea (arrow).

2.2. Case #2

A 46-year-old male with a history of hypertension, COPD, and a continued greater than 40-pack-year smoking history presented with chest pain and shortness of breath but no stridor or complaints of hemoptysis. Eight years prior, he had undergone a bronchoscopy at another hospital and was found to have a fibrinous lesion in his mid-trachea. No attempts were made to remove it. One week prior to the current presentation, he suffered a cardiopulmonary arrest, likely secondary to this lesion but was discharged from another hospital with a diagnosis of a COPD exacerbation.

On a chest x-ray there was a rounded opacity within the trachea approximately 5 cm above the carina, just inferior to the clavicular heads (Fig. 2a, b). On chest CT, there was a hypodense lesion measuring approximately 1.8 × 1.8 × 2 cm (Fig. 3).

On flexible bronchoscopy there was a polypoid lesion on a small stalk on the tracheal wall about 5 cm distal to the vocal cords. The lesion was soft and encompassed about 80% of the lumen (Fig. 4a). There were no other endobronchial lesions. Following initial visualization, we placed the suspension laryngoscopy and a flexible bronchoscope in the airway again to snare the lesion. It was about 2 cm, appeared slightly vascular, and on palpation felt slightly calcified (Fig. 4b). We replaced the bronchoscope and did not appreciate

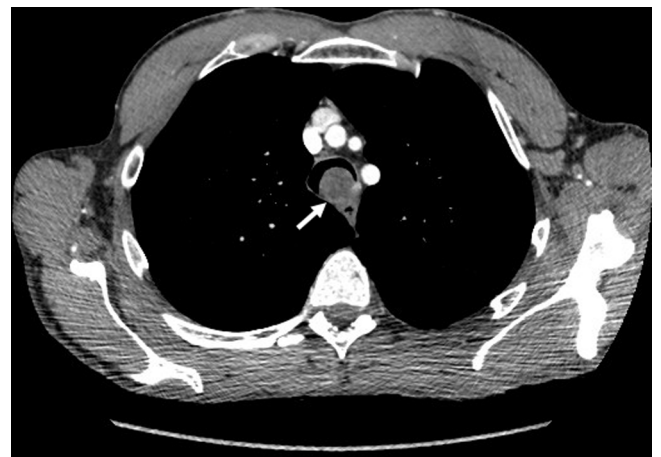

Fig. 3. Chest computed tomography scan with contrast showing a hypodense round lesion within the trachea with areas of fatty attenuation and peripheral enhancement (arrow).

any bleeding or any residual tissue at the stalk origin. The patient was extubated and discharged home from the recovery room.

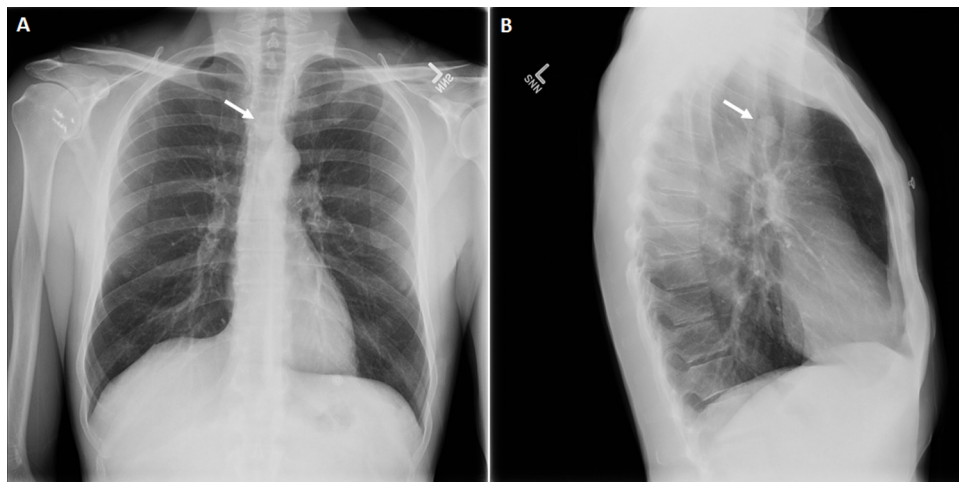


Fig. 2. Chest x-ray (A) anterior-posterior and (B) lateral showing rounded opacity within trachea approximately 5 cm above the carina, just inferior to the clavicular heads (arrow).

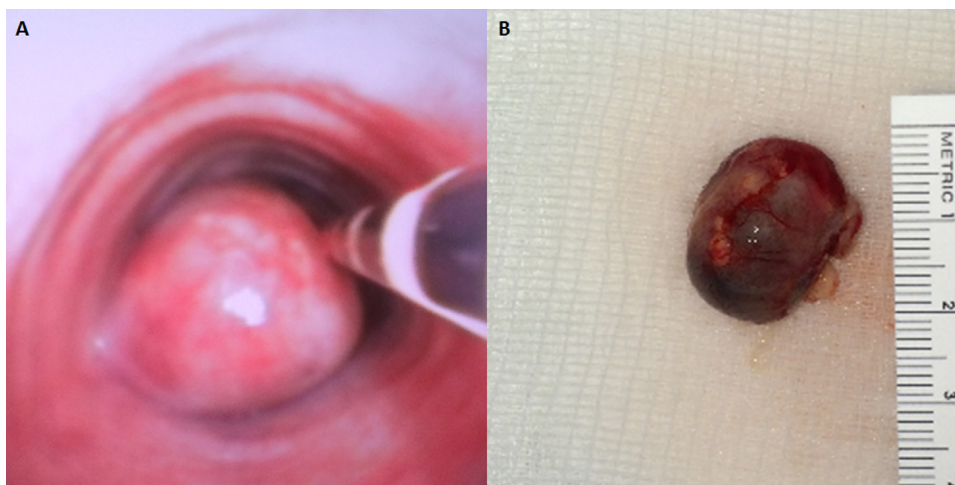


Fig. 4. (A) Flexible bronchoscopy shows a polypoid lesion at left side of trachea obstructing 80% of the lumen. (B) Excised specimen measures roughly 2 cm in diameter.

3. Discussion

A hamartoma is defined as a benign tumor-like configuration of cells presumably derived from primitive connective tissue such as cartilage, fat, bone, and smooth muscle cells [3,5]. Gardner discusses the proper usage of the term hamartoma in the context of the pathogenesis of odontogenic lesions and stresses that a hamartoma is a nonmalignant developmental anomaly [6]. From this we would expect endotracheal hamartomas to present early in life, yet the majority of documented endotracheal hamartomas, including our two cases, has presented between the 3rd and 7th decades of life. While this may indicate the propensity to ignore accurate nomenclature [6], it not only lends credence to the difficulty of diagnosis given its slow-growing nature [5], but also suggests that factors such as patient behavior or environmental exposure could contribute to acceleration of the disease to a point that is clinically presentable.

Most symptoms of tracheal hamartoma result from mechanical obstruction with the earliest presenting symptom being dyspnea, often progressing to chronic cough with or without expectoration. This leads to further delay of accurate diagnosis and the finding of many patient histories including diagnoses of chronic bronchitis, tracheitis, asthma, and other obstructive pulmonary diseases all relatively refractory to medical treatment [5]. One of our patients experienced cardiopulmonary arrest likely due to endotracheal hamartoma and Cetinkaya et al. reminds us the fatal potential of this lesion due to severe obstruction, so timely intervention is crucial. Almost all documented cases of endotracheal hamartoma with appropriate therapy, including our two cases, have resulted in minimal to no complications with a low rate of recurrence. In our literature review, an overwhelming majority of patients, like the second of our two cases, are Caucasian males with varying degrees of tobacco use and concurrent diagnoses of obstructive pulmonary disease with resolution of symptoms after surgical resection of the lesion [5,7–9]. Only one study by Suzuki et al. described a 70 year-old Japanese man with a peripheral intrapulmonary and endotracheal hamartoma but their focus was on multiple pulmonary hamartomas [2]. In that same report, they identified 14 published case reports of multiple chondromatous hamartomas split even by gender and several cases of leiomyomatous hamartomas almost exclusively female.

It is interesting to consider our first case because unlike other cases, this 67 year-old patient has an insignificant 2 pack year smoking history and he was asymptomatic at presentation. The tracheal hamartoma in this patient was discovered incidentally during an

unrelated procedure. Thus, in our contemplations of the pathogenesis of endotracheal hamartoma, it is hard to exclude the notion that these lesions can arise incidentally.

4. Conclusion

The pathogenesis of endotracheal hamartomas are relatively unknown and there is a discrepancy between what defines a hamartoma temporally and the age at which most endotracheal hamartomas present. We have found that endotracheal hamartoma has a tendency to present in Caucasian, male patients with a comorbidity of respiratory disease and variable smoking history, but it can also present in asymptomatic patients with no significant smoking history. Thus, early consideration of endotracheal hamartomas in patients with obstructive respiratory symptoms could prevent easily avoidable, yet fatal complications.

Conflicts of interest

No conflicts of interest.

Sources of funding

None.

Ethical approval

N/A.

Consent

Written informed consent was obtained from the patients for publication of this case report and accompanying images. A copy of the written consent is available for review by the Editor-in-Chief of this journal on request.

Author's contribution

Virginia R. Litle, MD: surgeon who operated on patients, specimen collection, editing the paper, final approval of manuscript.

Curtis Hon: writing the paper, editing the paper, submission of manuscript.

Carl O'Hara, MD: pathologic analysis of specimen.

Guarantor

Virginia R. Litle.

References

- [1] H.A. Gaissert, H.C. Grillo, M.B. Shadmehr, et al., Uncommon primary tracheal tumors, *Ann. Thorac. Surg.* 82 (2006) 268–272.
- [2] N. Suzuki, S. Ohno, Y. Ishii, S. Kitamura, Peripheral intrapulmonary hamartoma accompanied by a similar endotracheal lesion, *Chest* 106 (1994) 1291–1293.
- [3] E. Cetinkaya, G. Gunluoglu, S. Eyhan, M.Z. Gunluoglu, S.I. Dincer, A hamartoma located in the trachea, *Ann. Thorac. Surg.* 17 (2011) 504–506.
- [4] R.A. Agha, A.J. Fowler, A. Saetta, I. Barai, S. Rajmohan, D.P. Orgill, SCARE Group, The SCARE statement: consensus-based surgical case report guidelines, *Int. J. Surg.* 34 (2016) 180–186.
- [5] J.E. Alexander, R. Brodman, Endotracheal hamartoma, *N. Y. State J. Med.* 78 (1987) 408–409.
- [6] D.G. Gardner, The concept of hamartomas, *Oral Surg. Oral Med. Oral Pathol.* 45 (1978) 884–886.
- [7] C.F. Engelking, Hamartoma of trachea report of a case, with a review of the literature of benign trachea neoplasms, *Laryngoscope* 69 (1959) 1278–1286.
- [8] I.J. Hurst, K.G. Nelson, Tracheal hamartoma, *Chest* 72 (1977) 661–662.
- [9] M. Panagiotou, A. Kalkanis, N. Karagiannidis, V. Polychronopoulos, A case of tracheal hamartoma resected with loop electrocautery, *Case Rep. Pulmonol.* 2013 (2013) 1–4.

Open Access

This article is published Open Access at sciedirect.com. It is distributed under the [IJSCR Supplemental terms and conditions](#), which permits unrestricted non commercial use, distribution, and reproduction in any medium, provided the original authors and source are credited.