

# A case of adult onset Still's disease with mutations of the MEFV gene who is partially responsive to colchicine

Liang-Jun Ou-Yang, MD<sup>a</sup>, Kuo-Tung Tang, MD, PhD<sup>b,\*</sup>

## Abstract

**Rationale:** Familial Mediterranean fever (FMF) and adult onset Still's disease (AOSD) have overlapping features, and are categorized as being on the spectrum of autoinflammatory diseases (AIDs). FMF is more prevalent in the Mediterranean region but rarely, described in the Chinese population.

**Patient concerns:** We present an interesting case of a Han Chinese AOSD patient with episodic fever, wheals, and polyarthritis for 2 years.

**Diagnosis:** Sequencing analysis found exon 2 mutations of the MEFV gene (c.329T>C [L110P], and c.442G>C [E148Q]).

**Intervention:** Her arthritis was well-controlled with colchicine treatment, but fever, and rashes were not.

**Outcomes:** She eventually received tocilizumab, in addition to colchicine, and her symptoms completely disappeared.

**Lessons:** MEFV mutations may exist in AOSD patients, and treatment with colchicine might be helpful in such patients.

**Abbreviations:** AID = autoinflammatory diseases, AOSD = adult onset Still's disease, FMF = familial Mediterranean fever, IL-1 = interleukin-1, MEFV = mediterranean fever.

**Keywords:** adult onset Still's disease, case reports, colchicines, familial Mediterranean fever

## 1. Introduction

Autoinflammatory diseases (AIDs) are a cluster of diseases characterized by the aberrant activation of innate immunity. Familial Mediterranean fever (FMF) is 1 of the prototypes of AIDs. In light of the contribution of interleukin-1 (IL-1) to the pathogenesis, and therapeutic responsiveness to IL-1 antagonism, adult onset Still's disease (AOSD) has been advocated as being on the spectrum of AIDs in recent years.

FMF features recurrent brief episodes of inflammation which manifests as fever, synovitis, and serositis, and/or amyloidosis, and is associated with mediterranean fever (MEFV) gene mutations.<sup>[1]</sup> On the other hand, AOSD is characterized by fever, rash, synovitis, and/or hyperferritinemia.<sup>[2]</sup> These 2

diseases have overlapping features, although FMF has been regarded as being more prevalent in the Mediterranean region. Here we report a Han Chinese AOSD patient with mutations of the MEFV gene who is partially, responsive to colchicine therapy.

## 2. Case presentation

A 30-year-old woman, without any previous history of disease, or family history of autoimmune diseases/AIDs, experienced episodic fever reaching 38°C, along with concomitant itchy, evanescent wheals localized at her thighs, trunk, and arms, and polyarthritis involving bilateral hands proximal interphalangeal joints, which lasted for 3 to 4 days each time, since 2 years ago. She denied significant body weight loss or night sweats. These symptoms became more frequent, and each time lasted for more than a week. She received oral prednisolone of 0.41 mg/kg/day at another hospital for 5 months, with symptomatic relief. Fifteen months ago, she ceased steroid therapy, and her symptoms flared. Multiple lymphadenopathy in bilateral axillae developed, and a biopsy showed no malignancy. She then underwent Chinese herbal therapy but her symptoms persisted. Then she visited our department.

Upon physical examination, her body temperature was 39.0°C, heart rate 117 beats per minute, respiratory rate 20 per minute, and blood pressure 107/65 mmHg. She appeared well-developed and well-nourished. Her cardiac and pulmonary examination discovered no abnormalities. Joint examination revealed arthritis of her bilateral hands at the 3rd, 4th and 5th proximal interphalangeal joints. Multiple erythematous wheals in the bilateral thighs and legs were also discovered.

The laboratory examination results at the presentation are demonstrated in Table 1. Leukocytosis, elevated liver function test, and C-reactive protein were noted. Hyperferritinemia (ferritin: 2295 ng/mL) was also noted once. An abdominal sonography revealed mild hepatosplenomegaly. Hepatitis

Editor: N/A.

The study was approved by the Institutional Review Board of Taichung Veterans General Hospital (IRB TCVGH No. CE17349A).

Written informed consent was obtained from the patient who participated in the study.

The authors report no conflicts of interest.

<sup>a</sup> Department of Medicine, National Defense Medical Center, Taipei, <sup>b</sup> Division of Allergy, Immunology and Rheumatology, Taichung Veterans General Hospital, Taichung, R.O.C.

\* Correspondence: Kuo-Tung Tang, Division of Allergy, Immunology and Rheumatology, Taichung Veterans General Hospital, No. 1650, Sec. 4, Taiwan Blvd., Taichung 40705, R.O.C. (e-mail: dirac1982@vghtc.gov.tw).

Copyright © 2018 the Author(s). Published by Wolters Kluwer Health, Inc. This is an open access article distributed under the Creative Commons Attribution-NoDerivatives License 4.0, which allows for redistribution, commercial and non-commercial, as long as it is passed along unchanged and in whole, with credit to the author.

Medicine (2018) 97:15(e0333)

Received: 11 January 2018 / Received in final form: 12 March 2018 / Accepted: 14 March 2018

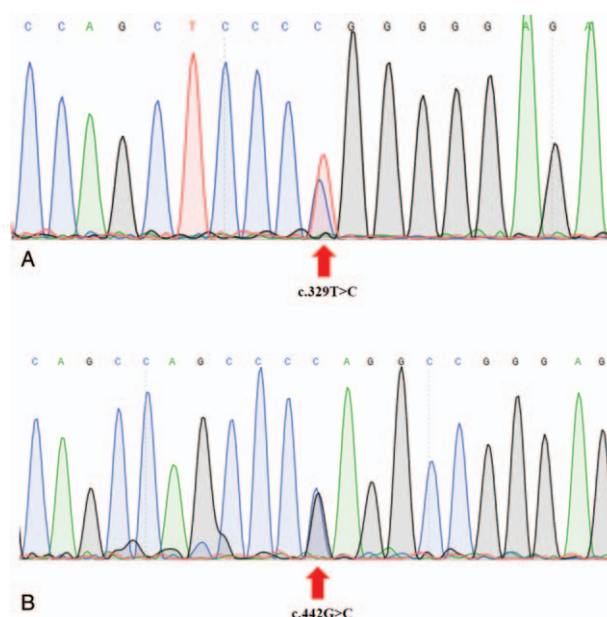
<http://dx.doi.org/10.1097/MD.0000000000010333>

**Table 1**

**Laboratory values at the presentation.**

Laboratory parameter	Patient value	Reference range
Leukocyte count ( $\times 10^9/L$ )	17440	3500–11000
Neutrophil (%)	81.0	40–74
Hemoglobin (g/dL)	10.6	12–16
Platelets ( $\times 10^9/L$ )	246	150–400
Creatinine (mg/dL)	0.48	0.7–1.4
Alanine aminotransferase (U/L)	1100	10–35
Aspartate aminotransferase	1211	8–38
Uric acid (mg/dL)	4.7	2.4–7.2
Ferritin (ng/mL)	2295	5–148
Erythrocyte sedimentation rate (mm/h)	55	$\leq 20$
C-reactive protein (mg/dL)	8.95	$< 0.3$
Antinuclear antibodies	Negative	–
Rheumatoid factor	Negative	–
Anti-SSA (EliA U/ml)	194	$< 7$
Anti-SSB (EliA U/ml)	0.6	$< 7$

markers for hepatitis B, and hepatitis C, and a blood polymerase chain reaction test for both cytomegalovirus, and Epstein-Barr virus were all negative. A liver biopsy showed lobular hepatitis with increased eosinophils infiltration, which was compatible with drug-related hepatitis. The Chinese herbal regimen was discontinued, and her liver function gradually recovered. A gallium scan showed diffusely, increased gallium uptake in the skeleton. However, a bone marrow biopsy excluded the presence of hematological malignancy. Although she possessed a positive anti-SSA antibody, she denied having symptoms such as dry eyes, or dry mouth, while a Schimer's test result was within normal limits. Consequently, a diagnosis of Sjogren's syndrome was waived. According to Yamaguchi's criteria,<sup>[3]</sup> she was diagnosed with AOSD, and initially, received aceclofenac 100mg once daily, prednisolone 5mg twice daily, and cyclosporine 25mg twice daily. Ten days later, the patient had no fever, her skin rashes had improved greatly, but the arthritis in the small joints of her hands mildly improved. Due to some atypical manifestations, she received MEFV gene mutation testing by Sanger sequencing on 3500 Applied Biosystems Genetic Analyzers, which discovered 2 heterozygous non-synonymous mutations in exon 2 (c.329T>C [p.Leu110Pro, L110P], and c.442G>C [p.Glu148Gln, E148Q]) (Fig. 1). Afterwards we ceased all medications, and prescribed colchicine 1mg twice daily for 21 days. Her arthritis became well-controlled after the colchicine prescription was implemented. However, a low grade fever, and wheals re-appeared. We then added prednisolone 5mg twice daily, and cyclosporine 25mg twice daily again for a month but the efficacy was poor. A monthly, intravenous tocilizumab at 4 mg/kg was administered, and her symptoms resolved a month later. Tocilizumab was continually, administered each month,



**Figure 1.** Sequence analysis of the MEFV exon 2 demonstrated 2 heterozygous mutations, A. c.329T>C (L110P) and B. c.442G>C (E148Q), in the blood sample obtained from the patient. MEFV = mediterranean fever.

and the doses of corticosteroid, colchicine, and cyclosporine were gradually tapered.

**3. Discussion and Conclusions**

AOSD is an inflammatory disorder characterized by quotidian fever lasting more than a week, along with arthritis, sore throat, and an evanescent rash. Atypical manifestations such as urticaria, and urticaria-like eruptions may also appear. Our patient's clinical manifestations fulfilled the Yamaguchi's criteria,<sup>[3]</sup> and the patient was diagnosed with AOSD. FMF is characterized by recurrent, short (typically 2–4 days), self-limiting fever episodes, along with abdominal, chest, joint, and/or skin involvement. Typically, it can be treated with colchicine. FMF is autosomal recessive, and associated with MEFV gene mutations. People with MEFV mutations can be found around the Mediterranean region. A few reports have described MEFV mutations in other Asian ethnic groups,<sup>[4–6]</sup> including Chinese. MEFV mutation can also be detected in autoimmune diseases such as systemic lupus erythematosus,<sup>[7,8]</sup> and rheumatoid arthritis,<sup>[9,10]</sup> with its association with clinical phenotypes being inferred. The c.329T>C and c.442G>C mutations in our patient, have been recognized as variants of uncertain or mild significance in FMF.<sup>[11,12]</sup> Three studies have illustrated MEFV mutations in

**Table 2**

**Studies describing MEFV mutations in patients with AOSD.**

Study	Citation	Case number	Gene analysis	Findings
Cosan, 2013	11	20 AOSD patients 103 HCs	Genotyping of common mutations	Increased MEFV gene mutation rate in AOSD patients, although not statistically significant
Kim, 2013	12	96 AOSD patients 165 HCs	Genotyping of common mutations	Lower frequency of sore throat and higher ESR in AOSD patients with E148Q mutation
Nonaka, 2014	13	48 AOSD patients 105 HCs	Direct DNA sequencing	Lower frequency of monocyclic phenotype in AOSD patients with MEFV mutations

AOSD = adult onset Still's disease, ESR = erythrocyte sedimentation rate, HC = healthy control, MEFV = mediterranean fever.

AOSD patients (Table 2),<sup>[13–15]</sup> and discovered some MEFV mutations potentially, predisposed to the development of AOSD and affecting its clinical phenotypes. However, response to colchicine treatment has not been mentioned in these studies.

Colchicine potentially, exerts its efficacy in FMF through its inhibition of the inflammasome/IL-1 $\beta$  pathway, and is generally safe, and well-tolerated.<sup>[16]</sup> The patient's clinical manifestations did not fulfill the Tel-Hashomer diagnostic criteria for FMF.<sup>[17]</sup> However, the patient reported a good response to colchicine for treatment of her arthritis, which was refractory to nonsteroidal anti-inflammatory drugs (NSAIDs), and low dose corticosteroids. Could this be explained by the patient's MEFV gene mutations? We could not give a definite answer.

In conclusion, MEFV mutations may exist in AOSD patients, and colchicine treatment might be useful in their management. More studies in the Han Chinese population are needed.

### Acknowledgments

We sincerely thank the technicians of Genetics Generation Advancement Corporation for their assistance in laboratory experiments.

### Author contributions

**Conceptualization:** K.-T. Tang

**Data curation:** L.-J. Ou-Yang

**Formal analysis:** K.-T. Tang

**Methodology:** K.-T. Tang

**Writing – original draft:** L.-J. Ou-Yang

**Writing – review & editing:** K.-T. Tang

### References

- [1] Telatar M, Grody WW. Molecular genetic testing for familial Mediterranean fever. *Mol Genet Metab* 2000;71:256–60.
- [2] Gerfaud-Valentin M, Jamilloux Y, Iwaz J, et al. Adult-onset Still's disease. *Autoimmun Rev* 2014;13:708–22.
- [3] Yamaguchi M, Ohta A, Tsunematsu T, et al. Preliminary criteria for classification of adult Still's disease. *J Rheumatol* 1992;19:424–30.
- [4] Booth DR, Lachmann HJ, Gillmore JD, et al. Prevalence and significance of the familial Mediterranean fever gene mutation encoding pyrin Q148. *QJM* 2001;94:527–31.
- [5] Tomiyama N, Higashiuesato Y, Oda T, et al. MEFV mutation analysis of familial Mediterranean fever in Japan. *Clin Exp Rheumatol* 2008;26:13–7.
- [6] He X, Lu H, Kang S, et al. MEFV E148Q polymorphism is associated with Henoch-Schonlein purpura in Chinese children. *Pediatr Nephrol* 2010;25:2077–82.
- [7] Deniz R, Ozen G, Yilmaz-Oner S, et al. Familial Mediterranean fever gene (MEFV) mutations and disease severity in systemic lupus erythematosus (SLE): implications for the role of the E148Q MEFV allele in inflammation. *Lupus* 2015;24:705–11.
- [8] Shinar Y, Kosach E, Langevitz P, et al. Familial Mediterranean FeVer gene (MEFV) mutations as a modifier of systemic lupus erythematosus. *Lupus* 2012;21:993–8.
- [9] Rabinovich E, Livneh A, Langevitz P, et al. Severe disease in patients with rheumatoid arthritis carrying a mutation in the Mediterranean fever gene. *Ann Rheum Dis* 2005;64:1009–14.
- [10] Inanir A, Yigit S, Karakus N, et al. Association of MEFV gene mutations with rheumatoid factor levels in patients with rheumatoid arthritis. *J Investig Med* 2013;61:593–6.
- [11] Shinar Y, Obici L, Aksentijevich I, et al. Guidelines for the genetic diagnosis of hereditary recurrent fevers. *Ann Rheum Dis* 2012;71:1599–605.
- [12] Dogan H, Faruk Bayrak O, Emert M, et al. Familial Mediterranean fever gene mutations in north-eastern part of Anatolia with special respect to rare mutations. *Gene* 2015;568:170–5.
- [13] Cosan F, Emrence Z, Erbag G, et al. The association of TNFRSF1A gene and MEFV gene mutations with adult onset Still's disease. *Rheumatol Int* 2013;33:1675–80.
- [14] Kim JJ, Kim JK, Shim SC, et al. MEFV gene mutations and their clinical significance in Korean patients with adult-onset Still's disease. *Clin Exp Rheumatol* 2013;31:60–3.
- [15] Nonaka F, Migita K, Jiuchi Y, et al. Increased prevalence of MEFV exon 10 variants in Japanese patients with adult-onset Still's disease. *Clin Exp Immunol* 2015;179:392–7.
- [16] Ozen S, Batu ED, Demir S. Familial Mediterranean fever: recent developments in pathogenesis and new recommendations for management. *Front Immunol* 2017;8:253.
- [17] Livneh A, Langevitz P, Zemer D, et al. Criteria for the diagnosis of familial Mediterranean fever. *Arthritis Rheum* 1997;40:1879–85.