



Contents lists available at ScienceDirect

International Journal of Surgery Case Reports

journal homepage: www.casereports.com

A case of undifferentiated pleomorphic sarcoma of the breast with lung and bone metastases

Haruhiko Yamazaki^{a,*}, Satoru Shimizu^b, Tatsuya Yoshida^a, Nobuyasu Suganuma^a, Takashi Yamanaka^a, Toshinari Yamashita^a, Yasushi Rino^c, Munetaka Masuda^c^a Department of Breast and Endocrine Surgery, Kanagawa Cancer Center, Yokohama, Japan^b Yokohama Tsurugamine Hospital, Yokohama, Japan^c Department of Surgery, Yokohama City University School of Medicine, Yokohama, Japan

ARTICLE INFO

Article history:

Received 17 May 2018

Received in revised form 25 July 2018

Accepted 30 July 2018

Available online 16 August 2018

Keywords:

Undifferentiated pleomorphic sarcoma

Breast

Chemotherapy

ABSTRACT

INTRODUCTION: Undifferentiated pleomorphic sarcoma (UPS) constitutes less than of all sarcomas in adults and rarely involves the breast. We herein present a patient with UPS of the breast with lung and bone metastases. This case was treated by eribulin as first chemotherapy, and performed mastectomy for local control.

CASE PRESENTATION: A 55-year-old female presented a tumor measuring over 5 cm with pain in the right breast. Pathology of the incisional biopsy specimen led to a diagnosis of UPS. Computed tomography revealed a right tumor, right pubic tumor with osteolysis, and multiple lung metastases. She was started on eribulin; however, the tumor grew in size, indicating progressive disease, and the patient underwent simple mastectomy for local control. Pathological evaluation of the excised tumor was consistent with UPS. The patient elected palliative treatment and died due to respiratory failure caused by multiple lung metastases that exacerbated four months after surgery.

DISCUSSION: Soft tissue sarcomas with distant metastases are treated with chemotherapy; however, there are currently no effective chemotherapeutic agents for UPS of the breast. Given the potential efficacy of eribulin in soft tissue tumors and the easy management of associated side effects, the patient was treated with eribulin, which however was insufficient for disease control.

CONCLUSION: The prognosis of UPS with distant metastasis remains poor. Treatment approaches including chemotherapy and surgery should be considered based on the patient's general condition, prognosis, and expectations on quality of life.

© 2018 The Author(s). Published by Elsevier Ltd on behalf of IJS Publishing Group Ltd. This is an open access article under the CC BY-NC-ND license (<http://creativecommons.org/licenses/by-nc-nd/4.0/>).

1. Introduction

Primary breast sarcomas are extremely rare, representing less than 1% of all primary breast malignancies [1]. Prognosis of primary breast sarcomas is associated with tumor diameter, distant metastasis, and histological grade [2]. Lymphatic spread is uncom-

mon in primary breast sarcomas, and dissemination usually occurs hematogenously, and lungs, bones, and liver are the primary organs for metastasis [2]. Conversely, undifferentiated pleomorphic sarcoma (UPS) constitutes less than 5% of all sarcomas in adults and has been rarely reported to involve the breast [3]. There are no comprehensive reports on primary UPS of the breast, and individual case reports are rare. We herein present the case of a patient with suspicious UPS of the breast with lung and bone metastases.

The work has been done in line with the SCARE criteria [4].

2. Presentation of case

A 55-year-old female presented to a local clinic with a tumor measuring over 5 cm with pain in the right breast. Inflammatory granuloma was suspected, and the patient was followed up. However, the tumor grew in size, and an incisional biopsy was performed six months after the first visit. Pathological examination led

Abbreviations: CT, computed tomography; PD, progression disease; ER, estrogen receptor; PR, progesterone receptor; EMA, epithelial membrane antigen; SMA, smooth muscle actin; UPS/MFH, undifferentiated pleomorphic sarcoma/malignant fibrous histiocytoma; US, undifferentiated/unclassified sarcomas; NOS, not otherwise specified; QOL, quality of life.

* Corresponding author at: Department of Breast and Endocrine Surgery, Kanagawa Cancer Center, 2-3-2 Nakao, Asahiku, Yokohama, Kanagawa 241-8515, Japan.

E-mail addresses: h.yamazaki0413@kcch.jp (H. Yamazaki), shimizustr0110@gmail.com (S. Shimizu), tyoshida0803@gmail.com (T. Yoshida), nsuganuma@kcch.jp (N. Suganuma), mtintksh@msn.com (T. Yamanaka), tyamashita@kcch.jp (T. Yamashita), rino@med.yokohama-cu.ac.jp (Y. Rino), mamasuda@yokohama-cu.ac.jp (M. Masuda).

<https://doi.org/10.1016/j.ijscr.2018.07.049>

2210-2612/© 2018 The Author(s). Published by Elsevier Ltd on behalf of IJS Publishing Group Ltd. This is an open access article under the CC BY-NC-ND license (<http://creativecommons.org/licenses/by-nc-nd/4.0/>).

to a diagnosis of UPS, and the patient was admitted to our hospital for treatment.

The patient had no medical history, and her family history included breast cancer in her aunt. On physical examination, the patient had a tumor measuring 50 mm in her right breast, and her Eastern Cooperative Oncology group (ECOG) performance status (PS) was poor with a score of 3. Mammography showed a microlobulated tumor occupying the lower outer quadrant of the right breast. Ultrasonography showed a low-echoic mass with irregular margins and a heterogeneous internal echo pattern (Fig. 1). Computed tomography showed right breast tumor, tumor in right pubic bone with osteolysis, and multiple lung metastases (Fig. 2). The patient was diagnosed as UPS with distant metastases and initiated on eribulin mesylate, a nontaxane microtubule dynamics inhibitor, considering her PS score and tolerability of treatment. She received three courses of eribulin without significant side effects. However, the primary tumor was observed to grow noticeably on physical examination week 9 after treatment initiation, indicating progressive disease. Due to concerns regarding self-destruction of tumor and bleeding, simple mastectomy was performed for local control.

Pathological analysis revealed that the tumor which exhibited a milky appearance by gross examination appeared necrotic and bleeding internally. Microscopic assessment of the sections prepared from the surgical specimen showed spindle-shaped cells with heteromorphic strong nuclei (Fig. 3). Immunohistochemistry showed that the tumor was negative for estrogen receptor, progesterone receptor, AE1/AE3, CAM5.2, CD34, epithelial membrane antigen, and desmin and was partially positive for smooth muscle actin and S-100. These results were consistent with the diagnosis of UPS. After surgery, the patient chose palliative treatment after consultation and died due to respiratory failure caused by multiple lung metastases which exacerbated four months after the surgery.

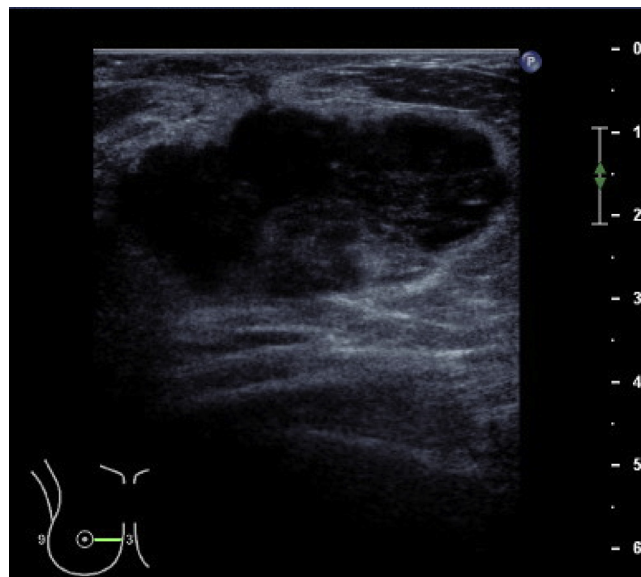


Fig. 1. Breast ultrasonography. Breast ultrasonography shows a low-echoic tumor measuring 51 mm in diameter with irregular margins and a heterogeneous internal echo pattern in the AB area of the right breast.

3. Discussion

In 2013, the WHO classification of soft tissue tumors was revised and the concept of undifferentiated pleomorphic sarcoma / malignant fibrous histiocytoma (UPS / MFH) disappeared, and a major item of undifferentiated / unclassified sarcomas (US) was created on behalf of UPS / MFH. In the definition of US, at most 20% of the whole soft tissue sarcoma is said to correspond to this disease concept [5]. There are five subtypes in

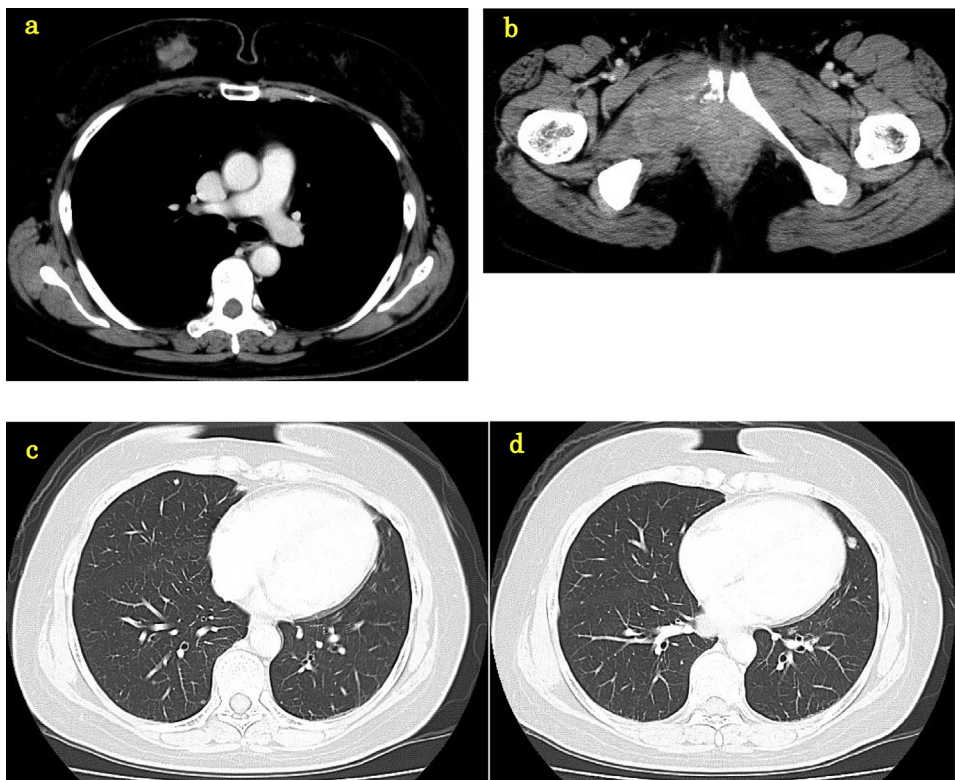


Fig. 2. Computed tomography. a. Computed tomography image showed right breast tumor. b. Computed tomography image showing right pubic tumor with osteolysis. c, d. Note the multiple lung metastases.

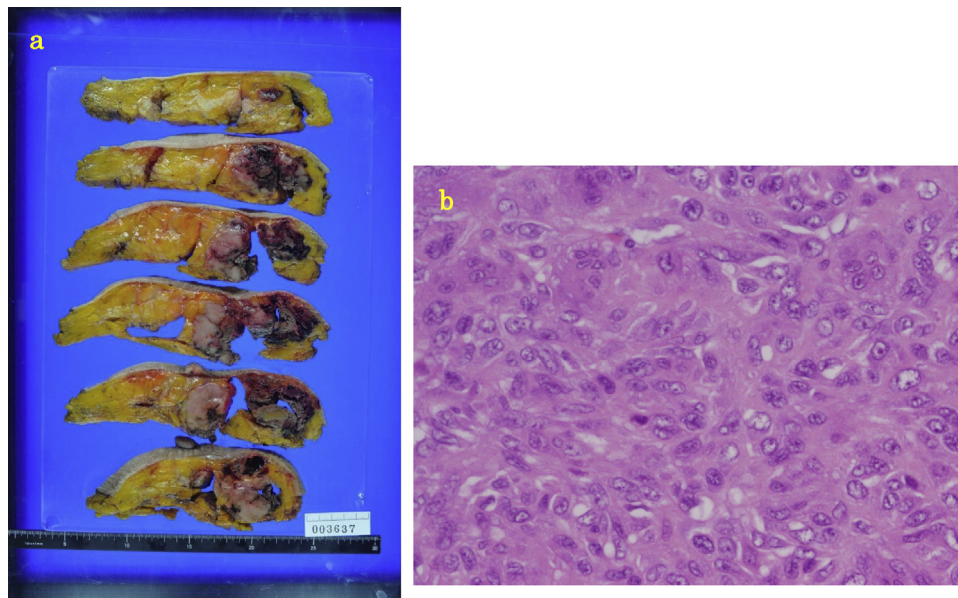


Fig. 3. Macroscopic and microscopic images of pathological specimens. a. Gross appearance of tumor which appears milky with necrosis and bleeding noticeable in cross-sections. b. Microscopic images of the sections from the tumor specimen showing spindle-shaped cells with heteromorphic strong nuclei. Original magnification, $\times 400$.

US. They are undifferentiated round cell sarcoma, undifferentiated spindle cell sarcoma, undifferentiated pleomorphic sarcoma, undifferentiated epithelioid sarcoma, undifferentiated sarcoma, and not otherwise specified (NOS). UPS / MFH corresponds to undifferentiated pleomorphic sarcoma. Since primary breast sarcoma is extremely rare, sufficient clinicopathological examination and treatment approaches have not yet been established. Surgery is a standard treatment approach in patients without distant metastasis, and complete resection is considered as the most important factor for long-term prognosis [2]. Lymphatic metastasis is rare in breast sarcoma. Based on the lack of evidence for improved prognosis, lymph node dissection is not performed routinely, as reported by numerous studies [6]. Mastectomy is often performed; however, some studies report that breast-conserving surgery in patients with small tumors was associated with no recurrence. Therefore, mastectomy may not be necessary in cases where sufficient negative margins can be secured [7]. The efficacy of chemotherapy and radiotherapy as adjuvant therapy after surgery remains unclear [2].

Chemotherapy is used for soft tissue tumors with distant metastases. The efficacy of doxorubicin in soft tissue tumors, as reported by Judson et al., has been used widely in clinical practice [8]. Thereafter, despite attempts in several studies, no other regimen was shown to be superior to treatment with doxorubicin as a single agent, which remains the first choice in soft tissue sarcomas [9]. Ifosfamide, dacarbazine, trabectedin, and pazopanib are used as secondary treatment options, with limited efficacy and accompany an increased risk of side effects. Therefore, more effective and tolerable drugs are sorely needed for soft tissue sarcomas. Eribulin was considered as an effective treatment option in the current patient, because it was shown to significantly prolong overall survival in patients with advanced liposarcoma or leiomyosarcoma with a pre-treatment history compared to dacarbazine [10]. In breast cancer, the EMBRACE trial demonstrated the efficacy of eribulin, which is commonly used in clinical practice [11].

The current patient had distant metastases at the time of initial presentation, and chemotherapy was considered as the first choice of treatment. However, due to the lack of drugs with proven efficacy in UPS of the breast, drug selection was challenging. Although doxorubicin is considered as the first-line treatment for soft tissue tumors, the PS of the patient was poor, and doxorubicin was

not administered due to potential resistance to treatment. In our knowledge, there are no reports that eribulin was used for UPS. However, we selected eribulin for treatment of the current patient for the following reasons. First, eribulin might be effective in soft tissue tumors. Second, eribulin has been extensively used for breast cancer treatment, and management of its side effects is not difficult. This was thought to lead to preserve the quality of life (QOL) of the patient. Although there were no serious side effects and the QOL was preserved in the current case, the tumor evolved to progressive disease after three courses of eribulin, indicating insufficient disease control. When the breast tumor self-destructs, bleeding and an unpleasant odor noticeably impair the patient's QOL. Since disease control was considered to be difficult with chemotherapy and due to the strong possibility of worsened QOL due to tumor self-destruction, the patient underwent simple mastectomy for local control. However, there is no evidence that local resection can improve prognosis in breast cancer patients with distant metastasis; therefore, decision for surgery should be evaluated on a case-by-case basis.

Although the disease control was insufficient with our treatment method, we were able to carry out the treatment that preserved QOL in UPS which is very poor prognosis.

4. Conclusion

The prognosis of UPS with distant metastasis is poor, and establishment of a more effective and highly tolerable treatment method is necessary. Treatment approaches including chemotherapy and surgery should be considered based on the patient's general condition, prognosis, and QOL.

Conflict of interest

There are no conflicts of interest.

Sources of funding

There are no sources of funding.

Ethical approval

It is not a research study, it is a case report so it has not been required any ethic committee.

Consent

Written informed comprehensive consent was obtained from the patient for publication of this case report and accompanying images. A copy of the written comprehensive consent is available for review by the Editor-in-Chief of this journal on request.

Author contributions

Haruhiko Yamazaki: Writing the paper.
 Satoru Shimizu: Reviewing the paper. Followup the patient.
 Tatsuya Yoshida: Reviewing the paper.
 Nobuyasu Suganuma: Reviewing the paper.
 Takashi Yamanaka: Reviewing the paper.
 Toshinari Yamashita: Reviewing the paper.
 Yasushi Rino: Others.
 Munetaka Masuda: Others.

Registration of Research Studies

This report is not a research involving human participants.

Guarantor

Toshinari Yamashita.

Acknowledgements

We would like to thank Kae Kawachi from the Department of Pathology at Kanagawa Cancer Center for interpretation of the anatomical pathology result.

References

- [1] J.W. Berg, R.V. Hutter, Breast cancer, *Cancer* 75 (1995) 257–269.
- [2] N. Li, M.T. Cusidó, B. Navarro, F. Tresserra, S. Baulies, C. Ara, R. Fabregas, Breast sarcoma. A case report and review of literature, *Int. J. Surg. Case Rep.* 24 (2016) 203–205.
- [3] C. Adem, C. Reynolds, J.N. Ingle, A.G. Nascimento, Primary breast sarcoma: clinicopathologic series from the Mayo Clinic and review of the literature, *Br. J. Cancer* 91 (2004) 237–241.
- [4] R.A. Agha, A.J. Fowler, A. Saetta, I. Barai, S. Rajmohan, D.P. Orgill, for the SCARE Group, The SCARE statement: consensus-based surgical case report guidelines, *Int. J. Surg.* 34 (2016) 180–186.
- [5] V.Y. Jo, C.D. Fletcher, WHO classification of soft tissue tumours: an update based on the 2013 (4th) edition, *Pathology* 46 (2014) 95–104.
- [6] E. Nizri, O. Merimsky, G. Lahat, Optimal management of sarcomas of the breast: an update, *Expert Rev. Anticancer Ther.* 14 (2014) 705–710.
- [7] T. Okabe, S. Noguchi, Primary angiosarcoma of the breast—a report of two cases—, *Jpn. Surg. Assoc.* 69 (2008) 302–307.
- [8] I. Judson, J. Verweij, H. Gelderblom, J.T. Hartmann, P. Schöffski, J.Y. Blay, J.M. Kerst, J. Sufliarsky, J. Whelan, P. Hohenberger, A. Krarup-Hansen, T. Alcindor, S. Marreand, S. Litière, C. Hermans, C. Fisher, P.C. Hogendoorn, A.P. dei Tos, W.T. van der Graaf, European Organisation and Treatment of Cancer Soft Tissue and Bone Sarcoma Group, Doxorubicin alone versus intensified doxorubicin plus ifosfamide for first-line treatment of advanced or metastatic soft-tissue sarcoma: a randomised controlled phase 3 trial, *Lancet Oncol.* 15 (2014) 415–423.
- [9] B. Seddon, S.J. Strauss, J. Whelan, M. Leahy, P.J. Woll, F. Cowie, C. Rothermundt, Z. Wood, C. Benson, N. Ali, M. Marples, G.J. Veal, D. Jamieson, K. Küver, R. Tirabosco, S. Forsyth, S. Nash, H.M. Dehbi, S. Beare, Gemcitabine and docetaxel versus doxorubicin as first-line treatment in previously untreated advanced unresectable or metastatic soft-tissue sarcomas (GeDDiS): a randomised controlled phase 3 trial, *Lancet Oncol.* 18 (2017) 1397–1410.
- [10] P. Schöffski, S. Chawla, R.G. Maki, A. Italiano, H. Gelderblom, E. Choy, G. Grignani, V. Camargo, S. Bauer, S.Y. Rha, J.Y. Blay, P. Hohenberger, D. D'Adamo, M. Guo, B.14 Chmielowski, A. Le Cesne, G.D. Demetri, S.R. Patel, Eribulin versus dacarbazine in previously treated patients with advanced liposarcoma or leiomyosarcoma: a randomised, open-label, multicentre, phase 3 trial, *Lancet* 387 (2016) 1629–1637.
- [11] J. Cortes, J. O'Shaughnessy, D. Loesch, J.L. Blum, L.T. Vahdat, K. Petrakova, P. Chollet, A. Manikas, V. Diéras, T. Delozier, V. Vladimirov, F. Cardoso, H. Koh, P. Bougnoux, C.E. Dutcus, S. Seegobin, D. Mir, N. Menezes, J. Wanders, C. Twelves, EMBRACE (Eisai Metastatic Breast Cancer Study Assessing Physician's Choice Versus E7389) investigators, Eribulin monotherapy versus treatment of physician's choice in patients with metastatic breast cancer (EMBRACE): a phase 3 open-label randomised study, *Lancet* 377 (2011) 914–923.

Open Access

This article is published Open Access at [sciencedirect.com](https://www.sciencedirect.com). It is distributed under the [IJSCR Supplemental terms and conditions](#), which permits unrestricted non commercial use, distribution, and reproduction in any medium, provided the original authors and source are credited.