

## Recurrent progressive anterior segment fibrosis syndrome following a descemet-stripping endothelial keratoplasty in an infant with congenital aniridia

Mihir Kothari, Kavita Rao, Samita Moolani

Progressive anterior segment fibrosis syndrome (ASFS), after intraocular surgery in older children ( $\geq 9$  years) and adults with congenital aniridia, is described in the literature. In this report, we describe an unique case of ASFS in an infant with congenital aniridia following a combined trabeculotomy-ectomy and its recurrence after a descemet stripping endothelial keratoplasty. The ophthalmologists should be well aware of this entity and warn the parents about its possibilities. Use of immunomodulators or prolonged anti-inflammatory therapy may be considered to prevent its occurrence.

**Key words:** Congenital aniridia, descemet stripping endothelial keratoplasty, progressive anterior segment fibrosis syndrome

Descemet stripping endothelial keratoplasty (DSEK) is a safe and effective surgical treatment for children aged as young as six months with endothelial dysfunction.<sup>[1-7]</sup> Herein, we present an infant with congenital aniridia who developed recurrent progressive ASFS following a DSEK.

### Case Report

A 3-week-old female child from Africa was diagnosed with congenital total bilateral aniridia and congenital glaucoma. She underwent a trabeculotomy in the right eye at 3 months of age and combined trabeculotomy-trabeculectomy in the left eye at 5 months of age. The intraocular pressure in both the eyes, following the surgery, was well controlled. However, the left eye cornea developed white opacification two weeks after the surgery that continued to become worse over the next 3 months. At 8 months of age the child was referred to us for further management.

On examination, the child had a central, steady and maintained fixation in the right eye and unmaintained fixation and exotropia in the left eye. Intra ocular pressure in both eyes [under sedation (oral triclofos, 50 mg/kg)] was 12 mmHg. Examination of the right eye revealed clear cornea with total aniridia and clear crystalline lens [Fig. 1a and b]. The horizontal corneal diameter in both eyes was equal (11.25 mm). Further examination of the right eye with direct gonioscopy showed rudimentary iris stump with an open angle. The optic disc was healthy. There was absence of foveal hypoplasia and nystagmus.

In the left eye, a fibrotic conjunctival bleb superiorly was present with grade 4 corneal edema precluding the view to intraocular structures [Fig. 1a and c]. B-scan ultrasonography of the left eye showed echo-free vitreous with attached retina.

Systemic examination including the ultrasound examination of the abdomen of the child was normal. The family history was significant for congenital aniridia with open angle glaucoma in the father and congenital aniridia with normal intraocular pressure in the elder sister.

We diagnosed the child with postoperative corneal endothelial dysfunction and advised a DSEK of the left eye. The donor tissue was prepared from an excellent grade cornea using a manual technique with the artificial anterior chamber. The visibility to the anterior chamber was poor that was improved to an extent by the application of methyl cellulose on the cornea and using oblique illumination system of the microscope at a higher intensity.

After entering the anterior chamber, a thick fibrinous membrane, adherent to the posterior surface of the cornea was encountered that was dissected using a crescent knife. A plane of dissection was made and the membrane was cut using vitreo-retinal scissors and was removed. This membrane was not adherent to the iris or the lens. The excised membrane was sent for histopathological evaluation.

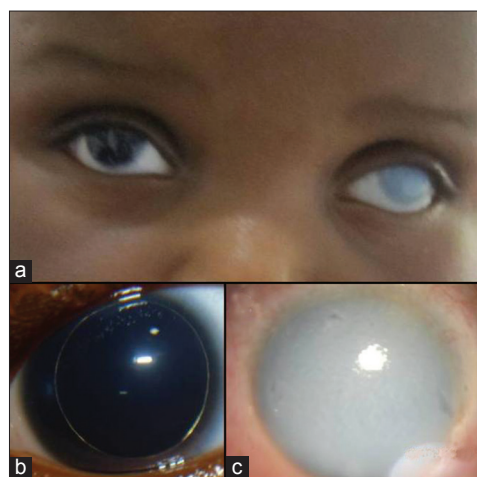
Seven millimeters of donor tissue was then trephined and inserted through a scleral tunnel and secured in place. Since

| Access this article online  |                                  |
|---|----------------------------------|
| Quick Response Code:  | Website:<br>www.ijjo.in          |
|  | DOI:<br>10.4103/0301-4738.128635 |
|   |                                  |

Department of Pediatric Ophthalmology and Adult Strabismus, Department of Cornea Services, Aditya Jyot Eye Hospital, Wadala, Mumbai, Maharashtra, India

**Correspondence to:** Dr. Mihir Kothari, Jyotirmay Eye Clinic, 205 Ganatra Estate, Khopat, Thane - 400 601, Maharashtra, India. E-mail: drmihirkothari@jyotirmay.com

Manuscript received: 21.08.12; Revision accepted: 13.06.13



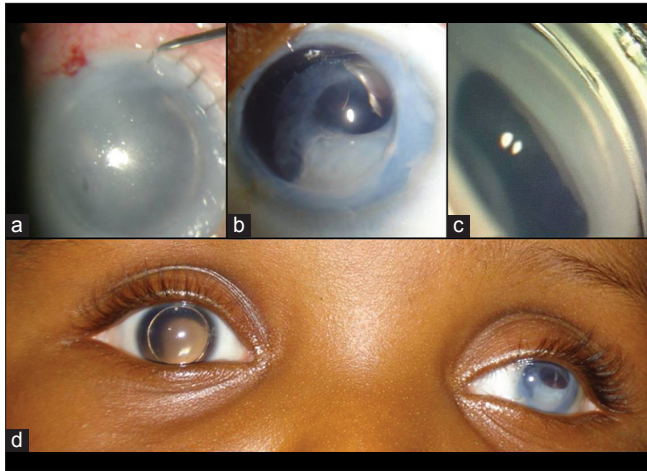
**Figure 1:** Preoperative face photograph (a) showing sensory exotropia in the left eye. Aniridia with clear cornea and crystalline lens in the right eye (b) and grade 4 corneal haze in the left eye (c)

there was a lack of proper tamponade for lenticule attachment due to breach in iris-lens diaphragm in aniridia, the anterior chamber was filled with a largest possible air bubble.

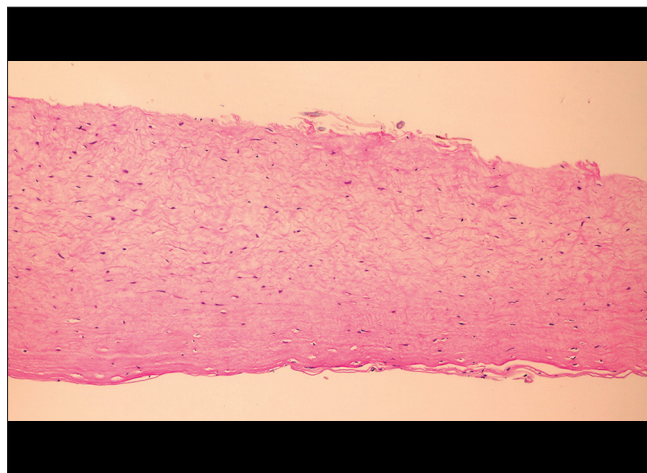
The cornea appeared clear on the operation table [Fig. 2a]. Postoperatively, the child was administered moxifloxacin 0.5% eye drops thrice a day, prednisolone acetate 1%, six times/day and 1% atropine sulfate twice a day. The cornea was noticed to have increased clarity over one week. No fibrous membrane was noticed in the anterior chamber.

The topical steroid was continued for 3 months. The histopathology of the tissue showed only the fibrous tissue adherent to the corneal stroma [Fig. 3].

Three months after the surgery, the parents presented with the history of increasing clarity of the cornea. However, they simultaneously noticed a white opacity inside the eye that became progressively more evident as the cornea cleared [Fig. 2b and d].



**Figure 2:** Intraoperative (a) and 3-month postoperative (b-d) photographs showing clearing of the cornea on the operation table after the DSEK, fibrous membrane in the anterior chamber (b and d) with clear cornea in the left eye and open angles on gonioscopy (c) in the left eye, 3 months following the DSEK



**Figure 3:** Hematoxylin-eosin preparation of the retrocorneal membrane demonstrating a collagenous membrane with fibrocytes

On examination, the child had a central, steady and maintained fixation in the right eye. The left eye had unmaintained, central and steady fixation. There was no significant refractive error in either eye.

The examination under anesthesia revealed normal intraocular pressure in both eyes and a fibrotic membrane in the anterior chamber of the left eye attached to the inferior edge of the donor tissue [Fig. 2b and d]. The membrane extended over the lens capsule across the anterior chamber. The membrane surrounded the lens equator and was noticeable on the posterior capsule in the area of the attachment of the zonules. The anterior chamber angle was open [Fig. 2c]. The crystalline lens was clear. There was no malposition of the crystalline lens. The anterior chamber was quiet, the fundus examination and intraocular pressure measurements were within normal limits. The child was diagnosed with recurrent anterior segment fibrosis syndrome (ASFS), and was started on the right eye patching and advised close follow-up.

## Discussion

Tsai *et al.*,<sup>[8]</sup> have reported a series of patients with progressive anterior segment fibrosis following an intraocular surgery in patients with congenital aniridia (aged 9-65 years). All the patients presented with corneal decompensation. Multiple intraocular surgeries and glaucoma surgery with artificial drainage device were reported to be the most important risk factors. The origin of the membrane was not known. In two patients, the progressive fibrosis led to tractional retinal detachment and hypotony.

The cause of progressive fibrosis was suspected to be an implant sitting very proximal to the rudimentary iris or *PAX6* gene related immune response. However, till date, no biochemical studies are performed reporting the differences in the aqueous humor of such patients and patients without aniridia or patients with aniridia who have had intraocular surgery but did not develop a fibrosis syndrome.

Unlike the previous report, in our patient, there was no intraocular foreign material and the ASFS developed after the first surgery itself. This was evident from the existence of a thick retrocorneal membrane, which was histopathologically a non-inflammatory collagenous membrane encountered during the DSEK, following the corneal decompensation three months after the first surgery. For such patients, type 1 Boston keraoprosthesis may offer a good management option, preventing the recurrence and at the same time provide clear visual axis.<sup>[9]</sup>

This is the first-case report where ASFS is reported at such a young age, without an intraocular implant and a recurrence following the membrane removal and DSEK. Further studies are necessary to elucidate the cause of this phenomenon. The clinicians should be aware of this syndrome and closely follow up the patients with congenital aniridia undergoing intraocular surgery. Recurrence is a strong possibility if the membrane removal is attempted. Though there is no evidence, prolonged use of anti-inflammatory therapy may be indicated following an intraocular surgery in patients with congenital aniridia.

## Acknowledgment

We acknowledge the literature support provided by Dr. Jatin Asher.

## References

1. Fernandez MM, Buckley EG, Afshari NA. Descemet stripping automated endothelial keratoplasty in a child. *J AAPOS* 2008;12:314-6.
2. Jeng BH, Marcotty A, Traboulsi EI. Descemet stripping automated endothelial keratoplasty in a 2-year-old child. *J AAPOS* 2008;12:317-8.
3. Ponchel C, Malecaze F, Arne JL, Fournie P. Descemet stripping automated endothelial keratoplasty in a child with Descemet membrane breaks after forceps delivery. *Cornea* 2009;28:338-41.
4. Kymionis GD, Kankariya VP, Diakonis VF, Karavitaki AE, Siganos CS, Pallikaris IG. Descemet stripping automated endothelial keratoplasty in a child after failed penetrating keratoplasty. *J AAPOS* 2012;16:95-6.
5. Ramappa M, Ashar J, Vaddavalli PK, Chaurasia S, Murthy SI. Endothelial keratoplasty in children: Surgical challenges and early outcomes. *Br J Ophthalmol* 2012;96:1149-51.
6. Ashar JN, Madhavi Latha K, Vaddavalli PK. Descemet's stripping endothelial keratoplasty (DSEK) for children with congenital hereditary endothelial dystrophy: Surgical challenges and 1-year outcomes. *Graefes Arch Clin Exp Ophthalmol* 2012;250:1341-5.
7. Busin M, Beltz J, Scorcia V. Descemet-stripping automated endothelial keratoplasty for congenital hereditary endothelial dystrophy. *Arch Ophthalmol* 2011;129:1140-6.
8. Tsai JH, Freeman JM, Chan CC, Schwartz GS, Derby EA, Petersen MR, *et al.* A progressive anterior fibrosis syndrome in patients with postsurgical congenital aniridia. *Am J Ophthalmol* 2005;140:1075-9.
9. Bakhtiari P, Chan C, Welder JD, de la Cruz J, Holland EJ, Djililian AR. Surgical and visual outcomes of the type I Boston Keratoprosthesis for the management of aniridic fibrosis syndrome in congenital aniridia. *Am J Ophthalmol* 2012;153:967-71.

**Cite this article as:** Kothari M, Rao K, Moolani S. Recurrent progressive anterior segment fibrosis syndrome following a descemet-stripping endothelial keratoplasty in an infant with congenital aniridia. *Indian J Ophthalmol* 2014;62:246-8.

**Source of Support:** Nil. **Conflict of Interest:** None declared.