

A Systematic Approach to Incision Planning and Graft Excision in Gender-affirming Vaginoplasty

Geolani W. Dy, MD*

Christi Butler, MD†

Blair Peters, MD*‡

Daniel D. Dugi III, MD, FACS*‡

Summary: We present our systematic approach to incision planning and skin graft excision for gender-affirming vaginoplasty. This approach is adaptable to patients of different body habitus and genital skin surface area, and it allows for early skin graft harvest with predictable wound tension at closure. We also describe how to adapt in cases of severe genital hypoplasia. (*Plast Reconstr Surg Glob Open* 2022;10:e4103; doi: 10.1097/GOX.0000000000004103; Published online 15 February 2022.)

INTRODUCTION

Although penile-inversion vaginoplasty has been performed since the 1950s,¹ few studies have reported on rationale and considerations of preoperative markings in vulvar construction. Careful planning can camouflage scars in natural skin creases and allow for early excision of scrotal skin graft for vaginal canal construction. We present a systematic technique for preoperative marking that allows for efficient early excision of scrotal skin graft, predictable wound tension, and camouflaged scarring, including for patients with genital hypoplasia.

METHODS

The perineal body is palpated, and at this level the base of a perineal flap 2–3 cm wide is marked, usually about 3 cm above the anus (Fig. 1). (See Video [online], which demonstrates the technique of presurgical incision planning.) (See figure, Supplemental Digital Content 1, which shows the appearance of patient demonstrated in supplemental video. S1a, Preoperative appearance. S1b, Immediate postoperative appearance. S1c, Appearance 9 months postoperatively. <http://links.lww.com/PRSGO/B922>.) The tip of this inverted U-shaped flap will later be anchored to the perineal body; the length is chosen to reach the perineal body based on the patient's habitus (typically 2–3 cm).

A dotted line is then drawn approximately 1 cm medial to the groin crease from above the adductor longus tendon to the lateral edge of the perineal flap. This will be the lateral incision border, resulting in a scar that becomes the natural-appearing lateral demarcation of the labia majora and is hidden in the groin crease.

The scrotal skin is held in the midline and pulled down to meet the base of the perineal flap with the desired amount of tension. This point is marked in the midline, estimating where the inferior border of the labia majora (A/A') will meet the inferior edges of the perineal flap (C/C'). Excessive tension can lead to wound breakdown, effacement of desired labial fullness, and unfavorable scarring; inadequate tension will leave excessive skin, giving an undesirable "scrotal" appearance.

The height of the lateral incision is determined using two rulers to find a point (B, B') along the lateral markings equidistant from A/A' and C/C', with the same tension in the scrotal skin as when A/A' to the perineal body was marked, typically ranging from 10 to 14 cm. A dotted line is marked between B/B' and A/A'. An assistant ensures that the base of the penile skin remains above the marking to maximally preserve vascular and lymphatic contributions. Later, the penoscrotal skin flap will be divided in the midline as needed to point D to eliminate tension where the tip of the perineal flap (point E) and point D are together anchored to the perineal body.

Point A/A' is then pulled toward the surgeon while an assistant pulls the penis up in the midline. The markings between A/A' and B/B' are assessed for symmetry and corrected. Excluding the perineal flap, these are the borders of the scrotal skin to be excised for skin graft, with A/A'→B/B' representing the labial flap length, and B/B'→C/C' the labial defect. At the time of skin closure, A/A' to C/C' are re-approximated as the inferior borders of the labia majora. Figure 2 demonstrates the results.

From the *Department of Urology, Oregon Health & Science University; Portland, Ore.; †Department of Urology, University of California San Francisco; San Francisco, Calif.; and ‡Division of Plastic & Reconstructive Surgery, Department of Surgery, Oregon Health & Science University, Portland, Ore.

Received for publication November 30, 2021; accepted December 3, 2021.

Copyright © 2022 The Authors. Published by Wolters Kluwer Health, Inc. on behalf of The American Society of Plastic Surgeons. This is an open-access article distributed under the terms of the Creative Commons Attribution-Non Commercial-No Derivatives License 4.0 (CCBY-NC-ND), where it is permissible to download and share the work provided it is properly cited. The work cannot be changed in any way or used commercially without permission from the journal.

DOI: 10.1097/GOX.0000000000004103

Disclosure: The authors have no financial interest to declare in relation to the content of this article.

Related Digital Media are available in the full-text version of the article on www.PRSGlobalOpen.com.

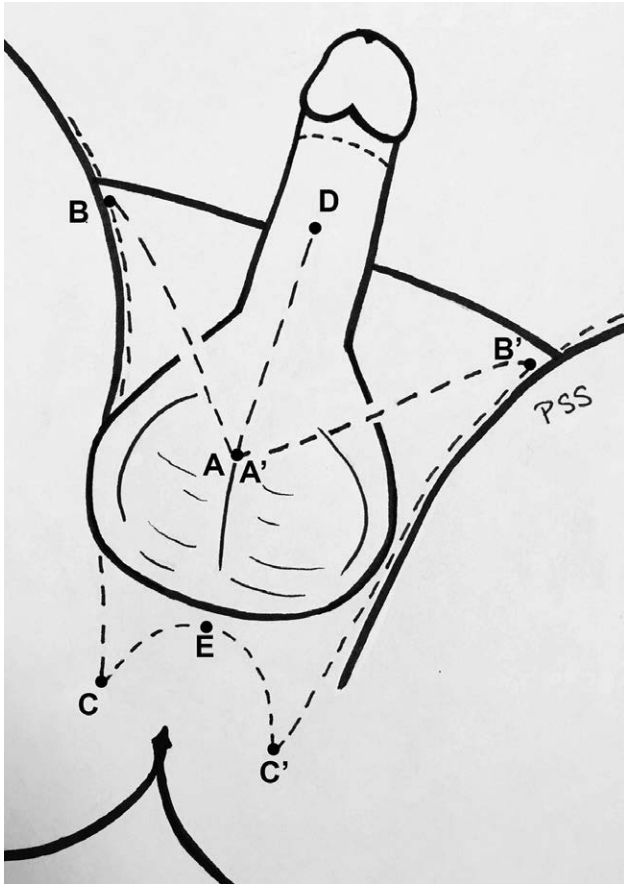


Fig. 1. Illustration of preoperative skin markings.

Variations: When the labial flap length (A/A'→B/B') is greater than the labial defect (B/B'→C/C'), we proceed and may later trim the narrow tip of the flap to improve vascularity at the end of the flap and avoid excessive labial skin. In cases of severe genital hypoplasia [dorsal penile skin length (DPS) <8cm and/or when point A/A' cannot be pulled down to the perineal body with acceptable tension], we favor late skin excision.^{2,3} Rather than excising the skin graft initially, a midline scrotal incision

Takeaways

Question: Knowing how much scrotal skin to excise during vaginoplasty can be difficult.

Findings: We present our systematic approach to planning surgical incisions to maximize efficiency and predictability.

Meaning: A systematic approach to markings allows for efficient and predictable skin excision and preoperative recognition of genital hypoplasia, which suggests an alternative approach.

is made through which penile exposure and disassembly is performed. The markings are then re-evaluated after clitoro-urethroplasty completion to assess what skin can safely be excised (Fig. 3). In our experience, patients with DPS less than 8cm tend to have insufficient penoscrotal skin flap surface area to reliably cover the area around the introitus. In severe cases, the penile skin flap may not reach the vaginal canal. Late skin excision prolongs surgical time since the graft is not processed until later; however, it allows the surgeon to use as much vascularized skin in constructing the vulva as necessary to avoid using skin graft on the vulvar surface.

Avoid having labial flap length less than labial defect length to avoid excessive wound tension. If a point B/B' cannot be found that satisfies this, we proceed with late skin excision.

RESULTS

Between August 2018 and June 2021, the authors used this technique in 142 of 148 gender-affirming vaginoplasties. Mean age and BMI was 41.3 and 28.3, respectively. Average DPS was 9.9cm; 16 of 148 patients had DPS less than 8cm. Late skin excision was utilized in six of 148 patients, of whom four had dorsal penile skin length less than 8cm.

DISCUSSION

While skin, peritoneum,⁴ or intestinal flaps⁵ may be used to construct the neovagina, genital skin is the only tissue available for the external, vulvar construction. Finding

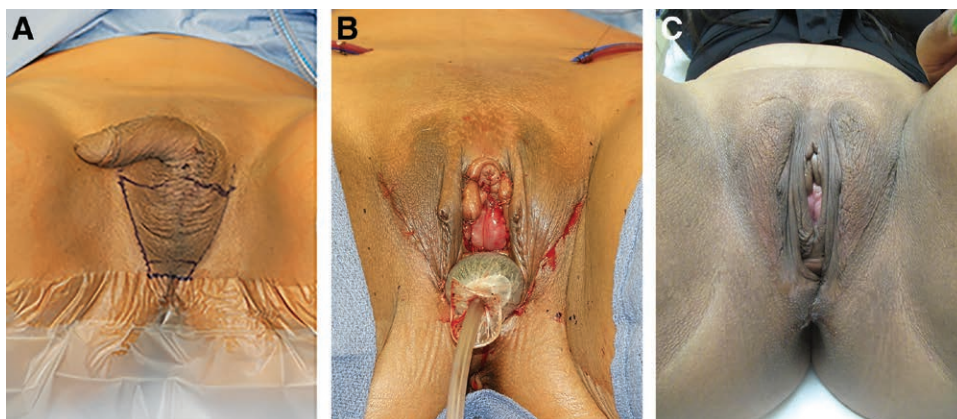


Fig. 2. Example patient. A, Preoperative appearance. B, Immediate postoperative appearance. C, Appearance 2 years postoperatively.

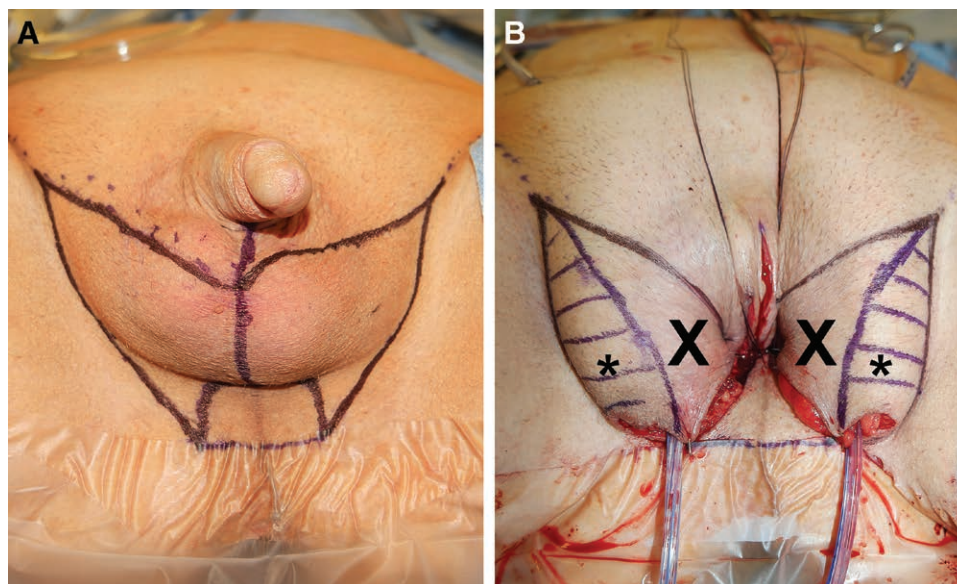


Fig. 3. Example of patient with genital hypoplasia (dorsal penile skin length: 6 cm). A, Preoperative appearance with markings using our system. B, After clitoro-urethroplasty, skin is advanced into wound to identify what skin can safely be excised. The hashed area marked with asterisk (*) indicates the area of excision; Areas marked with X indicate region predicted for excision preoperatively but were left intact after late excision due to genital hypoplasia.

a balance of wound tension and adequate skin excision can be challenging. This system for vaginoplasty incision markings has several advantages:

1. Ensuring that labial flap length ($A/A' \rightarrow B/B$) and labial defect length ($B/B' \rightarrow C/C'$) are of equal lengths simplifies skin closure and avoids “dog ears” at the supero-lateral borders of the labia majora while avoiding excessive wound tension. The surgeon’s judgment of appropriate tension in choosing the location for A/A' improves with experience.
2. Compared with methods that intentionally medialize scars,⁶ lateral labial scars in this method are more naturally camouflaged along the groin crease. We feel this is an aesthetic advantage.
3. Early (and maximal) excision of the scrotal skin allows for efficient graft processing while the surgery progresses.
4. A system for recognizing and adapting to genital hypoplasia allows safe and predictable planning for these challenging cases.

This technique can also be used for patients with greater body habitus. We tend to be slightly less aggressive with skin excision with patients with very low BMI (BMI <18). While no graft is needed for vulvoplasty,⁷ we find this method is equally useful. (See figure, Supplemental Digital Content 2, which shows an example of patient with BMI 50.5. S2a, Preoperative appearance. S2b, Immediate postoperative appearance. S2c, Appearance 1 year postoperatively. <http://links.lww.com/PRSGO/B923>.)

CONCLUSIONS

Preoperative markings affect scar location, the amount of skin harvested for grafting, and final wound tension. We describe our systematic approach for preoperative markings that can be used in all patients regardless of body habitus.

Daniel D. Dugi III, MD, FACS

3303 SW Bond Ave, CH-10-U

Portland, OR 97239

E-mail: dugi@ohsu.edu

REFERENCES

1. Goddard JC, Vickery RM, Terry TR. Development of feminizing genitoplasty for gender dysphoria. *J Sex Med.* 2007;4(4 Pt 1):981–989.
2. Opsomer D, Vyncke T, Mertens D, et al. Fifteen-year experience with the Ghent technique of penile inversion vaginoplasty. *Plast Reconstr Surg.* 2021;148:416e–424e.
3. Shoureshi P, Dugi D III. Penile inversion vaginoplasty technique. *Urol Clin North Am.* 2019;46:511–525.
4. Dy GW, Jun MS, Blasdel G, et al. Outcomes of gender affirming peritoneal flap vaginoplasty using the Da Vinci single port versus Xi robotic systems. *Eur Urol.* 2021;79:676–683.
5. Claes KEY, Pattyn P, D'Arpa S, Robbens C, Monstrey SJ. Male-to-female gender reassignment surgery intestinal vaginoplasty. *Clin Plast Surg.* 2018;45:351–360.
6. Salim A, Poh M. Gender-affirming penile inversion vaginoplasty. *Clin Plast Surg.* 2018;45:343–350.
7. Jiang D, Witten J, Berli J, et al. Does depth matter? Factors affecting choice of vulvoplasty over vaginoplasty as gender-affirming genital surgery for transgender women. *J Sex Med.* 2018;15:902–906.