

Original Article

Comparison of clinical and radiological outcomes using crestal approach sinus kit and piezoelectric surgery for sinus membrane elevation: A prospective clinical trial

Aishwarya Ratna Mamidi, Sruthima N. V. S. Gottumukkala, Satyanarayana Raju Mantena, Gautami S. Penmetsa, Konathala S. V. Ramesh, Mohan Kumar Pasupuleti

Department of Periodontics and Implantology, Vishnu Dental College, Bhimavaram, Andhra Pradesh, India

ABSTRACT

Background: To overcome the drawbacks of sinus floor augmentation procedures newer surgical techniques to reduce sinus perforation such as crestal approach sinus kit (CAS) and piezosurgery, which are minimally invasive procedures enabling uncomplicated sinus elevation have evolved. The aim of the present study was to investigate the performance of CAS kit compared to piezosurgery during maxillary sinus membrane elevation.

Materials and Methods: A total of 40 subjects requiring maxillary sinus membrane augmentation for rehabilitation with implant prosthesis in posterior maxilla were included in the study. The current study was a prospective clinical trial where osteotomy and sinus elevation was done using CAS kit in Group 1 and piezosurgery in Group 2. Platelet-rich fibrin was placed in osteotomy site and dental implants were inserted. Implant stability was evaluated at baseline and 3 months. Crestal bone loss was measured at 3, 6, and 12 months. Apical bone gain was measured at 6 and 12 months. Intragroup comparison of the study groups was done by Paired *t*-test, ANOVA test, and Friedman test. Intergroup comparison was done by unpaired *t*-test and Mann-Whitney *U*-test. $P < 0.05$ was considered statistically significant.

Results: Implant stability improved in both the groups, i.e., 79.2 ± 5.02 and 79 ± 5.31 in Group 1 and Group 2, respectively, at 3 months. Intergroup comparison showed no difference in all parameters; however, crestal bone loss was greater in piezosurgery group with a mean difference of 0.74 mm.

Conclusion: Both CAS and piezosurgery groups showed definitive improvement in all parameters. CAS group resulted in added benefits in terms of less crestal bone loss and intraoperative surgical time compared to piezosurgery group.

Key Words: Dental implants, minimally invasive surgical procedures, piezosurgery, platelet-rich fibrin, sinus floor augmentation

Received: 02-Nov-2021
Revised: 23-Feb-2022
Accepted: 12-Jul-2022
Published: 20-Oct-2022

Address for correspondence:
Dr. Sruthima N. V. S.
Gottumukkala,
Department of Periodontics
and Implantology Vishnu
Dental College, Bhimavaram,
Andhra Pradesh, India.
E-mail: sruthima@gmail.com

INTRODUCTION

Periodontal problems and dental caries are the most common causes for tooth loss.^[1] Implant placement

This is an open access journal, and articles are distributed under the terms of the Creative Commons Attribution-NonCommercial-ShareAlike 4.0 License, which allows others to remix, tweak, and build upon the work non-commercially, as long as appropriate credit is given and the new creations are licensed under the identical terms.

For reprints contact: WKHLRPMedknow_reprints@wolterskluwer.com

How to cite this article: Mamidi AR, Gottumukkala SN, Mantena SR, Penmetsa GS, Ramesh KS, Pasupuleti MK. Comparison of clinical and radiological outcomes using crestal approach sinus kit and piezoelectric surgery for sinus membrane elevation: A prospective clinical trial. Dent Res J 2022;19:88.

Access this article online



Website: www.drj.ir
www.drjjournal.net
www.ncbi.nlm.nih.gov/pmc/journals/1480

has become a widespread procedure to replace partially edentulous participants. Implants have many benefits such as improved masticatory efficiency and providing comfort to the patient.^[2]

Tooth extraction and subsequent socket repair, whether due to caries, trauma, or severe periodontal disease, frequently leads in osseous abnormalities of the alveolar ridge, including decreased height and width.^[3] In the posterior maxilla, migration of the maxillary sinus floor to a more inferior position as a result of the pneumatization, in addition to resorption of alveolar crestal bone, may complicate dental implants placement.^[4] To overcome such physiological and anatomical problems, sinus lift procedures, which facilitate the placement of longer implants in the posterior maxilla, have gained a lot of attention in recent years.

Boyne and James in 1980, and later Kent and Block in 1989, were the first to describe the technique of lateral sinus floor elevation.^[5] A crestal approach for sinus (CAS) floor elevation with subsequent placement of implants was first suggested by Tatum in 1986.^[6] The transcresal method of indirect sinus elevation entails raising the sinus membrane with simultaneous placement of an implant. The original approach entails breaking the sinus floor inward when preparing the implant bed with osteotomes of increasing sizes. Sinus perforation is the most common intraoperative complication for this technique.^[7]

The instruments of CAS kit are designed to toil the bone without perforating the membrane^[8] and piezosurgery device cuts the mineralized structures, without disturbing the soft tissues.^[9] Due to the air–water cavitation effect of the ultrasonic instrument, a piezosurgery device delivers a clear surgical site by maintaining a blood-free surgical field that allows visualization of the surgical area during bone cutting. The piezosurgery device precisely drills the bone without damaging soft tissues using piezoelectric ultrasonic vibration (25–30 kHz).^[9]

Despite the fact that there have been numerous studies on sinus membrane elevation, the application of minimally invasive techniques/approaches has not been thoroughly documented. It is worth noting that there has not been a single study in the literature comparing these two procedures to date. Hence, the purpose of the study was to evaluate and compare the clinical and radiological outcomes of sinus membrane elevation approaches done using CAS kit and piezosurgical unit.

MATERIALS AND METHODS

Study design and ethical aspects

The present study was a single-blinded, prospective clinical trial conducted at Vishnu Dental College's Department of Periodontics and Implantology from January 2019 to November 2020. The participants were categorized into two groups. The study received approval and ethical clearance from the Institutional Ethics Committee (Ref No: VDC/IEC/2018/18) as well as approval from the Clinical Trials Registry (REF/2019/08/020582). All clinical procedures followed the Declaration of Helsinki and the Good Clinical Practice Guidelines. The CONSORT guidelines were followed. [Figure 1].

Sample size and patient selection

The sample size was calculated using G Power 3.1 software (Armonk NY, USA). At a level of significance of 5%, a research power of 80%, and an expected effect size of 1.24, it was found that 18 samples per group were required (obtained from a pilot study). However, to account for dropouts, 20 samples per group were chosen. Before the trial began, all of the participants were informed about the study design and written informed consent was obtained to document that they understood the purpose of the study (including the surgical protocol, follow-ups, and potential complications).

Inclusion criteria

- Patient related: Age range between 25 and 50 years
- Teeth related: Maxillary edentulous sites with residual bone height 5–8 mm.

Exclusion criteria

- Patient related: active sinus infection and inflammation, participants undergoing radiation therapy, uncontrolled systemic diseases, poor oral hygiene maintenance, smokers, pregnancy

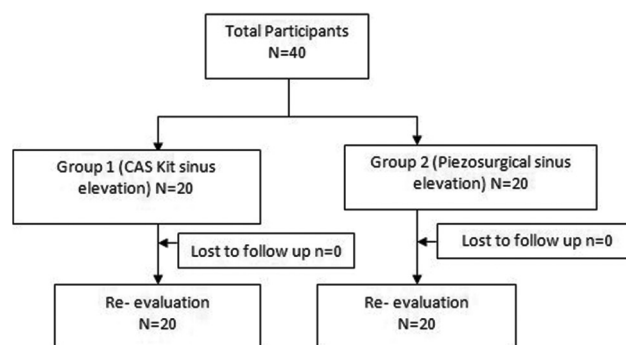


Figure 1: CONSORT flow chart.

and lactation, tumors, or pathologic growth in sinus

- Teeth related: Severe bruxism or clenching habit.

A randomized controlled clinical trial was conducted, and the assignment to Group 1 (CAS sinus elevation) and Group 2 (piezoelectric sinus elevation) was done using preprepared randomization cards with group identification number coded envelopes. All the participants were consecutively enrolled and surgeries were performed by a single surgeon.

Preoperative procedure

Alginate impressions were made for upper and lower arches. Diagnostic casts were made; occlusal stent was fabricated including one tooth anterior and posterior to the edentulous site. Long-cone paralleling technique was used to acquire digital intraoral periapical radiographs using a stent. To maintain stability in the vertical and horizontal planes, a modified commercial film positioner Rinn XCP Instrument Kit was employed. To prevent unwanted movements and angulations, an additional device was made in the shape of a hollow cylinder out of acrylic and fitted to the positioner and collimator. The vertical bone height measurement was done from crest of the bone to the sinus floor lining metal grid with 1 mm × 1 mm box for measurement.

Surgical procedure

Before the start of surgical procedure using a butterfly cannula, approximately 20 ml of the blood was drawn from cephalic vein of the patient and collected into two 10-ml Vacutainer blood collection tubes. The collected blood was centrifuged immediately within 60 s in a table-top centrifuge at a rate of 1300 rpm for 14 min. Advanced platelet-rich fibrin (PRF) was separated from the middle layer of the tubes and placed in a sterile PRF box to transform the clot into a membrane.

In the surgical site, i.e., in the posterior maxillary segments, local anesthesia with 2% lignocaine containing adrenaline at a concentration of 1: 200,000 was administered. A midcrestal incision was given using a 15C blade and full-thickness mucoperiosteal envelope flap was elevated.

In Group 1, after checking the residual bone height [Figures 2a and 3a], osteotomy preparation was done with a point (guide) drill and then a proper S-reamer drill was chosen in diameter and 1 mm shorter than the estimated bone height. For safety, drilled only 1 mm more in each step and used 1 mm

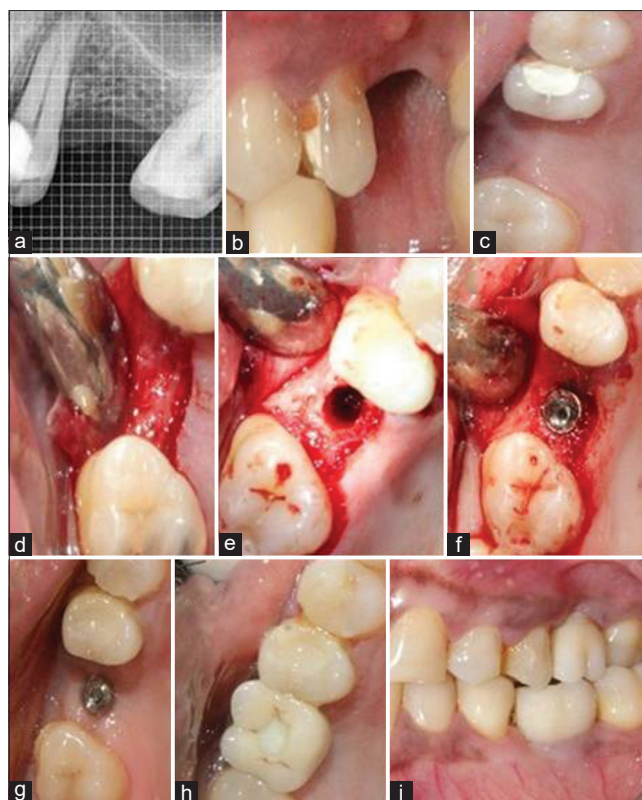


Figure 2: Surgical procedure Group 1:- (a) Preoperative radiograph - 26 (b and c) Preoperative views, (d) Flap elevation, (e) Osteotomy preparation and transcrestal sinus floor elevation done using CAS kit, (f) Implant placement, (g) Healing abutment placed after 3 months, (h) final restoration of crown, (i) Crown cementation. CAS: Crestal approach sinus.

longer stopper. S-Reamer diameter was considered based on fixture diameter and insertion depth in sinus. If the sinus inferior cortical wall did not perforate until the stopper reaches to the crestal bone, stopper was changed 1 mm longer size and drilling was done continuously [Figure 2b-e]. In Group 2, osteotomy preparation was done using piezo-osteotomy drills. A pilot drill was used to drill down to as much as 2 mm from residual bone. The diameter of the drill was increased consecutively considering the diameter of the implant to be placed. The apical breach was done using the piezosinus elevation tips [Figure 3b-e].

After feeling perforated in inferior cortical wall, the residual bone height was measured with depth gauge. If at all inferior wall got perforated, the patients were asked to close their nostrils and make them blow out to check the membrane status. After that, PRF membrane was inserted into the osteotomy site. Tapered implant with V-shaped thread design of 4.2 × 10 mm size was placed [Figures 2f and 3f]. Implant stability was measured using resonance frequency analysis;

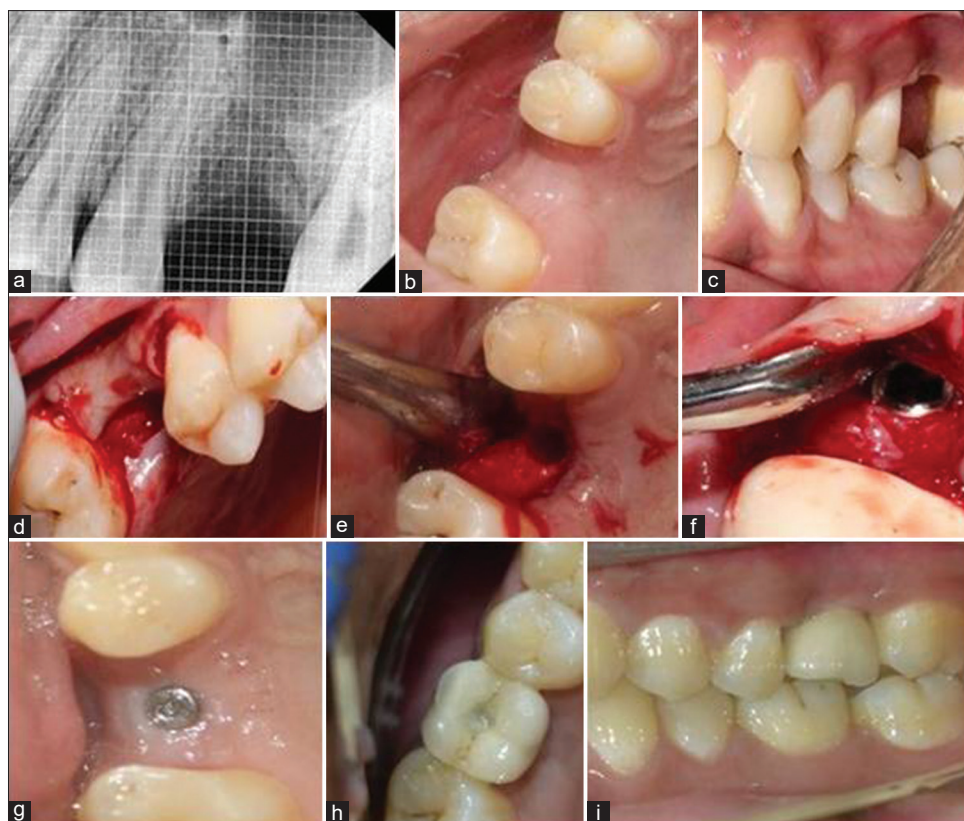


Figure 3: Surgical procedure, Group 2: (a) Preoperative radiograph - 26, (b and c) Preoperative views, (d) flap elevation, (e) osteotomy preparation and transcrestal sinus floor elevation done using Piezo tips, (f) Implant placement, (g) Healing abutment placed after 3 month, (h) final restoration of crown, (i) Crown cementation.

cover screws were connected followed by simple interrupted suturing done using 4-0 resorbable sutures. The area was protected using periodontal dressing [Figures 2 and 3].

Postoperative care

Participants were instructed not to brush over the surgical area. Antibiotics (amoxicillin + clavulanate 625 mg and metronidazole 400 mg three times a day for 3 days) and analgesics (diclofenac 50 mg twice a day for 3 days) were prescribed. Participants were advised to use 0.2% chlorhexidine mouthrinse twice daily for 1 week. Participants were recalled after 1 week during which sutures were removed and surgical area was evaluated for healing.

After allowing the healing period of 3 months for the implant to get osseointegrated, the second-stage surgery was performed. A crestal incision was given to expose the implant. The cover screw was removed and the head of the implant was thoroughly cleaned of any soft or hard tissue overgrowth and healing abutment was then placed (Figures 2g, 3g). After the physiologic contour of soft tissue was achieved (3 weeks), the transfer coping was placed

on the fixture and open or closed tray impressions were made using a silicone putty material in single stage to transfer implant position and restoration was fabricated. The final prosthesis was cemented using glass-ionomer cement on the abutment [Figures 2h, i and 3h, i].

The clinical parameters were recorded at baseline and 3, 6, and 12 months. In both the groups, intraoperative surgical time was recorded at baseline during the surgical procedure. Implant stability was evaluated at baseline and 3 months. Crestal bone loss was measured at 3, 6, and 12 months. Apical bone gain was measured at 6 and 12 months [Figures 4 and 5].

Statistical analysis

The data collected were entered into Excel sheet and the data were analyzed using SPSS 21.0 (IBM, Armonk, NY, USA) software. The results were evaluated statistically using the following methods: intragroup comparison of the study groups with means of all the parameters was done by Paired *t*-test, ANOVA test, and Friedman test. Intergroup comparison of parameters was done by unpaired *t*-test and Mann-Whitney *U*-test. Descriptive statistics were

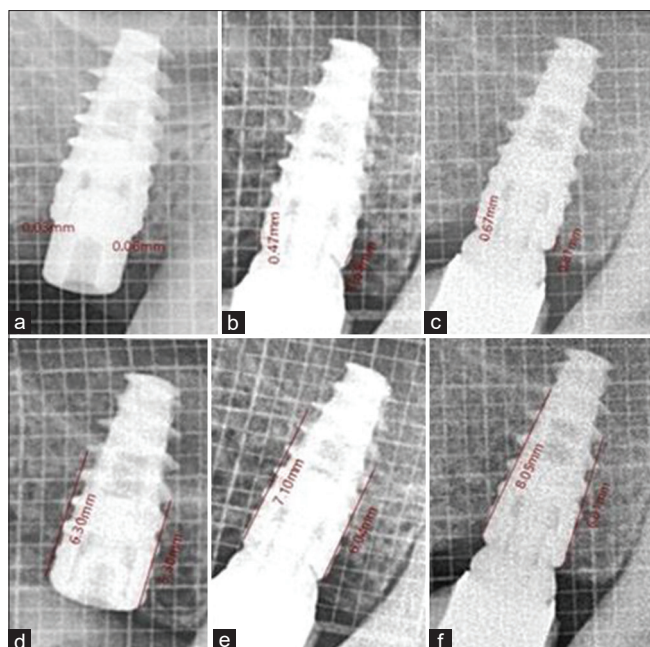


Figure 4: Group 1: Crestal bone loss at (a) 3 months, (b) 6 months, (c) 12 months; Apical bone gain at (d) Baseline, (e) 6 months, (f) 12 months.

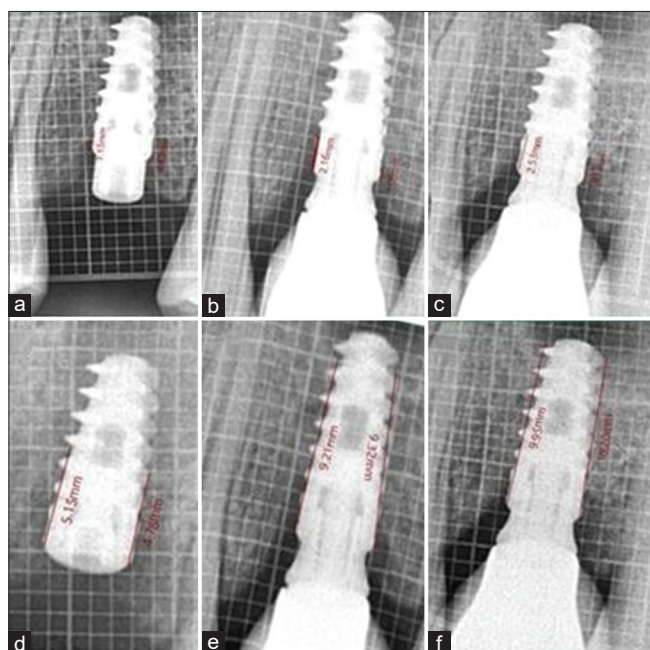


Figure 5: Group 2: Crestal bone loss at (a) 3 months, (b) 6 months, (c) 12 months; Apical bone gain (d) Baseline, (e) 6 months, (f) 12 months.

calculated as mean and standard deviation and level of clinical significance was set as 0.05.

RESULTS

A total of 36 patients were screened for inclusion and finally 20 participants with bilateral edentulous sites

in the posterior maxilla willing for implant placement and meeting all the study criteria were selected. The clinical and radiological parameters, i.e., implant stability, crestal bone loss, apical bone gain, and surgery time, were considered in all the participants. These parameters were compared at baseline and 3, 6, and 12 months. In both the groups, surgery time was recorded at baseline during the surgical procedure. Implant stability was evaluated at baseline and 3 months. Crestal bone loss was measured at 3, 6, and 12 months. Apical bone gain was measured at 6 and 12 months. The age of the subjects in the study ranged from 25 to 60 years with a mean age of 37.5 years. Fourteen males and six females were included in the study.

The mean baseline implant stability quotient (ISQ) was found to be 75.66 ± 6.05 in Group 1 and it was found to be increased to 79.2 ± 5.02 at 3 months; similarly, the mean baseline ISQ was found to be 74.3 ± 6.73 in Group 2 and it was found to be increased to 79 ± 5.31 at 3 months [Table 1], with both the groups showing adequate primary and secondary implant stability.

The mean crestal bone level on mesial side at 3 months in Group 1 was 0.06 ± 0.06 mm and it was increased to 0.29 ± 0.16 mm at 12 months, whereas the mean crestal bone level on distal side at 3 months in Group 1 was 0.11 ± 0.21 and it was increased to 0.29 ± 0.21 mm at 12 months. Similar results were observed in Group 2, where the mean crestal bone level on mesial side at 3 months was 0.58 ± 0.6 mm and it was increased to 1.02 ± 0.88 mm at 12 months. Whereas, the mean crestal bone level on distal side at 3 months in Group 2 was 0.50 ± 0.46 mm and it was increased to 1.03 ± 0.70 mm at 12 months [Table 1].

The mean crestal bone loss in the period of 12 months was found to be 0.295 mm mesially and 0.29 mm distally in Group 1 and 1.021 mm mesially and 1.039 mm distally in Group 2, which was statistically significant with the Group 2 showing greater bone loss.

The mean apical bone gain on mesial side was 1.875 mm and on distal side was 2.034 mm in Group 1 after 12 months, whereas the mean apical bone gain on mesial side was 1.982 mm and on distal side was 2.223 mm in Group 2 after 12 months [Table 2]. There was no considerable difference in the apical bone gain between the two study groups.

The average intraoperative surgical time taken was 82.77 min in Group 1 and 103.88 min in Group 2, but

Table 1: Comparison of mean implant stability quotient and crestal bone levels between Group 1 and Group 2

Parameters	Groups	Mean±SD	Mean difference	P		
ISQ values	Baseline					
	Group 1	75.66±6.05	1.30	0.655		
	Group 2	74.3±6.73				
	3 rd month					
Group 1	79.20±5.02	0.20	0.932			
Group 2	79.00±5.31					
Crestal bone levels (mm)	3 months					
	Mesial	Group 1	0.0610±0.06607	0.52	0.001*	
		Group 2	0.5810±0.60021			
	6 months	Group 1	0.2250±0.18435	0.574	0.045*	
		Group 2	0.7990±0.74082			
	12 months	Group 1	0.2950±0.16821	0.726	0.034*	
		Group 2	1.0210±0.88513			
	Crestal bone levels (mm)	3 months				
		Distal	Group 1	0.1110±0.21553	0.389	0.005*
			Group 2	0.5000±0.46698		
		6 months	Group 1	0.2520±0.21223	0.446	0.035*
			Group 2	0.6980±0.56948		
12 months		Group 1	0.2900±0.21349	0.746	0.019*	
		Group 2	1.0390±0.70048			

*P<0.05 statistically significant. ISQ: Implant stability quotient; SD: Standard deviation

Table 2: Mean apical bone gain within Group 1 and Group 2 at baseline 6 and 12 months

Apical bone gain (mm)	Group 1		Group 2	
	Mean gain	P	Mean gain	P
Mesial side				
Baseline-6 months	1.001	0.000*	1.231	0.001*
Baseline-12 months	1.875	0.001*	1.982	0.000**
6-12 months	0.8740	0.000	0.751	0.001*
Distal side				
Baseline-6 months	0.826	0.000*	1.060	0.000**
Baseline-12 months	2.034	0.000*	2.223	0.000**
6-12 months	1.208	0.001*	1.163	0.001*

*P<0.05 Statistically significant; **P<0.001- Highly statistically significant

there was no statistical difference in surgery time in between the two groups.

DISCUSSION

Maxillary sinus membrane elevation is an essential procedure to recover the appropriate bone height for implant treatment, which is generally used clinical technique by many dentists. Indirect sinus lift is a procedure, in which sinus is approached from crest

of alveolar ridge and an osteotome is used. The main intrasurgical complication for this procedure is sinus perforation. To overcome this problem, various new surgical techniques have been employed for sinus membrane elevation such as CAS kit and piezoelectric surgical procedures. The instruments of CAS kit are designed to grind the bone enabling safe sinus membrane elevation even at the septum area, using a high-speed drill with a special blade, reducing the risk of sinus membrane perforation. Piezosurgery device cuts the mineralized structures, without disturbing the soft tissues, and also involves the use of piezoelectric tips to elevate the sinus membrane. The advantage of piezoelectric osteotomy lies in being able to cut the bony window with great simplicity and precision when ensuring the membrane's integrity. The present study evaluated implant stability, crestal bone loss, apical bone gain, and intraoperative surgical time using CAS kit and piezoelectric surgery.

In the current investigation, residual bone height of >5 mm was selected and sinus was elevated using transcresal approach and the implants were placed in one-step procedure. In a one-stage procedure, a minimum base height of 4–5 mm is recommended for adequate implant stabilization and parallelism. One-step procedure is a conservative approach and less time-consuming with reduced postoperative morbidity.

A total of 40 implants using either of the techniques were placed and no intra- or postoperative complications were encountered. Implant stability is measured at two different stages. Primary stability is usually obtained from the mechanical engagement with cortical bone and it depends on bone density, surgical technique, and implant geometry. Primary stability is affected by bone quality and quantity, surgical technique, and implant geometry.^[10]

The mean implant stability increased significantly from baseline to 3 months in both the groups. The results of our study were comparable to an earlier study, where implant stability was compared using bicortical fixation, unicortical fixation, and indirect sinus elevation approaches, in which indirect sinus elevation group showed more implant stability. No difference in implant stability was observed between the two groups.^[11]

All the implants had ISQ values above 75 at first measurement, indicating that this procedure provided good primary stability, which is the most important

basis for implant success. The mean ISQ values of 69.1 and 59.6 were obtained in previous studies where implants were placed using indirect sinus elevation without bone grafting using osteotome technique, respectively.^[12,13] These values were less compared with our study, indicating that better implant stability can be achieved using CAS kit and piezoelectric techniques as compared to conventional osteotome techniques. All the implants remained stable throughout the study period.

Crest module is the transosteal portion of an implant that creates a transition zone to the load-bearing implant body and is designed to hold the prosthetic components in place. The tissue height above the implant is on an average 2.5 mm, and usually, the toothbrush bristles cannot enter a sulcus more than one mm. Crestal bone is weakest against shear forces and strongest against compressive forces. The bone loss may be due to the lack of mechanical stimulation in the crest region. A gradual and progressive increase in the loads during prosthetic fabrication stimulates an increase in density. This will result in definite preservation of crestal bone, particularly in Type 3 and Type 4 bone.^[14]

The mean crestal bone loss in Group 1 at 6 months was 0.25 mm. The crestal bone loss using CAS kit was less when compared to study conducted by Rawat *et al.*, where 0.6 mm of crestal bone loss was observed using osteotome technique, which was equivalent to the crestal bone loss of 0.79 mm in Group 2. The results indicate less crestal bone loss using minimally invasive CAS kit.^[15]

After 12 months of implant insertion, there was a statistically significant difference in crestal bone loss among Group 1 and 2 implants, i.e., 0.29 and 1.03 mm, respectively. The average bone loss being more around Group 2 implants, this could be because of the simplified surgical procedure using CAS kit with specially designed blades that can exactly drill the cortical bone with smooth grinding.

In the present study, it was observed that 12 months after implant placement, the mean crestal bone loss around Group 1 was 0.29 mm, which were in accordance with a study where CAS kit with hydraulic pressure was used.^[8] The mean crestal bone loss of 0.61 and 0.7 mm at 12 months was observed in Zhou *et al.* and Brizuela *et al.*'s studies, where CAS kit with hydraulic pressure was used in grafted sinuses,^[16,17] in which more bone loss was seen when

compared to our study, respectively. In the present study, CAS kit alone was used and less crestal bone loss was observed when compared to previous studies where CAS kit along with hydraulic pressure was used.

In a previous analysis, crestal bone loss of 0.23 and 0.74 mm in nongrafted and grafted sinuses was reported, which was in accordance with our findings, and they concluded that crestal bone loss was lower in nongrafted sinuses than in grafted sinuses.^[18] The rationale for the use of graft material is to maintain the Schneiderian membrane in the highest possible position and to improve implant stability and act as a space maintainer. Main factor affecting the primary stability of dental implants is bone height and its quality which could be improved independent of the presence of grafting materials. In the transcristal approach for nongraft sinus floor elevation with implant insertion, the tips of the implants maintain the membrane at a proper height and functions as "tent pegs." Within a closed cavity below a lifted sinus membrane, the osteogenic potential of the bone and sinus membrane is highly protected. Sinus membrane has innate osteogenic potential and contributes to bone regeneration in sinus elevation procedures.^[18,19] In nongrafted sinuses, the implant survival rate and new bone formation are comparable to grafted sinuses.^[18,20] However, in transcristal approach, the more protrusion of the implant into the sinus increases the risk of sinus membrane perforation. Especially, in sinus floor elevation procedures without grafting materials, the rotating implant thread can snag the Schneiderian membrane during installation of the implant. Furthermore, any indirect sinus elevation procedure can block the visualization of the sinus membrane. Hence, an accurate radiographic assessment such as CBCT and use of noninvasive surgical procedures such as piezosurgical unit may prevent membrane perforation.

No bone grafts were used in the current study and PRF was used as these membranes represent a simple and efficient way to cover and protect the sinus membrane or osteotomy window. PRF had been used as a bone grafting material in our study, which has acted as a "placeholder" to some extent and provided the necessary scaffold for bone regeneration. The PRF membrane could protect the sinus membrane during implant installation and thereby minimize the risk of membrane perforation or tear. PRF as a grafting material would have an advantage because the fibrin

matrix can aid in wound closure and membrane repair.^[19]

The mean bone gain measured in our study was 2.03 and 2.23 mm in Group 1 and 2, respectively, which was similar to what had been reported in studies conducted by Schmidlin *et al.*, Nedir *et al.*, with a mean bone gain of 2.5 mm after performing transalveolar sinus floor elevation without grafting material.^[21,22]

In our study, the residual bone height was >5 mm. The difference in the implant length protruding into the sinus is variable in our study. Implants that protrude more deeply into the sinus act as longer tent pegs, creating a larger cavity for the new bone to form. The implant length was found to be positively correlated with the new bone formation in this study, which was in accordance with earlier studies. The higher the membrane was elevated, the more bone would be created. More bone gain was obtained in our study in cases with a residual bone gain of 5–7 mm and less bone gain was obtained in cases with 8 mm residual bone height. The mean bone gain obtained in nongrafted sinuses was 2.45 mm in a former study which was in accordance with our study with a 12-month follow-up where they concluded that the application of grafting materials has no significant advantage in terms of clinical success after implant installation.^[21,22] Although both the approaches showed good success, a general limitation to success using these techniques is the reduced subantral bone height, which is necessary to stabilize the implant.

In our study, intraoperative surgical time was greater in piezosurgery group. It has been documented that piezosurgery is more time-consuming than conventional techniques due to the slow and precise bone cutting in piezosurgery in a former study conducted by Baldi *et al.* In our study, the mean surgical time obtained in Group 1 and Group 2 was 82 min and 103 min, respectively.^[9]

Within the limits of the current investigation, both the groups showed good primary stability, implant survival rate, adequate gain in apical bone, high predictability, low morbidity, and moderate surgical time. However, piezosurgery group showed a greater crestal bone loss as compared to CAS kit group. The advantages of both the techniques are minimally invasive and easy handling which requires short learning curve.

Limitations of the study

The long-term clinical significance should be analyzed with larger sample size in further research. Only two-dimensional radiological assessment was done, but three-dimensional radiological assessment will provide better assessment of treatment outcome.

CONCLUSION

Use of CAS kit for indirect sinus elevation showed better results in both clinical and radiological outcomes when compared to piezosurgery. Studies with larger sample sizes and longer follow-up should be carried out to further explore the effectiveness of CAS kit for transcresal sinus approach and implant placement.

Financial support and sponsorship

Nil.

Conflicts of interest

The authors of this manuscript declare that they have no conflicts of interest, real or perceived, financial or non-financial in this article.

REFERENCES

1. Lundgren S, Cricchio G, Hallman M, Jungner M, Rasmusson L, Sennerby L. Sinus floor elevation procedures to enable implant placement and integration: Techniques, biological aspects and clinical outcomes. *Periodontol* 2000 2017;73:103-20.
2. Tarun Kumar AB, Anand U. Maxillary sinus augmentation. *J Int Clin Dent Res Organ* 2015;7:81-93.
3. Abdullah A, Murriky A, Shafik S. Influence of platelet rich fibrin on postextraction socket healing: A clinical and radiographic study. *Saudi Dent J* 2017;29:149-55.
4. Bathla SC, Fry RR, Majumdar K. Maxillary sinus augmentation. *J Indian Soc Periodontol* 2018;22:468-73.
5. Boyne PJ, Lilly LC, Marx RE, Moy PK, Nevins M, Spagnoli DB, *et al.* *De novo* bone induction by recombinant human bone morphogenetic protein-2 (rhBMP-2) in maxillary sinus floor augmentation. *J Oral Maxillofac Surg* 2005;63:1693-707.
6. Tatum H Jr. Maxillary and sinus implant reconstructions. *Dent Clin North Am* 1986;30:207-29.
7. Summers RB. Sinus floor elevation with osteotomes. *J Esthet Dent* 1998;10:164-71.
8. Gatti F, Gatti C, Tallarico M, Tommasato G, Meloni SM, Chiapasco M. Maxillary sinus membrane elevation using a special drilling system and hydraulic pressure: A 2-year prospective cohort study. *Int J Periodontics Restorative Dent* 2018;38:593-9.
9. Baldi D, Menini M, Pera F, Ravera G, Pera P. Sinus floor elevation using osteotomes or piezoelectric surgery. *Int J Oral Maxillofac Surg* 2011;40:497-503.
10. Winkler S, Morris HF, Ochi S. Implant survival to 36 months as

- related to length and diameter. *Ann Periodontol* 2000;5:22-31.
11. Hsu A, Seong WJ, Wolff R, Zhang L, Hodges J, Olin PS, *et al.* Comparison of initial implant stability of implants placed using bicortical fixation, indirect sinus elevation, and unicortical fixation. *Int J Oral Maxillofac Implants* 2016;31:459-68.
 12. Lai HC, Zhuang LF, Lv XF, Zhang ZY, Zhang YX, Zhang ZY. Osteotome sinus floor elevation with or without grafting: A preliminary clinical trial. *Clin Oral Implants Res* 2010;21:520-6.
 13. Marković A, Mišić T, Calvo-Guirado JL, Delgado-Ruiz RA, Janjić B, Abboud M. Two-center prospective, randomized, clinical, and radiographic study comparing osteotome sinus floor elevation with or without bone graft and simultaneous implant placement. *Clin Implant Dent Relat Res* 2016;18:873-82.
 14. Aparna IN, Dhanasekar B, Lingeshwar D, Gupta L. Implant crest module: A review of biomechanical considerations. *Indian J Dent Res* 2012;23:257-63.
 15. Rawat A, Thukral H, Jose A. Indirect sinus floor elevation technique with simultaneous implant placement without using bone grafts. *Ann Maxillofac Surg* 2019;9:96-102.
 16. Zhou X, Hu XL, Li JH, Lin Y. Minimally invasive crestal sinus lift technique and simultaneous implant placement. *Chin J Dent Res* 2017;20:211-8.
 17. Brizuela A, Martín N, Fernández-Gonzalez FJ, Larrázabal C, Anta A. Osteotome sinus floor elevation without grafting material: Results of a 2-year prospective study. *J Clin Exp Dent* 2014;6:e479-84.
 18. Galindo-Moreno P, Fernández-Jiménez A, Avila-Ortiz G, Silvestre FJ, Hernández-Cortés P, Wang HL. Marginal bone loss around implants placed in maxillary native bone or grafted sinuses: A retrospective cohort study. *Clin Oral Implants Res* 2014;25:378-84.
 19. Kanayama T, Horii K, Senga Y, Shibuya Y. Crestal approach to sinus floor elevation for atrophic maxilla using platelet-rich fibrin as the only grafting material: A 1-year prospective study. *Implant Dent* 2016;25:32-8.
 20. Pjetursson BE, Ignjatovic D, Matuliene G, Brägger U, Schmidlin K, Lang NP. Transalveolar maxillary sinus floor elevation using osteotomes with or without grafting material. Part II: Radiographic tissue remodeling. *Clin Oral Implants Res* 2009;20:677-83.
 21. Nedir R, Bischof M, Vazquez L, Nurdin N, Szmukler-Moncler S, Bernard JP. Osteotome sinus floor elevation technique without grafting material: 3-year results of a prospective pilot study. *Clin Oral Implants Res* 2009;20:701-7.
 22. Schmidlin PR, Muller J, Bindl A, Imfeld H. Sinus floor elevation using an osteotome technique without grafting materials or membranes. *Int J Periodontics Restorative Dent* 2008;28:401-9.