



Case report

Conversion From Knee Arthrodesis Back to Arthroplasty: A Particular Challenge in Combination With Fungal Periprosthetic Joint Infection

Sven Frieler, MD ^{a, b, c, d, *}, Emre Yilmaz, MD ^a, Ryan Goodmanson, DO ^{c, d},
Yannik Hanusrichter, MD ^a, Thomas A. Schildhauer, MD ^a, Hinnerk Baecker, MD ^a

^a Department of Orthopedics and Trauma Surgery, BG University Hospital Bergmannsheil, Ruhr University Bochum - RUB, Bochum, Germany

^b Hansjörg Wyss Hip and Pelvic Center, Swedish Hospital, Seattle, WA, USA

^c Swedish Neuroscience Institute, Swedish Medical Center, Seattle, WA, USA

^d Seattle Science Foundation, Seattle, WA, USA

ARTICLE INFO

Article history:

Received 12 August 2020

Received in revised form

19 October 2020

Accepted 24 October 2020

Available online 5 December 2020

Keywords:

Arthroplasty

Knee arthrodesis

PJI

fPJI

Fungal periprosthetic joint infection

TKA

Conversion

Three-stage revision

ABSTRACT

A 58-year-old female treated at an outside facility with knee arthrodesis due to persistent periprosthetic joint infection fulfilled all prerequisites for a conversion back to arthroplasty, as part of a 2-stage revision. Owing to the detection of *Candida parapsilosis*, the treatment concept was converted to a three-stage procedure. A scheduled spacer exchange with additional amphotericin B-loaded polymethylmethacrylate was conducted as an intermediate revision before reimplantation. Conversion in the setting of fungal periprosthetic joint infection presents a challenge, and successful treatment hinges on the use of proper antifungal and antimicrobial protocols, advanced surgical techniques, and a multi-disciplinary team approach. At the 3-year follow-up, successful infection eradication as measured by the Delphi-based consensus definition was achieved with a range of motion of 0°–100°.

© 2020 The Authors. Published by Elsevier Inc. on behalf of The American Association of Hip and Knee Surgeons. This is an open access article under the CC BY-NC-ND license (<http://creativecommons.org/licenses/by-nc-nd/4.0/>).

Introduction

Knee arthrodesis is a viable salvage procedure after failed total knee arthroplasty (TKA), providing stability and decreased pain levels, but is also associated with low patient-reported outcome measures and high levels of functional disability [1–3]. Conversion of a fused knee back to arthroplasty can be a challenging procedure and has shown to be associated with high complication rates such as knee stiffness, extensor mechanism insufficiency, instability,

implant failure, and periprosthetic joint infection (PJI) [1,4–8]. Provided adherence to strict indications, a conversion back to knee arthroplasty might be an option for patients wanting to resume normal daily private and professional activities.

Prerequisites for patients undergoing this procedure are a sufficient extensor mechanism and adequate soft-tissue coverage. In addition, realistic patient expectations with regard to the functional outcome along with the willingness and motivation to continuously participate in the postoperative follow-up care are needed for the success of the procedure [1,9,10]. A recent meta-analysis showed good clinical results but a high complication rate of up to 65% [11]. The importance of a thorough patient selection process is emphasized and aids in the outcome of this rare procedure.

In the setting of PJI, a conversion must be planned meticulously. Fungal PJI (fPJI) presents even more of a challenge and has been considered as a difficult-to-treat (DTT) PJI, with high complication and failure rates reported in the literature [12,13]. Owing to its rarity, there is a lack of data for converting a knee arthrodesis back to arthroplasty in a patient with fPJI.

BG University Hospital Bergmannsheil, Bochum, Ruhr University Bochum - RUB, Bürkle-de-la-Camp-Platz 1, 44789, Bochum, Germany.

IRB statement: The authors certify that all applicable institutional and governmental regulations concerning the ethical use of clinical data were followed during the course of this research. This study (IRB ID: 18-6538-BR) was approved by the local ethics committee.

* Corresponding author. 550 17th Avenue, Suite 600, Seattle, WA 98122, USA. Tel.: +1 206 475 9514.

E-mail address: sven.frieler@bergmannsheil.de

<https://doi.org/10.1016/j.artd.2020.10.007>

2352-3441/© 2020 The Authors. Published by Elsevier Inc. on behalf of The American Association of Hip and Knee Surgeons. This is an open access article under the CC BY-NC-ND license (<http://creativecommons.org/licenses/by-nc-nd/4.0/>).

Case history

A 58-year-old Caucasian female without relevant comorbidities in addition to a spinal cord stimulator with spinal instrumentation in her history underwent a one-stage exchange from unicompartamental knee arthroplasty to TKA in June 2016.

Owing to further postoperative multidirectional instability, a one-stage exchange to a semiconstrained TKA was conducted in October 2016. This included additional metaphyseal augmentation to address relevant bone loss. During the early postoperative course, she developed an acute PJI and underwent multiple revisions with debridement, antibiotics, and implant retention without successful PJI eradication. In December 2016, a one-stage conversion to a cemented, intramedullary knee arthrodesis was carried out because of persistent PJI and large bone defects (Fig. 1a).

In June 2017, the patient subsequently presented to our total joint outpatient department for further treatment of her chronic PJI. The

main objective was to evaluate the possibility of PJI eradication and conversion back to TKA. A thorough workup, following the recommendations of the PRO-IMPLANT Foundation, was initiated, including preoperative joint aspiration for microbial cultures to identify bacterial and fungal pathogens, as well as determination of the synovial white blood cell count. Given the laboratory results of synovial white blood cell count of 3200/ μ l, draining sinus tract, and recent revision history, she met several major criteria for PJI [14–16]. Serum C-reactive protein and white blood cell were normal, and at this time, cultures were not growing any organisms. Therefore, culture-negative PJI was suspected. Figure 2 provides a detailed timeline of the patient history.

Treatment concept

The diagnosis and treatment algorithm is based on the recommendations of the PRO-IMPLANT Foundation [16,17]. It is built on a

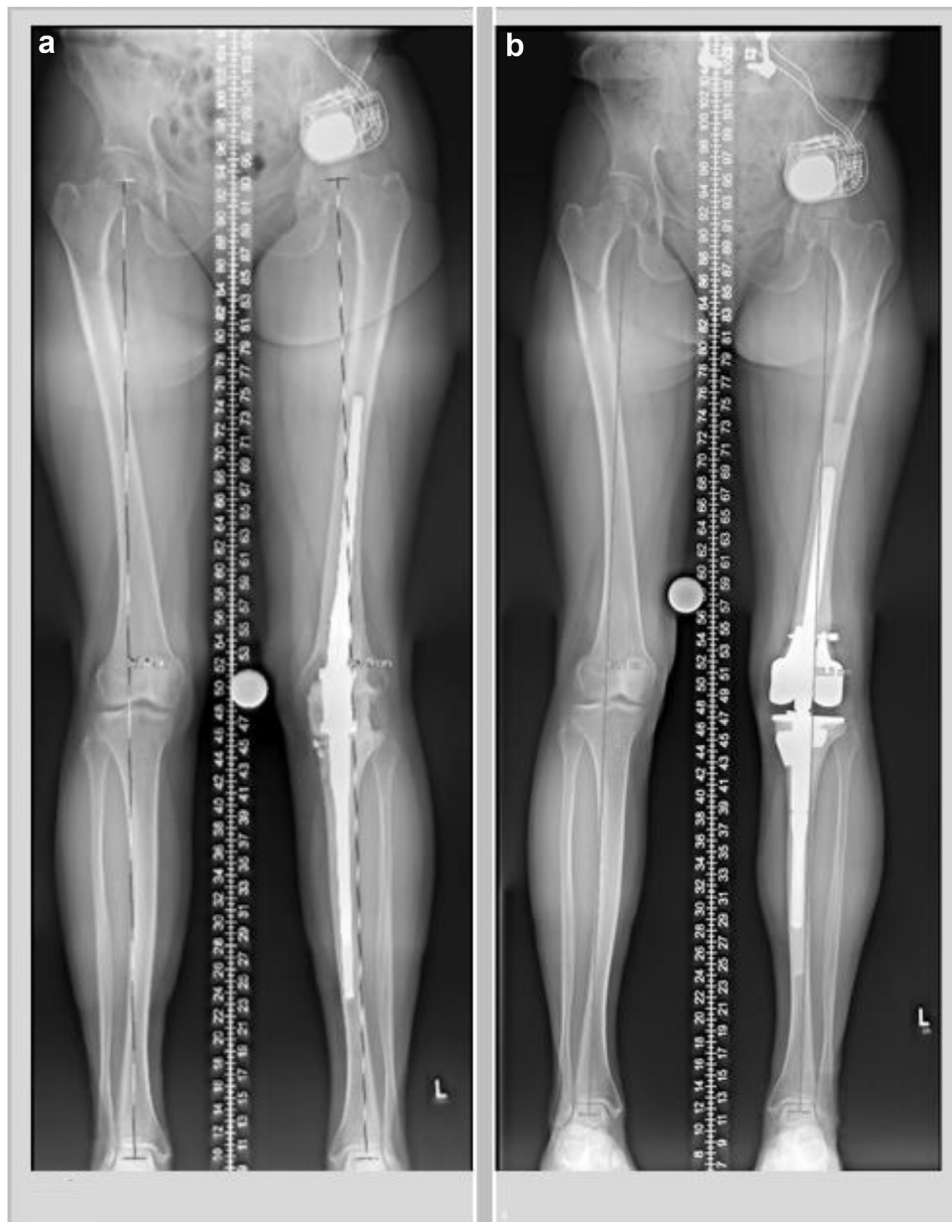

Figure 1. Conversion of an intramedullary knee arthrodesis (a) back to arthroplasty using a rotating hinge prosthesis (b).

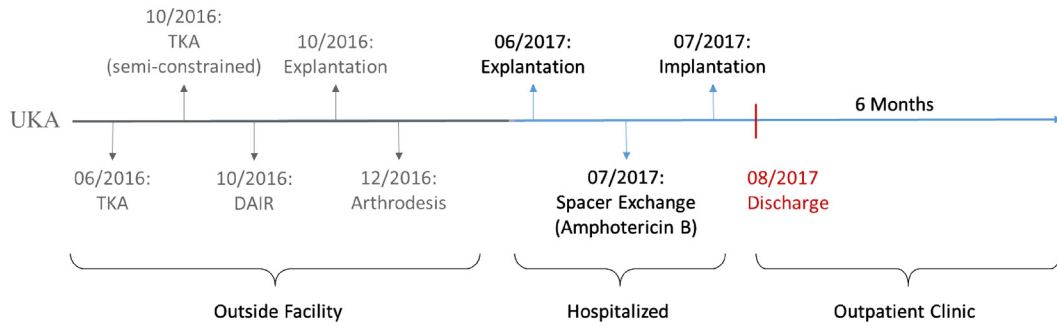


Figure 2. Timeline: patient history. UKA, unicompartmental knee arthroplasty; DAIR, debridement, antibiotics and implant retention.

multidisciplinary team (MDT) in which different medical specialties including infectologists, microbiologists, and orthopaedic surgeons are represented.

To determine the true extent of bone loss and to gather multiple tissue samples to identify the causative agent, a two-stage revision

was conducted. In addition, evaluation of the extensor mechanism must be an integral part of the initial operation to develop a precise planning of the further treatment. First, the cemented arthrodesis was explanted followed by a radical debridement with removal of all foreign material, cement remnants, and infected tissue. The

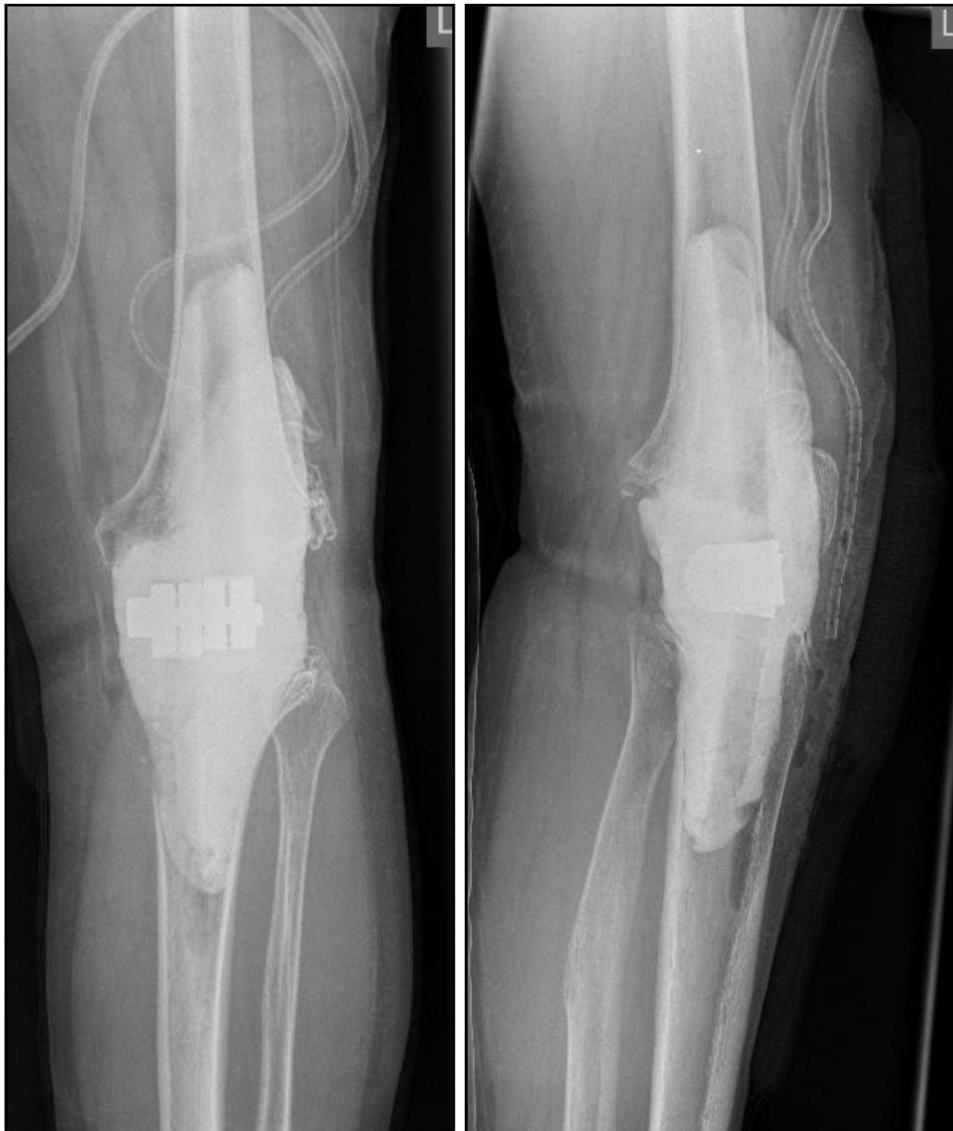

Figure 3. Poly(methyl methacrylate) spacer with carbon rods and a tube-to-tube connector.

extensor mechanism appeared to be intact. Tissue biopsies were taken along with sonication of the retrieved implants for microbiology and histologic workup. A fixed temporary arthrodesis with vancomycin- and gentamicin-loaded bone cement for dead-space management and local antimicrobial treatment was implanted [18,19]. Empirical antimicrobial therapy with ampicillin and sulbactam IV was initiated, after taking biopsies.

The microbiological analysis showed a polymicrobial infection with *Candida parapsilosis* and *Enterococcus faecium* in 2 of 5 samples. Histology of the periprosthetic tissue confirmed the diagnosis of PJI (≥ 23 granulocytes per 10 high-power fields) according to Krenn and Morawietz [20]. Following the recommendations of the PRO-IMPLANT Foundation [16,17] for dealing with DTT chronic PJI, 3 weeks after explantation, a scheduled spacer exchange to an amphotericin B–loaded, fixed poly(methyl methacrylate) spacer was conducted (Fig. 3). A rotating hinge revision arthroplasty (NexGen RH Knee, Zimmer Biomet, Warsaw, IN) was implanted another 3 weeks later (Fig. 4). Owing to extensive bone loss (AORI F2B/T2B), highly porous metaphyseal cones (Trabecular Metal, Zimmer Biomet, Warsaw, IN) were used for tibial and femoral

augmentation. Our treatment concept provides consistent antimicrobial and antifungal therapy without drug holiday and joint aspiration before implantation of a new prosthesis. Prerequisites for implantation are satisfactory clinical course and declining inflammatory parameters.

Owing to the detection of *Candida parapsilosis* and *Enterococcus faecium*, antimicrobial treatment with ampicillin and gentamicin in addition to caspofungin for antifungal therapy was started. Antimicrobial and antifungal IV therapy was administered for 10 days and then switched to oral medication with amoxicillin and fluconazole. The total duration of combined antimicrobial and antifungal therapy was 12 weeks with amoxicillin and 6 months with fluconazole (Fig. 5).

Outcome

The patient presented in the outpatient clinic after 3, 6, and 12 months and annually thereafter. At the 3-year follow-up, successful infection eradication was verified because of the Delphi-based consensus definition by Diaz-Ledezma et al. [21]: (1) healed

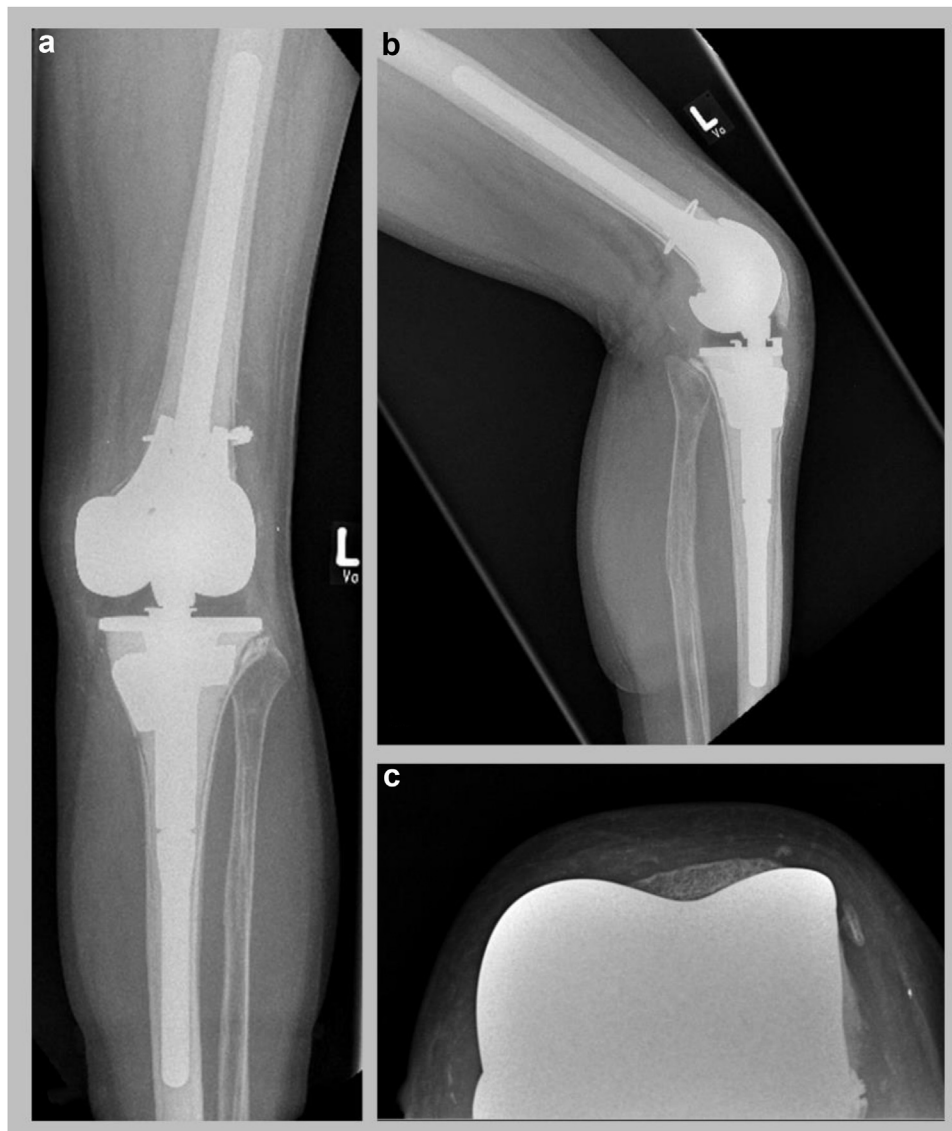

Figure 4. NexGen RH Knee (Zimmer Biomet, Warsaw, IN) in (a)anteroposterior, (b) lateral, and (c) tangential views of the patella.

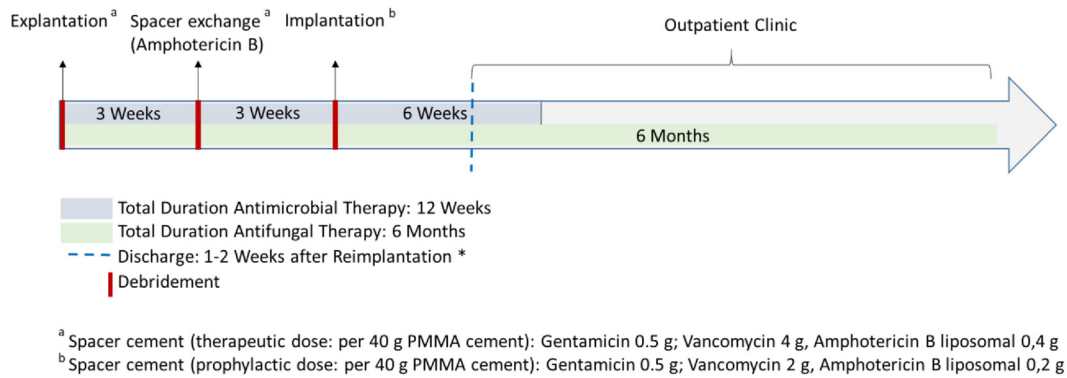


Figure 5. The three-stage exchange procedure.

wound without fistula persists, drainage, or pain and no infection recurrence caused by the same organism; (2) no subsequent surgical intervention for persistent or perioperative infection after revision surgery; and (3) no occurrence of PJI-related mortality.

The range of motion at the latest follow-up was 0°–100° (Fig. 6). No extension limitation or weakness, as well as no clinical or radiological signs of loosening, was observed (Fig. 4). No complication or reinfection was documented. The patient showed significant improvements in overall satisfaction and mobility. Her daily-life activity and capability to work have been re-established. The patient went back to work as a full-time geriatric nurse.

Discussion

A standardized antimicrobial and antifungal therapy based on previously published concepts of Zimmerli et al., the PRO-IMPLANT Foundation, and the European Bone and Joint Infection Society [16,22,23] to improve mobility and achieve infection eradication was conducted. Removal of the implant and any foreign material as part of a one- or two-stage exchange procedure [24] and antimicrobial treatment according to the susceptibility of the microorganism [23] form the core of their current management algorithm in chronic PJI. In severe cases with DTT microorganisms and/or unsatisfactory bone or soft tissue, a three-stage exchange must be considered.

Owing to the intraoperatively detected DTT pathogen (*Candida*), the procedure was adjusted from a two-stage to three-stage revision (Fig. 5) according to the PRO-IMPLANT recommendations. To the best of our knowledge, this is the first report of a patient with an fPJI who successfully underwent a conversion from an intramedullary knee arthrodesis to a rotating hinge prosthesis (Fig. 1a and b).

fPJI is a rare occurrence and has only been reported in approximately 1% of all PJIs [25]. For fPJI and for conversion from arthrodesis to arthroplasty, the literature provides only a few studies with a small number of patients and various treatment concepts [12]. No gold standard in the management of fPJI has been established. This includes the surgical procedure and the antimicrobial therapy or the duration of treatment, as noticed at the last International Consensus Meeting on Prosthetic Joint Infection [14].

Schoof et al. [26] reported heterogeneity in the treatment of fPJIs of the hip. Of 45 cases of fPJIs, 7 (16%) patients received a permanent resection arthroplasty. Two (4%) patients underwent one-stage exchanges and 26 (58%) 2-stage procedures. Furthermore, they noticed delayed arthrodesis in one (2%) patient, 5 (11%) debridements with retention of the prosthesis, and 4 (9%) patients were treated solely with antifungal suppression therapy. In 78% of the cases, the use of local antimycotic agents has not been reported. In 2018, Brown et al.

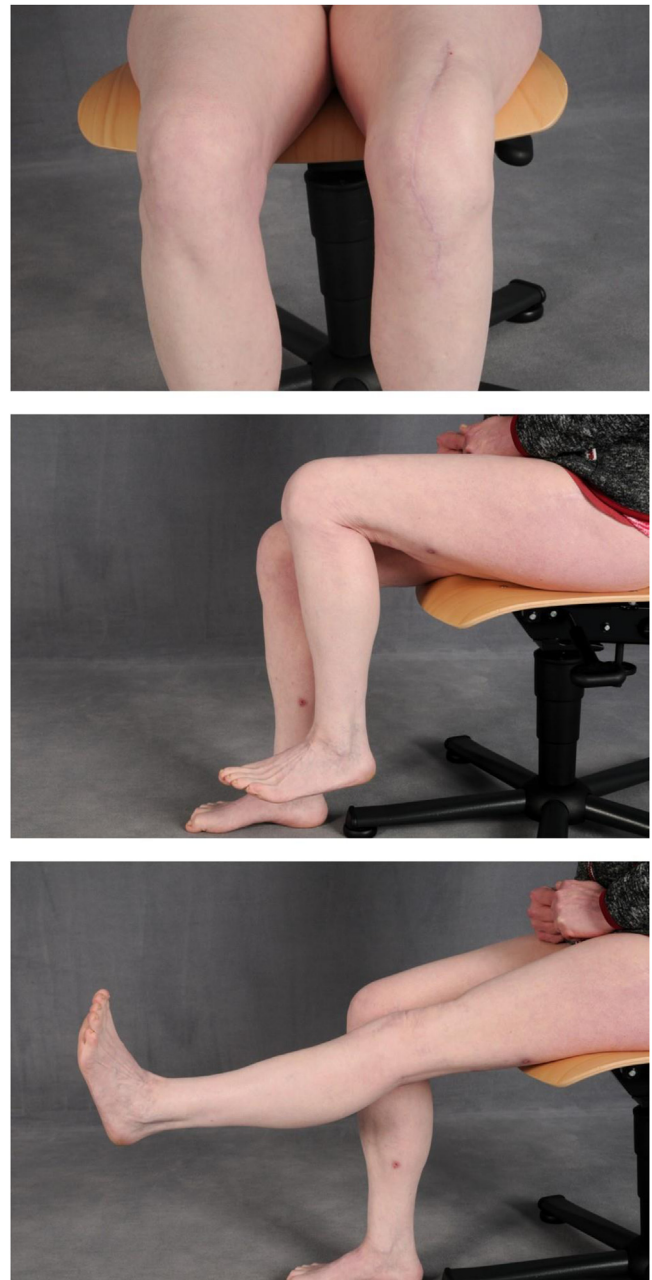

Figure 6. Patient at 3-y follow-up, knee in anteroposterior position.; extension 0° and flexion 100° in the lateral position.

[12] showed a similar heterogeneity presenting their fPJI collective, including 31 patients with PJI of the hip and knee, treated with debridement, antibiotics, and implant retention, two-stage exchange, resection arthroplasty, and different antimicrobial therapy.

Regarding the conversion from knee arthrodesis back to arthroplasty, Jauregui et al. [27] reported in their meta-analysis a good clinical outcome. The overall complication rate was 47% along with a failure rate of 11%. Nevertheless, most patients were satisfied with the procedure. Kernkamp et al. [11] reported in their analysis of 123 converted TKA a mean gain of flexion to be 80° and an improvement of Hospital for Special Surgery score by 20 points. However, they reported complications including skin necrosis (25%), infection (11%), revision (11%), and refusion of the knee (4.9%). A complication-free course has only occurred in about 35% of the reported cases and represents the specialized nature of this procedure and the follow-up necessary for its success.

Issues can arise in instances of infected knee arthrodesis that differ from that of a patient who underwent normal revision arthroplasty. However, owing to advances in total joint arthroplasty techniques, problems that previously posed issues to the orthopaedic surgeon, such as extensive bone defects, insufficiency of extensor apparatus, and persistent PJI, are only relative indications for arthrodesis today. Modern treatment techniques such as highly porous metaphyseal cones to address bone deficiency [28] and extensor mechanism reconstruction by using a particular monofilament polypropylene mesh [29,30] are lessening the instances where knee arthrodesis is needed. Along with technological advancements, new diagnostic and PJI management concepts, realized by an MDT, enable new treatment options for this subset of patients. Thus, the use of knee arthrodesis is limited to a limb-saving procedure and not a general treatment for failed TKA due to PJI. This is in accordance with Gottfriedsen et al. who reported a significant decrease in the 5-year cumulative incidence of knee arthrodesis in a nationwide register-based study [31].

Ravikumar et al. [32] showed the successful conversion of an infected fused knee to TKA. In our patient, successful infection eradication as measured by the Delphi-based consensus definition was achieved. The conversion from knee arthrodesis to TKA showed improvement in the range of motion, pain scores, and the overall satisfaction.

Conclusion

MDT approaches are combining modern surgical procedures with advanced antimicrobial therapy strategies, enabling the possibility for successful infection eradication even in PJI with DTT pathogens and in patients with compromised bone stock and soft-tissue conditions.

In the case of fPJI, a three-stage revision, combining the advantages of a second thorough debridement with the benefits of an optimized systemic and local antimicrobial and antifungal therapy, shows promising results.

Conflict of interests

The authors declare there are no conflicts of interest.

References

- [1] Henkel TR, Boldt JG, Drobny TK, Munzinger UK. Total knee arthroplasty after formal knee fusion using unconstrained and semiconstrained components: a report of 7 cases. *J Arthroplasty* 2001;16(6):768–76.
- [2] Kuchinad R, Fourman MS, Fragomen AT, Rozbruch SR. Knee arthrodesis as limb salvage for complex failures of total knee arthroplasty. *J Arthroplasty* 2014;29(11):2150–5.

KEY POINTS

1. Prerequisites for patients to undergo conversion from arthrodesis to total knee arthroplasty are (1) sufficient extensor mechanism, (2) adequate soft-tissue coverage, and (3) compliance and realistic patient expectations.
2. A standardized but individually adapted surgical treatment concept in combination with a consistent antimicrobial and antifungal therapy is crucial for successful infection eradication.
3. Patients need to be treated preoperatively and post-operatively by a multidisciplinary team in specialized departments.

- [3] Wood JH, Conway JD. Advanced concepts in knee arthrodesis. *World J Orthop* 2015;6(2):202–10.
- [4] Cameron HU, Hu C. Results of total knee arthroplasty following takedown of formal knee fusion. *J Arthroplasty* 1996;11(6):732–7.
- [5] Cho SH, Jeong ST, Park HB, Hwang SC, Kim DH. Two-stage conversion of fused knee to total knee arthroplasty. *J Arthroplasty* 2008;23(3):476–9.
- [6] Clemens D, Lereim P, Holm I, Reikeras O. Conversion of knee fusion to total arthroplasty: complications in 8 patients. *Acta Orthop* 2005;76(3):370–4.
- [7] Kim YH, Kim JS, Cho SH. Total knee arthroplasty after spontaneous osseous ankylosis and takedown of formal knee fusion. *J Arthroplasty* 2000;15(4):453–60.
- [8] Kim YH, Oh SH, Kim JS. Conversion of a fused knee with use of a posterior stabilized total knee prosthesis. *J Bone Joint Surg Am* 2003;85(6):1047–50.
- [9] Jamshidi K, Hadi H, Ramezan M, Moslem A. Conversion of fused knee following distal femur tumor surgery to total knee arthroplasty. *Iran Red Crescent Med J* 2013;15(9):870–2.
- [10] Ruggieri P, Kasimatis G, Errani C, Bosco G, Mercuri M. Desarthrodesis and prosthetic reconstruction of the knee after resection of bone tumors. *J Surg Oncol* 2010;102(7):832–7.
- [11] Kernkamp WA, Verra WC, Pijls BG, Schoones JW, van der Linden HM, Nelissen RG. Conversion from knee arthrodesis to arthroplasty: systematic review. *Int Orthop* 2016;40(10):2069–74.
- [12] Brown TS, Petis SM, Osmon DR, et al. Periprosthetic joint infection with fungal pathogens. *J Arthroplasty* 2018;33(8):2605–12.
- [13] Theil C, Schmidt-Braekling T, Gosheger G, Idelevich EA, Moellenbeck B, Dieckmann R. Fungal prosthetic joint infection in total hip or knee arthroplasty: a retrospective single-centre study of 26 cases. *Bone Joint J* 2019;101-b(5):589–95.
- [14] Aalirezaie A, Bauer TW, Fayaz H, et al. Hip and knee section, diagnosis, reimplantation: proceedings of international consensus on orthopedic infections. *J Arthroplasty* 2019;34(2s):S369–79.
- [15] Parvizi J, Tan TL, Goswami K, et al. The 2018 definition of periprosthetic hip and knee infection: an evidence-based and validated criteria. *J Arthroplasty* 2018;33(5):1309–1314. e2.
- [16] Renz N, Perka C, Trampuz A. [Management of periprosthetic infections of the knee]. *Orthopade* 2016;45(1):65–71.
- [17] Izakovicova P, Borens O, Trampuz A. Periprosthetic joint infection: current concepts and outlook. *EFORT Open Rev* 2019;4(7):482–94.
- [18] Pfitzner T, Preininger B, von Roth P, Perka C. [A novel technique for a stable intramedullary fixation of static spacers in two-stage septic revision TKA with severe bone defects]. *Z Orthop Unfall* 2015;153(2):203–5.
- [19] Rohner E, Pfitzner T, Preininger B, Zippelius T, Perka C. Temporary arthrodesis using fixator rods in two-stage revision of septic knee prosthesis with severe bone and tissue defects. *Knee Surg Sports Traumatol Arthrosc* 2016;24(1):84–8.
- [20] Krenn V, Morawietz L, Perino G, et al. Revised histopathological consensus classification of joint implant related pathology. *Pathol Res Pract* 2014;210(12):779–86.
- [21] Diaz-Ledezma C, Higuera CA, Parvizi J. Success after treatment of periprosthetic joint infection: a Delphi-based international multidisciplinary consensus. *Clin Orthop Relat Res* 2013;471(7):2374–82.
- [22] Zimmerli W. [Orthopaedic implant-associated infections: update of antimicrobial therapy]. *Orthopade* 2015;44(12):961–6.
- [23] Zimmerli W, Trampuz A, Ochsner PE. Prosthetic-joint infections. *N Engl J Med* 2004;351(16):1645–54.
- [24] Zimmerli W, Moser C. Pathogenesis and treatment concepts of orthopaedic biofilm infections. *FEMS Immunol Med Microbiol* 2012;65(2):158–68.
- [25] Nace J, Siddiqi A, Talamo CT, Chen AF. Diagnosis and management of fungal periprosthetic joint infections. *J Am Acad Orthop Surg* 2019;27(18):e804–18.
- [26] Schoof B, Jakobs O, Schmid S, et al. Fungal periprosthetic joint infection of the hip: a systematic review. *Orthop Rev (Pavia)* 2015;7(1):5748.

- [27] Jauregui JJ, Buitrago CA, Pushilin SA, Browning BB, Mulchandani NB, Maheshwari AV. Conversion of a surgically arthrodesed knee to a total knee arthroplasty-is it Worth it? A meta-analysis. *J Arthroplasty* 2016;31(8):1736–41.
- [28] Angerame MR, Jennings JM, Holst DC, Dennis DA. Management of bone defects in revision total knee arthroplasty with use of a stepped, porous-coated metaphyseal sleeve. *JBS Essent Surg Tech* 2019;9(2):e14.
- [29] Abdel MP, Fuchs M, von Roth P. [Management of extensor mechanism injuries following total knee arthroplasty]. *Orthopade* 2016;45(1):47–53.
- [30] Abdel MP, Salib CG, Mara KC, Pagnano MW, Perry KI, Hanssen AD. Extensor mechanism reconstruction with use of Marlex mesh: a series study of 77 total knee Arthroplasties. *J Bone Joint Surg Am* 2018;100(15):1309–18.
- [31] Gottfriedsen TB, Schroder HM, Odgaard A. Knee arthrodesis after failure of knee arthroplasty: a nationwide register-based study. *J Bone Joint Surg Am* 2016;98(16):1370–7.
- [32] Ravikumar M, Kendoff D, Citak M, Luck S, Gehrke T, Zahar A. One stage conversion of an infected fused knee to total knee replacement - a surgical challenge. *Open Orthop J* 2013;7:67–71.