

# Hemiogenesis of thyroid with dual thyroid ectopia: A rare case report

Pankaj S Jha, Varsha Rote-Kaginalkar, Prashant Titare, Manoj B Jadhav

Department of Radiodiagnosis, Govt Medical College and Hospital, Aurangabad, Maharashtra, India

**Correspondence:** Dr. Pankaj S Jha, Department of Radiodiagnosis, Govt Medical College and Hospital, Aurangabad - 431 001, Maharashtra, India. E-mail: pankaj.jha201289@gmail.com

## Abstract

Developmental defects of the thyroid gland are very rare. The common developmental abnormalities are ectopic thyroid, hemiogenesis and agenesis of thyroid gland. These developmental defects may or may not be associated with deranged thyroid function tests. Ultrasonography (USG) is the initial modality of choice for thyroid hemiogenesis but further evaluation by computed tomography (CT) scan or nuclear scan should be done to look for ectopic thyroid tissue rest. Here, we report a rare case of a 9-year-old female having hemiogenesis of the right thyroid lobe and isthmus along with dual ectopic thyroid tissue at prehyoid and infrahyoid regions of the neck presenting as a midline neck swelling and subclinical hypothyroidism.

**Key words:** Ectopic thyroid; subclinical hypothyroidism; thyroid hemiogenesis

## Introduction

Embryological development of the thyroid gland begins from median diverticulum, an endodermal thickening, in the floor of pharynx. It grows caudally as bifurcating tubular ducts to form the lateral lobes and isthmus. Congenital thyroid anomalies may result due to abnormal gland descent, defective organogenesis, incomplete genesis of a lobe with or without ectopic thyroid tissue.<sup>[1]</sup>

Developmental abnormalities of the thyroid gland can be divided into three major groups: agenesis of thyroid gland; dysgenesis of thyroid gland; and abnormalities due to persistence of the thyroglossal duct. Dysgenesis can be in the form of hemiogenesis of the thyroid or as an ectopic thyroid.

Thyroid hemiogenesis is a rare congenital anomaly of thyroid in which one thyroid lobe fails to develop, with or without agenesis of isthmus. The estimated prevalence rate of thyroid

hemiogenesis is 0.05–0.2%. The left lobe of thyroid gland is not formed in approximately 80% of the cases. The isthmus is absent in approximately half of the cases of thyroid hemiogenesis.<sup>[2]</sup> Ectopic thyroid tissue is an entity that is characterized by the presence of thyroid tissue in locations other than its usual pretracheal location. Dual thyroid ectopia is the presence of thyroid gland tissue in two different abnormal locations. It is rare with incidence ranging from one in 50,000 to 70,000.<sup>[3]</sup> It is very uncommon to find both thyroid hemiogenesis and dual thyroid ectopia in an individual.

Here, we report a patient having both the above mentioned congenital abnormalities. To our knowledge, only one similar case report has been reported in the world literature.

## Case Report

A 9-year-old girl presented to our service with a midline neck swelling in the infrahyoid location for

This is an open access journal, and articles are distributed under the terms of the Creative Commons Attribution-NonCommercial-ShareAlike 4.0 License, which allows others to remix, tweak, and build upon the work non-commercially, as long as appropriate credit is given and the new creations are licensed under the identical terms.

**For reprints contact:** reprints@medknow.com

**Cite this article as:** Jha PS, Rote-Kaginalkar V, Titare P, Jadhav MB. Hemiogenesis of thyroid with dual thyroid ectopia: A rare case report. Indian J Radiol Imaging 2018;28:14-7.

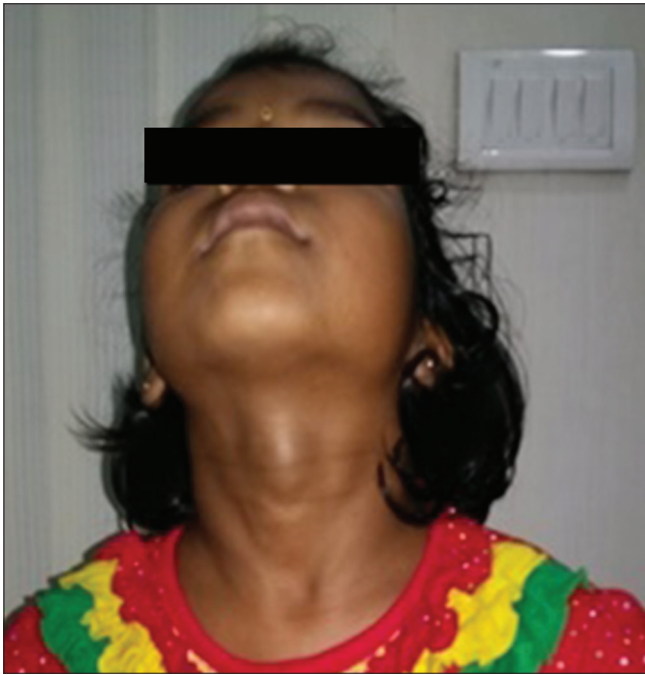### Access this article online

#### Quick Response Code:



**Website:**  
www.ijri.org

**DOI:**  
10.4103/ijri.IJRI\_292\_17

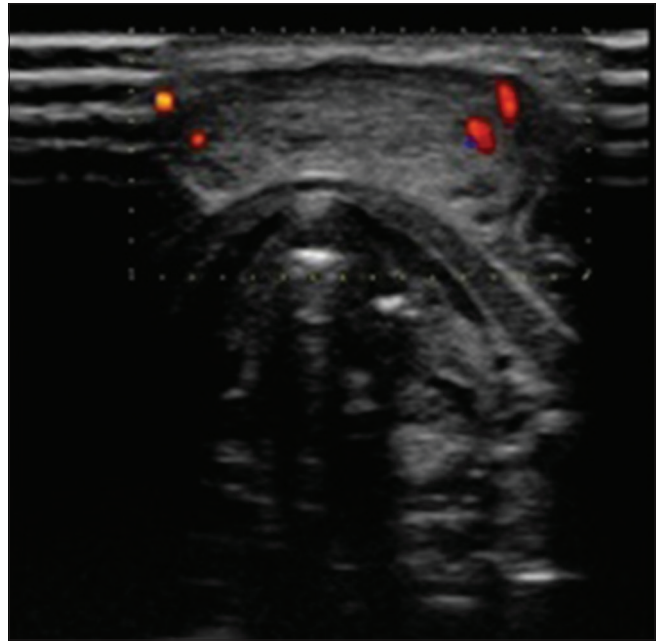


**Figure 1:** Clinical photograph of patient showing midline neck swelling below hyoid and above the level of normal thyroid gland

3 years [Figure 1]. The swelling was painless, and gradually increasing in size. Clinical examination of the neck was done which showed a soft swelling in the midline neck just below the hyoid bone which moved freely with deglutition. The systemic examinations revealed no significant abnormality. Thyroid function test was done which showed elevated TSH (9.2 mIU/L) and normal free T4 (1.2 ng/ml). It was in keeping with subclinical hypothyroidism. Then the patient was subjected to further radiological evaluation.

Ultrasonography (USG) of the neck revealed absent isthmus and right lobe of thyroid in thyroid fossa. The left lobe of thyroid was present in its usual location measuring 1.4 × 1.1 × 1 cm (small in size) with inhomogeneous hyperechoic echotexture. A well-defined homogeneous tissue with internal vascularity was seen anterior to thyroid cartilage in midline corresponding to clinically palpable neck swelling [Figure 2], suggesting the possibility of undescended remnant thyroid tissue.

CT neck was performed which confirmed the USG findings and revealed additional findings. On plain study, there were two well-defined hyperdense ectopic foci of thyroid tissue, one in infrahyoid location along the course of thyroglossal duct (measuring 2.3 × 1.5 × 1.3 cm) and other at prehyoid location (measuring 5.5 × 4 mm). On contrast study, there was marked homogeneous enhancement in ectopic tissues while the normally located left thyroid lobe was relatively less enhancing [Figures 3 and 4]. There was no evidence of calcifications, cystic, or nodular components within the ectopic or orthotopic thyroid tissue.



**Figure 2:** Transverse USG neck image showing echogenic ectopic thyroid with internal vascularity anterior to larynx

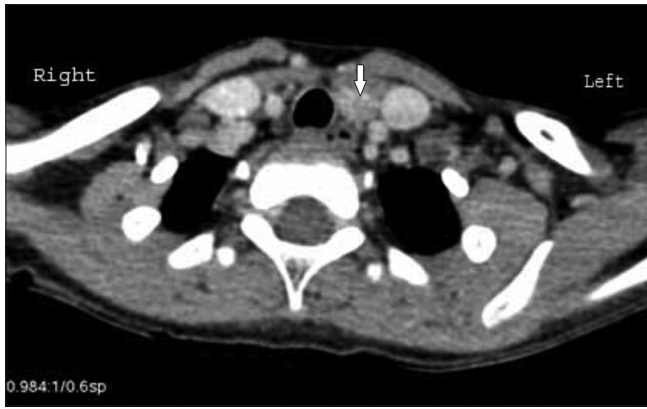
99m Tc pertechnetate thyroid nuclear scan [Figure 5] revealed the functioning two ectopic thyroid tissues corresponding to their locations on the CT scan. There was no uptake in normal location of thyroid gland which confirmed that the left thyroid lobe was nonfunctioning.

A final diagnosis of right thyroid hemiagenesis with nonfunctioning left thyroid lobe and functioning dual thyroid ectopia in prehyoid and infrahyoid locations was made. The patient was started on thyroxine 25mcg daily.

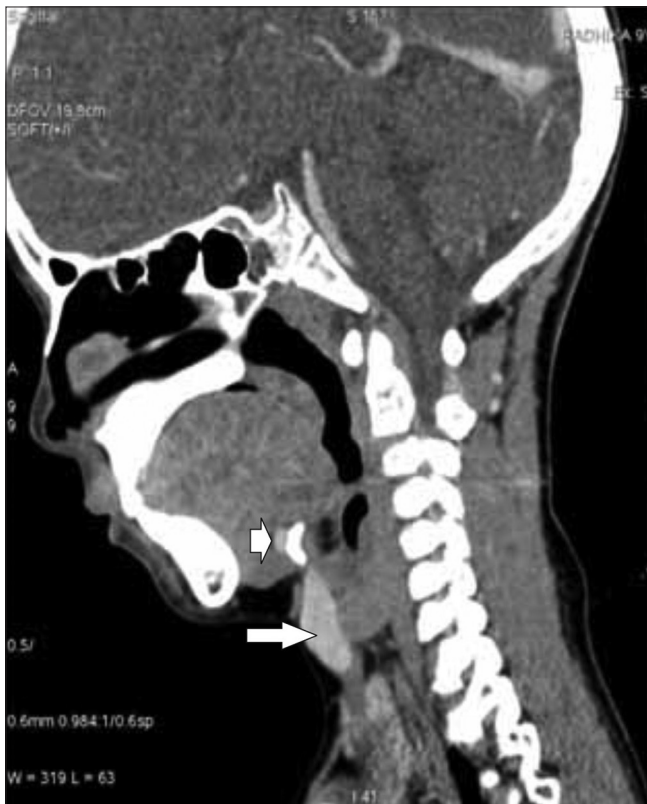
### Discussion

The thyroid gland is the first endocrine gland to develop in an embryo around 4–5 weeks of gestation. It descends from the posterior dorsal midline of tongue to the region in front of the second to fourth tracheal rings in neck. Anomalies of descent lead to ectopic thyroid tissue, which may be found anywhere along thyroglossal duct. The most common ectopic thyroid is lingual thyroid. It has also been reported at other ectopic midline locations of the neck near the hyoid bone, larynx and trachea, mediastinum, and esophagus. The pathogenesis of ectopic thyroid tissue is unclear. Genetic defects including mutation in the paired box transcription factor PAX8, and the thyroid transcription factors TTF1 and TTF2 have been implicated.<sup>[4]</sup>


It is very rare to have two ectopic foci of thyroid tissue simultaneously and only 19 cases of dual ectopia with no normal thyroid have been reported in world literature. It is more common in females with a female: male ratio of 1.25:1. In most cases, the first ectopic focus is lingual or sublingual and the second is infrahyoid or suprahyoid.



**Figure 3:** Axial CT neck image showing normally located left lobe of thyroid (arrow) with non-visualisation of isthmus and right lobe



**Figure 4:** Sagittal CT neck image showing two enhancing ectopic thyroid tissue in prehyoid (arrowhead) and infrahyoid (arrow) locations in midline neck



**Figure 5:** 99m Tc pertechnetate thyroid scan shows two focal areas of radiotracer uptake in midline neck with no evidence of uptake in normal thyroid bed

In terms of thyroid function, about half of the patients are euthyroid and the rest are hypothyroid. All diseases capable

of affecting the normal thyroid can affect ectopic thyroid such as the adenoma, hyperplasia, inflammation, and rarely malignancy.<sup>[5]</sup>

Thyroid hemiogenesis is a congenital abnormality in which one thyroid lobe fails to develop with or without absence of isthmus. Many times, it is an incidental finding. Coexisting thyroid disorders that have been reported in the remnant thyroid lobe include hyperthyroidism, hypothyroidism, multinodular goiter, chronic thyroiditis, adenocarcinoma, and papillary thyroid carcinoma which renders the normal thyroid lobe nonfunctioning. Thyroid function is abnormal in 38–47% of the patients.<sup>[6]</sup>

In the present case, the isthmus and right lobe of thyroid was not seen in their usual location in the neck, consistent with right thyroid hemiogenesis. The normally located left thyroid lobe was nonfunctioning. Two functioning ectopic thyroid tissues were noted in prehyoid and infrahyoid regions of neck in midline. In a similar study by Velayutham *et al.* in 2013,<sup>[7]</sup> there was hemiogenesis of right lobe along with double ectopic thyroid tissue at suprahyoid and infrahyoid regions, however, the left lobe of thyroid was normally functioning in their study.

Radiological imaging modalities, such as USG, CT scan, and MRI help in establishing the diagnosis.

Thyroid scintigraphy is complementary in confirming the location and function of ectopic thyroid tissue; however, it could be misleading sometimes as pathologies in thyroid tissue render it nonfunctioning. Therefore, scintigraphy findings should be correlated with findings of ultrasonography and cross-sectional imaging.

There is no consensus about the optimal management strategy of this rare entity. Surgery is the treatment of choice in symptomatic cases. For completely asymptomatic and euthyroid cases, regular follow-up is recommended to detect development of complications. For mild symptoms of hypothyroidism, levothyroxine replacement therapy is effective.<sup>[8]</sup> Our patient is on regular follow-up since last 4 months. She was started on thyroxine pharmacotherapy, the swelling was reduced, and patient is euthyroid at present.

## Conclusion

We report this rare case of right thyroid hemiogenesis with nonfunctioning, normally located left thyroid lobe and dual thyroid ectopia. To our knowledge, only one such case has been reported in world literature till now.

## Declaration of patient consent

The authors certify that they have obtained all appropriate patient consent forms. In the form the patient(s) has/have

given his/her/their consent for his/her/their images and other clinical information to be reported in the journal. The patients understand that their names and initials will not be published and due efforts will be made to conceal their identity, but anonymity cannot be guaranteed.

#### Financial support and sponsorship

Nil.

#### Conflicts of interest

There are no conflicts of interest.

#### References

1. O'Rahilly R. The timing and sequence of events in the development of the human endocrine system during the embryonic period proper. *Anat Embryol (Berl)* 1983;166:439-51.
2. Kocakusak A, Akinci M, Arıkan S, Sunar H, Yucel A, Senturk O. Left thyroid lobe hemiogenesis with hyperthyroidism: Report of a case. *Surg Today* 2004;34:437-9.
3. Runge SW, Vaucher SS, Lambert R, Turpin S, Van Vliet G, Deladoëy J. A high prevalence of dual thyroid ectopy in congenital hypothyroidism. *J Clin Endocrinol Metab* 2012;97:E978-81.
4. Sood A, Kumar R. The ectopic thyroid gland and the role of nuclear medicine techniques in its diagnosis and management. *Hell J Nucl Med* 2008;11:168-71.
5. Baik SH, Choi JH, Lee HM. Dual ectopic thyroid. *Eur Arch Otorhinolaryngol* 2002;259:105-7.
6. Ruchala M, Szczepanek E, Szaflarski W, Moczko J, Czarnywojtek A, Pietz L, *et al.* Increased risk of thyroid pathology in patients with thyroid hemiogenesis: Results of a large cohort case-control study. *Eur J Endocrinol* 2010;162:153-60.
7. Velayutham K, Mahadevan S, Velayutham L, Jayapaul M, Appakalai B, Kannan A. A case of hemiogenesis of thyroid with double ectopic thyroid tissue. *Indian J Endocrinol Metab* 2013;17:756-8.
8. Noussios G, Anagnostis P, Goulis DG, Lappas D, Natsis K. Ectopic thyroid tissue: Anatomical, clinical, and surgical implications of a rare entity. *Eur J Endocrinol* 2011;165:375-82.