



Leriche Syndrome with Digital Gangrene: Is Aortic Bypass Grafting Safe in Intravenous Drug Abusers? A Case Report and Literature Review

Syed Muhammad Hammad Ali, Ossama Ather, and Aasim Malik

Department of Surgery, Fatima Memorial Hospital College of Medicine & Dentistry, Lahore, Pakistan

A 47-year-old male with Leriche syndrome presented with digital gangrene due to TASC II type-D occlusion of the distal aorta and common iliac arteries. Open revascularization was performed using a Dacron aorto-biiliac bypass graft; however, the postoperative course revealed a nondisclosed history of intravenous opioid abuse as he went into withdrawal psychosis. Our report highlights ways to mitigate infection risk associated with prosthetic aortic grafts in suspected or confirmed intravenous drug abusers. The literature review suggests alternative strategies like aortoiliac endarterectomy, total endovascular approach using non-covered stents, or a hybrid approach. The primary use of autologous venous grafts should be considered as a last resort so that the veins are retained for future use in case of graft infection. Patient factors like comorbidities, fitness to undergo surgery, anatomical extent of occlusion, and availability of facilities/expertise can further guide the management plan owing to a lack of evidence-based guidelines.

Key Words: Leriche syndrome, Intravenous substance abuse, Vascular grafting, Prosthesis-related infections, Chronic limb-threatening ischemia

Received October 26, 2021

Revised January 3, 2022

Accepted March 10, 2022

Published on March 31, 2022

Corresponding author:

Syed Muhammad Hammad Ali

Department of Surgery, Fatima Memorial Hospital, Shadman, Lahore 54000, Pakistan

Tel: 92-42-111-555-600 (Ext. 385)

Fax: 92-42-3742-1993

E-mail: hali921@hotmail.com

<https://orcid.org/0000-0002-7770-0297>

Copyright © 2022 The Korean Society for Vascular Surgery

This is an Open Access article distributed under the terms of the Creative Commons Attribution Non-Commercial License (<http://creativecommons.org/licenses/by-nc/4.0>) which permits unrestricted non-commercial use, distribution, and reproduction in any medium, provided the original work is properly cited.

Cite this article; Vasc Specialist Int 2022. <https://doi.org/10.5758/vsi.210072>

INTRODUCTION

Leriche syndrome is a classic presentation of aortoiliac occlusive disease (AIOD) in males with a triad of buttock or thigh claudication, erectile dysfunction, and the absence of palpable femoral pulses [1]. This signifies occlusion of the abdominal aorta near its bifurcation, with extension into the iliac system. Management depends on the anatomic location and extent of the disease, as well as certain patient factors. Known revascularization strategies include endovascular intervention and open surgical repair via endarterectomy or bypass grafting. However, placement of a prosthetic graft in the abdomen, pelvis, or groin carries the risk of catastrophic graft infection, particularly in the case of intravenous (IV) drug abusers, with a significant increase in morbidity and mortality [2,3]. Likewise, the introduction

of bacteria into the bloodstream through inadvertent arterial cannulation or repeated venipuncture under nonsterile settings in IV drug abuse can also infect the endovascular material [4]. Although the overall reported incidence of prosthetic material infection in AIOD is low (<1%-3%), the incidence secondary to IV drug abuse is unknown [5].

We report the case of a patient with Leriche syndrome who presented with digital gangrene of the foot. He underwent aortic bypass grafting but was found to have a previously unknown history of regular IV opioid abuse as his postoperative stay precipitated withdrawal symptoms. This case brings an important question into the discussion as to what the optimal course of action should be in patients known beforehand to be IV opioid addicts who develop AIOD with chronic limb-threatening ischemia.

To the best of our knowledge, no evidence-based recom-

recommendations are available in the literature that can guide the management of chronic limb-threatening AIOD in IV drug abusers. Therefore, this case warrants a thorough literature review to explore the indications, efficacy, and outcomes of different treatment modalities for AIOD with chronic limb-threatening ischemia, particularly in the context of increased risk of prosthetic material infection.

Informed consent was obtained from the patient for publication of this case report and accompanying images. Ethical approval was granted by the institutional review board of Fatima Memorial Hospital College of Medicine & Dentistry (no. FMH-2/03/2022-IRB-1018).

CASE

A 47-year-old male with a history of long-standing type 1 diabetes mellitus (T1DM) for the past 30 years and a 40-pack-year smoking history presented with progressive painless black discoloration of the lateral two toes of his right foot and one-week history of fever. He also experienced intermittent fatigue and pain on exertion involving both buttocks and thighs. The patient also complained of erectile dysfunction for a year. Physical examination revealed gangrene involving the dorsum of the right fourth and fifth toes, with drainage of pus. Right lower extremity pulses were weak, and the right dorsalis pedis pulse was impalpable. The patient had a fever of 37.8°C. Baseline laboratory test results were normal, except for leukocytosis (12,960/ μ L).

IV heparin and empiric antibiotic therapy were initiated after wound culture, which was positive for *Proteus mirabilis*, and the antibiotics were replaced with definitive therapy

based on sensitivity. Computed tomography angiography revealed absence of flow in the lower abdominal aorta starting just below the origin of the inferior mesenteric artery (IMA) and in both common iliac arteries (CIAs); consistent with distal aortic and bilateral iliac artery occlusion (Fig. 1). To reestablish the blood flow and to save the patient's foot, surgical intervention with aortic bypass grafting was planned after the patient underwent preoperative work-up to assess perioperative risk.

The abdominal aorta was exposed through a midline incision. After clamping the aorta just above the IMA, vertical aortotomy was performed, followed by endarterectomy. A Dacron graft was used as the bypass conduit which was sutured proximally to the aorta and distally to the CIA on the left and external iliac artery (EIA) on the right side via end-to-side anastomosis (Fig. 2). The intraoperative course was uneventful, and successful revascularization of the right foot was confirmed by a normal postoperative dorsalis pedis pulse.

However, the patient became delirious with psychosis during his surgical intensive care unit (ICU) stay on postoperative day 2. The patient experienced visual hallucinations, irrelevant speech, physically aggressive behavior, restlessness, and disorientation. Further diagnostic workup, including brain CT, serum electrolytes, and blood counts, was unremarkable. Cerebrospinal fluid analysis, Gram stain, and culture were also normal except for elevated levels of proteins (67.3 mg/dL) and glucose (10.2 mmol/L). Neuropsychiatric consultation was sought, and a diagnosis of drug withdrawal psychosis was established after the patient's family admitted regular use of IV opioids by the patient. After postoperative surgical recovery was complete, the

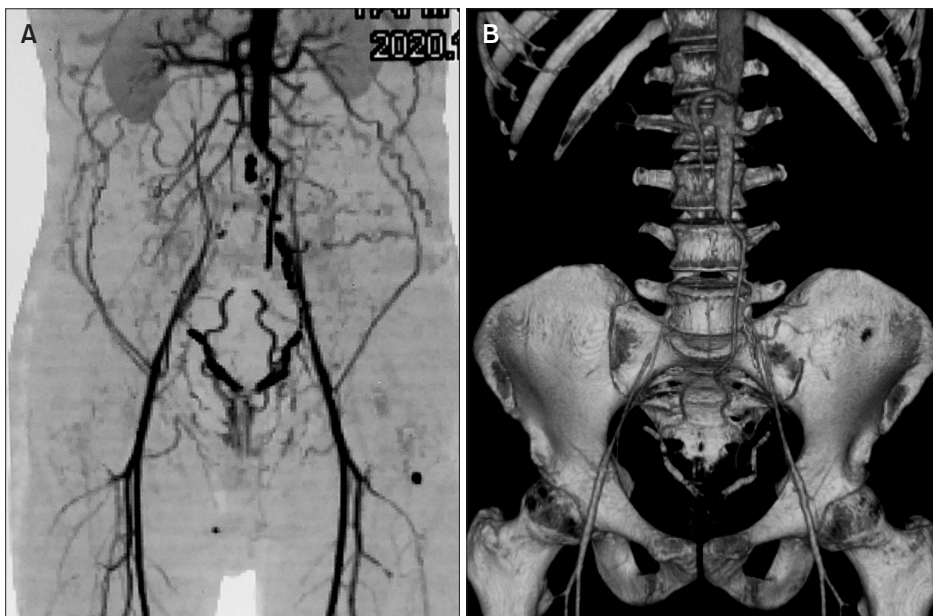


Fig. 1. (A) Preoperative computed tomography angiography (CTA) showed extensive occlusion of the distal aorta and both common iliac arteries. The collaterals were filling the external iliac arteries on both sides. (B) A 3-dimensional reconstructed CTA showed the aortoiliac occlusion.

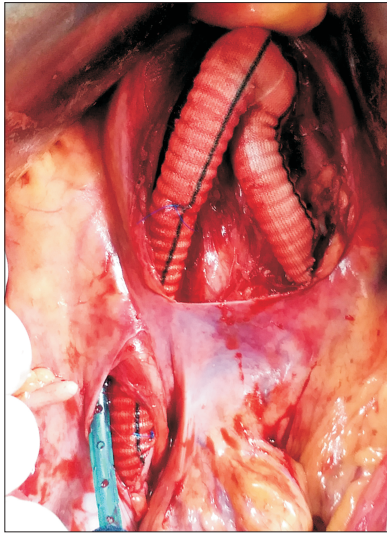


Fig. 2. Intraoperative picture showed the aorto-biiliac Dacron graft in the retroperitoneum with the right limb tunneled behind the base of mesentery. A retroperitoneal drain was seen along the graft.

patient was transferred to the medical ICU under the care of neuropsychiatry, where he was managed for two weeks until discharge. The patient was commenced on a rehabilitation program after extensive counseling about the disastrous outcomes of graft infection following further IV drug abuse. We prolonged the postoperative antibiotic course to six weeks, considering his prolonged hospital stay and risk factors. Additionally, the patient was thoroughly counseled on the critical risks of future IV drug abuse. A follow-up visit after 1 year showed complete patency of the graft along with resolution of his digital gangrene and claudication symptoms with abstinence from IV drug use confirmed by regular urine screening. The patient was keeping well on maintenance antipsychotic therapy.

DISCUSSION

AIOD involves atheromatous plaque formation in the infrarenal segment of the abdominal aorta extending into the iliac arteries. René Leriche, a French surgeon, first noted and described a unique presentation of AIOD in males with symptoms of claudication, impotence, and absence of peripheral pulses in the lower extremities [1]. This constellation of symptoms, known as Leriche syndrome, signifies aortic occlusion at its bifurcation, which is a common site of blood flow turbulence, leading to shear stress and intimal injury.

The exact prevalence of AIOD is unknown, as many patients are often asymptomatic because of the development of collaterals over time. However, hypertension, smoking,

diabetes mellitus, dyslipidemia, advanced age, and male sex are the most common predisposing factors [6]. Measurement of bedside ankle-brachial pressure index and physiological testing with pulse volume recording and Doppler waveform can serve as useful screening tools, although imaging with CT or magnetic resonance angiography is required to determine the extent of disease involvement. Two classification systems of AIOD are commonly used: one is based on the anatomical location of occlusion (type I to IV), and the other, known as Trans-Atlantic Inter-Society Consensus II (TASC II), classifies the disease based on the severity of occlusion (type A to D).

Definitive treatment involves restoration of blood flow by endovascular intervention or open surgical repair, such as aortoiliac endarterectomy or bypass grafting. The choice of procedure depends mainly on the extent of occlusive disease, and individual risk factors for surgery. However, the reduced availability of expertise and equipment, particularly in developing countries, can also limit the choice of therapy. In general, according to the TASC II recommendations, endovascular intervention is the preferred treatment option for type A and B lesions, while more complex lesions such as type C and D, are preferably managed by open surgical repair [7].

Open surgical bypass grafting uses a prosthetic conduit with a primary patency rate of approximately 80% (Fig. 3). Dacron and polytetrafluoroethylene (PTFE) are the two most commonly used synthetic grafts, with no evidence of one being superior to the other in terms of graft infection risk [8]. In contrast, endarterectomy involves the surgical removal of occluding atheromatous plaques after separation from the vessel wall. Lesions involving the aorta and CIAs can be easily managed with direct endarterectomy; however, lesions involving the EIA may require extensive eversion endarterectomy. Even though endarterectomy is largely obsolete after the widespread adoption of simpler bypass grafting, it still has comparably high long-term patency rates and outcomes in AIOD compared with bypass grafting [9,10]. Moreover, endarterectomy provides better resolution of impotence in patients with Leriche syndrome, as the plaque occluding the origin of the internal iliac arteries can be easily visualized, accessed, and removed. Hence, it can be considered a safe alternative to bypass or endovascular stenting in certain conditions, especially when the risk of graft infection is high. Complications of endarterectomy include prolonged operative time, excessive blood loss, and aneurysm formation in vessels with underlying pathology.

Endovascular treatment of AIOD involves angioplasty (intraluminal or subintimal), with or without stents or stent grafts. Percutaneous reintervention is always possible, and secondary patency rates are similar to those of open

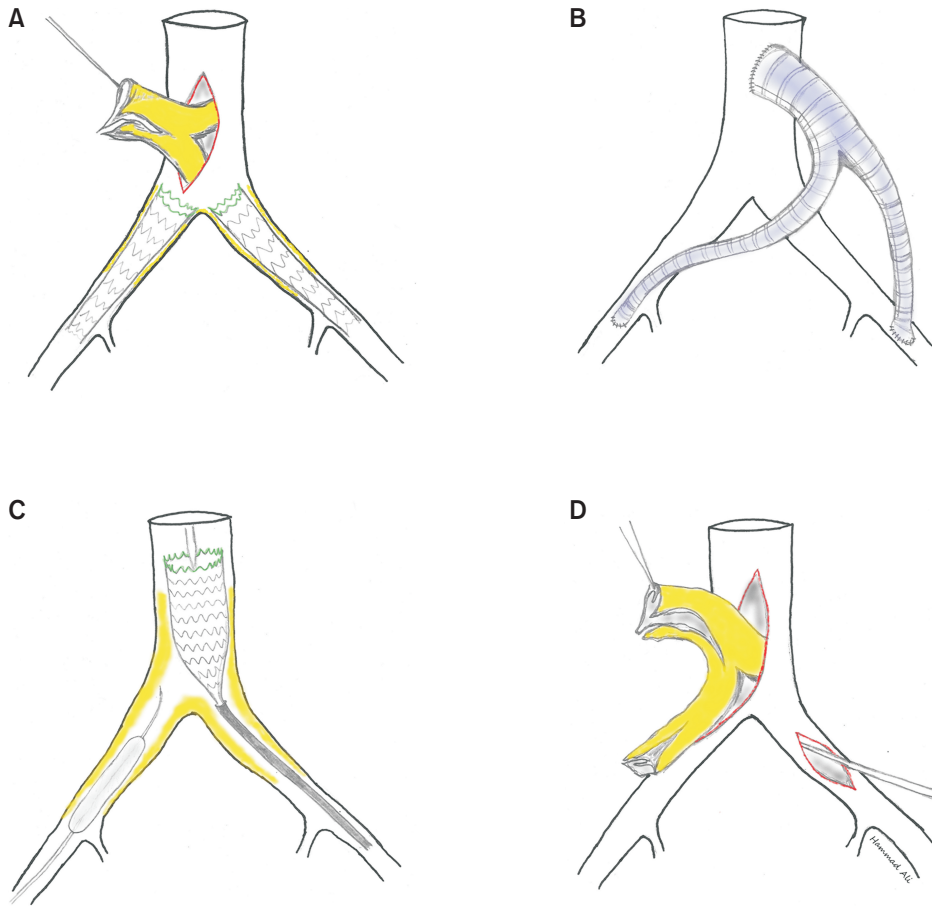


Fig. 3. Illustrations show various reconstruction methods for aortoiliac occlusive disease. (A) A hybrid surgery of aortic endarterectomy followed by bilateral iliac stenting. (B) Aorto-biiliac bypass graft with a prosthetic conduit. (C) A total endovascular revascularization with balloon angioplasty and stenting. (D) Aortoiliac endarterectomy.

surgical repair [11]. Moreover, recent studies have shown comparable outcomes between surgical bypass and endovascular intervention, even for more extensive lesions (TASC II types C and D), provided these were performed by expert interventionalists in high-volume centers [12,13]. Intraluminal stents can be bare-metal or covered, and the latter are covered with synthetic materials such as PTFE, which isolates the lumen of the stent from the atherogenic vascular intima. Covered stents are more commonly used in complex lesions, such as TASC II types C and D, with improved outcomes. However, there is no conclusive evidence of the superiority of one type of stent over another [14]. Additionally, stent configuration around the aortic bifurcation has been debated recently. The kissing stent configuration uses two separate limbs of expandable stents in both iliac arteries, which extend into the aortic lumen. In contrast, covered endovascular reconstruction of the aortic bifurcation (CERAB) is more anatomically and physiologically oriented to the original aortic bifurcation. CERAB utilizes three covered balloon-expandable stents, with a single wide stent in the distal aorta and two separate stents in both iliac arteries extending to the aorta to minimize turbulence. CERAB showed promising results in complex AIOD compared with

kissing stents [15]. However, CERAB still uses a prosthetic graft and incurs higher costs; it may not be an alternative to open bypass for IV abusers, especially in developing countries. Another hurdle for endovascular treatment of AIOD is heavily calcified plaques resistant to balloon expansion.

Aortic grafts, independent of the route of placement, (i.e., endovascular or open approach) are prone to infections with an incidence rate of approximately 1% [5]. Despite the low incidence rates, if infected, the outcome is catastrophic with increased morbidity and mortality, and requires aggressive management with explantation of the infected aortic graft, revascularization using extra-anatomic bypass or in situ reconstruction using autologous tissue, allograft, or antibiotic-impregnated grafts, and long-term antibiotic administration [2]. Thirty-day mortality in patients with aortic endograft infections can reach up to 17%, whereas in-hospital mortality rates of aortic prosthetic grafts are reported to be up to 20% [16]. IV drug abusers are particularly at risk of such infections [3]. First, repeated use of IV injections under nonsterile conditions can introduce and disseminate infection into the bloodstream. The most commonly implicated organisms are gram-positive cocci,

including *Staphylococcus aureus* and *Streptococcus* spp. Other organisms such as *Escherichia coli*, anaerobes, and *Candida* spp. can also infect the grafts. Second, aortic bypass grafts, especially in the aorto-bifemoral type of configuration, are usually tunnelled into the groin. Injected drug abusers frequently use the groin when other injection sites are exhausted. Foreign bodies, such as grafts or stents, provide a potential surface for bacterial pathogens to adhere to and establish the infection nidus. Once set in, graft infection can manifest as either acute (high-grade fever, sepsis, and abdominal pain) or chronic (draining sinuses and fistulas) symptoms. Once infected, reconstruction of the aortic system with a new graft remains the mainstay of management in addition to long-term antibiotics. Grafts impregnated with antibiotics (e.g., rifampicin), silver-coated, or cryopreserved grafts are commonly used for aortic graft infections following explantation; however, their prophylactic use in case of risk factors such as IV drug abuse remains undocumented [17].

Kanka et al. [18] described a hybrid technique to avoid prosthetic material placement in the groin of a known IV drug abuser. The authors combined open aortic and femoral endarterectomy along with the deployment of covered stents in both iliac arteries.

Autologous femoral vein grafts may also be used, precluding prosthetic graft material, and have high patency rates [19]. Nevertheless, data for the primary management of AIOD are scarce, as autologous grafting is largely employed for the reconstruction of explanted infected grafts. This is because harvesting autologous veins and reconstructing the neo-aortoiliac system is a long-drawn-out procedure, and patients can experience postoperative limb edema. It should be a last resort in the management of AIOD in young patients, as the femoral veins can be used for future revascularization in infected grafts. In our case, the patient had type D TASC-II aortoiliac occlusion with critical limb ischemia that warranted a timely revascularization strategy, given that the infrainguinal runoff was satisfactory. The absence of surgical risk factors and the presence of occlusion in the distal aorta and CIA (sparing the external iliac arteries) would have made him a good candidate for alternate open surgical repair via endarterectomy if the history of regular injection drug abuse was known. Although antibiotic prophylaxis beyond 24 hours is not recommended, we prolonged the postoperative antibiotic course to 6 weeks given the fact that the patient had a prolonged hospital stay for 3 weeks and several risk factors such as T1DM, incision near the groin, and ICU admission [20]. In addition, risk of graft infection through hematogenous spread is highest in the first 2 months postoperatively; we decided to extend the antibiotic cover to allow complete

wound healing and for rehabilitative therapy to take effect.

In cases where prosthetic graft placement is inevitable, patients should be counseled about life-threatening complications and detrimental outcomes of aortic bypass graft infection with ongoing IV drug abuse. Cognitive behavioral therapy and rehabilitation programs may also prove beneficial in this regard. Such patients are usually immunocompromised due to IV drug use-related co-infections, such as HIV and hepatitis B and C, which can worsen graft infections. Screening for these diseases must also be performed during the initial visits. This case report highlights the need for large-scale studies on the safety and outcomes of revascularization strategies and devising management algorithms for patients actively using IV drugs who develop symptomatic aortoiliac occlusion.

FUNDING

None.

CONFLICTS OF INTEREST

The authors have nothing to disclose.

ORCID

Syed Muhammad Hammad Ali

<https://orcid.org/0000-0002-7770-0297>

Ossama Ather

<https://orcid.org/0000-0003-2946-6026>

Aasim Malik

<https://orcid.org/0000-0001-8344-4691>

AUTHOR CONTRIBUTIONS

Concept and design: AM, SMHA. Analysis and interpretation: OA, SMHA. Data collection: none. Writing the article: OA, AM. Critical revision of the article: all authors. Final approval of the article: all authors. Statistical analysis: none. Obtained funding: none. Overall responsibility: SMHA.

REFERENCES

- 1) Brunicaudi FC, Andersen DK, Billiar TR, Dunn DL, Hunter JG, Kao LS, et al. *Schwartz's principles of surgery*. 11th ed. New York: McGraw-Hill; 2019.
- 2) Kilic A, Arnaoutakis DJ, Reifsnnyder T, Black JH 3rd, Abularrage CJ, Perler BA, et al. Management of infected vascular grafts. *Vasc Med* 2016;21:53-60.
- 3) Li K, Beckerman WE, Luo X, Peng HW, Chen KQ, He CG. Graft infection after prosthetic bypass surgery for infectious femoral artery pseudoaneurysm in intravenous drug users: manifestation, management, and prognosis. *Ann Vasc Surg* 2021;70:449-458.
- 4) Buora A, Floriani M, Gabrielli L. Extra-anatomic autologous reconstruction with hepatic-iliac artery bypass graft for aortic endograft infection. *J Vasc Surg* 2015;61:237-239.
- 5) Shiraev T, Barrett S, Heywood S, Mirza W, Hunter-Dickson M, Bradshaw C, et al. Incidence, management, and outcomes of aortic graft infection. *Ann Vasc Surg* 2019;59:73-83.
- 6) Diehm C, Schuster A, Allenberg JR, Darius H, Haberl R, Lange S, et al. High prevalence of peripheral arterial disease and co-morbidity in 6880 primary care patients: cross-sectional study. *Atherosclerosis* 2004;172:95-105.
- 7) Norgren L, Hiatt WR, Dormandy JA, Nehler MR, Harris KA, Fowkes FG. Inter-society consensus for the management of peripheral arterial disease (TASC II). *J Vasc Surg* 2007;45 Suppl S:S5-S67.
- 8) Roll S, Müller-Nordhorn J, Keil T, Scholz H, Eidt D, Greiner W, et al. Dacron vs. PTFE as bypass materials in peripheral vascular surgery—systematic review and meta-analysis. *BMC Surg* 2008;8:22.
- 9) Manunga J, Mirza A, Skeik N, Stanberry L, Jayarajan S, Sullivan TM. Comparative long-term outcomes of patients with aortoiliac occlusive disease limited to common iliac arteries who underwent endarterectomy versus bypass grafting. *Ann Vasc Surg* 2020;68:1-7.
- 10) Theriot JM, Feldman ZM, Korayem AH, Chander RK, Finlay DJ. Minimally invasive aortobiiliiofemoral endarterectomy for aortoiliac occlusive disease is a compelling alternative to bypass. *Vasc Endovascular Surg* 2019;53:97-103.
- 11) Jongkind V, Akkersdijk GJ, Yeung KK, Wisselink W. A systematic review of endovascular treatment of extensive aortoiliac occlusive disease. *J Vasc Surg* 2010;52:1376-1383.
- 12) Piffaretti G, Fargion AT, Dorigo W, Pulli R, Gattuso A, Bush RL, et al. Outcomes from the multicenter Italian registry on primary endovascular treatment of aortoiliac occlusive disease. *J Endovasc Ther* 2019;26:623-632.
- 13) Rocha-Neves J, Ferreira A, Sousa J, Pereira-Neves A, Vidoedo J, Alves H, et al. Endovascular approach versus aortobifemoral bypass grafting: outcomes in extensive aortoiliac occlusive disease. *Vasc Endovascular Surg* 2020;54:102-110.
- 14) Hajibandeh S, Hajibandeh S, Antoniou SA, Torella F, Antoniou GA. Covered vs uncovered stents for aortoiliac and femoropopliteal arterial disease: a systematic review and meta-analysis. *J Endovasc Ther* 2016;23:442-452.
- 15) Reijnen MM. Update on covered endovascular reconstruction of the aortic bifurcation. *Vascular* 2020;28:225-232.
- 16) Li HL, Chan YC, Cheng SW. Current evidence on management of aortic stent-graft infection: a systematic review and meta-analysis. *Ann Vasc Surg* 2018;51:306-313.
- 17) Filiberto AC, Scali ST, Patterson S, Neal D, Elder CT, Shah SK, et al. Treatment and outcomes of aortic graft infections using a decision algorithm. *Ann Vasc Surg* 2021;76:254-268.
- 18) Kanka KC, Pak JJ, Hadley D, Alexander JQ. Hybrid aortoiliac revascularization to avoid nonautogenous groin reconstruction in an intravenous drug abuser. *Ann Vasc Surg* 2011;25:387.e11-387.e14.
- 19) Pallister ZS, Chung J. Femoral vein reconstruction for aortic infections. *Vasc Specialist Int* 2021;37:4-13.
- 20) Wilson WR, Bower TC, Creager MA, Amin-Hanjani S, O'Gara PT, Lockhart PB, et al. Vascular graft infections, mycotic aneurysms, and endovascular infections: a scientific statement from the American Heart Association. *Circulation* 2016;134:e412-e460.