

VATS sleeve resections

VATS sleeve rezeksiyonlar

Arkin Acar¹ , Kenan Can Ceylan² 

Institution where the research was done:

SBÜ İzmir Dr. Suat Seren Chest Diseases and Surgery SUAM, İzmir, Türkiye

Author Affiliations:

¹Department of Thoracic Surgery, Katip Çelebi University, İzmir Atatürk Training and Research Hospital, İzmir, Türkiye

²Department of Thoracic Surgery, SBÜ İzmir Dr. Suat Seren Chest Diseases and Surgery SUAM, İzmir, Türkiye

ABSTRACT

Sleeve resections in central tumors is a surgical method preferred over pneumonectomy owing to its parenchyma-sparing features. With the increasing surgical experience and developing technology in recent years, sleeve resections can be performed using the video-assisted thoracoscopic surgery method. However, these resections are technically challenging and require significant experience. In this review, we discuss sleeve resections with video-assisted thoracoscopic surgery in the light of the literature.

Keywords: Bronchial sleeve resection, lobectomy, video-assisted thoracoscopic surgery.

Approximately 3 to 19% of patients undergoing surgical treatment for primary lung cancer require bronchoplastic procedures.^[1] Bronchial sleeve resection is a surgical treatment method preferred over pneumonectomy in appropriate patients with central lung cancer due to its success in preserving healthy lung parenchyma and respiratory functions.^[2] Performing video-assisted thoracoscopic surgery (VATS) for bronchial sleeve resection is still controversial in most centers due to its technical difficulties. Indeed, initial studies published after the VATS method became widespread showed that the probability of sleeve resection was a contraindication for VATS.^[3,4]

A VATS lobectomy is defined as a lobectomy in which intrathoracic structures are visualized with videothoracoscopic equipment, a utility incision of

ÖZ

Santral tümörlerde sleeve rezeksiyonlar, parankim koruyucu olması nedeniyle pnömonektomiye tercih edilen cerrahi bir yöntemdir. Son yıllarda artan cerrahi deneyim ve gelişen teknoloji ile birlikte video yardımcı torakoskopik cerrahi yöntemi kullanılarak sleeve rezeksiyonlar yapılabilmektedir. Ancak bu rezeksiyonlar teknik olarak zordur ve önemli deneyim gerektirmektedir. Bu derlemede, video yardımcı torakoskopik cerrahi ile yapılan sleeve rezeksiyonlar literatür eşliğinde tartışıldı.

Anahtar sözcükler: Bronşiyal sleeve rezeksiyon, lobektomi, video yardımcı torakoskopik cerrahi.

less than 8 cm is used without separating ribs, hilar structures (vein, artery, and bronchus) are dissected separately, and standard lymph node dissection or sampling is performed.^[5] A VATS lobectomy should provide similar safety and oncological outcomes compared to the thoracotomy approach. Similarly, oncological and surgical outcomes obtained in the open method should be ensured in VATS sleeve resections. In this review, we discuss the main features and techniques of VATS sleeve resection surgeries.

General Features

History

The first case of bronchial sleeve resection using the VATS approach in the literature was reported in 2002.^[6] Santambrogio et al.^[6] performed left sleeve

Corresponding author: Kenan Can Ceylan

E-mail: kcanceylan@gmail.com

Doi: 10.5606/tgkdc.dergisi.2023.24737

Received: February 07, 2023

Accepted: February 21, 2023

Published online: April 25, 2023

Cite this article as: Acar A, Ceylan KC. VATS sleeve resections. Turk Gogus Kalp Dama 2023;31(Suppl 1):S45-S53. doi: 10.5606/tgkdc.dergisi.2023.24737.

©2023 All right reserved by the Turkish Society of Cardiovascular Surgery.



This is an open access article under the terms of the Creative Commons Attribution-NonCommercial License, which permits use, distribution and reproduction in any medium, provided the original work is properly cited and is not used for commercial purposes (<http://creativecommons.org/licenses/by-nc/4.0/>).

lower lobectomy with VATS in a 15-year-old patient diagnosed with mucoepidermoid carcinoma. In 2013, Diego Gonzalez-Rivas et al.^[17] published their first case of uniportal VATS sleeve lobectomy. Due to the increasing experience and developing technology, many advanced operations, such as VATS bronchovascular sleeve and carinal sleeve resections, are currently applied in various centers.^[8-10] However, there are few case series for VATS sleeve resections in the literature,^[11] and there is no recommendation for their clinical implementation in official guidelines, yet.^[12]

Advantages

The superiority of the VATS method over thoracotomy regarding morbidity, drainage time, length of hospital stay, and postoperative quality of life has been demonstrated many times.^[13-16] A surgeon with a high VATS experience can also use all these advantages for sleeve lobectomy patients. Thus, the benefits of both sleeve lobectomy and the VATS method are combined, and the patient is provided with a much more comfortable and less morbid postoperative period.

In recent years, studies have been published comparing VATS sleeve resections with the open method. Accordingly, in 2019, Gao et al.^[17] reported that VATS sleeve lobectomies could be performed with faster postoperative recovery and equivalent oncological outcomes compared to the open method in centrally located tumors. Although the studies of Deng^[18] and Mayne^[19] reported that VATS sleeve resections were associated with a longer operative time compared to the open method, Xie et al.^[20] found that VATS sleeve lobectomies could be performed in a similar period of time. Nonetheless, all these publications have demonstrated that VATS sleeve resections provide less operative trauma, less blood loss, faster recovery, and similar survival and oncological outcomes compared to the open method.^[12,17-20]

Preoperative and intraoperative process

Patients should be evaluated in detail in the preoperative period, as all pulmonary resection candidates. In particular, preoperative examination of all patients to be performed bronchial sleeve resection with fiberoptic bronchoscopy is crucial in demonstrating bronchial surgical margins. Although various positions can be given for different operations, the patient is usually placed in the lateral decubitus position for VATS sleeve resections. To better open the intercostal space, a pillow can be placed under the patient's axillary cavity, and the operating table can be

flexed between the iliac crest and the xiphoid process. While the surgeon and assistant (camera) are usually positioned in front of the patient, the screen is located posterior to the patient. While performing sleeve resection with VATS, a double-lumen endotracheal tube or bronchial blocker is used for one-lung ventilation, as in all lung surgery approaches. If the lung is still not deflated while entering the thorax, maneuvers such as bronchial aspiration, carbon dioxide (CO₂) insufflation, and regional lung compressions to facilitate atelectasis can be performed.

Port insertion

While performing VATS sleeve resection, there are several approaches depending on the surgeon's preference, as uniportal, two- or three-port methods can be used. The critical issue here is to perform the operation by providing the surgeon's comfort and vision with maximum efficiency. Although uniportal and two-port approaches are also used, we usually use three-port access as per the McKenna approach. Accordingly, a 4-cm utility incision is used in the mid-axillary region within the fourth or fifth intercostal space. A camera port is incised in the anterior axillary seventh intercostal space, and a third port is opened in the eighth to ninth intercostal space under the scapula (Figure 1). The stapler is usually used from the posterior port opened according to the hilus. However, a certain rule may not be fully adhered to while opening the ports. The locations of the port entrances should be adapted to each patient, considering the conditions that may differ for each patient (such as diaphragmatic height, mediastinum, and hilum placement).

Surgical equipment

In general, a 10-mm 30° thoracoscope is used in VATS operations. In some clinics, 5-mm thorascopes or 0 to 120° optics are also available. With the help of an HD video screen, a very high-quality image is obtained. There are even three-dimensional video-screen systems, and as in robotic surgery, it provides a sense of depth and superior vision in complex cases.

All instruments of open surgery can also be used for VATS sleeve resections. Various videothoroscopic instrument sets are currently sold. While performing VATS sleeve lobectomy in our clinic, endoscopic grasper, endoscopic scissors, long ovarian clamp, endoscopic knot tying and pusher, and coated forceps are routinely used together with the conventional surgery set. After dissecting the vascular and bronchial structures, a sling can be made with free silk or nylon tape to facilitate stapler placement. Sometimes, the tip

of a Foley catheter can be used as a guide by inserting it into the stapler. Finally, a soft tissue retractor placed in the utility port can greatly increase the comfort of the surgeon. An automatic skin retractor or a soft tissue retractor such as Alexis® (Applied Medical Resources Corporation, Rancho Santa Margarita, CA, USA) can be used for this purpose.

In the videothoracoscopic method, many different techniques and instruments are used for hemostasis. Suturing, cauterization, or endoclip applications (titanium or hem-o-lock clips) can be performed to control vascular hemorrhages. Electrocautery used in routine surgery is helpful in both hemostasis and separation of adhesions with a long tip or hook. Apart from all these, there are also energy devices whose use has become widespread in recent years. These devices work on ultrasonic or bipolar current principles. In routine practice, Harmonic® Scalpel

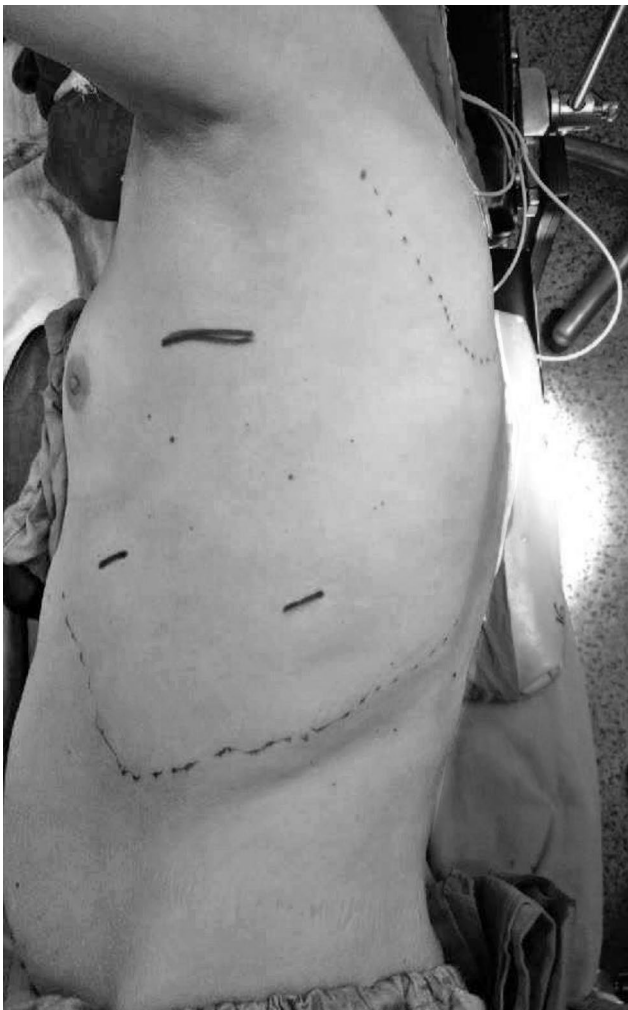

Figure 1. The positioning and the port entries of the patient.

(Ethicon Endo-Surgery, Inc., Cincinnati, OH, USA) from ultrasonic energy devices and EnSeal® (Ethicon Endo-Surgery, Inc., Cincinnati, OH, USA) and LigaSure™ (Covidien, Mansfield, MA, USA) from advanced bipolar electrocautery devices are used most frequently. Bipolar devices can successfully seal vascular structures up to 7 mm in diameter.^[21] All these devices can be applied safely in cases such as adhesion separation, inferior pulmonary ligament release, and lymph node dissection, as well as success in hemostasis, and can shorten the operation time.

Another application area in VATS lobectomy operations is the use of staplers. While performing lobectomy, different staplers are used for vascular, bronchial, and parenchymal tissue. Although there are many different stapler models of different brands, staples are 30-45-60-mm long and classified into 2 mm (grey), 2.5 mm (white-vascular), 3.5 mm (blue), 3.8 mm (gold) and 4.1 mm (green) according to their stapling depths. In general, white stapler cartridges are used in vascular structures and green in lobar bronchus and fissures. Automatic and curved tip staplers developed in recent years can increase the comfort of the surgeon considerably, as they perform safer and less stressful stapling-cutting applications.

Anastomosis

There is no common consensus regarding the anastomosis technique in VATS sleeve resections. In some publications, bronchial anastomosis is performed with separate sutures; in others, the membranous part is performed continuously, the cartilage part is sutured separately, while in some, the entire anastomosis is performed with continuous suturing. In their study, Palade et al.^[22] compared sleeve resection cases operated with separate and continuous sutures regarding postoperative complications and observed no significant differences. However, in recent years, the general trend has favored continuous suturing, since the technique is simpler and faster. The suture material also differs in the literature, as the suturing technique. While some centers operate with non-absorbable materials, it has been reported that absorbable sutures are used in some centers. Our clinic also uses both absorbable and non-absorbable materials, 3/0 or 4/0, in sleeve resection patients. The surgeon should choose the most suitable surgical material according to the patient and the operation.

Resection Types

In VATS sleeve resections, there is no difference in principle from the open method. All the rules applied in the open method are also available in the VATS

method. The distal and proximal segments of the bronchial level to be resected are carefully dissected. After the resection is completed, these distal and proximal structures are anastomosed to each other, and the process is terminated. Care should be taken to perform systemic lymph node dissection in patients with malignancy. Resection types are briefly described below.

Right sleeve upper lobectomy

Upper lobectomy is performed completely with the VATS, saving the bronchus last. After the upper lobe bronchus, intermediate bronchus, and right main bronchus are thoroughly dissected, the main bronchus is cut from the most distal possible point, and the intermediate bronchus is cut from the most proximal point possible. Stay sutures are placed on the main and intermediate bronchi. After the lobe is removed from the thorax, the right main bronchus is anastomosed to the intermediate bronchus through end-to-end suturing (Figures 2 and 3). Optionally, the anastomosis line is supported by bringing a flap from the surrounding tissues.

Right sleeve middle lobectomy

This is a rare sleeve resection and VATS middle lobectomy is performed up to the bronchus. The intermediate bronchus, middle lobe bronchus,

and lower lobe bronchus are well visualized. The intermediate bronchus is cut, and the distal incision is made with some angle to protect the superior segment entrance of the lower lobe. Since the pulmonary artery is located just behind the bronchus, care must be taken not to injure it while cutting the bronchus. Following the stay sutures, the intermediate and lower lobe bronchus are anastomosed end-to-end with continuous suturing.

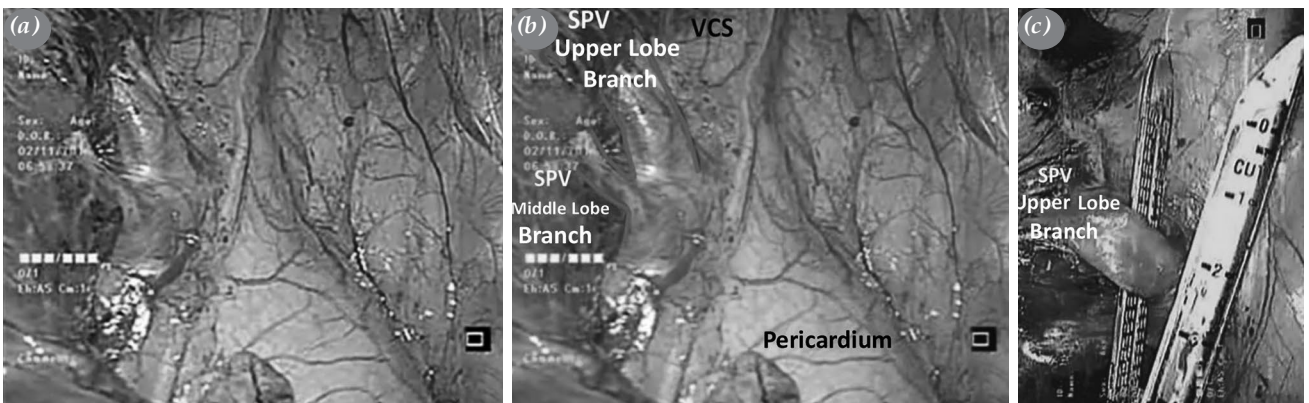
Right sleeve lower lobectomy

This is a very rare type of sleeve resection, and usually, inferior sleeve bilobectomy is required compared to this method. If necessary, VATS right lower lobectomy is completed up to the bronchus. The intermediate bronchus is cut just below the upper lobe branching. The middle lobe bronchus is cut, and an end-to-end anastomosis is performed between the intermediate and middle lobe bronchus.

Right sleeve inferior bilobectomy

This technique is used in tumor operations located in the intermediate bronchus and extending to the upper lobe bronchus opening. Following the completion of bilobectomy inferior with VATS, the main bronchus and upper lobe bronchus are also visualized. The upper lobe bronchus and the right main bronchus are cut. Following the stay sutures,

Dissection of the vein



Dissection of the artery

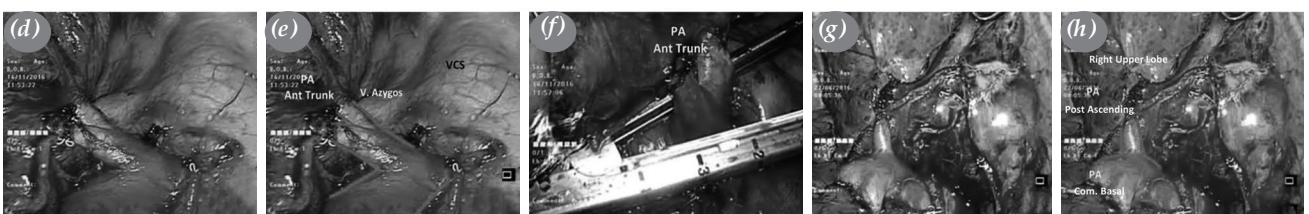
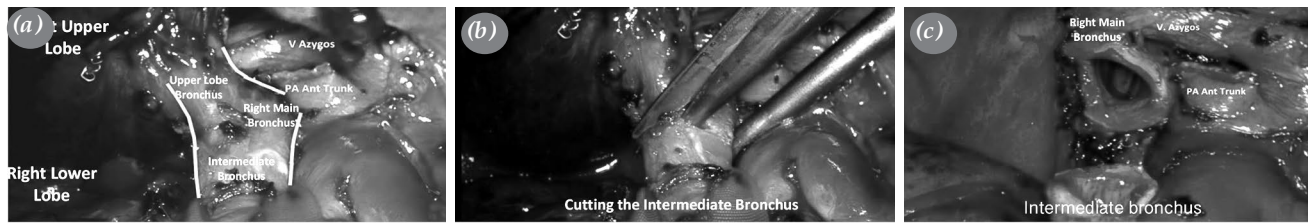
Figure 2. Dissection of the right upper lobe vein and artery. (a, b) Dissecting the upper lobe vein. (c) Stapling the upper lobe vein. (d, e) Dissecting the upper lobe arteries. (f) Stapling the anterior trunk artery. (g, h) Visualizing the posterior ascending artery.

SPV: Superior pulmonary vein; VCS: Vena cava superior.

Dissection of the bronchus



Bronchial anastomosis

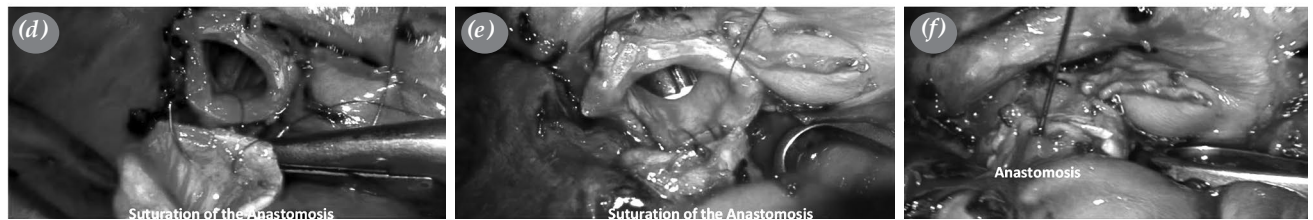

Figure 3. The bronchial anastomosis after dissecting right intermediate and main bronchi. (a) Dissection of the bronchial structures. (b, c) Cutting the intermediate bronchus. (d-f) Forming the bronchial anastomosis.

these two structures are anastomosed to each other with continuous suturing. In bronchial anastomosis, care should be taken not to torsion the upper lobe bronchus.

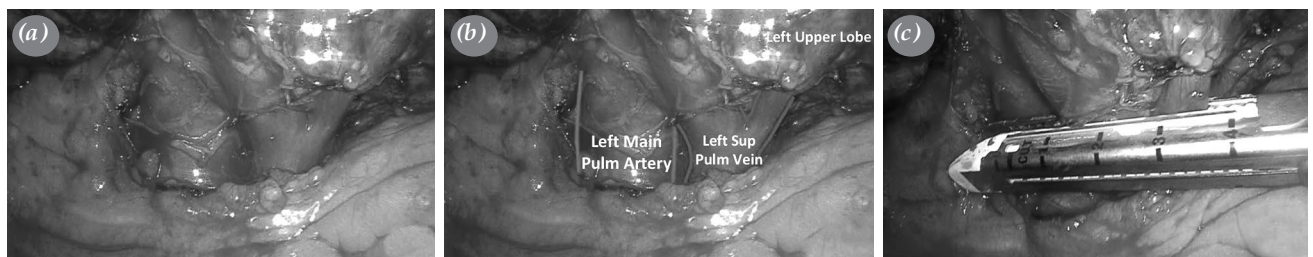
Right sleeve superior bilobectomy

This is a method used in the surgical treatment of endobronchial tumors reaching the level of the middle lobe from the upper lobe entrance. Following superior VATS bilobectomy, the main bronchus and lower lobe bronchus are carefully dissected. After the main and lower lobe bronchus is cut, they are anastomosed to each other end-to-end.

Left sleeve upper lobectomy

Anatomically longer left main bronchus provides more possibilities for left sleeve upper lobectomy. However, the absence of the intermediate bronchus, the adjacency of the aortic arch and the main pulmonary artery, and the shortness of the upper lobe bronchus cause a more challenging sleeve upper lobectomy compared to the right. Technically, after VATS left upper lobectomy is completed, stay sutures are placed in the left main bronchus and lower lobe bronchus. These structures are cut with a scalpel and then anastomosed end-to-end (Figures 4 and 5).

Dissection of the vein



Dissection of the artery


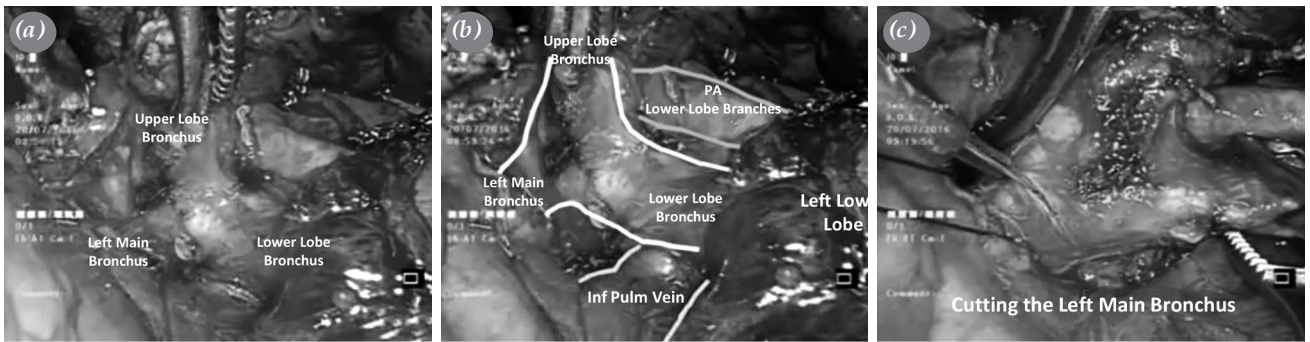


Figure 4. Dissection of the left upper lobe vein and artery. (a, b) Visualizing the left upper lobe vein. (c) Stapling the vein. (d-h) Dissecting the left upper lobe arteries and the stapling procedure.

PA: Pulmonary artery.

Dissection of the bronchus



Bronchial anastomosis

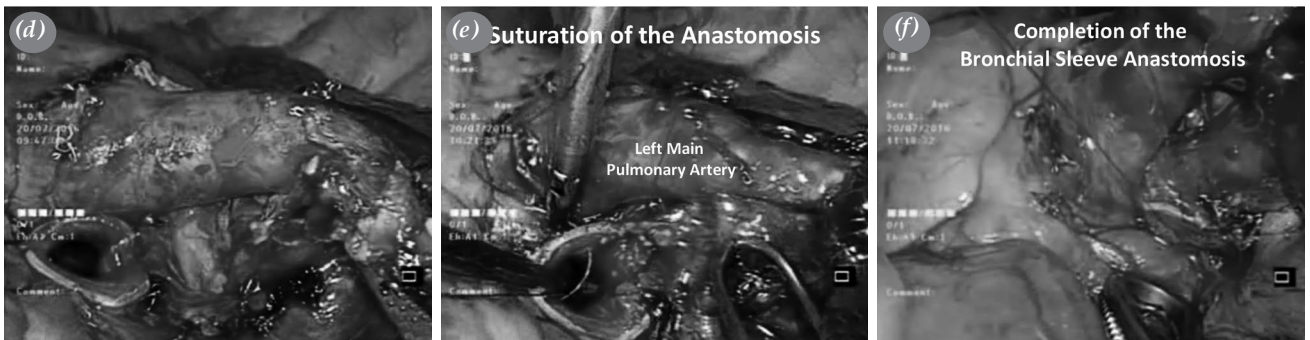

Figure 5. The bronchial anastomosis after dissecting left lower lobe and main bronchi. (a, b) Dissection of the bronchial structures. (c) Cutting the left main bronchus. (d-f) Forming the bronchial anastomosis.

Left sleeve lower lobectomy

This type of resection is one of the most difficult of all sleeve lobectomies.^[23] The presence of the pulmonary artery, which must be retracted during anastomosis, atrium, and upper lobe vein makes anastomosis very challenging. Following VATS left lower lobectomy is completed, and the upper lobe bronchus and main bronchus are cut. The aortic arch above the anastomotic line is another challenge of this end-to-end anastomosis. The end-to-end anastomosis is completed and the operation is completed.

Carinal sleeve resection

This method, which is unlikely to be applied on the left side, can be usually performed for tumors in the right upper lobe or right main bronchus. Isolated carinal resection may be sometimes required for tracheal tumors close to the carina level. The azygos vein may need to be sacrificed and, in some cases, the esophagus should be retracted. Using the same open method, stay sutures are placed in the trachea, left main bronchus, and right main bronchus. If necessary, relevant lung resection is performed. The carina is,

then, resected and the left lung is ventilated with the aid of a spiral endobronchial tube placed in the surgical field. The trachea and left main bronchus are anastomosed end-to-end, if the right pneumonectomy is performed. If an isolated carinal resection is applied without resection of the lung parenchyma, first, the right and left main bronchus are sutured together, and the carina is reconstructed (neo-carina). Then, the reconstructed carina is anastomosed with the trachea end-to-end. Although there are cases of carinal sleeve resection performed with uniportal VATS in the literature, it is obvious that VATS is not a very comfortable approach for these operations.

In carinal resections, the anesthesia method is as effective as the surgical technique on the operation success, morbidity, and mortality. Globally, a cross-field ventilation approach is used together with an orotracheal intubation tube. Nonetheless, in recent years, high-frequency jet ventilation has begun to be preferred in challenging operations such as carina resections where the airway is compromised.^[24] In this approach, a catheter with a smaller diameter than the intubation tube is advanced into the distal airway.

Thus, the procedure can be completed without the need to remove the tube from the field during anastomosis and without exposing the patient to hypoxemia.^[25]

Isolated bronchial sleeve resection

In this method, lung parenchyma is not resected. It is usually applied for benign endobronchial diseases. The bronchial part with the lesion is cut distal and proximal. The exposed bronchial openings are, then, anastomosed in an end-to-end fashion.

Vascular sleeve resections

Vascular sleeve resections may be required, usually on the left side, since the left upper lobe and the first branches of the pulmonary artery are closely related. In this method, approximately 5,000 IU of heparin sodium is administered intravenously before clamping the pulmonary artery. A clamp is, then, placed on the proximal pulmonary artery and distal pulmonary artery section or on the vein of the remaining lung section instead of the distal pulmonary artery. Vein clamping increases vision and provides a more comfortable anastomosis area. The anastomosis is completed with 5/0 or 6/0 prolene continuous sutures. Before the suture is knotted, the proximal clamp is opened to evacuate the air. The anastomosis is completed by knotting the suture.

Points to Consider Regarding the Anastomosis Line

The most feared complications after sleeve resection operations consist of bronchopleural fistula, bronchopulmonary fistula, and anastomotic stenosis. Contrary to the suture technique and the material used in sleeve anastomosis, the common consensus is that the anastomosis line should not be tense, and unnecessary bronchial dissection beyond the anastomosis level should be avoided.^[26] Technically, if the anastomosis is performed properly, almost all of the anastomosis-related complications are due to ischemia.^[27] Therefore, the teams performing the operation should be aware of the fact that the bronchial and pulmonary arteries have a rich anastomosis network at the lobar bronchus level^[28] and that excessive bronchial dissection should be avoided. While suturing the anastomosis, if two bronchial structures with different diameters are anastomosed, the large-diameter bronchus should be sutured more intermittently, and the small-diameter bronchus should be sutured more frequently to ensure that the two structures fit together well.

Another critical point is to support the anastomosis line with surrounding tissue flaps. For this purpose, intercostal muscle flaps, thymopericardial fatty tissue flaps, and mediastinal pleural flaps can be used.

However, there are publications in the literature indicating that the flap, itself, may cause a stricture as a result of ossification of the intercostal muscle flap.^[29]

In conclusion, video-assisted thoracoscopic surgery sleeve resections require a high level of experience due to their technical difficulty. The fact that the surgeon has performed a significant number of surgeries on sleeve resections using the open method and lung resections using video-assisted thoracoscopic surgery before initiating this method is crucial regarding the feasibility and safety of the technique. In addition, watching and observing live operations would contribute to the surgeon in terms of the steps to be followed. It is of utmost importance to be able to manage complications that may occur and complete the operation following the technical and oncological principles.

Due to constantly improving surgical techniques, developing endoscopic instrumentation, and increasing experience in minimally invasive approaches, challenging operations such as sleeve resections can be performed with video-assisted thoracoscopic surgery currently. In the hands of experienced surgeons, video-assisted thoracoscopic surgery sleeve resection is a safe and effective method that offers patients a more comfortable postoperative period. However, if the surgeon is not experienced, if the operation time is prolonged, or if it is complicated, insisting on the video-assisted thoracoscopic surgery method in sleeve resections may be harmful to the patient. Converting to thoracotomy should be always considered an option. Patient selection should be made carefully, taking into account all these issues.

Data Sharing Statement: The data that support the findings of this study are available from the corresponding author upon reasonable request.

Author Contributions: Idea/concept, control/supervision: K.C.C.; Design, data collection and/or processing, literature review, writing the article: A.A.; Analysis and/or interpretation, critical review, materials: K.C.C.; References: K.C.C., A.A.

Conflict of Interest: The authors declared no conflicts of interest with respect to the authorship and/or publication of this article.

Funding: The authors received no financial support for the research and/or authorship of this article.

REFERENCES

1. Yamamoto K, Miyamoto Y, Ohsumi A, Kojima F, Imanishi N, Matsuoka K, et al. Sleeve lung resection for lung cancer: Analysis according to the type of procedure. *J Thorac Cardiovasc Surg* 2008;136:1349-56. doi: 10.1016/j.jtcvs.2008.05.018.

2. Deslauriers J, Grégoire J, Jacques LF, Piraux M, Guojin L, Lacasse Y. Sleeve lobectomy versus pneumonectomy for lung cancer: A comparative analysis of survival and sites or recurrences. *Ann Thorac Surg* 2004;77:1152-6. doi: 10.1016/j.athoracsur.2003.07.040.
3. Hanna JM, Berry MF, D'Amico TA. Contraindications of video-assisted thoracoscopic surgical lobectomy and determinants of conversion to open. *J Thorac Dis* 2013;5 Suppl 3:S182-9. doi: 10.3978/j.issn.2072-1439.2013.07.08.
4. Paul S, Altorki NK, Sheng S, Lee PC, Harpole DH, Onaitis MW, et al. Thoracoscopic lobectomy is associated with lower morbidity than open lobectomy: A propensity-matched analysis from the STS database. *J Thorac Cardiovasc Surg* 2010;139:366-78. doi: 10.1016/j.jtcvs.2009.08.026.
5. Swanson SJ, Herndon JE 2nd, D'Amico TA, Demmy TL, McKenna RJ Jr, Green MR, et al. Video-assisted thoracic surgery lobectomy: Report of CALGB 39802--a prospective, multi-institution feasibility study. *J Clin Oncol* 2007;25:4993-7. doi: 10.1200/JCO.2007.12.6649.
6. Santambrogio L, Cioffi U, De Simone M, Rosso L, Ferrero S, Giunta A. Video-assisted sleeve lobectomy for mucoepidermoid carcinoma of the left lower lobar bronchus: A case report. *Chest* 2002;121:635-6. doi: 10.1378/chest.121.2.635.
7. Gonzalez-Rivas D, Fernandez R, Fieira E, Rellan L. Uniportal video-assisted thoracoscopic bronchial sleeve lobectomy: First report. *J Thorac Cardiovasc Surg* 2013;145:1676-7. doi: 10.1016/j.jtcvs.2013.02.052.
8. Gonzalez-Rivas D, Yang Y, Stupnik T, Sekhniaidze D, Fernandez R, Velasco C, et al. Uniportal video-assisted thoracoscopic bronchovascular, tracheal and carinal sleeve resections. *Eur J Cardiothorac Surg* 2016;49 Suppl 1:i6-16. doi: 10.1093/ejcts/ezv410.
9. Huang J, Li J, Qiu Y, Xu X, Sekhniaidze D, Chen H, et al. Thoracoscopic double sleeve lobectomy in 13 patients: A series report from multi-centers. *J Thorac Dis* 2015;7:834-42. doi: 10.3978/j.issn.2072-1439.2015.04.55.
10. Lyscov A, Obukhova T, Ryabova V, Sekhniaidze D, Zuiev V, Gonzalez-Rivas D. Double-sleeve and carinal resections using the uniportal VATS technique: A single centre experience. *J Thorac Dis* 2016;8(Suppl 3):S235-41. doi: 10.3978/j.issn.2072-1439.2016.02.25.
11. Ceylan KC, Acar A, Örs Kaya Ş. The initial experience on thoracoscopic sleeve lobectomy: Continuous suturing technique of the bronchial anastomosis in 12 cases. *Surg Laparosc Endosc Percutan Tech* 2020;30:476-9. doi: 10.1097/SLE.0000000000000831.
12. Geropoulos G, Esagian SM, Skarentzos K, Ziogas IA, Katsaros I, Kosmidis D, et al. Video-assisted thoracoscopic versus open sleeve lobectomy for non-small cell lung cancer: A systematic review and meta-analysis from six comparative studies. *Asian Cardiovasc Thorac Ann* 2022;30:881-93. doi: 10.1177/02184923221115970.
13. McKenna RJ Jr, Houck W, Fuller CB. Video-assisted thoracic surgery lobectomy: Experience with 1,100 cases. *Ann Thorac Surg* 2006;81:421-6. doi: 10.1016/j.athoracsur.2005.07.078.
14. Handy JR Jr, Asaph JW, Douville EC, Ott GY, Grunkemeier GL, Wu Y. Does video-assisted thoracoscopic lobectomy for lung cancer provide improved functional outcomes compared with open lobectomy? *Eur J Cardiothorac Surg* 2010;37:451-5. doi: 10.1016/j.ejcts.2009.07.037.
15. Taioli E, Lee DS, Lesser M, Flores R. Long-term survival in video-assisted thoracoscopic lobectomy vs open lobectomy in lung-cancer patients: A meta-analysis. *Eur J Cardiothorac Surg* 2013;44:591-7. doi: 10.1093/ejcts/ezt051.
16. Zhang Z, Zhang Y, Feng H, Yao Z, Teng J, Wei D, et al. Is video-assisted thoracic surgery lobectomy better than thoracotomy for early-stage non-small-cell lung cancer? A systematic review and meta-analysis. *Eur J Cardiothorac Surg* 2013;44:407-14. doi: 10.1093/ejcts/ezt015.
17. Gao HJ, Jiang ZH, Gong L, Ma K, Ren P, Yu ZT, et al. Video-assisted vs thoracotomy sleeve lobectomy for lung cancer: A propensity matched analysis. *Ann Thorac Surg* 2019;108:1072-9. doi: 10.1016/j.athoracsur.2019.04.037.
18. Deng HY, Qiu XM, Zhu DX, Tang X, Zhou Q. Video-assisted thoracoscopic sleeve lobectomy for centrally located non-small cell lung cancer: A meta-analysis. *World J Surg* 2021;45:897-906. doi: 10.1007/s00268-020-05877-5.
19. Mayne NR, Darling AJ, Raman V, Balderson S, Berry MF, Harpole DH Jr, et al. Perioperative outcomes and 5-year survival after open versus thoracoscopic sleeve resection for lung cancer. *Semin Thorac Cardiovasc Surg* 2021;33:522-30. doi: 10.1053/j.semtcvs.2020.08.013.
20. Xie D, Deng J, Gonzalez-Rivas D, Zhu Y, Jiang L, Jiang G, et al. Comparison of video-assisted thoracoscopic surgery with thoracotomy in bronchial sleeve lobectomy for centrally located non-small cell lung cancer. *J Thorac Cardiovasc Surg* 2021;161:403-13.e2. doi: 10.1016/j.jtcvs.2020.01.105.
21. Lacin T, Batirel HF, Ozer K, Demirutku A, Ahiskali R, Yuksel M. Safety of a thermal vessel sealer on main pulmonary vessels. *Eur J Cardiothorac Surg* 2007;31:482-5. doi: 10.1016/j.ejcts.2006.11.038.
22. Palade E, Holdt H, Passlick B. Bronchus anastomosis after sleeve resection for lung cancer: Does the suture technique have an impact on postoperative complication rate? *Interact Cardiovasc Thorac Surg* 2015;20:798-804. doi: 10.1093/icvts/ivv058.
23. Gonzalez-Rivas D, Delgado M, Fieira E, Pato O. Left lower sleeve lobectomy by uniportal video-assisted thoracoscopic approach. *Interact Cardiovasc Thorac Surg* 2014;18:237-9. doi: 10.1093/icvts/ivt441.
24. Gritsiuta AI, Bakhos CT, Abbas AE, Petrov RV. High-frequency jet ventilation jets the way to minimally invasive carinal resection? *J Thorac Dis* 2022;14:4590-2. doi: 10.21037/jtd-22-1196.
25. Qiu Y, Yu F, Yao F, Wu J. The efficacy of high-frequency jet ventilation on intraoperative oxygen saturation compared to cross-field ventilation in patients undergoing carinal resection and reconstruction. *J Thorac Dis* 2022;14:3197-204. doi: 10.21037/jtd-22-355.
26. Soultanis KM, Chen Chao M, Chen J, Wu L, Yang C, Gonzalez-Rivas D, et al. Technique and outcomes of 79 consecutive uniportal video-assisted sleeve lobectomies. *Eur J Cardiothorac Surg* 2019;56:876-82. doi: 10.1093/ejcts/ezz162.

27. Kutlu CA, Goldstraw P. Tracheobronchial sleeve resection with the use of a continuous anastomosis: Results of one hundred consecutive cases. *J Thorac Cardiovasc Surg* 1999;117:1112-7. doi: 10.1016/s0022-5223(99)70247-3.
28. Fréchette E, Deslauriers J. Surgical anatomy of the bronchial tree and pulmonary artery. *Semin Thorac Cardiovasc Surg* 2006;18:77-84. doi: 10.1053/j.semtcvs.2006.06.002.
29. Deeb ME, Sterman DH, Shrager JB, Kaiser LR. Bronchial anastomotic stricture caused by ossification of an intercostal muscle flap. *Ann Thorac Surg* 2001;71:1700-2. doi: 10.1016/s0003-4975(00)02583-2.