



Since January 2020 Elsevier has created a COVID-19 resource centre with free information in English and Mandarin on the novel coronavirus COVID-19. The COVID-19 resource centre is hosted on Elsevier Connect, the company's public news and information website.

Elsevier hereby grants permission to make all its COVID-19-related research that is available on the COVID-19 resource centre - including this research content - immediately available in PubMed Central and other publicly funded repositories, such as the WHO COVID database with rights for unrestricted research re-use and analyses in any form or by any means with acknowledgement of the original source. These permissions are granted for free by Elsevier for as long as the COVID-19 resource centre remains active.



ELSEVIER

Available online at www.sciencedirect.com

SCIENCE @ DIRECT®

Veterinary Immunology and Immunopathology 112 (2006) 141–155

Veterinary
immunology
and
immunopathology

www.elsevier.com/locate/vetimm

Natural feline coronavirus infection: Differences in cytokine patterns in association with the outcome of infection

Anja Kipar^{a,*}, Marina L. Meli^b, Klaus Failing^c, Tatjana Euler^a,
Maria A. Gomes-Keller^b, Dirk Schwartz^a, Hans Lutz^b,
Manfred Reinacher^a

^a *Institut für Veterinär-Pathologie, Justus-Liebig-Universität Giessen, Frankfurter Strasse 96, 35392 Giessen, Germany*

^b *Clinical Laboratory, Faculty of Veterinary Medicine, VetSuisse Faculty, 8057 Zurich, Switzerland*

^c *Department of Biostatistics, Justus-Liebig-Universität Giessen, 35392 Giessen, Germany*

Received 10 August 2005; received in revised form 5 January 2006; accepted 15 February 2006

Abstract

Natural and experimental feline coronavirus (FCoV) infection leads to systemic viral spread via monocyte-associated viraemia and induces systemic proliferation of monocytes/macrophages. In the majority of naturally infected animals, FCoV infection remains subclinical and is associated with generalised B and T cell hyperplasia, but no other pathological findings. A minority of cats, however, develop feline infectious peritonitis (FIP), a fatal systemic granulomatous disease. This is generally accompanied by B and T cell depletion. The obvious functional differences of lymphatic tissues in FCoV-infected cats with and without FIP suggest that they contribute to the outcome of FCoV infection. This study attempted to evaluate the functional changes in haemolymphatic tissues after natural FCoV infection, with special emphasis on the magnitude, phenotype and function of the monocyte/macrophage population. The spleen, mesenteric lymph nodes and bone marrow from naturally FCoV-infected cats with and without FIP and specific pathogen-free (SPF) control cats were examined for the quantity and activation state of monocytes/macrophages both by immunohistology and by quantitative real time PCR for the transcription of interleukin (IL)-1 β , IL-6, IL-10, IL-12 p40, tumour necrosis factor (TNF), granulocyte colony stimulating factor (G-CSF), macrophage-CSF (M-CSF) and GM-CSF. Compared to cats with FIP, FCoV-infected cats without FIP exhibited significantly higher IL-10 levels in the spleen and significantly lower levels of IL-6, G- and M-CSF in mesenteric lymph nodes. In cats with FIP, however, IL-12 p40 levels were significantly lower in lymphatic tissues in comparison to both SPF cats and FCoV-infected cats without FIP. In comparison to SPF cats, FIP cats had significantly higher IL-1 β levels and lower TNF levels in mesenteric lymph nodes and lower M-CSF levels in the spleen. Findings indicate that FCoV-infected cats which do not develop FIP are able to mount an effective FCoV-specific immune response and can avoid excessive macrophage activation and FIP, possibly by upregulation of IL-10 production. Development of FIP, however, might be due to

* Corresponding author. Present address: Department of Veterinary Pathology, Faculty of Veterinary Science, University of Liverpool, Crown Street, Liverpool L69 7ZJ, UK. Tel.: +44 151 794 4260 (Secr.); fax: +44 151 794 4268.

E-mail address: akipar@liverpool.ac.uk (A. Kipar).

a lack of IL-12 which inhibits an effective cellular immune response and allows for monocyte/macrophage activation and the development of FIP.

© 2006 Elsevier B.V. All rights reserved.

Keywords: FCoV; FIP; Haemolympathic tissues; Cytokine transcription; IL-10; IL-12

1. Introduction

Feline infectious peritonitis (FIP) is a well-known and widely distributed coronavirus (FCoV)-induced systemic disease in cats, characterised by fibrinous-granulomatous serositis with protein-rich effusions into body cavities, granulomatous-necrotising phlebitis and periphlebitis and granulomatous inflammatory lesions in several organs (Hayashi et al., 1977; Weiss and Scott, 1981; Kipar et al., 1998, 2005).

FCoV is transmitted via the faecal-oral route and primarily infects enterocytes (Pedersen, 1995), but subsequently spreads systemically via monocyte-associated viraemia (Gunn-Moore et al., 1998; Kipar et al., 1999; Meli et al., 2004). However, FCoV-infected circulating monocytes are not only responsible for viral dissemination, but also, in an activated state, for the development of vasculitis (Weiss and Scott, 1981; Jacobse-Geels et al., 1982; Pedersen, 1995; Kipar et al., 2005).

Despite the generally high prevalence of FCoV infection in the cat population, FIP morbidity is low and rarely surpasses 5% (Addie et al., 1995; Pedersen, 1995; Gunn-Moore et al., 1998). This is due to the fact that virulent FCoV are predominantly generated within the individual infected host (Vennema et al., 1998). In virulent FCoV, deletions in genes encoding non-structural proteins of yet unknown function, which develop during replication, have been observed (Vennema et al., 1998; Kennedy et al., 2001).

Previous studies revealed major differences in the composition and functional state of lymphatic tissues of FCoV-infected cats with and without FIP (Kipar et al., 1999, 2001a). In cats with FIP, T and B cell depletion is consistently observed (Weiss and Scott, 1981; Kipar et al., 2001a). In experimentally infected animals with FIP, enhanced lymphocyte apoptosis in B and T cell zones of the spleen and mesenteric lymph nodes was also described (Haagmans et al., 1996; Dean et al., 2003). Prior to lymphocyte depletion, however, most animals appear to develop a specific,

systemic B cell response with formation of secondary follicles (Kipar et al., 2001a). In addition, lymphatic tissues contain increased numbers of monocytes/macrophages, some of which are proliferating (Kipar et al., 1999, 2001a). In contrast, FCoV-infected cats without FIP exhibit generalised B and T cell hyperplasia with a high rate of lymphocyte proliferation (Kipar et al., 1999, 2001a). Regardless of the development of FIP, FCoV infection induces a specific systemic immune response with FCoV antibodies, circulating FCoV-specific immune complexes and the presence of plasma cells positive for FCoV-specific antibodies in lymphatic tissues (Osterhaus et al., 1977; Kipar et al., 1999; Meli et al., 2004). In FIP lesions, B cells are the dominant lymphocyte subtype; they gradually replace the macrophages and seem to develop into plasma cells positive for FCoV-specific antibodies (Kipar et al., 1998, 1999). These findings suggest that animals susceptible to FIP fail to avoid the potential detrimental sequelae of FCoV infection and therefore develop both FIP and lymphatic depletion (Kipar et al., 2001a).

Based on morphological and limited functional studies, the pathogenesis of FIP lesions is now relatively well understood (Hasegawa and Hasegawa, 1991; Foley et al., 2003; Berg et al., 2005; Kipar et al., 2005). However, data on the immunological processes associated with the development of the disease are limited and mainly restricted to experimentally infected animals (Haagmans et al., 1996; Dean et al., 2003). In the present study, an attempt was made to evaluate the potential contribution of haemolympathic tissues to the outcome of natural FCoV infection in the individual cat. Examinations focused on the assessment of the functional state of the spleen, mesenteric lymph nodes and bone marrow in cats with FIP, in comparison to FCoV-infected cats without FIP and uninfected specific pathogen-free (SPF) cats, with special emphasis on the magnitude, phenotype and function of the monocyte/macrophage population. It included quantitative real time PCR for

feline interleukin (IL)-1 β , IL-6, IL-10, IL-12 p40, tumour necrosis factor (TNF), granulocyte colony stimulating factor (G-CSF), macrophage-CSF (M-CSF) and GM-CSF.

2. Materials and methods

2.1. Animals, tissue processing, histology and immunohistology

The study was performed on 15 necropsied cats which had died or been euthanased with lesions of FIP (group 1). Animals ranged from 5 months to 4 years of age (Table 1). Group 2 consisted of 13 apparently healthy SPF cats, aged 1 year, which had been housed for 30 weeks with cats developing FIP (Kipar et al., 1999). All group 2 cats had shown positive results in tests for CoV antibodies, circulating FCoV-specific immune complexes and monocyte-associated FCoV viraemia (Kipar et al., 1999). The haemolymphatic tissues from group 1 and group 2 cats had also tested positive for FCoV RNA by RT-PCR (Kipar et al., 2006). Nine SPF cats aged 9.5 months and five SPF cats aged 15 months served as uninfected controls (group 3).

Table 1
Age, gender and distribution of FIP lesions in cats with FIP (group 1)

Cat	Age	Gender	FIP lesions
1	6 mo	m	Peritoneum
2	2 y	f	Peritoneum [ascites], mes lnn
3	4 y	m	Peritoneum [ascites]
4	Juvenile	m	Kidneys, spleen, liver, lungs, brain, spinal cord
5	Juvenile	f	Peritoneum, spleen, pancreas
6	Juvenile	f	Peritoneum, mes lnn
7	Juvenile	m	Peritoneum, mes lnn, spinal cord
8	Juvenile	m	Peritoneum [ascites], mes lnn
9	4 y	f	Brain
10	6 mo	mn	Peritoneum
11	1.5 y	mn	Peritoneum [ascites], mes lnn
12	5 mo	m	Peritoneum, kidneys, lungs, liver, spleen
13	2 y	mn	Kidneys, brain, eyes
14	1 y	f	Kidneys, brain
15	1.5 y	mn	Kidneys, pleura, lungs [pleural effusion]

y, year(s); mo, months; m, male; f, female; n, neutered; mes lnn, mesenteric lymph nodes.

All animals were necropsied at times ranging from a few minutes to 2 h after death, and samples from the spleen, mesenteric lymph nodes and bone marrow were collected and frozen at -80°C for RNA extraction. The tissue samples from the spleen and mesenteric lymph nodes were taken from areas without macroscopic FIP lesions.

Additional haemolymphatic tissue and organ samples were fixed in 10% buffered formalin and routinely embedded in paraffin. Sections (5 μm) were stained with haematoxylin and eosin (HE) or by immunohistology (IH). In haemolymphatic tissues monocytes, recently blood-derived macrophages and myelomonocytic cells were demonstrated by IH, using a cross-reacting mouse monoclonal antibody against the human myeloid/histiocyte antigen (clone MAC387, DakoCytomation GmbH, Ely, UK; Kipar et al., 1998, 2001a,b, 2005). Expression of the CD18 component of β_2 -integrin adhesion molecules was shown by a mouse monoclonal antibody against feline CD18 (clone FE3.9F2, Leukocyte Antigen Biology Lab., University of California, Davis, USA; Kipar et al., 2005). Both haemolymphatic tissues and organ specimens with histologically confirmed FIP lesions were examined for the presence of FCoV antigen (clone FCV3-70, Custom Monoclonals Int., West Sacramento, USA; Kipar et al., 1998, 2005).

2.2. Immunohistological scoring system

The percentage of cells labelled for myeloid/histiocyte antigen and CD18 in relation to the total cell population in the different compartments (e.g. the splenic red pulp) was blindly evaluated semi-quantitatively (i.e. by counting the immunolabelled cells and the total number of nucleated cells in several high power fields) by light microscopy. The scoring was made in 25% steps.

2.3. Evaluation of activity and composition of haemolymphatic tissues

Using a previously described evaluation protocol on HE-stained sections (Kipar et al., 2001a), activity and composition of haemolymphatic tissues in SPF cats was considered as normal (controls). In SPF cats, splenic white pulp was represented by small primary and/or secondary follicles and few, cell-rich periarter-

ial lymphocyte layers in T cell zones; splenic red pulp exhibited moderate numbers of mononuclear cells. Mesenteric lymph nodes generally exhibited cell-rich secondary follicles, broad, cell-rich T cell zones and mild histiocytosis of the medullary sinuses. Lymphocyte depletion and hyperplasia, both in follicles and T cell zones were graded as mild (+), moderate (++) or severe (+++), based on the degree of reduction or increase in cellularity of the tissue compartments (Kipar et al., 2001a). Grading as +/++ or ++/+++ was used when variability between different areas of the organ was observed. Bone marrow activity was graded as low (+), moderate (++) , moderate to high (++/+++) or high (+++), based on the cellularity of a cross section of the femoral bone marrow cylinder. In SPF cats, bone marrow activity was mostly high and occasionally moderate to high.

2.4. RNA extraction and cDNA synthesis

For RNA extraction, approximately 100 mg of tissue was homogenised with a tissue homogeniser (PCR Tissue Homogenizing Kit, Süd-Laborbedarf GmbH, Gauting, Germany) and lysed with 700 μ l lysis buffer. Total RNA was extracted with a commercially available kit (RNeasy Mini kit; QIAGEN, Hilden, Germany) according to the manufacturer's protocol (Kipar et al., 2001b). RNA was dissolved in 30 μ l RNase-free water and digested with RNase-free DNase I (Promega GmbH, Mannheim, Germany) and subjected to the synthesis of cDNA using avian myoblastosis virus (AMV) reverse transcriptase (Promega) according to published protocols (Leutenegger et al., 1999; Kipar et al., 2001b).

2.5. TaqMan primers and probes and real time TaqMan-PCR for feline IL-1 β , IL-6, IL-10, IL-12 p40, TNF, G-CSF, M-CSF and GM-CSF

Quantitative real time TaqMan PCR, using an automated fluorometer (ABI Prism 7700 Sequence Detection System) was used for the relative quantification of feline (f) IL-1 β , fIL-6, fIL-10, fIL-12 p40, fTNF, fG-CSF, fM-CSF and fGM-CSF transcription (Leutenegger et al., 1999; Kipar et al., 2001b). Feline GAPDH levels served as internal controls.

For each target gene, two primers and an internal oligonucleotide as a probe (FAM (6-carboxyfluores-

cein)-labelled at the 5' end (reporter dye), TAMRA (6-carboxytetramethylrhodamine)-labelled at the 3' end (quencher dye), phosphate-blocked at the 3' end to prevent extension by AmpliTaq Gold DNA polymerase) were used. Primer (f, r) and probe (p) sequences were as previously published for the following systems: IL-1 β (76 bp PCR product; Kipar et al., 2001b), IL-6 (110 bp PCR product; Kipar et al., 2001a,b), IL-10 (76 bp PCR product; Leutenegger et al., 1999), IL-12 p40 (81 bp PCR product; Leutenegger et al., 1999), TNF (74 bp PCR product; Kipar et al., 2001b) and GAPDH (82 bp PCR product; Leutenegger et al., 1999). Primer and probe sequences for the CSFs were as follows: G-CSF (NCBI-Accession No. Y08558; 117 bp PCR product): fGCSF.410f (5'-CAGCTGGACAT-CACCGACTTT-3'), fGCSF.526r (5'-CTGGAAGGC-CGAGGTGAA-3'), fGCSF.440p (5'-CCACGTC-TTCCATCTGCTGCCAGAT-3'); M-CSF (M. Lineberger, personal communication; 79 bp PCR product): fMCSF.361f (5'-CAGCTGCTTACCAGGGACTAT-3'), fMCSF.457r (5'-GACATTCTTGATCTTTTC-CAGCA-3'), fMCSF.390p (5'-AGGACAAGGCCTGTGTACGAACCTTCCATG-3'), GM-CSF (NCBI-Accession No. AF053007; 79 bp PCR product): fGMCSF.160f (5'-AATGAAACGGTAGAAGTTCGTCTCTG-3'), fGMCSF.238r (5'-CGTACAGCTTTA-GGTGAGTCTGCA-3'), fGMCSF.191p (5'-TTG-ACCCTGAGGAGCCGAATTGCC-3').

From every cDNA sample, parallel reactions were performed in duplicate in separate tubes for the detection of fGAPDH and all cytokines. Amplification conditions and assay compositions were identical for all reactions and followed previously published protocols (Kipar et al., 2001b). Primer and probe concentrations were 400 nM and 80 nM, respectively, for fGAPDH, fIL-1 β , fIL-6, fIL-10, fIL-12 p40 and fTNF, 300 nM and 75 nM for fGM-CSF primers and probe, and 300 nM and 200 nM for fG-CSF and fM-CSF primers and probes.

2.6. Verification of TaqMan PCR specificity

The specificity of the TaqMan PCR systems for feline GAPDH, IL-1 β , IL-6, IL-10, IL-12 p40 and TNF was demonstrated previously (Leutenegger et al., 1999; Kipar et al., 2001b). TaqMan PCR products for feline G-CSF, M-CSF and GM-CSF were run on a 2% agarose gel. Fragments were cloned, using a TOPO TA

Cloning[®]PCR[®]2.1-TOPO[®]Kit (Invitrogen BV, Groningen, The Netherlands), propagated in *E. coli* (TOP10F[®]One Shot[®] *E. coli*) vector, and sequenced with a fluorescence-based automated sequencing system (ABI 377 DNA sequencer; SeqLab, Sequence Laboratories Göttingen GmbH, Göttingen, Germany) to confirm the specificity.

2.7. Relative quantification of cytokine transcripts

Relative quantification of cytokine signals was done by the comparative C_T method and was reported as relative transcription or the *n*-fold differences relative to the calibrator cDNA (fGAPDH) (Leutenegger et al., 1999; Kipar et al., 2001b). For each sample, differences between the target and internal control C_T were calculated and served to normalize for differences in the amount of total nucleic acid added to each reaction and the efficiency of the reverse transcriptase step as previously described (Kipar et al., 2001b).

2.8. Statistical analysis

Statistical analysis was performed, using the statistical programme package BMDP (Dixon, 1993). The Kruskal–Wallis test, followed by the Nemenyi comparison, was applied to compare cytokine transcription levels in organs of all three groups of cats. Additionally, the Wilcoxon Mann Whitney test was used to compare cytokine transcription levels in organs of cats with FIP and SPF cats.

3. Results

3.1. Lesions in cats with FIP (group 1)

Lesions typical for FIP were represented by a fibrinous to granulomatous peritonitis and pleuritis, often associated with effusion, and/or by granulomatous lesions in various organs as well as lymph nodes and the central nervous system (Table 1). Brain and spinal cord involvement was characterised by a granulomatous leptomeningitis, often with granulomatous phlebitis and periphlebitis. The latter was also observed occasionally in eyes, renal cortices and lungs. Immunohistologically, FCoV antigen was demonstrated within macrophages in the lesions.

3.2. Haemolymphatic tissues: activity and composition, FCoV antigen expression

3.2.1. Spleen and mesenteric lymph nodes

Cats with FIP exhibited mild to severe follicular depletion in spleen (13/15) and mesenteric lymph nodes (mes lnn, 15/15). Primary and/or secondary follicles were observed in both organs. T cell zones were mildly to moderately depleted in both the spleen (12/15) and mes lnn (13/15). In seven cases, the splenic red pulp was very cell-rich and predominantly composed of macrophage-like mononuclear cells. In 13 cases, mes lnn exhibited mild to severe histiocytosis, mainly of marginal sinuses, which was often associated with marked dilation of the sinuses.

FCoV-infected cats without FIP generally exhibited secondary follicles both in the spleen and mes lnn. In the spleen, these were normal (2/13) or hyperplastic (9/13) and in only two cases were mildly depleted. In the mes lnn, secondary follicles were normal (3/13) or hyperplastic (10/13). T cell zones were mainly normal (11/13) in the spleen and often hyperplastic (7/13) in the mes lnn.

Myeloid/histiocyte antigen (m/h Ag)-positive monocytes/macrophages represented less than 25% of the cells in the splenic red pulp of SPF cats; they were more numerous in some FCoV-infected cats without FIP and often represented the dominant cell population in cats with FIP (Figs. 1a and 2a and b). In SPF cats, up to 50% of cells in the red pulp were CD18-positive; in FCoV-infected cats without FIP, the number of CD18-positive cells was often higher and generally surpassed 75% in cats with FIP (Figs. 1b and 2c and d).

In the mes lnn, the m/h Ag was only expressed by scattered sinus histiocytes in all groups of cats. In SPF cats and FCoV-infected cats without FIP, CD18 expression was also restricted to few, faintly positive sinus histiocytes. Whereas in cats with FIP, sinus histiocytes generally exhibited a strong cytoplasmic and peripheral CD18 reaction (Fig. 3).

3.2.2. Bone marrow

Bone marrow activity was moderate to high in all groups of cats. In the majority of SPF cats, m/h Ag expression was seen in up to 50% of nucleated cells. The number of positive cells was often higher in

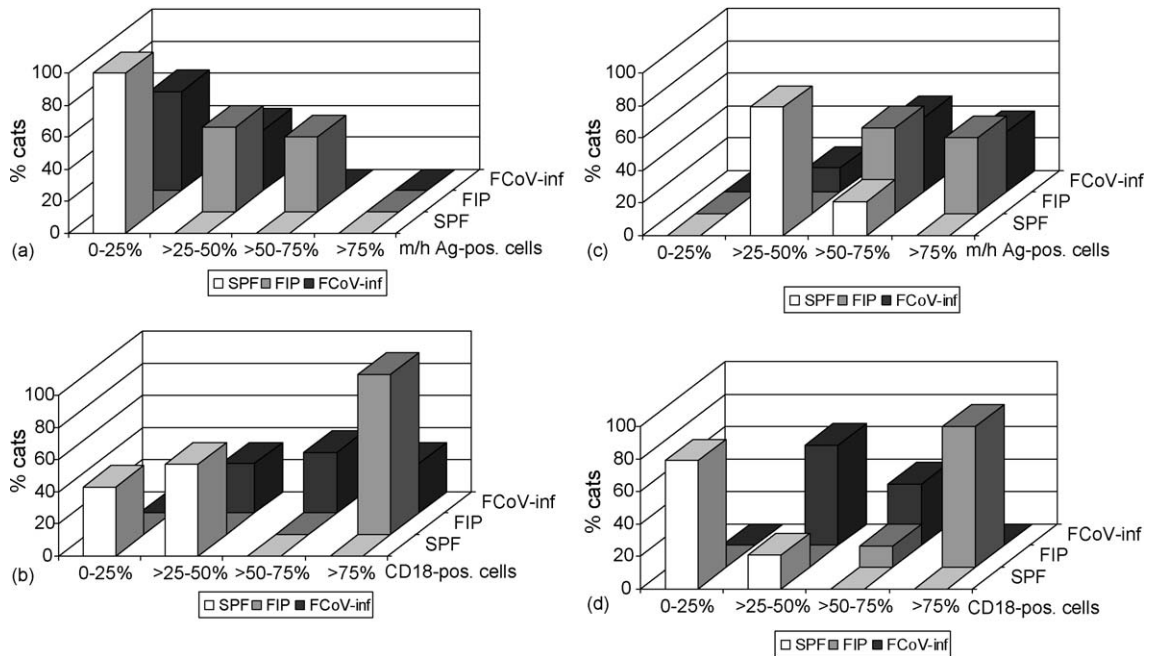


Fig. 1. Comparison of macrophage populations in SPF cats ($n = 14$), cats with FIP ($n = 15$) and FCoV-infected cats without FIP ($n = 13$). (a) Percentage of myeloid/histiocyte antigen-positive cells among cells in the splenic red pulp. (b) Percentage of CD18-positive cells among cells in the splenic red pulp. (c) Percentage of myeloid/histiocyte antigen-positive cells among nucleated cells in the bone marrow. (d) Percentage of CD18-positive cells among nucleated cells in the bone marrow.

FCoV-infected cats without FIP, whereas m/h Ag-positive cells generally represented the dominant cell population in cats with FIP (Fig. 1c). In SPF cats, the amount of CD18-positive cells was rarely above 25%, whereas it ranged between 25% and 75% in FCoV-infected cats without FIP. In cats with FIP, more than 75% of nucleated cells were CD18-positive in the majority of cases (Figs. 1d and 4a and b).

3.2.3. Presence of FCoV antigen

The demonstration of FCoV antigen by IH yielded negative results in haemolymphatic tissues of all cats, except for the granulomatous lesions of cats with FIP (see above).

3.3. Comparison of cytokine transcription levels in spleen, mesenteric lymph nodes and bone marrow

In general, cytokine transcription levels were very variable (Fig. 5).

3.3.1. Spleen

In SPF cats, all cytokines were constitutively transcribed. GM-CSF mRNA was only detected in 43% (6/14), but all other cytokines were detected in more than 60% of the samples. IL-1 β , IL-10, IL-12 p40, TNF and particularly M-CSF were transcribed at relatively high levels (Fig. 5a).

Cats with FIP and FCoV-infected cats without FIP also exhibited constitutive transcription of all cytokines, with lowest rates of detection for GM-CSF (4/13 (31%) FCoV-infected cats without FIP; 9/15 (60%) cats with FIP).

Comparing the three groups of cats, average IL-1 β , IL-10 and TNF transcription levels were highest in FCoV-infected cats without FIP (Fig. 5a). The increase in transcription was significant in the case of IL-10 when comparing the FCoV-infected cats without FIP with the FIP cats (Table 2). In contrast, cats with FIP exhibited the lowest IL-12 p40 and M-CSF transcription levels (Fig. 5a). The reduction in transcription of these cytokines was

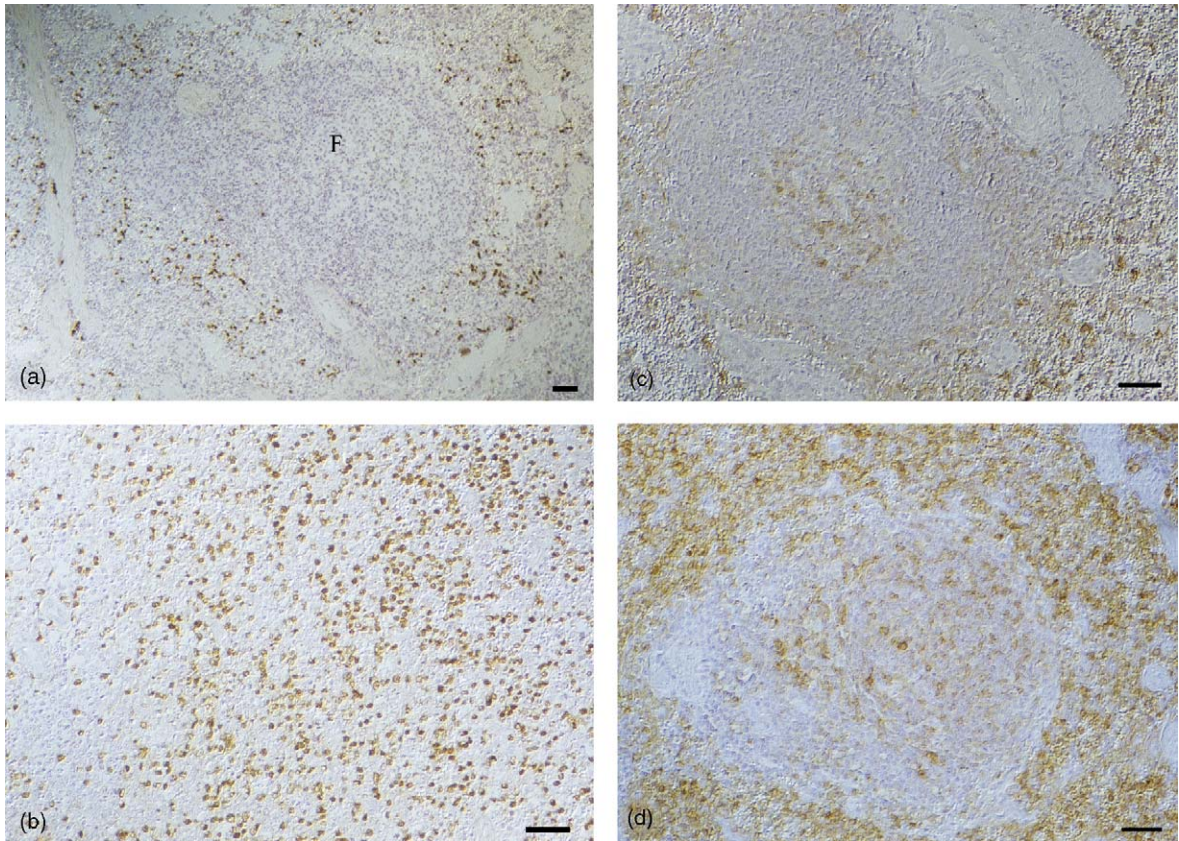


Fig. 2. Spleen. (a) SPF cat. In the red pulp, a few cells express the myeloid/histiocyte antigen. F = follicle. Peroxidase anti-peroxidase method. Papanicolaou's haematoxylin counterstain. Bar = 100 μ m. (b) Cat with FIP. In the red pulp, the vast majority of nucleated cells express the myeloid/histiocyte antigen. Peroxidase anti-peroxidase method. Papanicolaou's haematoxylin counterstain. Bar = 100 μ m. (c) SPF cat. In the red pulp, a few cells express CD18. In the follicle, CD18 expression is restricted to a few cells in the center (follicular dendritic cells). Avidin–biotin peroxidase complex method. Papanicolaou's haematoxylin counterstain. Bar = 100 μ m. (d) Cat with FIP. In the red pulp, the vast majority of nucleated cells express CD18. In the follicle, CD18 expression is restricted to a few cells in the center (follicular dendritic cells). Avidin–biotin peroxidase complex method. Papanicolaou's haematoxylin counterstain. Bar = 100 μ m. (For interpretation of the references to colour in this figure legend, the reader is referred to the web version of the article.)

significant in cats with FIP compared to SPF cats (Table 2).

3.3.2. Mesenteric lymph nodes

In SPF cats, all cytokines were constitutively transcribed, confirmed by demonstration of mRNA in at least 60% of the samples. Highest average transcription levels were observed for TNF, followed by M-CSF (Fig. 5b).

Cats with FIP and FCov-infected cats without FIP also exhibited constitutive transcription of all cytokines, with at least 58% of samples positive for the respective mRNA. Comparing the three

groups of cats, average IL-6, G-CSF and M-CSF transcription levels were lowest in FCov-infected cats without FIP (Fig. 5b). The reduction in transcription of these cytokines was significant in FCov-infected cats without FIP compared to FIP cats (Table 2). In cats with FIP, there was evidence for increased transcription of IL-1 β and M-CSF and decreased transcription of IL-12 p40 and TNF (Fig. 5b). The reduction in IL-12 p40 transcription was significant in comparison to both other groups of cats. The increase in IL-1 β transcription and the decrease in TNF transcription were significant in comparison to SPF cats (Table 2).

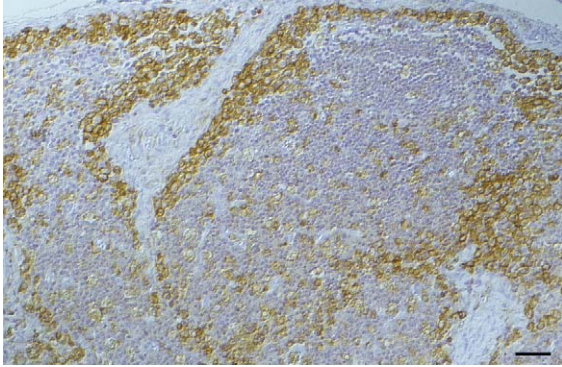


Fig. 3. Cat with FIP. Mesenteric lymph node. Severe sinus histiocytosis. Sinus histiocytes exhibit strong expression of CD18 which is often most intense in the cell periphery. Avidin–biotin peroxidase complex method. Papanicolaou's haematoxylin counterstain. Bar = 100 μ m.

3.3.3. Bone marrow

In SPF cats, constitutive transcription was mainly seen for IL-1 β , IL-10, TNF and M-CSF, as mRNA from all other cytokines was often not detected (Fig. 5c). In general, transcription levels for all cytokines were lower than in the spleen and mes lnn, and IL-6, G-CSF and GM-CSF were transcribed in the lowest amounts.

The overall cytokine transcription pattern was similar in both other groups of cats (Fig. 5c). In FCoV-infected cats without FIP, IL-6 and GM-CSF transcription was not detected at all. Average IL-10 and M-CSF transcription levels were highest in cats with FIP (Fig. 5c). There was no evidence of statistically significant differences in the transcription of cytokines in the bone marrow of the three groups of cats.

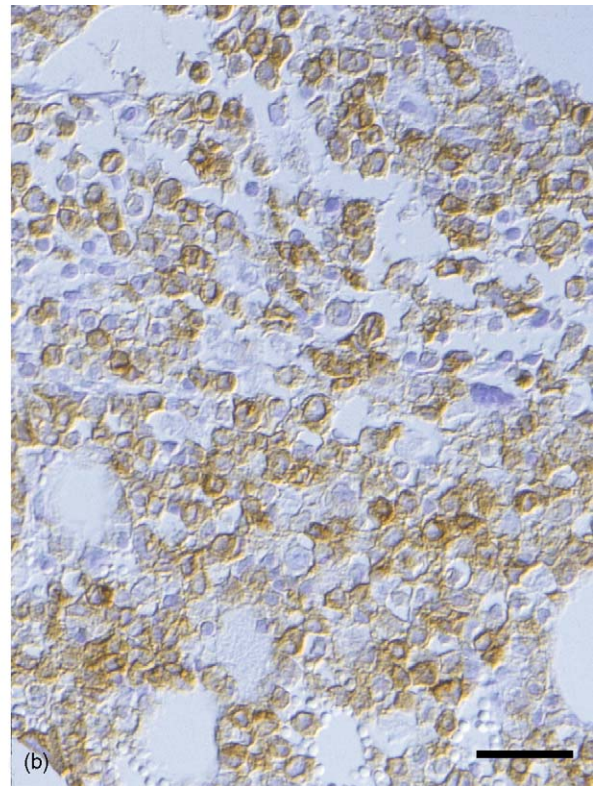


Fig. 4. Bone marrow. (a) SPF cat. Numerous scattered myeloid cells exhibit faint expression of CD18. (b) Cat with FIP. The majority of myeloid cells exhibit strong expression of CD18. Avidin–biotin peroxidase complex method. Papanicolaou's haematoxylin counterstain. Bars = 50 μ m.

Table 2

Statistical analysis of differences in the relative quantity of cytokine transcription levels in the spleen, mesenteric lymph nodes and bone marrow

Organ	Cat group	Compared to cat group	Cytokine	Tendency ^a	Significance (<i>p</i>)
(a) Comparison of cats with FIP, FCoV-infected cats without FIP and SPF cats					
Spleen	FCoV-inf.	FIP	IL-10	↑	<0.05
Spleen	FIP	SPF	M-CSF	↓	<0.05
Mes lnn	FCoV-inf	FIP	IL-6	↓	0.05
Mes lnn	FCoV-inf	FIP	G-CSF	↓	<0.05
Mes lnn	FCoV-inf	FIP	M-CSF	↓	<0.05
Mes lnn	FIP	SPF	IL-12 p40	↓	<0.05
Mes lnn	FIP	FCoV-inf	IL-12 p40	↓	<0.05
Organ			Cytokine	Tendency ^b	Significance (<i>p</i>)
(b) Comparison of cats with FIP and SPF cats					
Spleen			IL-12 p40	↓	<0.05
Spleen			M-CSF	↓	<0.05
Mes lnn			IL-1β	↑	<0.05
Mes lnn			IL-12 p40	↓	<0.01
Mes lnn			TNF	↓	<0.05

^a Tendency = cytokine transcription levels in one group in comparison to another group of cats.^b Tendency = cytokine transcription levels in FIP cats in comparison to SPF cats.

3.4. Relationship between cytokine transcription patterns and type and distribution of FIP lesions or magnitude of monocyte/macrophage populations in cats with FIP

There was no evidence to suggest a relationship between cytokine transcription patterns and type and distribution of FIP lesions or the presence or absence of FIP lesions in the mes lnn and splenic serosa, respectively. Also, there was no distinct evidence of higher transcription levels of any cytokines examined either in the spleen or the mes lnn, of those cats where a cell-rich red pulp or a moderate to intense sinus histiocytosis in the mes lnn were observed.

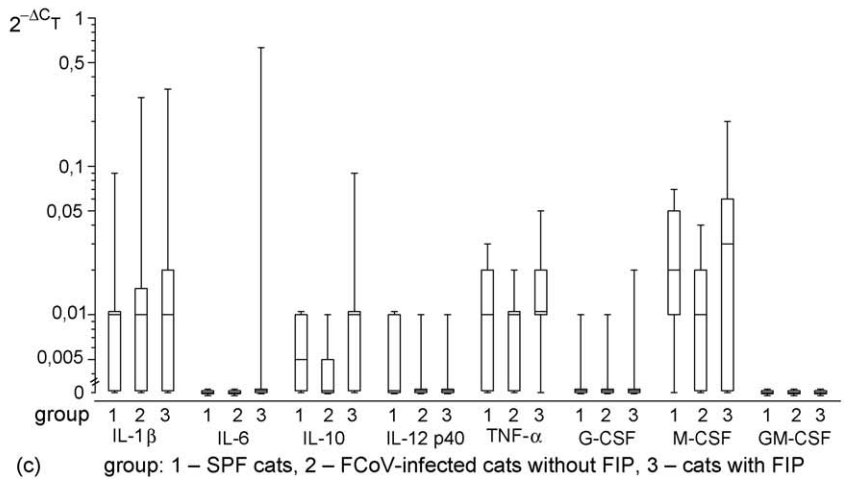
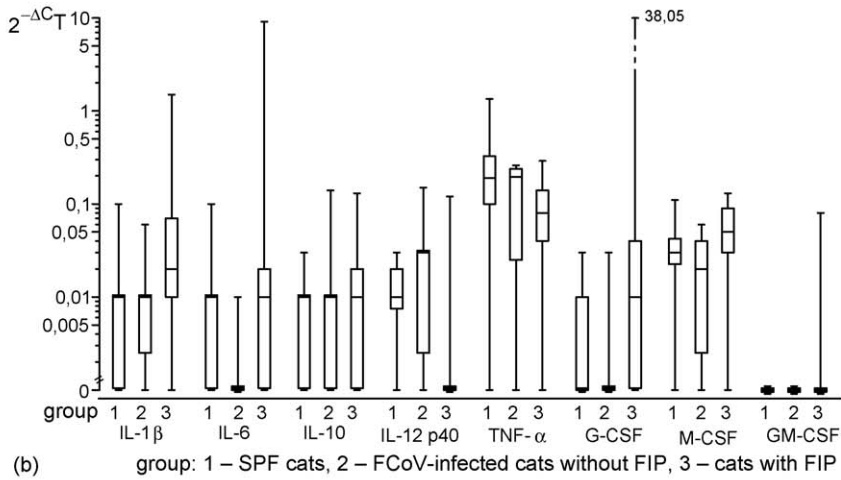
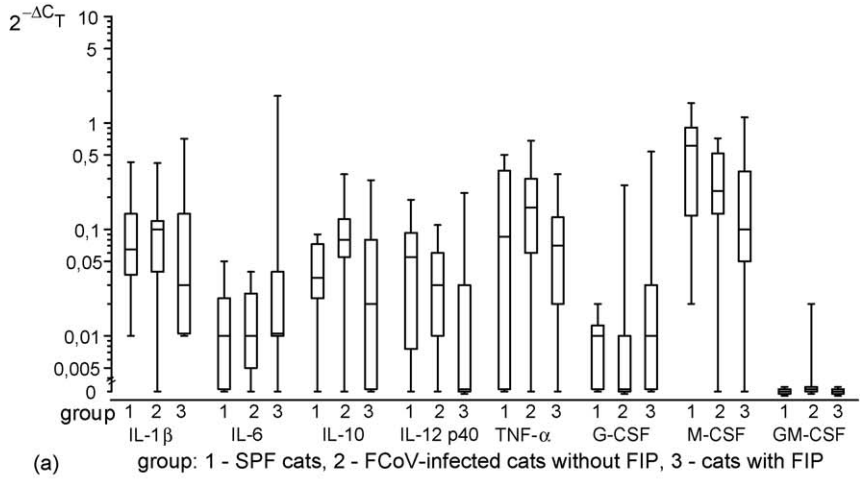
4. Discussion

We have evaluated the activity and composition of haemolymphatic tissues in naturally FCoV-infected cats with particular emphasis on the macrophage population and the transcription levels of cytokines that are produced by, and/or act on, monocytes/macrophages (namely IL-1β, IL-6, IL-10, IL-12 p40, TNF, G-CSF, M-CSF and GM-CSF).

This is the first study to evaluate the constitutive transcription of cytokines in feline haemolymphatic tissues. The spleen, mes lnn and (although at a

generally far lower level) bone marrow constitutively transcribe all cytokines examined, which indicates their role in the homeostatic balance of healthy cats. Although the study was performed on a relatively homogeneous group of young adult SPF cats, high variability in individual transcription levels was observed. A similarly high variability has previously been described in isolated feline monocytes (Kipar et al., 2001b, 2006). Such an obviously wide biological range of cytokine levels renders comparative studies, in particular on natural diseases, difficult. Not unexpectedly, therefore, equally variable cytokine transcription levels were seen in both FCoV-infected cats without FIP (again a relatively homogeneous group of cats with regard to age and previous SPF status) and cats with FIP (a group heterogeneous both in age and background).

The haemolymphatic tissues of both FCoV-infected cats without FIP and cats with FIP exhibited evidence of proliferation and activation of monocytes/macrophages and their precursors. Bone marrow of these two groups contained increased numbers of m/h Ag-positive, myelomonocytic cells (Horny et al., 1990). In particular in cats with FIP, m/h Ag-positive cells were also very numerous in the splenic red pulp, where they represent monocytes or recently blood-derived macrophages (Rugtveit et al., 1996; Kipar et al., 2005). In both organs, the same cell types



exhibited β_2 -integrin upregulation, as shown by increased CD18 expression. In the bone marrow, where increased CD18 expression was most pronounced in cats with FIP, it is a feature of myelomonocytic cell maturation (Kim and Feldman, 2002) and can be induced by cytokines, such as GM-CSF and M-CSF (Aglietta et al., 1993; Kamps et al., 1999). In cats with FIP, the mes lnn exhibited pronounced sinus histiocytosis, again with β_2 -integrin upregulation, represented by intense CD18 expression in particular on the cell surface. Like in the splenic red pulp, this indicates activation of the macrophages (Freyer et al., 1988; Fernandez-Segura et al., 1996). In contrast to the splenic macrophages, the majority of sinus macrophages in the mes lnn were m/h Ag-negative, which suggests they originated from local macrophages and thus proliferated locally, instead of being monocytes recruited into the lymph nodes (Rugtveit et al., 1996). Interestingly, cytokines known to be produced by macrophages and to stimulate macrophages to proliferate and increase in activity, such as G-, M- and GM-CSF, IL-6 and/or TNF (Aglietta et al., 1993; Oriksa et al., 1993; Springer, 1994; Kamps et al., 1999) were not upregulated in either group of cats despite the obvious abundance of activated macrophages in the haemolympathic tissues. Accordingly, a systemic effect seems likely, possibly via cytokines released from circulating monocytes, as they (a) trigger FCoV viraemia, (b) are activated in the course of FIP (Gunn-Moore et al., 1998; Kipar et al., 1999, 2005; Meli et al., 2004) and (c) produce the respective effector cytokines (Clark and Kamen, 1987; Brandt et al., 1988; Sallerfors and Olofsson, 1992; Aglietta et al., 1993; Kerst et al., 1993; Springer, 1994; Kipar et al., 2005).

With regards to the lymphocyte populations and the overall cytokine transcription patterns, however, major differences were seen between the groups of cats. Healthy FCoV-infected cats without FIP exhibited the generalised B and T cell hyperplasia already described in a previous study (Kipar et al., 1999, 2001a) and displayed overall significantly higher IL-

10 levels in the spleen as well as significantly lower IL-6, G-CSF and M-CSF levels in the mes lnn when compared to cats with FIP. Reduced IL-6 and CSF transcription could be an effect of IL-10 which is known to downregulate these cytokines in humans (de Waal Malefyt et al., 1991a; Hannen et al., 1999). IL-10 also inhibits release of other cytokines, such as IL-12, TNF and IL-1 β (de Waal Malefyt et al., 1991a; Koch et al., 1996). This might explain why in FCoV-infected cats without FIP, transcription levels of these cytokines were not significantly higher than in SPF cats despite the abundance of activated macrophages in the tissues (de Waal Malefyt et al., 1991a; Trinchieri, 1993). In a FIP DNA vaccination study where IL-12 was co-expressed with viral antigens, enhanced susceptibility of cats to FIP was observed in the presence of IL-12 (Glansbeek et al., 2002). These findings suggest that prevention of IL-12 release is essential to avoid disease in FCoV-infected cats.

IL-10 reduces the antigen-specific proliferation of T cells by downregulating MHC II expression in monocytes and macrophages (de Waal Malefyt et al., 1991b) which might in FCoV infection limit the specific immune response despite the persistent antigen challenge in the course of prolonged viraemia (Gunn-Moore et al., 1998; Kipar et al., 1999; Meli et al., 2004). IL-10 also stimulates NK cells and upregulates both Fc γ receptor I expression and antibody-dependent cellular cytotoxicity in monocytes (te Velde et al., 1992; Moore et al., 2001). Thus, it might contribute to viral clearance and account for the generally lower viral load observed in healthy FCoV-infected cats in comparison to cats with FIP (Kipar et al., 2006). IL-10 may also contribute to the B cell hyperplasia present in healthy FCoV-infected animals (Kipar et al., 2001a), as it induces both the proliferation of antigen receptor-activated B cells and IFN- γ secretion (Rousset et al., 1992; Lauw et al., 2000). On the other hand, IL-10 downregulates the β_2 -integrin expression in monocytes (Petit-Bertron et al., 2003) which may reduce their capacity to adhere to endothelial cells and thereby to initiate the FIP-

Fig. 5. Box and Whisker plots, demonstrating levels of cytokine transcription in SPF cats, FCoV-infected cats without FIP and cats with FIP. The amount of target was calculated by $2^{-\Delta\text{CT}}$, resulting in evaluation of the experimental samples as an n -fold difference relative to the calibrator fGAPDH (Kipar et al., 2001b). The plots display the range of values, the minimum and maximum, low (first) and high (third) quartiles and the median. (a) Cytokine transcription levels in the spleen; group: (1) SPF cats, (2) FCoV-infected cats without FIP, (3) cats with FIP; (b) cytokine transcription levels in mesenteric lymph nodes; group: (1) SPF cats, (2) FCoV-infected cats without FIP, (3) cats with FIP; (c) cytokine transcription levels in bone marrow; group: (1) SPF cats, (2) FCoV-infected cats without FIP, (3) cats with FIP.

specific vasculitis (Kipar et al., 2005). Taken together, our results indicate that IL-10 is a key cytokine in FCoV infection, ensuring an effective specific immune response, but avoiding the inflammatory processes associated with the development of FIP (Kipar et al., 2005), by inhibiting the virus-induced macrophage activation. In lymphatic tissues, IL-10 is produced by monocytes/macrophages and B and T cells (Benjamin et al., 1992; Moore et al., 1993; Dean et al., 2003). It remains to be clarified which cells in the spleen are responsible for the IL-10 production in FCoV-infected cats without FIP, whether IL-10 upregulation represents a direct viral effect on these cells and which factors determine whether IL-10 is produced or not.

In cats with FIP, lymphatic tissues exhibit generalised T and B cell depletion, albeit with evidence of previous activation (Kipar et al., 2001a), and significantly lower IL-12 p40 transcription levels than both other groups of cats. IL-12 p40, the inducible monomer of IL-12 is secreted predominantly by activated mononuclear phagocytes and dendritic cells (Trinchieri, 1993). The reduced production of IL-12 observed in lymphatic tissues in this and a previous study (Dean et al., 2003), and in brains with FIP lesions (Foley et al., 2003) in the presence of abundant activated macrophages in haemolymphatic tissues and granulomatous infiltrates in cats with FIP indicates impairment of the immune response, in particular of the Th1 response (Trinchieri, 1993; O'Garra, 1998). Monocytes/macrophages produce IL-12 when in contact with activated T cells and under the influence of IFN- γ and GM-CSF in particular (Shu et al., 1995; Kennedy et al., 1996). Interestingly, neither IFN- γ (data not shown) nor GM-CSF were transcribed at lower levels in haemolymphatic tissues of cats with FIP despite the obvious T cell depletion in these animals. Also, IL-10 is obviously not responsible for the reduced IL-12 transcription as overall IL-10 levels were not elevated in cats with FIP (Koch et al., 1996). Results of this investigation are difficult to compare with those of a previous study which examined virus-positive and virus-negative lymphatic tissues of cats with FIP (Dean et al., 2003); there, the presence of virus was associated with increased IL-10 and decreased IL-12 transcription, but potential differences between FCoV-infected cats with and without disease were not assessed. Still, the general T cell

depletion (Haagmans et al., 1996; Kipar et al., 1999, 2001a; de Groot-Mijnes et al., 2005) together with the obvious lack of significant IFN- γ production in organs or lymphatic tissues with FIP lesions (Dean et al., 2003; Foley et al., 2003) indicate impairment of the T cell-mediated macrophage stimulation in FIP. As previous studies did not identify a direct effect of FCoV on T cells (Haagmans et al., 1996; Dean et al., 2003; de Groot-Mijnes et al., 2005), a lack of T cell activation by macrophages has to be considered, possibly due to FCoV-induced impairment of antigen presentation and/or inhibition of IL-12 production by monocytes/macrophages. The latter seems likely due to the fact that FCoV induces high antibody titres (Osterhaus et al., 1977; Kipar et al., 1999; Meli et al., 2004) and that Fc γ ligation can lead to suppression of IL-12 transcription in macrophages (Grazia Cappiello et al., 2001) and indicates direct inhibition of IL-12 production by FCoV.

We also demonstrated significantly reduced TNF transcription, but increased IL-1 β transcription in the mes Inn of cats with FIP in comparison to SPF cats. Considering that both these cytokines are generally released under similar circumstances and have similar functions (Abbas and Lichtman, 2003), a direct, selective effect of FCoV on the function of sinus histiocytes appears likely. Increased IL-1 β production may contribute to both the remittent fever observed in the course of FIP and the systemic changes in cats with FIP, such as the generalised activation of endothelial cells (Dinarelo, 1994; Kipar et al., 2005). The reduced TNF production, however, cannot readily be explained, in particular as a previous study provided evidence of increased TNF production in virus-positive, depleted lymphatic tissue of cats with FIP (Dean et al., 2003).

5. Conclusion

In summary, our findings suggest that, regardless of the development of FIP, FCoV induces proliferation and activation of monocytes/macrophages which is likely mediated by FCoV-infected circulating monocytes. Thereby, a constant supply of cells for viral replication and spread is ensured. In parallel, FCoV provokes a specific systemic immune response. Healthy, long-term FCoV-infected cats mount an

effective T and B cell response with general T and B cell hyperplasia; here, the immune response might be limited by upregulation of IL-10. The presence of FIP lesions, however, is associated with T and B cell depletion and reduced IL-12 production in lymphatic tissues. A lack of IL-12 might be responsible for the obviously impaired cellular immune response and a failure to reduce/limit the viral load in FIP (Kipar et al., 2006). Despite this FIP is associated with general activation of monocytes/macrophages, as reflected by their upregulation of adhesion molecules and cytokine production (Dean et al., 2003; Kipar et al., 2005). This indicates that the development of granulomatous inflammatory processes and fatal FIP are the consequence of exaggerated activation of monocytes/macrophages. The cells that are directly affected by FCoV and the mechanisms that elicit these effects need to be investigated further. It also needs to be clarified whether the virus or the immunophenotype of the individual cat are responsible for the variable effect of FCoV infection on the host's lymphatic tissue. FCoV virulence is associated with deletions in non-structural genes of yet unknown function and increased viral replication (Vennema et al., 1998; Kennedy et al., 2001; Kipar et al., 2006). Further studies have to clarify whether viral gene products interact with effector molecules, such as CD40, CD40 ligand or MHC II, or have a direct effect on gene transcription in infected cells.

Acknowledgements

We wish to thank Dr. M. Linenberger, Division of Hematology, Department of Medicine, University of Washington, USA, for kindly providing the sequence of the feline M-CSF gene to design primers and probes. We are grateful to Dr. C. Leutenegger, Department of Medicine and Epidemiology, School of Veterinary Medicine, University of California, Davis, USA, for his assistance with primer and probe optimisation. Thanks are due to Dr. W. Leukert for the clinical supervision of the FCoV-infected cats without FIP and to Dr. M. Hosie and Prof. O. Jarrett, Department of Veterinary Pathology, University of Glasgow Veterinary School, UK, who kindly provided the SPF cat tissues. Furthermore, we acknowledge the cooperation with Prof. R.M. Bohle and Dr. L. Fink,

Department of Pathology, University of Giessen, Germany, who provided the real time-PCR facilities. Finally, we are most grateful to Mr. A. Barth for excellent and independent technical work. This study was supported by a grant from the Deutsche Forschungsgemeinschaft (KI 617/3).

References

- Abbas, A.K., Lichtman, A.H., 2003. Cytokines. In: *Cellular and Molecular Immunology*, fifth ed. Saunders, Philadelphia, USA, pp. 243–274.
- Addie, D.D., Toth, S., Murray, G., Jarrett, O., 1995. Risk of feline infectious peritonitis in cats naturally infected with feline coronavirus. *Am. J. Vet. Res.* 56, 429–434.
- Aglietta, M., Pasquino, P., Sanavio, F., Stacchini, A., Severino, A., Fubini, L., Morelli, S., Volta, C., Monteverde, A., Piacibello, W., 1993. Granulocyte-macrophage colony stimulating factor and interleukin 3: target cells and kinetics of response in vivo. *Stem Cells* 11 (Suppl. 2), 83–87.
- Benjamin, D., Knobloch, T.J., Dayton, M.A., 1992. Human B-cell interleukin-10: B-cell lines derived from patients with acquired immunodeficiency syndrome and Burkitt's lymphoma constitutively secrete large quantities of interleukin-10. *Blood* 80, 1289–1298.
- Berg, A.L., Ekman, K., Belak, S., Berg, M., 2005. Cellular composition and interferon-gamma expression of the local inflammatory response in feline infectious peritonitis (FIP). *Vet. Microbiol.* 111, 15–23.
- Brandt, S.J., Peters, W.P., Atwater, S.K., Kurtzberg, J., Borowitz, M.J., Jones, R.B., Shpall, E.J., Bast Jr., R.C., Gilbert, C.J., Oette, D.H., 1988. Effect of recombinant human granulocyte-macrophage colony-stimulating factor on hematopoietic reconstitution after high-dose chemotherapy and autologous bone marrow transplantation. *N. Engl. J. Med.* 318, 869–876.
- Clark, S.C., Kamen, R., 1987. The human hematopoietic colony-stimulating factors. *Science* 236, 1229–1237.
- Dean, G.A., Olivry, T., Stanton, C., Pedersen, N.C., 2003. In vivo cytokine response to experimental feline infectious peritonitis virus infection. *Vet. Microbiol.* 97, 1–12.
- de Groot-Mijnes, J.D., van Dun, J.M., van der Most, R.G., de Groot, R.J., 2005. Natural history of a recurrent feline coronavirus infection and the role of cellular immunity in survival and disease. *J. Virol.* 79, 1036–1044.
- de Waal Malefyt, R., Abrams, J., Bennett, B., Figdor, C.G., de Vries, J.E., 1991a. Interleukin 10 (IL-10) inhibits cytokine synthesis by human monocytes: an autoregulatory role of IL-10 produced by monocytes. *J. Exp. Med.* 174, 1209–1220.
- de Waal Malefyt, R., Haanen, J., Spits, H., Roncarolo, M.G., te Velde, A., Figdor, C., Johnson, K., Kastelein, R., Yssel, H., de Vries, J.E., 1991b. Interleukin 10 (IL-10) and viral IL-10 strongly reduce antigen-specific human T cell proliferation by diminishing the antigen-presenting capacity of monocytes via

- downregulation of class II major histocompatibility complex expression. *J. Exp. Med.* 174, 915–924.
- Dinareello, C.A., 1994. The biological properties of interleukin-1. *Eur. Cytokine Netw.* 5, 517–531.
- Dixon, W.J. (Ed.), 1993. *BMDP Statistical Software Manual*, vol. 1 and 2. University of California Press, Berkeley, Los Angeles, Oxford.
- Fernandez-Segura, E., Garcia, J.M., Campos, A., 1996. Topographic distribution of CD18 integrin on human neutrophils as related to shape changes and movement induced by chemotactic peptide and phorbol esters. *Cell. Immunol.* 171, 120–125.
- Foley, J.E., Rand, C., Leutenegger, C., 2003. Inflammation and changes in cytokine levels in neurological feline infectious peritonitis. *J. Fel. Med. Surg.* 5, 313–322.
- Freyer, D.R., Morganroth, M.L., Rogers, C.E., Arnaout, M.A., Todd 3rd, R.F., 1988. Modulation of surface CD11/CD18 glycoproteins (Mo1, LFA-1, p150,95) by human mononuclear phagocytes. *Clin. Immunol. Immunopathol.* 46, 272–283.
- Glansbeek, H.L., Haagmans, B.L., te Lintelo, E.G., Egberink, H.F., Duquesne, V., Aubert, A., Horzinek, M.C., Rottier, P.J.M., 2002. Adverse effects of feline IL-12 during DNA vaccination against feline infectious peritonitis virus. *J. Gen. Virol.* 83, 1–10.
- Grazia Cappiello, M., Sutterwala, F.S., Trinchieri, G., Mosser, D.M., Ma, X., 2001. Suppression of IL-12 transcription in macrophages following Fc gamma receptor ligation. *J. Immunol.* 166, 4498–4506.
- Gunn-Moore, D.A., Gruffydd-Jones, T.J., Harbour, D.A., 1998. Detection of feline coronaviruses by culture and reverse transcriptase-polymerase chain reaction of blood samples from healthy cats and cats with clinical feline infectious peritonitis. *Vet. Microbiol.* 62, 193–205.
- Haagmans, B.T., Egberink, H.F., Horzinek, M.C., 1996. Apoptosis and T-cell depletion during feline infectious peritonitis. *J. Virol.* 70, 8977–8983.
- Hannen, M., Banning, U., Bonig, H., Kim, Y.M., Shin, D.I., Lorenz, I., Seeger, K., Korholz, D., 1999. Cytokine-mediated regulation of granulocyte colony-stimulating factor production. *Scand. J. Immunol.* 50, 461–468.
- Hasegawa, T., Hasegawa, A., 1991. Interleukin 1 alpha mRNA-expressing cells on the local inflammatory response in feline infectious peritonitis. *J. Vet. Med. Sci.* 53, 995–999.
- Hayashi, T., Goto, N., Takahashi, R., Fujiwara, K., 1977. Systemic vascular lesions in feline infectious peritonitis. *Jpn. J. Vet. Sci.* 39, 365–377.
- Horny, H.P., Campbell, M., Steinke, B., Kaiserling, E., 1990. Acute myeloid leukemia: immunohistologic findings in paraffin-embedded bone marrow biopsy specimens. *Hum. Pathol.* 21, 648–655.
- Jacobse-Geels, H.E.L., Daha, M.R., Horzinek, M.C., 1982. Antibody, immune complexes, and complement activity fluctuations in kittens with experimentally induced feline infectious peritonitis. *Am. J. Vet. Res.* 43, 666–670.
- Kamps, A.W., Hendriks, D., Smit, J.W., Vellenga, E., 1999. Role of macrophage colony-stimulating factor in the differentiation and expansion of monocytes and dendritic cells from CD34+ progenitor cells. *Med. Oncol.* 16, 46–52.
- Kennedy, M.K., Picha, K.S., Fanslow, W.C., Grabstein, K.H., Alderson, M.R., Clifford, K.N., Chin, W.A., Mohler, K.M., 1996. CD40/CD40 ligand interactions are required for T cell-dependent production of interleukin-12 by mouse macrophages. *Eur. J. Immunol.* 26, 370–378.
- Kennedy, M., Boedeker, N., Gibbs, P., Kania, S., 2001. Deletions in the 7a ORF of feline coronavirus associated with an epidemic of feline infectious peritonitis. *Vet. Microbiol.* 81, 227–234.
- Kerst, J.M., Slaper-Cortenbach, I.C., van der Schoot, C.E., Hooibrink, B., von dem Borne, A.E., an Oers, R.H., 1993. Interleukin-6 is a survival factor for committed myeloid progenitor cells. *Exp. Haematol.* 21, 1550–1557.
- Kim, J., Feldman, R.A., 2002. Activated Fes protein tyrosine kinase induces terminal macrophage differentiation of myeloid progenitors (U937 cells) and activation of the transcription factor PU.1. *Mol. Cell. Biol.* 22, 1903–1918.
- Kipar, A., Bellmann, S., Kremendahl, J., Köhler, K., Reinacher, M., 1998. Cellular composition, coronavirus antigen expression and production of specific antibodies in lesions in feline infectious peritonitis. *Vet. Immunol. Immunopathol.* 65, 243–257.
- Kipar, A., Bellmann, S., Gunn-Moore, D.A., Leukert, W., Köhler, K., Menger, S., Reinacher, M., 1999. Histopathological alterations of lymphatic tissues in cats without feline infectious peritonitis after long-term exposure to FIP virus. *Vet. Microbiol.* 69, 131–137.
- Kipar, A., Köhler, K., Leukert, W., Reinacher, M., 2001a. Evaluation of lymphatic tissue activity in cats with spontaneous feline infectious peritonitis. *J. Comp. Path.* 125, 182–191.
- Kipar, A., Leutenegger, C.M., Hetzel, U., Akens, M.K., Mislin, C.N., Reinacher, M., Lutz, H., 2001b. Cytokine mRNA levels in isolated feline monocytes. *Vet. Immunol. Immunopathol.* 78, 305–315.
- Kipar, A., May, H., Menger, S., Weber, M., Leukert, W., Reinacher, M., 2005. Morphological features and development of granulomatous vasculitis in feline infectious peritonitis. *Vet. Pathol.* 42, 321–330.
- Kipar, A., Baptiste, K., Barth, A., Reinacher, M., 2006. Natural FCoV infection: cats with FIP exhibit significantly higher viral loads than healthy infected cats. *J. Fel. Med. Surg.* 8, 69–72.
- Koch, F., Stanzl, U., Jennewein, P., Janke, K., Heufler, C., Kapgen, E., Romani, N., Schuler, G., 1996. High level IL-12 production by murine dendritic cells: upregulation via MHC class II and CD40 molecules and downregulation by IL-4 and IL-10. *J. Exp. Med.* 184, 741–746.
- Lauw, F.N., Pajkrt, D., Hack, C.E., Kurimoto, M., van Deventer, S.J., van der Poll, T., 2000. Proinflammatory effects of IL-10 during human endotoxemia. *J. Immunol.* 165, 2783–2789.
- Leutenegger, C.M., Mislin, C.N., Sigrist, B., Ehrenguber, M.U., Hofmann-Lehmann, R., Lutz, H., 1999. Quantitative real-time PCR for the measurement of feline cytokine mRNA. *Vet. Immunol. Immunopathol.* 71, 291–305.
- Meli, M., Kipar, A., Müller, C., Jenal, K., Gönczi, E.-E., Borel, N., Gunn-Moore, D., Chalmers, S., Lin, F., Reinacher, M., Lutz, H., 2004. High viral loads despite absence of clinical and pathological findings in cats experimentally infected with feline coronavirus (FCoV) type I and in naturally FCoV-infected cats. *J. Fel. Med. Surg.* 6, 69–81.

- Moore, K.W., O'Garra, A., de Waal Malefyt, R., Vieira, P., Mosmann, T.R., 1993. Interleukin-10. *Annu. Rev. Immunol.* 11, 165–190.
- Moore, K.W., de Waal Malefyt, R., Coffman, R.L., O'Garra, A., 2001. Interleukin-10 and the interleukin-10 receptor. *Annu. Rev. Immunol.* 19, 683–765.
- O'Garra, A., 1998. Cytokines induce the development of functionally heterogeneous T helper cell subsets. *Immunity* 8, 275–283.
- Orikasa, M., Kawase, T., Suzuki, A., 1993. Induction of macrophagic and granulocytic differentiation of murine bone marrow progenitor cells by 1,25-dihydroxyvitamin D₃. *Calcif. Tissue Int.* 53, 193–200.
- Osterhaus, A.D.M.E., Horzinek, D.J., Reynolds, D.J., 1977. Seropidemiology of feline infectious peritonitis using transmissible gastroenteritis virus antigen. *J. Vet. Med. B* 24, 835–841.
- Pedersen, N.C., 1995. An overview of feline enteric coronavirus and infectious peritonitis virus infections. *Feline Pract.* 23, 7–20.
- Petit-Bertron, A.F., Fitting, C., Cavaillon, J.M., Adib-Conquy, M., 2003. Adherence influences monocyte responsiveness to interleukin-10. *J. Leukoc. Biol.* 73, 145–154.
- Rousset, F., Garcia, E., Defrance, T., Peronne, C., Vezzio, N., Hsu, D.H., Kastelein, R., Moore, K.W., Banchereau, J., 1992. Interleukin 10 is a potent growth and differentiation factor for activated human B lymphocytes. *Proc. Natl. Acad. Sci. USA* 89, 1890–1893.
- Rugtveit, J., Scott, H., Halstensen, T.S., Norstein, J., Brandtzig, P., 1996. Expression of the L1 antigen (calprotectin) by tissue macrophages reflects recent recruitment from peripheral blood rather than upregulation of local synthesis: implications for rejection diagnosis in formalin-fixed kidney specimens. *J. Pathol.* 180, 194–199.
- Sallerfors, B., Olofsson, T., 1992. Granulocyte-macrophage colony-stimulating factor (GM-CSF) and granulocyte colony-stimulating factor (G-CSF) secretion by adherent monocytes measured by quantitative immunoassays. *Eur. J. Haematol.* 49, 199–207.
- Shu, U., Kiniwa, M., Wu, C.Y., Maliszewski, C., Vezzio, N., Hakimi, J., Gately, M., Delespesse, G., 1995. Activated T cells induce interleukin-12 production by monocytes via CD40-CD40 ligand interaction. *Eur. J. Immunol.* 25, 1125–1128.
- Springer, T.A., 1994. Traffic signals for lymphocyte recirculation and leukocyte emigration: the multistep paradigm. *Cell* 76, 301–314.
- te Velde, A.A., de Waal Malefyt, R., Huijbens, R.J., de Vries, J.E., Figdor, C.G., 1992. IL-10 stimulates monocyte Fc gamma R surface expression and cytotoxic activity. Distinct regulation of antibody-dependent cellular cytotoxicity by IFN-gamma, IL-4, and IL-10. *J. Immunol.* 149, 4048–4052.
- Trinchieri, G., 1993. Interleukin-12 and its role in the generation of TH1 cells. *Immunol. Today* 14, 335–338.
- Vennema, H., Poland, A., Foley, J., Pedersen, N.C., 1998. Feline infectious peritonitis viruses arise by mutation from endemic feline enteric coronaviruses. *Virology* 243, 150–157.
- Weiss, R.C., Scott, F.W., 1981. Pathogenesis of feline infectious peritonitis: pathologic changes and immunofluorescence. *Am. J. Vet. Res.* 4, 2036–2048.