

Malignant Subdural Hematoma Associated with High-Grade Meningioma

Shinichiro Teramoto, MD¹ Akira Tsunoda, MD¹ Kaito Kawamura, MD¹ Natsuki Sugiyama, MD¹
Rikizo Saito, MD¹ Chikashi Maruki, MD¹

¹ Department of Neurosurgery, Koshigaya Municipal Hospital, Saitama, Japan

Surg J 2018;4:e91–e95.

Address for correspondence Shinichiro Teramoto, MD, Department of Neurosurgery, Koshigaya Municipal Hospital, 10-47-1 Higashikoshigaya, Koshigaya City, Saitama 343-0023, Japan (e-mail: tera.2@hotmail.co.jp).

Abstract

A 70-year-old man, who had previously undergone surgical resection of left parasagittal meningioma involving the middle third of the superior sagittal sinus (SSS) two times, presented with recurrence of the tumor. We performed removal of the tumor combined with SSS resection as Simpson grade II. After tumor removal, since a left dominant bilateral chronic subdural hematoma (CSDH) appeared, it was treated by burr hole surgery. However, because the CSDH rapidly and repeatedly recurred and eventually changed to acute subdural hematoma, elimination of the hematoma with craniotomy was accomplished. The patient unfortunately died of worsening of general condition despite aggressive treatment. Histopathology of brain autopsy showed invasion of anaplastic meningioma cells spreading to the whole outer membrane of the subdural hematoma. Subdural hematoma is less commonly associated with meningioma. Our case indicates the possibility that subdural hematoma associated with meningioma is formed by a different mechanism from those reported previously.

Keywords

- ▶ high-grade meningioma
- ▶ recurrent chronic subdural hematoma
- ▶ outer membrane of subdural hematoma

The incidence of recurrent chronic subdural hematoma (CSDH) accounts for ~5 to 33% of postsurgical cases.¹ CSDH recurs most frequently between 1 and 3 months after surgery.¹ Early recurrence of CSDH is determined as relapse of symptoms or re-accumulation of the hematoma within 3 months following surgery.¹ There are many etiologies for recurrence of CSDH.^{1,2} Subdural hematoma is a less frequent complication in meningioma.³ Besides, CSDH is rarely associated with meningioma.³ ▶ **Table 1** summarizes previously reported cases of meningioma in association with CSDH.^{3–18} Although several mechanisms to cause subdural hematoma in meningioma have been previously reported,^{3,15,19} our case suggested a different mechanism from them. We describe a case of malignant subdural hematoma that rapidly and repeatedly recurred in association with meningioma.

Case Report

A 70-year-old man, who had previously undergone surgical resection of left parasagittal meningioma involving the

middle third of the superior sagittal sinus (SSS) two times, presented with right lower limb weakness. The first and second removals of the tumor via open surgery remained as Simpson grade IV because of hardening of the tumor and adhesion to surrounding structures including the SSS. The remaining tumor massively recurred within 1 year after the last discharge despite γ -knife radiosurgery following the second tumor removal (▶ **Fig. 1a–c**). We attempted removal of the tumor combined with SSS resection because obstruction of the SSS caused by the developed tumor was confirmed. The tumor was consequently removed as Simpson grade II. The residual tumor, including the dural tail sign, was not observed on postoperative magnetic resonance imaging (▶ **Fig. 1d–f**). The third histopathological result showed an atypical meningioma, World Health Organization (WHO) grade II. Postoperatively the patient was transferred to a rehabilitation hospital.

The patient who manifested a progressive headache was readmitted with a diagnosis of left dominant bilateral CSDH 1 month after removal of the tumor (▶ **Fig. 2a**). He had no

received
March 6, 2018
accepted after revision
May 1, 2018

DOI <https://doi.org/10.1055/s-0038-1660511>
ISSN 2378-5128.

Copyright © 2018 by Thieme Medical Publishers, Inc., 333 Seventh Avenue, New York, NY 10001, USA.
Tel: +1(212) 584-4662.

License terms



Table 1 Summary of previously reported cases of meningioma associated with chronic subdural hematoma

No.	Author	Year	Sex	Age	CSDH		Meningioma		
					Side	Side	Location	Histology	Outcome
1	Cusick and Bailey ⁴	1972	F	47	Bilateral	Right	Convexity	Transitional	Dead
2	Modesti et al ⁵	1976	F	49	Left	Left	Parasagittal	Meningothelial	SD
			M	69	Left	Left	Convexity	Meningothelial	GR
3	Walsh et al ⁶	1977	F	77	Right	Right	Olfactory groove	Meningothelial	Dead
4	Sakai et al ⁷	1981	M	36	Right	Right	Sphenoid ridge	Meningothelial	Dead
5	Baskinis et al ⁸	1984	M	68	Right	Right	Convexity	Angiomatous	GR
6	Tomita et al ⁹	1985	F	61	Right	Right	Convexity	Meningothelial	GR
7	Wang et al ¹⁰	1985	F	62	Left	Left	Convexity	N/A	N/A
8	Itoyama et al ¹¹	1987	F	63	Bilateral	Left	Sphenoid ridge	Transitional	GR
9	Chen et al ¹²	1992	M	79	Left	Left	Convexity	Meningothelial	MD
10	Pozzi et al ¹³	1993	F	73	Left	Left	Convexity	Transitional	N/A
			F	85	Left	Left	Convexity	N/A	N/A
11	Popovic et al ¹⁴	1994	F	47	Right	Right	Convexity	Meningothelial	N/A
12	Tanaka et al ¹⁵	1994	F	47	Right	Right	Convexity	Meningothelial	GR
13	Sinha and Dharker ¹⁶	2001	M	68	Left	Right	Convexity	N/A	GR
			F	70	Left	Right	Convexity	N/A	GR
14	Di Rocco et al ³	2006	M	72	Right	Right	Convexity	Meningothelial	GR
			M	74	Left	Left	Convexity	Transitional	GR
15	Czyz et al ¹⁷	2011	F	69	Bilateral	Bilateral	Parasagittal	N/A	GR
16	Nery et al ¹⁸	2017	F	85	Left	Left	Convexity	Microcystic	GR

Abbreviations: CSDH, chronic subdural hematoma; GR, good recovery; MD, moderate disability; N/A, not applicable; SD, severe disability.

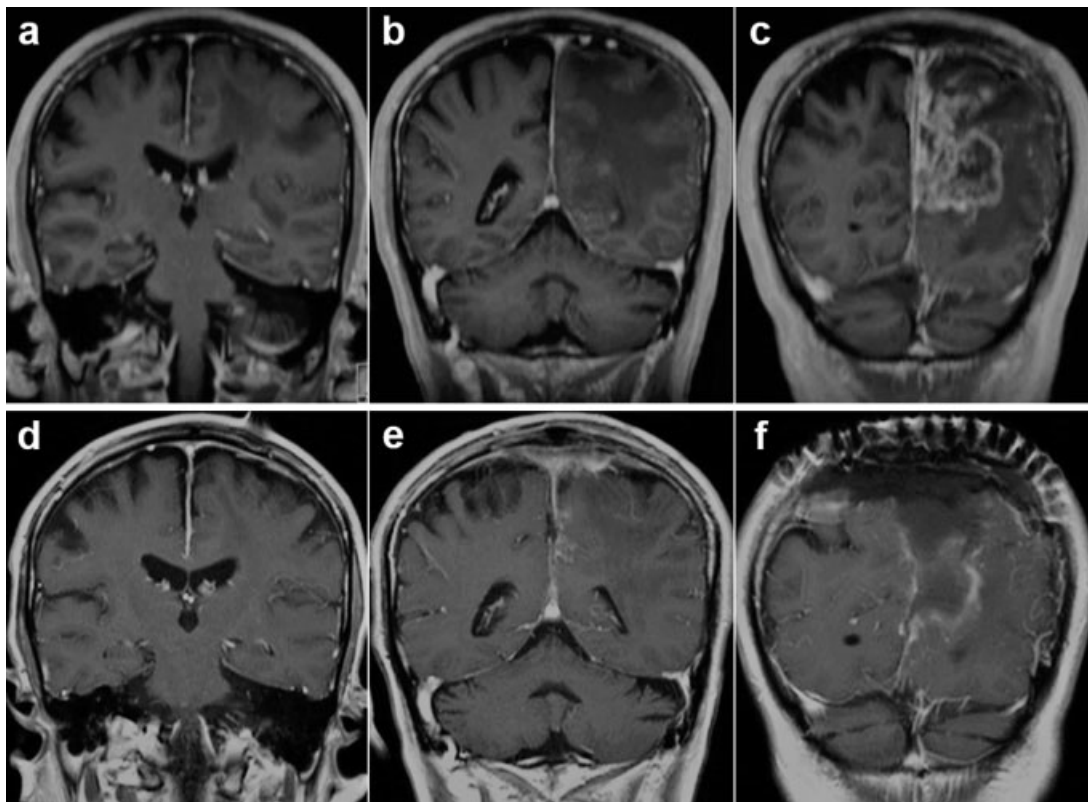


Fig. 1 (a–c) Preoperative MRI showing recurrent left parasagittal meningioma located in the middle third of the superior sagittal sinus. (d–f) Postoperative MRI showing tumor removal combined with superior sagittal sinus resection as Simpson grade II without distinct dural tail sign. MRI, magnetic resonance imaging.

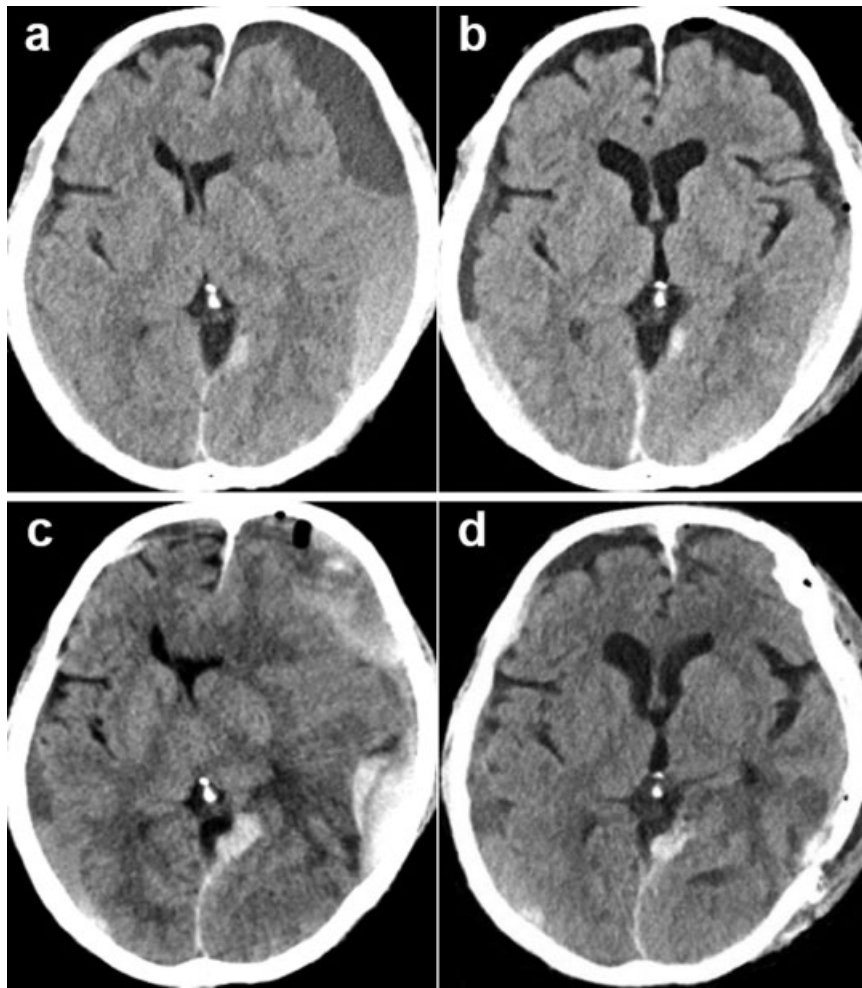


Fig. 2 (a) CT on the readmission showing left dominant bilateral CSDH appeared after tumor removal. (b) Postoperative CT of the first burr hole surgery showing resolution of CSDH. (c) Preoperative CT of hematoma elimination with craniotomy showing left acute subdural hematoma changed from repeatedly recurrent CSDH. (d) Postoperative CT of craniotomy showing elimination of acute subdural hematoma. CSDH, chronic subdural hematoma; CT, computed tomography.

clinical history, such as head injury, antithrombotic therapy, coagulation disorders, and alcohol abuse. In addition, postoperative images revealed no signs of CSDH. The left subdural hematoma alone was treated by burr hole surgery, which was successful (►Fig. 2b). However, recurrence of CSDH occurred 5 days after surgery. Although a second burr hole evacuation of subdural hematoma was performed, a third evacuation was required owing to its rapid recurrence within 2 days after the second evacuation. Because CSDH eventually changed to acute subdural hematoma (►Fig. 2c), craniotomy was accomplished 10 days after the third hematoma evacuation (►Fig. 2d). The hematoma and outer membrane of the subdural hematoma were eliminated as much as possible. Furthermore, the dura mater within the craniotomy area was removed and replaced with artificial dura mater. Histopathological features of the outer membrane of the subdural hematoma showed anaplastic meningioma, WHO grade III. Unfortunately, the patient died of worsening of general condition despite aggressive treatment one and a half months since the onset of CSDH although the subdural hematoma had obviously not recurred. His brain was inves-

tigated by autopsy after death. Histopathology of brain autopsy demonstrated invasion of anaplastic meningioma cells spreading to the whole outer membrane of the subdural hematoma (►Fig. 3).

Discussion

Numerous causative factors for recurrence of CSDH have been addressed including advanced age, antithrombotic medications, coagulopathy, and various neuroimaging features of hematoma.^{1,2} Although subdural hematoma formation in meningioma is rare, several mechanisms have been proposed as follows^{3,15,19}: (1) bleeding of the tumor into the subdural space, (2) rupture of abnormal vascular networks supplying the tumor in the subdural space, and (3) collapse of the subdural vessels due to compression of the tumor.

No correlation between the occurrence of subdural hematoma and the location or histological characteristics of meningioma has been described.^{15,20} On the other hand, the malignant histological type has been reported with a high frequency in meningioma complicated with subdural

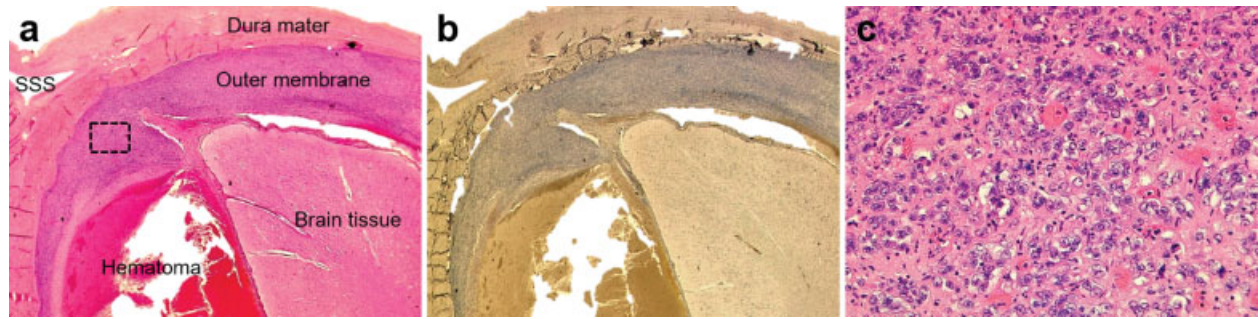


Fig. 3 Histopathological photomicrograph of the brain autopsy. (a) H&E stain and (b) epithelial membrane antigen immunostain of coronal brain section showing the outer membrane of the subdural hematoma entirely infiltrated by meningioma cells. Magnification, $\times 10$. (c) High-magnification image of the black dotted square box of the H&E stain revealing high cellular density, nuclear polymorphisms, and numerous mitoses, indicating anaplastic meningioma. Magnification, $\times 400$. H&E, hematoxylin and eosin; SSS, superior sagittal sinus.

hematoma.^{15,20} Patil observed that a dural reaction of the meningioma formed the neomembrane similar to the outer membrane of CSDH despite neither subdural fluid collection nor blood clots.²¹ Moreover, they noticed that tumor cells were not expressed in the neomembrane originating from the meningioma.²¹ In our case, the outer membrane of the subdural hematoma was entirely infiltrated by meningioma cells. To the best of our knowledge, no previous report has mentioned similar findings to our case. Meningioma with malignant transformation is indicated to acquire hematogenous spread.²² The outer membrane of CSDH is highly vascularized and enriched with numerous capillaries.¹ Invasion of meningioma cells might occur hematogenously to the outer membrane of CSDH. Otherwise, meningioma in our case might have had capsule-like growth along the dura as en plaque meningioma. Formation of subdural hematoma related to a malignant tumor is considered to be the result of capillary dilatation and rupture of the outer membrane via fine vessel obstruction by tumor cells.²³ In high-grade meningioma, vascular endothelial growth factor (VEGF) is expressed and involved in permeabilization of blood vessels as well as tumor angiogenesis and vasculogenesis.²⁴ VEGF is detected in the outer membrane of CSDH and has an association with expansion of hematoma and recurrent bleeding.²⁵ Therefore, disruption of vulnerable tumor vessels or the effect of VEGF may allow the outer membrane infiltrated by meningioma cells to exude the hematoma into the subdural space.

An effective treatment strategy for subdural hematoma associated with meningioma is the elimination of hematoma at the same time as removal of the tumor.^{19,26} Early surgical intervention is advocated, especially in cases accompanying acute subdural hematoma.²⁰ Our case had rapid and repeated recurrence of subdural hematoma despite prompt evacuation of the hematoma, eventually leading to death. Removal of the outer membrane surrounding subdural hematoma is presently not regarded as important.¹ However, the prognosis of our patient might have been improved by early removal of not only the hematoma but also as much of the outer membrane as possible.

In the case of CSDH associated with meningioma, especially high-grade meningioma, histopathological features of

the outer membrane of subdural hematoma should be investigated. The subdural hematoma needs to be treated with caution when tumor infiltration is demonstrated in the outer membrane.

Conflicts of Interest

None.

Acknowledgments

None.

References

- 1 Yadav YR, Parihar V, Namdev H, Bajaj J. Chronic subdural hematoma. *Asian J Neurosurg* 2016;11(04):330–342
- 2 Yamamoto H, Hirashima Y, Hamada H, Hayashi N, Origasa H, Endo S. Independent predictors of recurrence of chronic subdural hematoma: results of multivariate analysis performed using a logistic regression model. *J Neurosurg* 2003;98(06):1217–1221
- 3 Di Rocco F, Mannino S, Puca A, Lauriola L, Pompucci A. Intracranial meningiomas associated with non-traumatic chronic subdural hematoma. *Acta Neurochir (Wien)* 2006;148(10):1097–1102, discussion 1102
- 4 Cusick JF, Bailey OT. Association of ossified subdural hematomas and a meningioma. Case report. *J Neurosurg* 1972;37(06):731–734
- 5 Modesti LM, Binet EF, Collins GH. Meningiomas causing spontaneous intracranial hematomas. *J Neurosurg* 1976;45(04):437–441
- 6 Walsh JW, Winston KR, Smith T. Meningioma with subdural hematoma. *Surg Neurol* 1977;8(04):293–295
- 7 Sakai N, Ando T, Yamada H, Ikeda T, Shimokawa K. [Meningioma associated with subdural hematoma—report of a case and review of 15 reported cases (author's transl)]. *Neurol Med Chir (Tokyo)* 1981;21(03):329–336
- 8 Baskinis N, Grotenhuis A, Wandt H. Chronic subdural hematoma associated with an intracapsular meningioma. Case report and short review of the literature. *J Neurosurg Sci* 1984;28(01):17–23
- 9 Tomita Y, Kikuchi Y, Nanami T, Furukawa K, Onodera E, Kanaya H. [A case of convexity meningioma associated with chronic subdural hematoma]. *No Shinkei Geka* 1985;13(10):1115–1119
- 10 Wang AM, Chinwuba CE, O'Reilly GV, Kleeffeld J. Subdural hematoma in patients with brain tumor: CT evaluation. *J Comput Assist Tomogr* 1985;9(03):511–513
- 11 Itoyama Y, Fukumura A, Itoh Y, Urasaki E, Koga K. [Primary brain tumor complicating subdural hematoma]. *No To Shinkei* 1987;39(12):1157–1161

- 12 Chen JW, U HS, Grafe MR. Unsuspected meningioma presenting as a subdural haematoma. *J Neurol Neurosurg Psychiatry* 1992;55(02):167–168
- 13 Pozzi M, Dario A, Marra A, Scamoni C, Dorizzi A. Associated chronic subdural haematoma and meningeal neoplasm. Two case reports. *J Neurosurg Sci* 1993;37(02):113–117
- 14 Popovic EA, Lyons MK, Scheithauer BW, Marsh WR. Mast cell-rich convexity meningioma presenting as chronic subdural hematoma: case report and review of the literature. *Surg Neurol* 1994;42(01):8–13
- 15 Tanaka N, Yamamoto M, Jimbo M, Ide M, Kubo O. Meningioma associated with chronic subdural hematoma and meningothelial cell cluster within the hematoma capsule—case report. *Neurol Med Chir (Tokyo)* 1994;34(03):176–179
- 16 Sinha VD, Dharker SR. Meningioma associated with contralateral chronic subdural haematoma: a short report. *Neurol India* 2001;49(02):204–206
- 17 Czyż M, Jarmundowicz W, Szarek D, Tabakow P, Markowska-Wojciechowska A. Bilateral chronic subdural haematomas in a patient with meningioma of the superior sagittal sinus - case report and pathophysiological study. *Neurol Neurochir Pol* 2011;45(05):500–504
- 18 Nery B, Costa RAF, Pereira LCT, et al. Spontaneous subdural hematoma associated with microcystic meningioma: first case report in the literature. *Br J Neurosurg* 2017:1–4
- 19 Lefranc F, Nagy N, Dewitte O, Balériaux D, Brotchi J. Intracranial meningiomas revealed by non-traumatic subdural haematomas: a series of four cases. *Acta Neurochir (Wien)* 2001;143(10):977–982, discussion 982–983
- 20 Chaskis C, Raftopoulos C, Noterman J, Flament-Durand J, Brotchi J. Meningioma associated with subdural haematoma: report of two cases and review of the literature. *Clin Neurol Neurosurg* 1992;94(03):269–274
- 21 Patil AA. Intracranial meningioma with subdural membrane. A case report. *Acta Neurochir (Wien)* 1982;66(1-2):103–107
- 22 Enam SA, Abdulrauf S, Mehta B, Malik GM, Mahmood A. Metastasis in meningioma. *Acta Neurochir (Wien)* 1996;138(10):1172–1177, discussion 1177–1178
- 23 Kimura S, Kotani A, Takimoto T, Yoshino A, Katayama Y. Acute aggravation of subdural fluid collection associated with dural metastasis of malignant neoplasms: case report and review of the literature. *Brain Tumor Pathol* 2014;31(04):299–303
- 24 Reszec J, Hermanowicz A, Rutkowski R, Turek G, Mariak Z, Chyczewski L. Expression of MMP-9 and VEGF in meningiomas and their correlation with peritumoral brain edema. *BioMed Res Int* 2015;2015:646853
- 25 Hong HJ, Kim YJ, Yi HJ, Ko Y, Oh SJ, Kim JM. Role of angiogenic growth factors and inflammatory cytokine on recurrence of chronic subdural hematoma. *Surg Neurol* 2009;71(02):161–165, discussion 165–166
- 26 Bosnjak R, Derham C, Popović M, Ravnik J. Spontaneous intracranial meningioma bleeding: clinicopathological features and outcome. *J Neurosurg* 2005;103(03):473–484