



## Case study

## Neonatal encephalitis due to Chikungunya vertical transmission: First report in Brazil



Antonio Carlos Bandeira, MD MPH, Infectious Diseases Associate Professor<sup>a,\*</sup>,  
 Gubio Soares Campos, Ph.D., Head<sup>b</sup>, Silvia Ines Sardi, Ph.D.<sup>b</sup>,  
 Veronica França Diniz Rocha, MD, Hospital Infection Control Committee<sup>c</sup>,  
 Guilherme Cesar Mendes Rocha, MD, Neuroradiologist<sup>d</sup>

<sup>a</sup> Faculdade de Tecnologia e Ciências Medical School, Av. Luís Viana, 8812, Salvador – Bahia, Brazil

<sup>b</sup> Federal University of Bahia, Virology Laboratory, Brazil

<sup>c</sup> Hospital Geral Roberto Santos, Salvador, Brazil

<sup>d</sup> Hospital Aliança, Salvador, Brazil

## ARTICLE INFO

## Article history:

Received 29 June 2016

Received in revised form 19 July 2016

Accepted 19 July 2016

## Keywords:

Chikungunya-associated encephalitis

Chikungunya neonatal

Neurological syndromes

Neonatal encephalitis

Vertical transmission.

## ABSTRACT

**Purpose:** To report the first case of Chikungunya encephalitis acquired in the perinatal period during the current outbreak in Brazil

**Methods:** Case report.

**Results:** A male neonate with 3500 g developed macular erythematous rash, hypoactivity and fever progressing to generalized seizures. His mother had experienced a disseminated rash and fever before delivery. EEG showed diffuse slowing and cranial NMR was suggestive of encephalitis. Rt-PCR for Chikungunya virus (CHIKV) was positive in cerebrospinal fluid (CSF), blood, urine and saliva. The newborn was discharged home with neurological improvement.

**Conclusion:** We report the first case of a perinatal CHIKV infection associated with a rapidly evolving encephalitis and an extensive dissemination of the virus as documented by positive rt-PCR results in CSF, blood, urine and saliva in the present outbreak in Brazil. In countries experiencing outbreaks of CHIKV infections, clinicians and neonatologists must be familiar with the possibility of the occurrence of neurologic complications and its possible consequences.

© 2016 The Authors. Published by Elsevier Ltd. This is an open access article under the CC BY-NC-ND license (<http://creativecommons.org/licenses/by-nc-nd/4.0/>).

## Why this case is important

CHIKV is a RNA virus belonging to the Alphavirus Family and transmitted by *Aedes* mosquitoes. The disease is usually manifested as fever, arthralgia and rash.

In 2014 the first autochthonous cases of CHIKV in Brazil were confirmed and, since then, the disease has spread throughout the country [1].

Neurological complications are rare but have been increasingly reported in newborns and adults.

Neurocognitive outcomes in neonates exposed to perinatal CHIKV infections have revealed neurodevelopmental delays, cerebral palsies and microcephaly [2].

And vertical transmission has been implicated in nine cases of CHIKV encephalopathy in the La Reunion Island in 2005–2006 [3].

This case reveals the potential of a serious neurological involvement in a newborn with acute CHIKV acquired in the perinatal period and represents the first description of neonatal CHIKV-encephalitis in Brazil since the start of the outbreak.

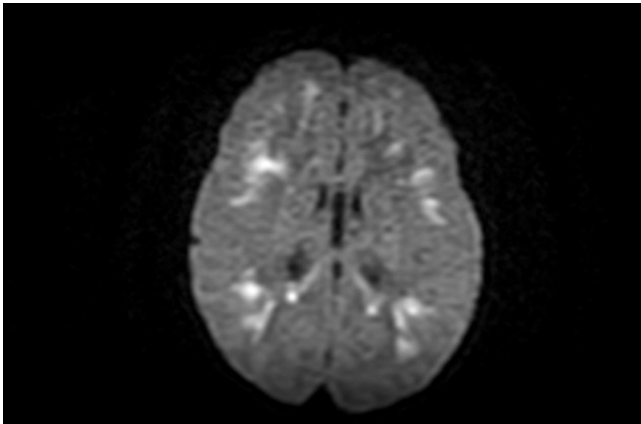
## Case description

LCVA, 35 yr-old, gave birth in November 24th, 2015 of a male neonate with 3500 g, cephalic perimeter of 34.0 cm and with normal vital signs at Hospital Aliança, a 210 bed tertiary hospital in Salvador, Brazil. Antenatal visits were normal except for reporting that four days before a C-section delivery she experienced a disseminated rash and fever with dengue serology positive for IgG and negative for IgM.

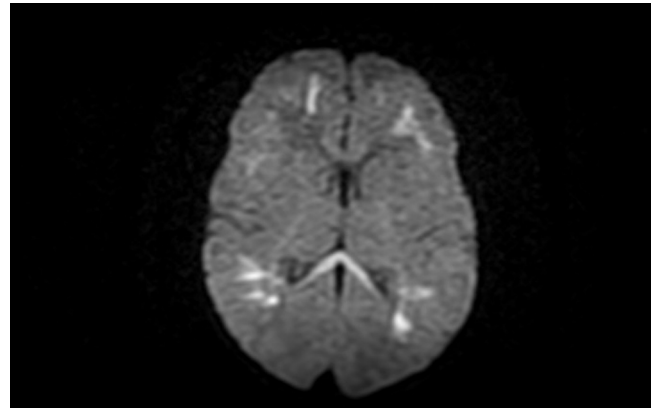
The neonate was doing well until November 28th when the newborn developed a macular erythematous rash, hypoactivity and temperature of 37.9 °C. On November 30th, the neonate began

\* Corresponding author.

E-mail addresses: [antoniobandeira@gmail.com](mailto:antoniobandeira@gmail.com) (A.C. Bandeira), [gubiosoaes@gmail.com](mailto:gubiosoaes@gmail.com) (G.S. Campos), [sissardi@yahoo.com.br](mailto:sissardi@yahoo.com.br) (S.I. Sardi), [veronica.diniz.rocha@gmail.com](mailto:veronica.diniz.rocha@gmail.com) (V.F.D. Rocha), [guilhermecmrocha@uol.com.br](mailto:guilhermecmrocha@uol.com.br) (G.C.M. Rocha).



**Fig. 1.** Diffusion-weighted NMR imaging of the brain.



**Fig. 3.** Diffusion-weighted NMR imaging showing corpus callosum involvement.

presenting generalized seizures that responded to anticonvulsants.

Blood, saliva, urine, and CSF samples were screened for CHIKV, Zika, and Dengue using rt-PCR techniques [4,5]. Briefly, RNA was extracted using QIAmp Viral RNA mini kit according to manufacturer's instructions for CHIKV. The amplification product was 305 bp within the gene that codes for the viral envelope protein E2 of CHIKV [4]. For Zika virus, the amplicon product was 192 bp within the gene that codes for the viral NS5 region [5]. HSV was screened in CSF and Acyclovir was initiated. EEG showed diffuse slowing compatible with the diagnosis of encephalitis.

Brain NMR showed hyperintensity signals on diffusion-weighted imaging (DWI) involving the subcortical white matter of the frontal, parietal, temporal areas, and the corpus callosum as shown in Figs. 1–3, and were unremarkable in T1 or T2 weighted images with no enhancement in post-contrast T1-weighted NMR imaging (Fig. 4).

NMR imaging of the brain showing no enhancement of the lesions.

CSF results: 0.7 mononuclear cells per mm<sup>3</sup>, protein 106 mg/dL; glucose 23 mg/dL; immune markers for syphilis (Fta-Abs, VDRL) and toxoplasmosis (indirect immunofluorescence assay) were negative; and aerobic, mycobacterial and fungal cultures were all negative. Rt-PCR for CHIKV was positive in CSF, blood, urine and saliva. Rt-PCR for Zika virus, Dengue virus, and HSV were all negative.

The newborn began to show improvement in neurological parameters, being more active, from December 9th and was discharged home on December 16th. The newborn was more

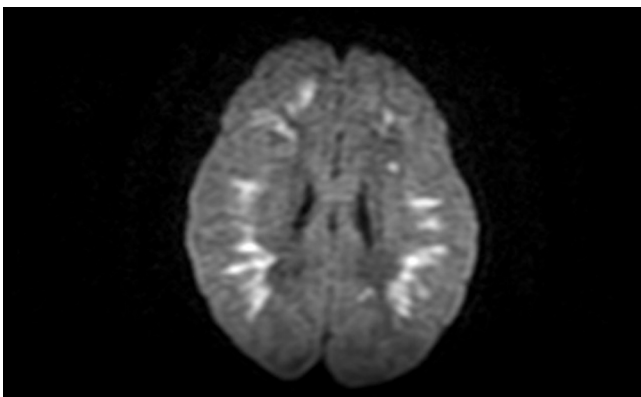
active, less hypotonic, and showing a normal sucking and palmar grasp reflexes.

#### Other similar and contrasting cases in the literature

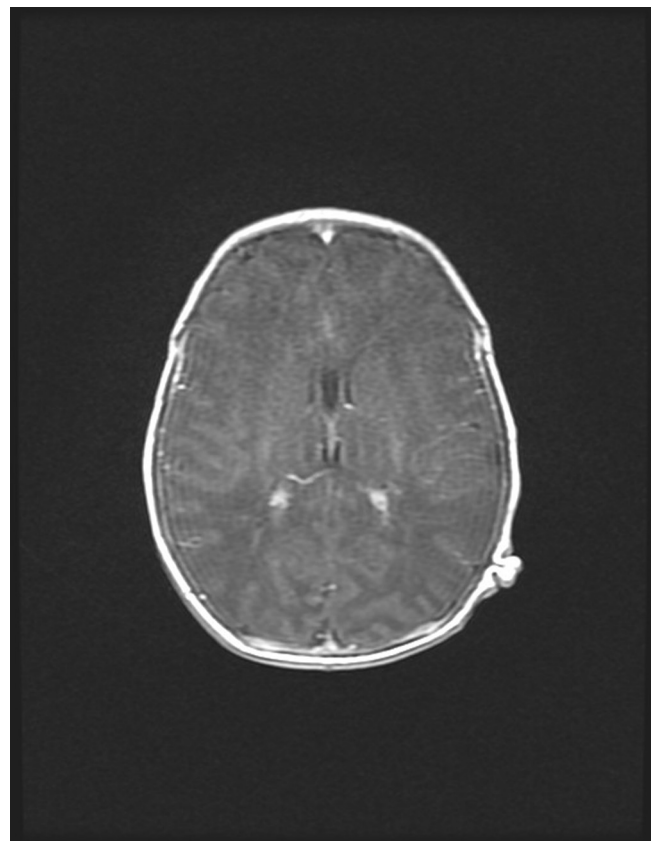
Géraldin et cols presented cases of CHIKV encephalopathy with a similar pattern of neurological involvement as seen in our case and indicative of an early cytotoxic edema with marked reduction of the apparent diffusion coefficient [3].

In La Reunión Island CHIKV outbreak during 2005–2006, cases of chikungunya-associated encephalitis contributed to a two-fold increase in the regional overall incidence of all encephalitis [6].

During an outbreak in India 3 fatal cases in children were documented and were associated with nervous system



**Fig. 2.** Diffusion-weighted NMR imaging of the brain.



**Fig. 4.** Post-contrast T1-weighted.

complications [7,8]. In the La Reunión epidemic, a similar report of 3 deaths were documented in children under 18 years, and 2 of them were due to encephalitis [9].

The pathogenic mechanism of the various neurological syndromes during CHIKV infection is largely unknown. Neurological involvement in CHIKV infection may include encephalitis [10], meningoencephalitis [11], encephalomyeloradiculitis [12], among others.

Casolari et cols have described a 83 year-old patient from Italy with a fatal encephalitis in the course of a CHIKV infection and suggested a possible association between high viral load that was found in CSF and serum and the poor outcome [13]. We did not quantify CHIKV viral load in this case even though we did find positive molecular results in many different body fluids possibly indicating a high replicative viral kinetics.

In our case report, the woman was submitted to a C-section but a possible benefit of this intervention to prevent vertical transmission of CHIKV was not confirmed in another study of 10 vertical CHIKV transmission cases [14].

Pierre-Yves Robillard et cols have described 10 cases of vertical transmission of CHIKV virus to neonates and the onset of symptoms occurred between three to seven days after birth [14]. Neonates born to viraemic women diagnosed during labor or during the last 4 weeks before delivery may have serious outcomes [15], as was also observed in a case series from Colombia [16].

CHIKV lesions generally present as a multifocal brain involvement, affecting structures such as temporal lobes, insular cortices, basal ganglia and periventricular white matter [11,12]. The brain lesions presented in our case had a distribution similar to the ones described in the literature and associated with CHIKV encephalitis. The restricted diffusion abnormalities seen in NMR imaging usually precedes signal abnormalities seen on fluid-attenuated inversion recovery (FLAIR) images and is also known to resolve earlier than the FLAIR signal abnormalities during the recovery period [11,12].

## Discussion

This case report of a vertical CHIKV-associated encephalitis documented with rt-PCR in the CSF, blood, urine and saliva represents the first description of this neurological involvement in a neonate since the introduction of CHIKV in Brazil in 2014. It has been a huge challenge the rapid differential diagnosis of serious neurological complications in a scenario of concurrent arboviral diseases in Brazil since we have been faced with the Zika outbreak and the reappearance of DENV-4 [17,18].

In countries experiencing outbreaks of CHIKV infections, clinicians and neonatologists must be familiar with the possibility of this serious neurological involvement and its possible consequences.

## Conflict of interests

The authors declare no competing interests.

## Funding

None.

## Ethical approval

Approved.

## References

- [1] Preparação e resposta à introdução do vírus Chikungunya no Brasil. Ministério da Saúde. Secretaria de Vigilância em Saúde. Brasília: Ministério da Saúde, 2014.
- [2] Gerardin P, Sampéris S, Ramful D, Boumahni B, et al. Neurocognitive outcome of children exposed to perinatal mother-to-child chikungunya virus infection: the CHIMERE cohort study on Reunion island. *PLoS Negl Trop Dis* 2014;8(7):1–14.
- [3] Gerardin P, Barau G, Michault A, Bintner M, et al. Multidisciplinary prospective study of mother-to-child chikungunya virus infections on the Island of La Reunion. *PLoS Med* 2008;5(3):413–23.
- [4] Edwards CJ, Welch SR, Chamberlain J, et al. Molecular diagnosis and analysis of Chikungunya virus. *J Clin Virol* 2007;39:271–5.
- [5] Balm MND, Lee CK, Lee HK, et al. A diagnostic polymerase chain reaction assay for Zika virus. *J Med Virol* 2012;84:1501–5.
- [6] Gerardin P, Couderc T, Bintner M, Tournebise P, et al. Chikungunya virus-associated encephalitis. *Neurology* 2016;86:1–9.
- [7] Pialoux G, Gauzère B-A, Strobel M. Infection à virus Chikungunya: revue générale par temps d'épidémie Chikungunya virus infection: review through an epidemic. *Med Maladies Infect* 2006;36(5):253–63.
- [8] Chatterjee SN, Chakravarti SK, Mitra AC, Sarkar JK. Virological investigation of cases with neurological complications during the outbreak of haemorrhagic fever in Calcutta. *J Indian Med Assoc* 1965;45(6):314–6.
- [9] Robin S, Ramful D, Le Seach F, Jaffar-Bandjee MC, et al. Neurologic manifestations of pediatric chikungunya infection. *J Child Neurol* 2008;23(9):1028–35.
- [10] Gauri LA, Ranwa BL, Nagar K, Vyas A, et al. Post Chikungunya brain stem encephalitis. *JAPI* 2012;60(4):68–9.
- [11] Chusri S, Siripaitoon P, Hirunpat S, Silpapojakul K. Case reports of neuro-Chikungunya in southern Thailand. *Am J Trop Med Hyg* 2011;85(2):386–9.
- [12] Ganesan K, Diwan A, Shankar SK, Desai SB, et al. Chikungunya encephalomyeloradiculitis: report of 2 cases with neuroimaging and 1 case at autopsy findings. *Am J Neuroradiol* 2008;29:1636–7.
- [13] Casolari S, Briganti E, Zanotti M, Zauli T, et al. A fatal case of encephalitis associated with Chikungunya virus infection. *Scand J Infect Dis* 2008;40(11–12):995–6.
- [14] Robillard P-Y, Boumahni B, Gerardin P, Michault A, et al. Vertical maternal fetal transmission of the Chikungunya virus. Ten cases among 84 pregnant women. *Presse Med* 2006;35(5 Pt 1):785–8.
- [15] Senanayake MP, Senanayake SM, Vidanage KK, et al. Vertical transmission in chikungunya infection. *Ceylon Med J* 2009;54:47–50.
- [16] Villamil-Go'mez Wilmer, Alba-Silvera Luz, Menco-Ramos Antonio, Gonzalez-Vergara Alfonso, et al. Congenital chikungunya virus infection in sincelejo, Colombia: a case series. *J Trop Pediatr* 2015;0:1–7.
- [17] Campos GS, Bandeira AC, Sardi SI. Zika virus outbreak, Bahia, Brazil. *Emerg Infect Dis* 2015;21:1885–6.
- [18] Rodriguez-Morales AJ, Bandeira AC, Franco-Paredes C. The expanding spectrum of modes of transmission of Zika virus: a global concern. *Ann Clin Microbiol Antimicrob* 2016;15:13.