

Case Report

Jian Fan, Ming-Ming Wang, Yu-Ping Liu*

Retrieval of a broken sewing needle from the sacrum aided by a permanent magnet: a case report and literature review

<https://doi.org/10.1515/med-2017-0063>

received December 2, 2016; accepted October 18, 2017

Abstract: Penetrating sacral injuries are very rare, but foreign bodies that penetrate the sacrum often cause pain, cerebrospinal fluid leakage, and neurological symptoms. Careful preoperative medical and imaging examinations, determining the position of the foreign body, and surgical exploration are essential in the management of such cases. We present the case of a woman who visited our emergency department with a broken sewing needle in her sacrum. The incident occurred when the patient accidentally sat on the needle while sewing by hand. Pain while sitting was the main clinical finding after the accident. The patient was treated successfully by surgical exploration aided by a permanent magnet. At follow-up a few months later, she was symptom-free. In clinical practice physicians often encounter patients with metallic foreign bodies. Permanent magnets play an important role in the removal of metallic foreign bodies, and emergency department physicians should master the methods and techniques.

Keywords: Broken needle; Magnet; Sacrum

1 Introduction

In the clinic, we often treat patients with metal foreign bodies; which is often caused blast injury, machine crushed injury, bullet wounds and so on. These metal

foreign bodies remain in the body and if not removed they are likely to cause wound infection, pain, two-stage infection, and occurrence of sepsis. However, when the small metal foreign body enter the human body, it is very difficult to locate them due to human muscle and blood. Sometimes we cannot find the foreign bodies even with the help of X-ray. In the use of the permanent magnet this can reduce the time taken to remove the operation time and radiation over-exposure, thereby reducing the risk of harm and potential infection to the patient.

A foreign body penetrating the sacrum of patients is a rare occurrence. Wood and nails have been reported in the literature as common foreign bodies that penetrate the sacrum [1, 2]. Injuries from broken needles are less common. In this report, we present a case of a penetrating sacral injury caused by a broken needle. The advantages of using permanent magnets during surgery are also discussed.

2 Case report

A 45-year-old healthy woman presented to the emergency department of our hospital approximately 3 hours after experiencing an accidental, self-inflicted injury in which a broken sewing needle penetrated her sacrum. The patient had been sitting on cushion sewing a quilt with a sewing needle, as it is popular in northern China to sew quilts in the summer for its use in the winter. She had placed the sewing needle and thread on the quilt and then stood up from the cushion. She lost her footing while turning and fell down, inadvertently sitting on the sewing needle and thread. Sufficient pressure was exerted that the sewing needle penetrated her sacrum. She initially tried to pull out the sewing needle, but only part of the needle was removed. She originally presented to a community hospital, where her transfer to our institution was suggested. Upon arrival, neurological and rectal examinations were completed, and the patient was found to be without sacral nerve damage and rectal bleeding.

*Corresponding author: Yu-Ping Liu, Department of Trauma Orthopedics, Tengzhou Central People's Hospital, Jining Medical College, Tengzhou, China, Email: liu9534@sohu.com

Jian Fan, Department of Trauma Orthopedics, Tongji hospital, Tongji University, China

Ming-Ming Wang, Department of Trauma Orthopedics, Tengzhou Central People's Hospital, Jining Medical College, Tengzhou, China

Plain radiographs of the sacrum (Figure 1) were obtained to determine the location of the broken sewing needle and to rule out an injury to the rectum. Given the length of the broken sewing needle and its proximity to this structure we used a cross made of needles from two 20-mL syringes to mark the location of the broken sewing needle. The broken needle was located in the left center of the spinal canal at the level of the foramen of the sacral canal.

The patient was taken to the emergency operating room for the removal of the broken sewing needle. Before surgery, the patient was administered penicillin and a tetanus booster. Under only local anesthesia, the patient underwent surgery to remove the foreign body. During the operation, we discovered that the broken sewing needle was very difficult to find; bleeding was minimal because of the foreign body's small size. Because the sewing needle was made of steel, we finally decided to put a permanent magnet into a sterile glove (Figure 2) to help us extract the needle. The broken needle was then successfully extracted from the incision without cerebrospinal fluid leakage (as is shown in the Figure 2 and 3). Operators were reminded that they should use aseptic techniques during this process. The permanent magnet can be sterilized by autoclaving.

The incision was thoroughly treated with pure iodine for 10 minutes to prevent infection, and the wound bed was copiously irrigated with 3 L of normal saline. The deep layers of the wound were then closed with 2-0 monofilament, and the superficial layers with 3-0 nylon. The patient was administered penicillin for 24 hours postop-

eratively and prescribed oral antibiotics with amoxicillin/clavulanic acid and ciprofloxacin for 3–5 days. The patient was followed for about 3 months and was pain-free with no limitations of motion.

Ethical approval: The research related to human use was complied with all the relevant national regulations, institutional policies and in accordance the tenets of the Helsinki Declaration, and was approved by the authors' institutional review board or equivalent committee.

Informed consent: Informed consent was obtained from all individuals included in this study

3 Discussion

Magnetic force have been used for many years to remove metallic foreign bodies from eye, respiratory tract, and alimentary tract and so on. However the use of this agency to remove metallic foreign bodies from soft tissues is reported less in the literature. Related research reports were as follows [3-10]: (Table 1)

To our knowledge, there are only a few other published reports of foreign body injuries to the sacrum. Gul et al. [1] reported the case of a 23-year-old man who had fallen from a 3-m-tall tree and sustained a wound to his lower back that was 2 cm in diameter. A 10 cm × 2 cm wooden fragment was removed from the S1–S2 spinal canal interlaminary space. Lorraine et al. [2] reported the case of a 21-year-old male roofer who was successfully

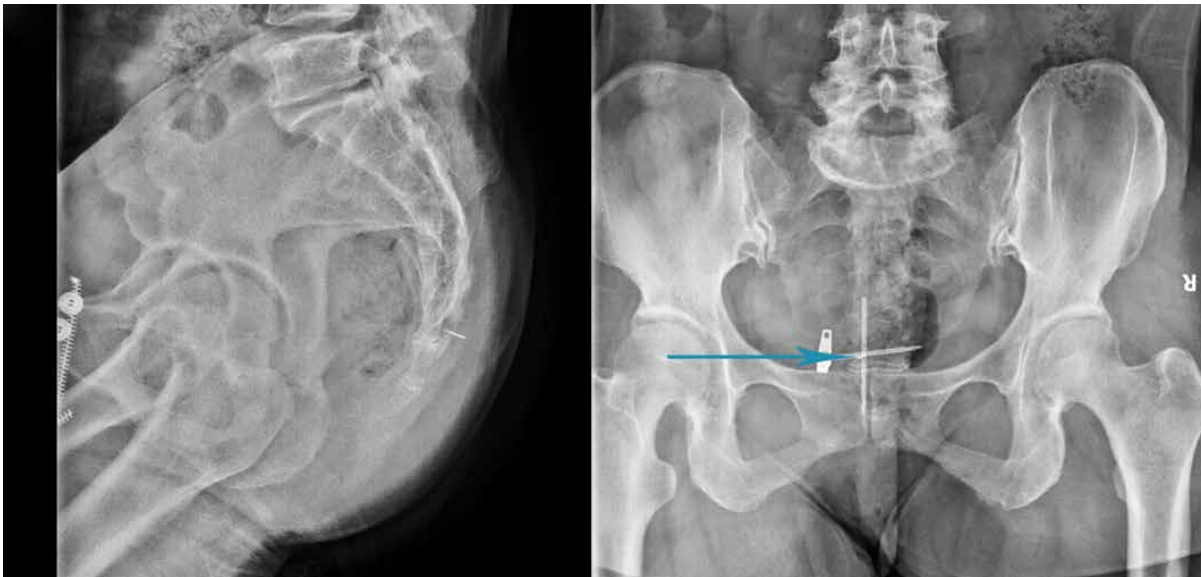


Figure 1: The location of the broken needle in lateral and anteroposterior radiographs, which located in the intersection (cyan arrow) of cross two needles of 20 ml syringe




Figure 2: A: the broken needle and the permanent magnet, B: the permanent magnet used in the operation, the length of the broken needle is about 1,2 cm.

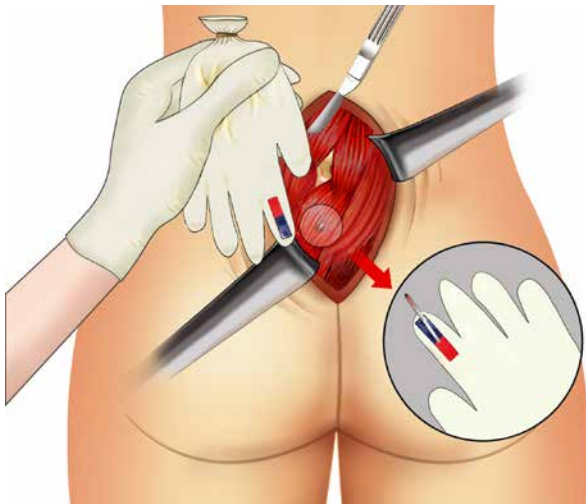


Figure 3: Schematic diagram of operation process was shown in Figure 3

treated for a nail gun injury to the sacrum. Some surgeons [11-13] believe that simple extraction of the foreign body, such as the nail or needle, could be done in most cases, unless there was gross contamination, joint penetration, or neurological compromise, and emphasized that these cases should be explored further if the foreign body is near neurovascular structures or if the foreign body is a nail with barbs.

In the case of broken needle injuries to the sacrum, we believe that a meticulous neurological examination and prophylactic antibiotic administration are essential prior to surgery to manage the penetrating intra-spinal injuries. Preoperative localization of foreign body is the most important task. We use the coincidence of the broken sewing needle and a cross made of the needles of two 20-mL syringes as the center of the incision. We extended the permanent magnet 3 cm up and down from the cross to find the broken sewing needle. The proximity

of the foreign body to important neurological structures and the potential for a cerebrospinal fluid leak should be noted during the retrieval of foreign bodies, especially at the superior aspect of the sacrum. In addition, the broken sewing needle was very light, weighing little more than 1 g, and we noted that the magnet attracted a 40-g metal vascular clamp from 1 cm away.

All in all, we believe that magnets can only play a supplementary role in the surgical removal of foreign bodies, especially metallic foreign bodies, but surgeons should not completely depend on the way to remove the foreign body. Preoperative localization is one of the most important parts of the operation; if positioning errors occur, aiding methods are futile. When necessary, preoperative ultrasonography or three-dimensional computed tomography should be performed. In addition, the incision sometimes should be appropriately extended. Foreign body removal with the use of a magnet should be performed within 1 week of when the foreign body entered the body; otherwise, the foreign body will be soon be enclosed by fiber and granulation tissue. Auxiliary application of a magnet to remove the foreign bodies is suitable for deep and/or bleeding incisions and foreign bodies with small volumes, because it can be very difficult to find foreign bodies.

Application of this method may have unexpected effects; however it can help surgeons avoid radiation overexposure. Moreover, it can also help to remove the small, broken pieces of foreign bodies when they fracture. We think that accurate preoperative localization and application of a permanent magnet [7] combined with an incision that is sometimes appropriately extended during the removal of iron foreign body operation will produce the same result with less effort.

Patients with metallic foreign bodies are sometimes very difficult to manage, largely due to radiation overex-

Table 1: Characteristics of 8 studies related to retrieval of foreign bodies from the soft tissue with the help of magnet

| First author, year of publication | Country | Number of cases | Genders | Age | Site of foreign body | Name of Foreign body | Operation time | Complications |
|-----------------------------------|---------|-----------------|---------------|--------------------|--|--|--------------------------------|---------------|
| Wu 2016 (3) | Tai wan | 1 | M | 50 | hand | iron particles | No report | No |
| Møller S 2015(4) | Denmark | 2 | M/M | 74/56 | leg/abdomen | Irregular metal plate | No report | NO |
| Aydın Sarihan 2014(5) | Turkey | 5 | M/M/M/ F/M | 25/18/35 /55/45 | Hand/forearm/ hand/fore- head/hand | Irregular metal plate and needle | 6min/5min/ 18min/10sec/4min | No |
| F.J. Pérez Lara 2014(6) | Spain | 1 | F | 19 | abdomen | Irregular metal plate | No report | No |
| Mathai J 2007(7) | India | 1 | M | 27 | neck | Irregular metal plate | No report | No |
| Prasad R 2000 (8) | USA | 1 | F | 54 | hip | broken scalpel blade | within 5 minutes | No |
| J. Chin 2000(9) | UK | 1 | M | 30 | neck | Irregular metal plate | No report | No |
| BROD RC 1961(10) | USA | 1 | M | 39 | hip | needle | No report | No |

posure and a long operation time. Removals of metallic foreign bodies with the help of the permanent magnet can reduce radiation overexposure and the operation time, thereby reducing the risk of harm to the patient and potential infection. We believe that all emergency physicians should learn to apply this method in order to remove metallic foreign bodies from patients, which can play an unexpected effect during the operation.

Conflicts of interest: The authors have declared that there are no conflicts of interest.

Acknowledgments: This work was supported by Shandong Provincial Natural Science Foundation, China (grant No. ZR2016HL14).

References

- [1] Gul S, Dusak A, Songur M, Kalayci M, Acikgoz B. Penetrating spinal injury with a wooden fragment: a case report and review of the literature. *Spine*. 2010;35:E1534-1536
- [2] Stern LC, Moore TA. Nail gun injury to the sacrum: case report and review of the literature. *Spine*. 2011;36:E1778-1780
- [3] Wu CS, Chen W, Fu TY, Wei KC. Magnet hanging on the skin – An easy method to detect occult metallic cutaneous foreign body. *Journal of the European Academy of Dermatology and Venereology : JEADV*. 2016;30:e36-e7
- [4] Moller S, Rasmussen P. [Removal of a foreign metallic body with a magnet]. *Ugeskrift for laeger*. 2015;177:V12140658
- [5] Sarihan A, Can C. Soft tissue foreign body removal with magnet in ED settings. *The American journal of emergency medicine*. 2014;32:952 e3-5
- [6] Perez Lara FJ, Ferrer Berges A, Oliva Munoz H. Removal of a metallic foreign body from the abdominal wall using an orientable magnetic locator. *Journal of plastic, reconstructive & aesthetic surgery : JPRAS*. 2014;67:e97-98
- [7] Mathai J, Ahmed S, Pushpakumari KP, Reynolds AM. Removal of a metallic foreign body in the neck with a magnet: A case report. *Indian journal of otolaryngology and head and neck surgery : official publication of the Association of Otolaryngologists of India*. 2007;59:382-383
- [8] Prasad R, Amstutz HC, Sparling EA. Use of a magnet to retrieve a broken scalpel blade. *The Journal of arthroplasty*. 2000;15:806-808
- [9] Chin JT, Davies SJ, Sandler JP. Retrieval of a metallic foreign body in the neck with a rare earth magnet. *Journal of accident & emergency medicine*. 2000;17:383-384
- [10] Brown TE. Factors related to turnover among Veterans Administration nursing assistants. *Journal of clinical and experimental psychopathology & quarterly review of psychiatry and neurology*. 1961;22:226-234
- [11] Nathoo N, Sarkar A, Varma G, Mendel E. Nail-gun injury of the cervical spine: simple technique for removal of a barbed nail. *Journal of neurosurgery Spine*. 2011;15:60-63
- [12] de Barros Filho TE, Cristante AF, Marcon RM, Ono A, Bilhar R. Gunshot injuries in the spine. *Spinal cord*. 2014;52:504-510
- [13] Beaty N, Slavin J, Diaz C, Zeleznick K, Ibrahimi D, Sansur CA. Cervical spine injury from gunshot wounds. *Journal of neurosurgery Spine*. 2014;21:442-449