

Free Air in the Cavernous Sinus Secondary to Acute Isolated Sphenoid Sinusitis

Satoshi Matsuo¹ and Kenichi Matsumoto²

Pneumocephalus is a rare but important complication of acute isolated sphenoid sinusitis (ISS). If not adequately treated, it may cause serious neurological and life-threatening complications. We report the presence of free air in the cavernous sinus arising from intracranial extension of acute ISS. A 41-year-old healthy man presented to our department with a 7-day history of headache. Neurological examination revealed no meningitis, and cerebrospinal fluid culture was negative. A head computed tomography (CT) and magnetic resonance imaging on admission revealed sinusitis in the sphenoid sinus and presence of air in the cavernous sinus. We started an antibiotic treatment and the patient's fever immediately decreased and the inflammatory response improved. In addition, the bilateral retro-orbital headache diminished. A repeated head CT scan revealed that fluid retention in the sphenoid sinus and air in the cavernous sinus had disappeared. To our knowledge, this is the fifth case of pneumocephalus accompanied by acute ISS reported in the literature and the first case report of intracranial air located only in the cavernous sinus. Meningitis accompanied by pneumocephalus can be a warning sign for poor outcome in patients with ISS.

Keywords: air, cavernous sinus, isolated sphenoid sinusitis, pneumocephalus

Introduction

Acute isolated sphenoid sinusitis (ISS) is a relatively uncommon disease, representing 1–3% cases of acute bacterial sinusitis.¹ Meningitis accompanied by pneumocephalus is a rare but important complication of acute ISS. This condition, if unrecognized and not adequately treated, may cause severe neurological or life-threatening complications.

Several authors have reported cases of pneumocephalus accompanied by acute ISS and all reported cases showed free air in the subarachnoid space.^{2–5} We report a patient with free air only in the cavernous sinus accompanied by acute ISS.

Case Report

A 41-year-old healthy man presented to our department with a 7-day history of headache. Several days prior to the

admission, he visited a medical clinic with headache. Although symptomatic treatment was initiated, it did not improve the headache, which was located bilaterally, in the retro-orbital region. Prior to this episode, the patient enjoyed good health and denied any recent head trauma, head surgery, or scuba diving.

No orbital or periorbital swelling was observed and no chemosis was present. The patient's vital signs, except his temperature (38°C) were stable. His mental status was alert and his cranial nerves were intact. Neither neck stiffness nor Kernig's sign was observed. Laboratory data revealed increased total white cell count (24,090/mm³), neutrophilia (90.8%), and high C-reactive protein (5.64 mg/dL) level. The opening pressure at lumbar puncture was normal (16 cm H₂O). Although CSF culture was negative, the blood culture showed *Peptostreptococcus prevotii* growth after admission. He had no history of CSF rhinorrhea.

A head computed tomography (CT) and magnetic resonance imaging (MRI) images demonstrated opacified sphenoid sinus (Figs. 1A, D). Moreover, air was observed at multiple sites in the bilateral cavernous sinus (Fig. 1B). A sagittal CT image showed a bone defect in the clivus (Fig. 1C). A sagittal MRI showed enhanced circumferential sphenoid sinus mucosa and dura covering the clivus (Fig. 1D). A tentative diagnosis of acute ISS and pneumocephalus was considered. A combination of intravenous ceftriaxone, vancomycin, and clindamycin was started, and the patient was closely monitored. Immediately after starting the antibiotic treatment, the patient's fever decreased and inflammatory response improved. Furthermore, the bilateral retro-orbital headache diminished. A head CT scan performed 17 days after admission demonstrated that the sphenoid sinus was free of fluid retention and the cavernous sinus was free of air (Fig. 1E). Head MRI performed after discharge revealed no gadolinium enhanced circumferential sphenoid sinus mucosa (Fig. 1F). The dural enhancement of the clivus was significantly decreased (Fig. 1F).

Discussion

Acute ISS is a relatively uncommon disease but represents a potentially life-threatening infectious process owing to its associated complications such as bacterial meningitis and cavernous sinus thrombosis.⁶ Pneumocephalus is a less common complication of acute ISS. A literature review revealed four cases with pneumocephalus caused by acute ISS. Table 1 shows the clinical features of these cases, along with the present case.^{2–5} All four patients showed intracranial air location in the subarachnoid space. Interestingly, the brain

¹Department of Neurosurgery, Graduate School of Medical Sciences, Kyushu University, Fukuoka; Fukuoka

²Department of Neurosurgery, Saga-Ken Medical Centre Koseikan, Saga, Saga

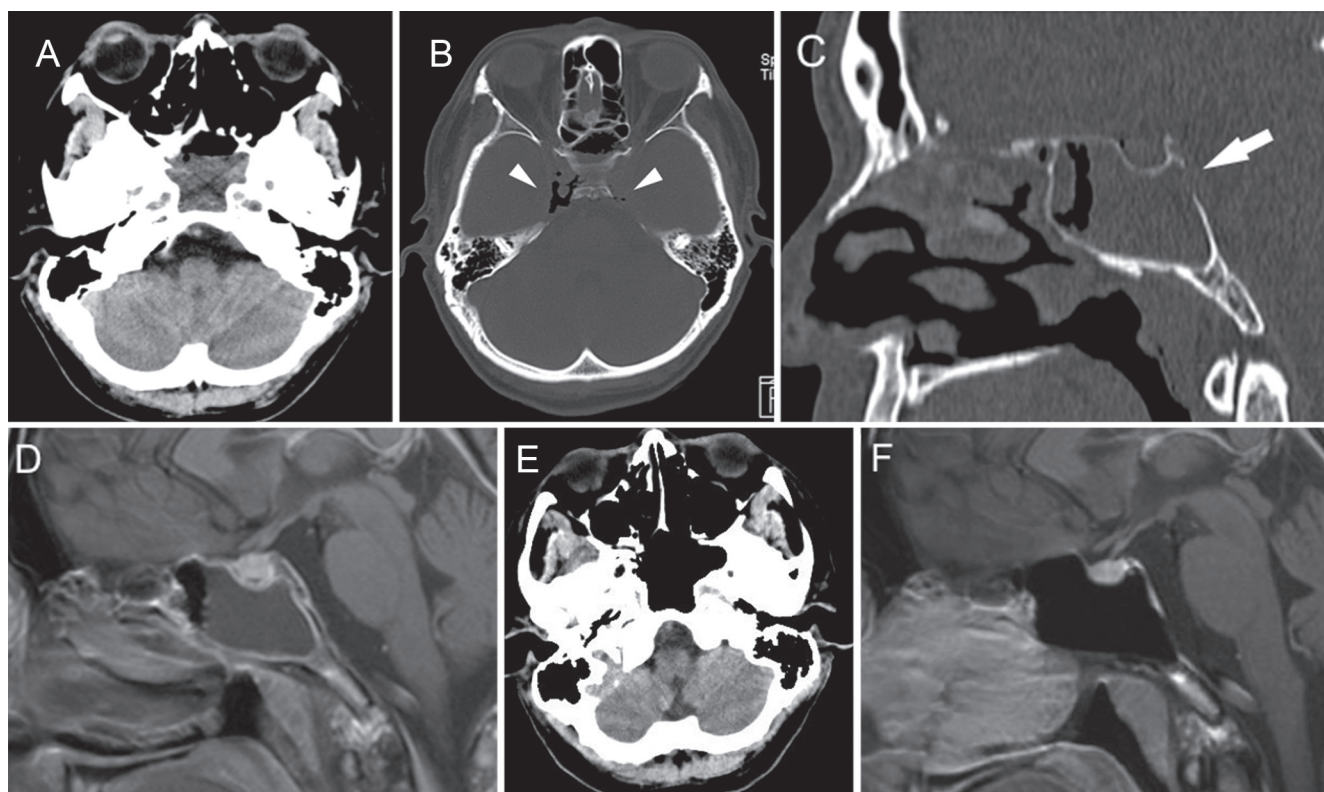


Fig. 1 Computed tomographic (CT) scans and magnetic resonance (MR) images of the patient. A: An axial, non-enhanced CT image on admission demonstrated opacified sphenoid sinus. B: Bone window of axial CT image demonstrated free air (arrowheads) in the bilateral cavernous sinus on admission. C: A sagittal, non-enhanced CT image revealed a defect (arrow) in the posterior wall of sphenoid sinus. D: A sagittal T₁-weighted gadolinium enhanced MR image on admission demonstrated opacified sphenoid sinus and enhanced peripheral mucous membrane. The dura covering the clivus was enhanced. E: No accumulation of fluid was found with non-enhanced axial CT image during the follow-up. F: A follow-up sagittal T₁-weighted gadolinium enhanced MR image revealed that an enhanced peripheral mucous membrane of the sphenoid sinus diminished. The enhancement of the dura covering the clivus was markedly decreased.

CT of the present case revealed that intra-cranial air existed only in the cavernous sinus.

Air in the cavernous sinus has been associated with trauma,⁷⁾ surgery, and iatrogenic causes.^{8–10)} In patients without symptoms originating in the cavernous sinus, air does not appear to be a significant problem.^{11,12)} However, we examined the reason for the presence of air because it can be a sign of neurological or neurosurgical emergencies.¹³⁾ Our patient denied any recent head trauma or head surgery, and we did not cannulate peripheral or central veins before the scan. One explanation for the findings of the present case may be that only the outer membrane of the dura mater was breached because of ISS. Brain CT of the present case revealed bone destruction in the posterior wall of the sphenoid sinus. The intracranial air could be attributed to an infection that had weakened the wall of the sphenoid sinus and breached only the outer membrane of the dura mater, allowing air to enter into the cavernous sinus. Our hypothesis is supported by the findings that the present case showed no evidence of meningitis or CSF leak.

Current treatment recommendations for acute ISS include prompt administration of oral or intravenous antibiotics, which can cure acute ISS if diagnosed and treated early.^{4,14)} During the antibiotic therapy, if the symptoms worsen or

continue 24–48 h, or if there are signs of other complications, surgical drainage is indicated.^{4,15–17)} Otherwise, severe suppurative complications including epidural abscess, subdural empyema, meningitis, cerebral abscess, cavernous sinus thrombosis, and superior sagittal sinus thrombosis may occur.¹⁸⁾ Here antibiotic therapy was initiated and patient was closely observed because the patient manifested no symptoms except bilateral retro-orbital headache. After antibiotic administration, the patient became afebrile and his headache immediately diminished.

Mortality due to acute ISS reached 27% and was mainly caused by delayed diagnosis.¹⁹⁾ Although mortality and morbidity due to acute ISS have improved, delayed diagnosis may yet cause permanent neurological complications.^{4,16)} Three of the five cases (cases 1, 2, and 4) showed evidence of meningitis and two of these three cases (cases 2 and 4) resulted in poor outcome (Table 1). Conversely, the present case showed no evidence of meningitis, and the patient fully recovered without complications. Considering acute ISS clinical features with pneumocephalus, associated meningitis can be a warning sign for poor outcome. We suggest that patients with acute ISS and pneumocephalus who also show evidence of meningitis require urgent medical and surgical drainage on admission.

Table 1 Clinical features of isolated sphenoid sinusitis accompanied with pneumocephalus

| Case | Author, Year | Age, Sex | Location of free air | Other intracranial complications | Surgical drainage | Outcome |
|------|--------------------------------------|----------|-------------------------------------|---|-------------------|----------------|
| 1 | Naganuma et al. (1986) ²⁾ | 18, M | Left sylvian fissure | Meningitis | + | good |
| 2 | Lin et al. (2009) ³⁾ | 14, M | Prepontine and ambient cistern | Meningitis, cavernous sinus thrombosis, left orbital cellulitis | + | death |
| 3 | Tan and Ong (2004) ⁴⁾ | 10, M | Middle cranial fossa | – | + | good |
| 4 | Ohe et al. (2012) ⁵⁾ | 60, M | Interpeduncular and ambient cistern | Meningitis, multiple cerebral infarction | + | comatose state |
| 5 | Present case | 41, M | Bilateral cavernous sinus | None | – | good |

M: male.

In conclusion, ISS can extend to the intracranium and cause pneumocephalus. To prevent neurological and life-threatening complications, immediate antibiotic therapy is required.

Conflicts of Interest Disclosure

The authors declare no conflicts of interest.

References

- 1) Wang ZM, Kanoh N, Dai CF, Kutler DI, Xu R, Chi FL, Tian X: Isolated sphenoid sinus disease: an analysis of 122 cases. *Ann Otol Rhinol Laryngol* 111: 323–327, 2002
- 2) Naganuma H, Imai S, Wakao T, Koizumi H, Koizumi J, Minowa A: Pneumocephalus secondary to acute sinusitis—case report. *Neurol Med Chir (Tokyo)* 26: 541–544, 1986
- 3) Lin JJ, Wu CT, Hsia SH, Wang HS, Lin KL: Pneumocephalus: a rare presentation of Candida sphenoid sinusitis. *Pediatr Neurol* 40: 398–400, 2009
- 4) Tan HK, Ong YK: Acute isolated sphenoid sinusitis. *Ann Acad Med Singap* 33: 656–659, 2004
- 5) Ohe Y, Maruyama H, Deguchi I, Fukuoka T, Kato Y, Nagoya H, Dembo T, Tanahashi H: An adult case of pneumocephalus and pneumococcal meningitis associated with the sphenoid sinusitis. *Inter Med* 51: 1129–1131, 2012
- 6) Unlu HH, Aslan A, Goktan C, Egrilmez M: The intracranial complication of acute isolated sphenoid sinusitis. *Auris Nasus Larynx* 29: 69–71, 2002
- 7) Bartynski WS, Wang AM: Cavernous sinus air in a patient with basilar skull fracture: CT identification. *J Comput Assist Tomogr* 12: 141–142, 1988
- 8) Nusrath MA, Postlethwaite KR, Thomson PJ: Gas in the cavernous sinus—iatrogenic or pathological? *Br J Oral Maxillofac Surg* 48: 394–395, 2010
- 9) Brook J, Moss E: Air in the cavernous sinus following scalp vein cannulation. *Anaesthesia* 49: 219–220, 1994
- 10) Nedelmann M, Pittermann P, Gast KK, Mueller-Forell W, Dieterich M: Involvement of jugular valve insufficiency in cerebral venous air embolism. *J Neuroimaging* 17: 258–260, 2007
- 11) Rubinstein D, Symonds D: Gas in the cavernous sinus. *AJNR Am J Neuroradiol* 15: 561–566, 1994
- 12) Horton JC, Langer PD, Turner GE: Free air in the cavernous sinus as an incidental finding. *J Clin Neuroophthalmol* 13: 50–53, 1993
- 13) Curnes JT, Creasy JL, Whaley RL, Scatliff JH: Air in the cavernous sinus: a new sign of septic cavernous sinus thrombosis. *AJNR Am J Neuroradiol* 8: 176–177, 1987
- 14) Lu YJ, Chang CN, Pai PC, Wei KC, Chuang CC: Isolated sphenoid sinusitis or mucocele: a potential complication of endonasal transsphenoidal surgery. *J Neurooncol* 91: 63–67, 2009
- 15) Marseglia GL, Pagella F, Licari A, Scaramuzza C, Marseglia A, Leone M, Ciprandi G: Acute isolated sphenoid sinusitis in children. *Int J Pediatr Otorhinolaryngol* 70: 2027–2031, 2006
- 16) Ruoppi P, Seppä J, Pukkila M, Nuutinen J: Isolated sphenoid sinus diseases: report of 39 cases. *Arch Otolaryngol Head Neck Surg* 126: 777–781, 2000
- 17) Goldman GE, Fontanarosa PB, Anderson JM: Isolated sphenoid sinusitis. *Am J Emerg Med* 11: 235–238, 1993
- 18) Gallagher RM, Gross CW, Phillips CD: Suppurative intracranial complications of sinusitis. *Laryngoscope* 108: 1635–1642, 1998
- 19) Lew D, Southwick FS, Montgomery WW, Weber AL, Baker AS: Sphenoid sinusitis. A review of 30 cases. *N Engl J Med* 309: 1149–1154, 1983

Corresponding author:

Satoshi Matsuo, MD, Department of Neurosurgery, Graduate School of Medical Sciences, Kyushu University, 3-1-1 Maidashi, Higashi-ku, Fukuoka, Fukuoka 812-8582, Japan.

✉ smatsuo1979@gmail.com