

# Does conventional defecography has a role to play in evaluation of evacuatory disorders in Indian population?

Sheo Kumar, Pankaj Sharma<sup>1</sup>, Gustav Andreisek<sup>2</sup>

Department of Radiodiagnosis, Sanjay Gandhi Post Graduate Institute of Medical Sciences, Lucknow, <sup>1</sup>Delhi State Cancer Institute, Delhi, India, <sup>2</sup>Institute of Diagnostic and Interventional Radiology, University Hospital Zurich, Switzerland CH-8091

**Correspondence:** Dr. Pankaj Sharma, Department of Radiodiagnosis, Delhi State Cancer Institute, Delhi - 110 095, India.  
E-mail: pankajrad7477@yahoo.com

## Abstract

Barium studies are one of the best investigations for evaluating submucosal and extrinsic mass lesions. However, barium studies bring less money, are operator dependent and one of the more difficult investigations for radiologists to master. Economic factors have acted as powerful disincentives for performing gastrointestinal (GI) fluoroscopy in most radiology practices. In this pictorial essay, we discuss the role of conventional defecography in evaluating evacuatory disorders in the Indian population.

**Key words:** Decubitus; evacuation; protusion; submucosal

## Introduction

The exact frequency of constipation in Indian population is unknown.<sup>[1]</sup> Most affected are women. Constipated patients with functional anorectal abnormalities complain of fecal evacuation difficulties in terms of incomplete evacuation, excessive straining, and need for manually assisted evacuation. The first step in management of constipation is to exclude organic and anatomic causes. Only the patients in whom an obstructive and/or malignant lesion such as colorectal carcinoma as well as slow colonic transit has been ruled out should undergo evacuation imaging to assess for functional defecatory disorders.<sup>[2]</sup>

Defecography, Magnetic resonance defecography (MRD), the balloon expulsion test, anorectal ultrasound, anorectal manometry, defecometry, sphincter electromyography, and pudendal nerve terminal motor latency study may be

used to diagnose fecal evacuation disorder. Defecography is the dynamic study of expulsion of radio-opaque material from the rectum, in order to assess changing anatomical relationships of the pelvic floor and associated organs during defecation.<sup>[3]</sup> Defecography has a substantial diagnostic and therapeutic effect, allows evaluation in supine position, and is of considerable benefit to referring clinicians.<sup>[4-8]</sup> Defecography may provide useful information in incompetent patients with outlet obstruction constipation symptoms, but has little value in incontinent patients without such symptoms.<sup>[9]</sup> The radiation dose for defecography is approximately 2-3 mSv.<sup>[10]</sup>

## Relevant Anatomy

The pelvic floor in women is divided into three compartments: The anterior compartment (bladder and urethra), middle compartment (vagina and uterus), and posterior or anorectal compartment.<sup>[11]</sup> Complete survey of the entire pelvis is necessary for optimal patient management because abnormalities of the three pelvic compartments are frequently associated.<sup>[12]</sup>

The puborectalis muscle forms a sling around the rectum. A tear in the anterior portion of the endopelvic fascia (pubocervical fascia) results in bladder descent or a cystocele, while a tear in the posterior

### Access this article online

#### Quick Response Code:



Website:  
www.ijri.org

DOI:  
10.4103/0971-3026.113625

aspect (rectovaginal fascia) results in an anterior rectocele or enterocele.

The anorectum plays an important role in regulation of defecation and in the maintenance of continence.<sup>[13,14]</sup> Normal defecation involves the coordinated relaxation of the internal anal sphincter, puborectalis, and external anal sphincter muscles, together with increased intra-abdominal pressure and colonic motor activity that propels stools toward the rectum.

## Technique

Patient is instructed to come after overnight fasting. Patient cooperation is of outmost importance and the entire procedure is explained to the patient during preparatory phase. Informed consent is taken and privacy of patient is maintained. The patient is instructed to drink 400 ml of thin barium 1 h prior to the actual study. Complete bowel cleansing is usually not necessary for preparation. Low lighting helps in relieving patient's anxiety.

Covering the table with a plastic sheet helps overcome the patient's embarrassment and allows easier cleaning after the examination. The patient is positioned in the left lateral decubitus position. A total of approximately 100 ml of semisolid barium sulfate paste is injected into the rectum via two 50 ml syringes with short plastic tubing attached to the syringes [Figure 1]. The anal verge is marked using a small skin marker sticker. A specially constructed radiolucent commode is positioned and fixed to the table. The table is repositioned into the upright vertical position, with the patient seated on the commode.

The patient is instructed to perform several maneuvers and these are marked on the radiological images: Rest, squeeze, strain, defecate, and post evacuation. The patient is instructed to evacuate the barium paste as completely as possible. A digital fluoroscopy cine clip is obtained of the entire procedure.

The normal radiological appearances during defecation may be summarized as: Rapid initiation, pelvic floor descent, loss of puborectalis impression, increase in anorectal angle (ARA), shortening of the anal canal, and anal canal opening widely.

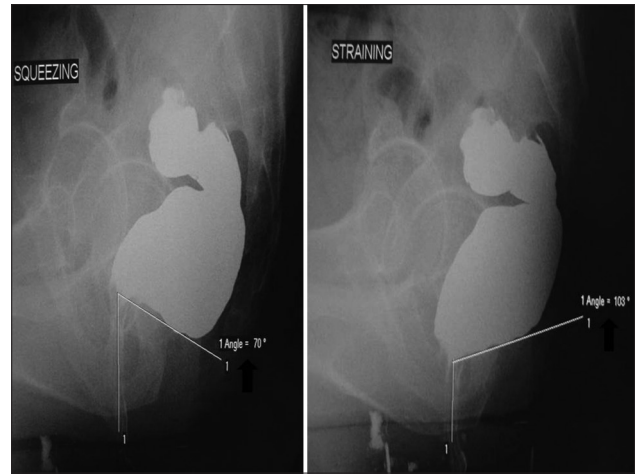
During the standard defecogram, the rectum and small bowel loops are usually opacified.<sup>[15]</sup> However, opacification of the bladder or vagina is not routinely performed. Low *et al.*<sup>[16]</sup> concluded that vaginal opacification during defecography may aid in diagnosis of pelvic floor pathology.

## Relevant terminology, lines, and angles for interpretation of defecatory disorders<sup>[17,18]</sup>

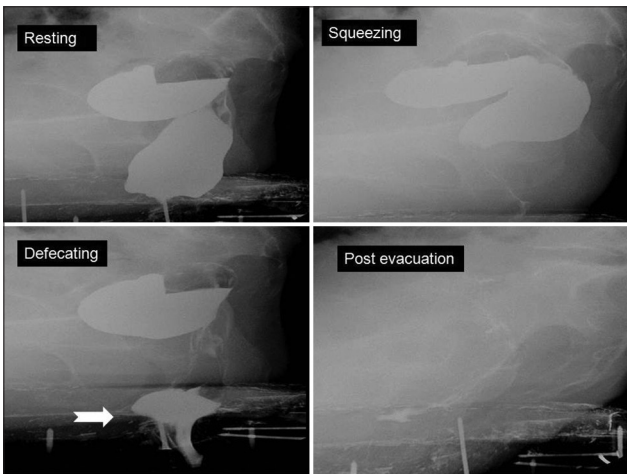
- Anorectal junction is defined as the point of taper of the distal part of the rectum as it meets the anal canal
- The ARA is defined as the angle between the posterior wall of the distal part of the rectum and the central axis of the anal canal [Figure 2]. ARA change in healthy volunteers between rest and squeezing and between rest and defecation is usually 15-20%.<sup>[19]</sup> ARA change of 10% or less between pelvic positions is abnormal
- Pubococcygeal line (PCL) should be drawn from the inferior border of the pubic symphysis to the last coccygeal joint. PCL represents the level of the pelvic floor and is the landmark for measuring organ prolapsed. The perpendicular distance from PCL to the bladder neck, vaginal vault, and anorectal junction, respectively, should be measured on images obtained when the patient is at rest and during maximal pelvic strain
- In descending perineal syndrome, the pelvic muscles lose tone, resulting in excessive descent of the entire pelvic floor at rest or during evacuation. To show pathologic pelvic floor descent, the measurements are made on the images, which show maximal organ descent, usually during maximal straining or evacuation [Figures 3-5]
- Enterocele is defined as herniation of pelvic peritoneal sac into the rectogenital space, the rectovaginal septum in women, passing below the proximal one-third of the vagina. Since a filled rectum does not allow sufficient space for small bowel to descend into the pelvis, enterocele usually occurs at the end of evacuation as a consequence of increased intra-abdominal pressure. The pelvic peritoneal sac may contain fat, called peritoneocele, small bowel, or sigmoid colon
- Rectocele is defined as an outward bulge of the rectal wall. Rectoceles are measured as the depth of wall protrusion beyond the expected margin of the normal anorectal wall [Figures 6 and 7]. They usually involve the anterior wall but may rarely occur posteriorly. They are common findings but become clinically relevant when symptoms occur, as they are responsible for obstructed or incomplete evacuation, requiring vaginal or perineal digitations to empty the rectum
- Cystocele is diagnosed when bladder base descends more than 1 cm below PCL
- Vaginal or cervical prolapse is defined as descent of the vaginal vault or cervix below PCL
- Intussusception is defined as circular invagination of the proximal rectal wall involving both the mucosa and muscular layer during defecation [Figure 8]. This causes a mechanical obstruction to the passage of stool. Extra-anal invagination is termed as rectal prolapse [Figure 9]
- Dyskinesia is defined as muscular contraction of the pelvic floor muscles, usually the puborectalis, during defecation. The puborectalis muscle is frequently hypertrophic and makes a prominent impression on the rectal wall [Figure 10]
- Anismus is defined as failure to evacuate more than



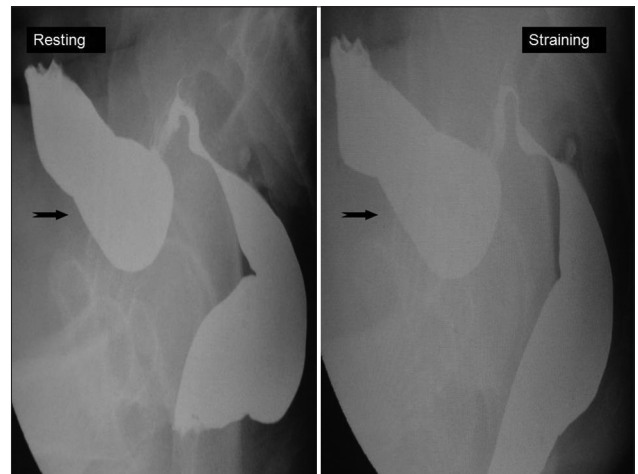
**Figure 1:** Image showing materials and things required for defecography – barium sulfate (black arrow), rectal insufflation syringe and tube (black curved arrow), commode on foot end of table (black arrowhead)



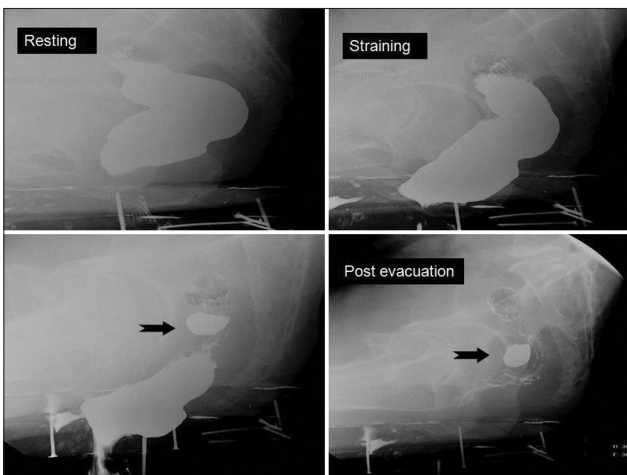
**Figure 2:** Note the change of ano-rectal angle (ARA) between squeezing and straining position (black arrow)



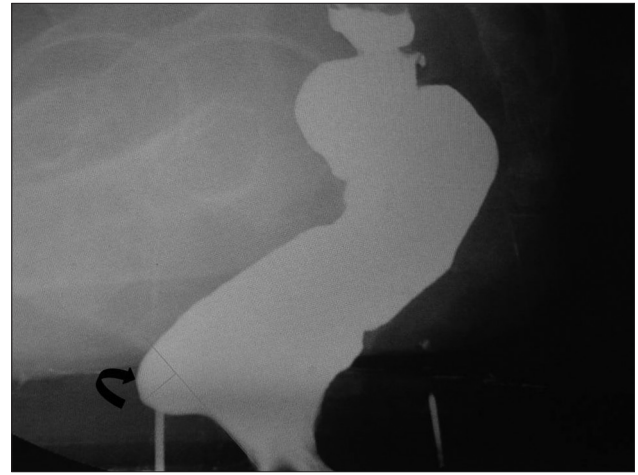
**Figure 3:** Note severe rectal descent (62 mm) (white arrow) in this 54-year-old female with complete emptying on post-evacuation film



**Figure 4:** There is weakness of pelvic floor with sagging of sigmoid colon (black arrow) in this 48-year-old male



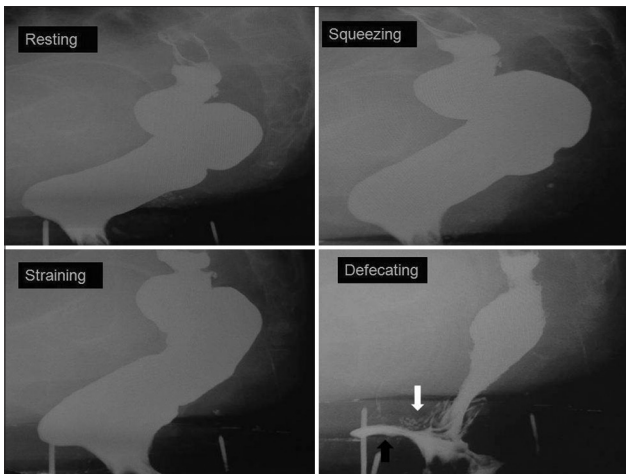
**Figure 5:** Note the presence of sigmoid diverticulae (black arrow) in this 51-year-old male



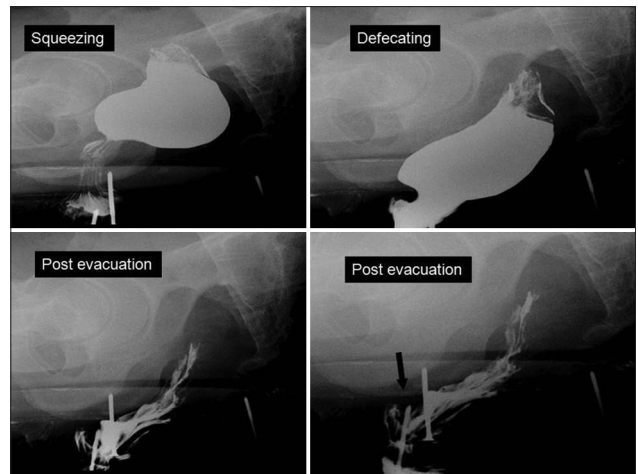
**Figure 6:** Image showing measurement of rectocele as perpendicular distance from anterior anal plane (black curved arrow)

- two-third of the barium paste in less than 30 seconds
- Incontinence is defined as spillage of barium paste from

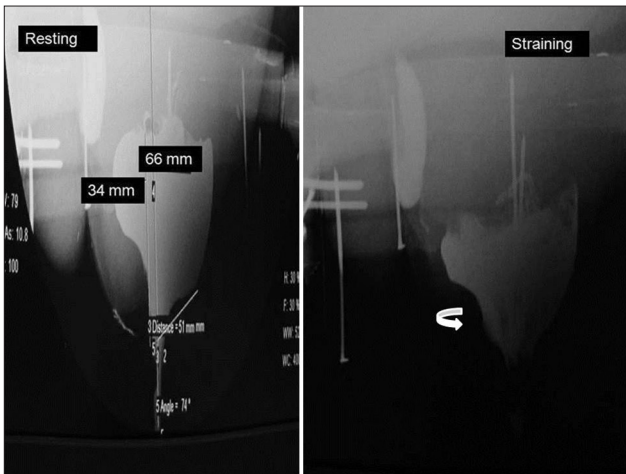
anal canal, prior to initiation of defecation. Patients can present with either fecal leakage they are unaware of,



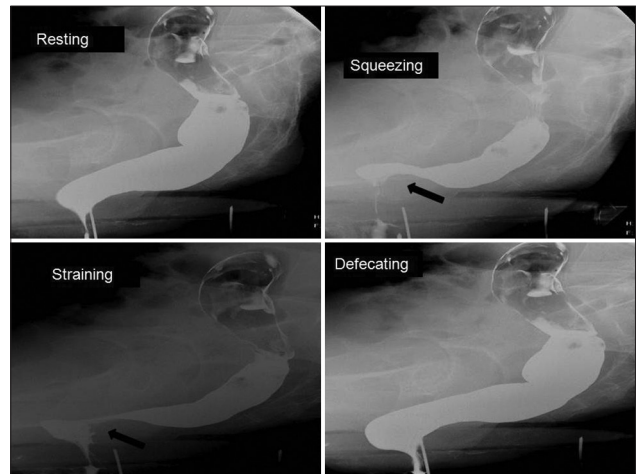
**Figure 7:** Note moderate rectal descent (34 mm) and severe anterior rectocele (42 mm) (black arrow) in this 45-year-old female. During defecation, rectocele became more prominent with incomplete emptying accompanied by intra-rectal intussusception (white arrow)



**Figure 8:** Note moderate rectal descent (36 mm) and intra-rectal intussusceptions (black arrow) in this 48-year-old male



**Figure 9:** Note severe rectal descent along with rectal prolapse (white curved arrow) in this 47-year-old female



**Figure 10:** Note persistent puborectalis impression (black arrow) in this 46-year-old female. Also note the presence of moderate rectocele (24 mm)

**Table 1: The three-point grading system followed for measuring cystocele, vaginal vault descent, enterocele, rectal descent, and rectocele**

Abnormality	Small cm	Moderate cm	Large cm
Cystocele	<3	3-6	>6
Vaginal vault descent	<3	3-6	>6
Enterocele	<3	3-6	>6
Rectal descent	<3	3-6	>6
Anterior proctocele	<2	2-4	>4

suggesting an internal sphincter abnormality, or urge incontinence, indicating external sphincter damage.

Table 1 shows the three-point grading system followed for measuring cystocele, vaginal vault descent, rectocele, rectal descent, and enterocele.

Defecography using Magnetic Resonance Imaging (also

referred to as MRD) is a special method which is suitable for patients with multicompartiment involvement and for those who have undergone previous surgical repairs. Hetzer *et al.*<sup>[20]</sup> concluded that MRD findings led to change in surgical approach in 67% of patients who underwent surgery for fecal incontinence. Its main advantage is direct visualization of pelvic structure including the bladder, vagina, cervix and rectum. In addition, MRD allows dynamic assessment of the pelvic floor. However, main drawback is that MRI is an expensive imaging modality with limited availability. Thus, conventional defecography despite being an investigation with radiation hazards is being used extensively in many places in India for evaluation of fecal evacuatory disorders. Its main advantages are cost-effectiveness and excellent resolution for submucosal and extrinsic pathology.

So, we conclude that conventional defecography has an

important role to play in the Indian population, especially with myriad of findings which can be detected like rectocele, rectal intussusceptions, rectal descent, enterocele, and rarely other findings like sigmoid diverticulae. However, the results of any dynamic pelvic examination, need to be considered in the light of the patient's history and other tests, so that appropriate therapy is administered.

## References

1. Ghoshal UC. Review of pathogenesis and management of constipation. *Trop Gastroenterol* 2007;28:91-5.
2. Stoker J, Halligan S, Bartram C. Pelvic floor imaging. *Radiology* 2001;218:621-41.
3. Morris AM, Parker SC. Defecography: Technique, interpretation and current use. In: Wexner SD, Duthie GS, editors. *Constipation*. 2<sup>nd</sup> ed. Pa: Springer; 2006. p. 85-98.
4. Harvey CJ, Halligan S, Bartram CI, Hollings N, Sahdev A, Kingston K. Evacuation proctography: A prospective study of diagnostic and therapeutic effects. *Radiology* 1999;211:223-7.
5. Felt-Bersma RJ, Luth WJ, Janssen JJ, Meuwissen SG. Defecography in patients with anorectal disorders. Which findings are clinically relevant? *Dis Colon Rectum* 1990;33:277-84.
6. Maglinte DD, Kelvin FM, Hale DS, Benson JT. Dynamic cystoproctography: A unifying diagnostic approach to pelvic floor and anorectal dysfunction. *Am J Roentgenol* 1997;169:759-67.
7. Levine MS, Rubesin SE, Laufer I. Barium studies in Modern Radiology: Do they have a role? *Radiology* 2009;250:18-22.
8. Somers S, Bartram C, Fielding JR, Lee KH, Gore RM. Dynamic evaluation of the anorectum. In: Gore RM, Levine MS, eds. *Textbook of gastrointestinal radiology*. 3<sup>rd</sup> ed. Philadelphia, Pa: Saunders; 2008. p. 969-87.
9. Rex DK, Lappas JC. Combined anorectal manometry and defecography in 50 consecutive adults with fecal incontinence. *Dis Colon Rectum* 1992;35:1040-5.
10. Stoker J, Rociu E, Wiersma TG, Lameris JS. Imaging of anorectal disease. *Br J Surg* 2000;87:10-27.
11. Weber AM, Abrams P, Brubaker L, Cundiff G, Davis G, Dmochowski RR, *et al.* The standardization of terminology for researchers in pelvic floor disorders. *Int Urogynecol J* 2001;12:178-86.
12. Maglinte DD, Kelvin FM, Hale DS, Benson JT. Dynamic cystoproctography: A unifying diagnostic approach to pelvic floor and anorectal dysfunction. *Am J Roentgenol* 1997;169:759-67.
13. Barnett JL, Hasler WL, Camilleri M. American Gastroenterological Association medical position statement on anorectal testing techniques. *American Gastroenterological Association. Gastroenterology* 1999;116:732-60.
14. Terra P, Stoker J. The current role of imaging techniques in fecal incontinence. *Eur Radiol* 2006;16:1727-36.
15. Shorvon PJ, Stevenson GW. Defecography: Setting up a service. *Br J Hosp Med* 1989;41:460-6.
16. Low VH, Ho LM, Freed KS. Vaginal opacification during defecography: Direction of vaginal migration aids in diagnosis of pelvic floor pathology. *Abdom Imaging* 1999;24:565-8.
17. Stoker J, Rociu E, Wiersma TG, Lameris JS. Imaging of anorectal disease. *Br J Surg* 2000;87:10-27.
18. Halligan S, Malouf A, Bartram CI, Marshall M, Hollings N, Kamm MA. Predictive value of impaired evacuation at proctography in diagnosing anismus. *Am J Roentgenol* 2001;177:633-6.
19. Goei R. Anorectal function in patients with defecation disorders and asymptomatic subjects: Evaluation with defecography. *Radiology* 1990;174:121-3.
20. Hetzer FH, Andreisek G, Tsagari C, Sahrbacher U, Weishaupt D. MR Defecography in patients with fecal incontinence: Imaging findings and their effect on surgical management. *Radiology* 2006;240:449-457.

**Cite this article as:** Kumar S, Sharma P, Andreisek G. Does conventional defecography has a role to play in evaluation of evacuatory disorders in Indian population?. *Indian J Radiol Imaging* 2013;23:92-6.

**Source of Support:** Nil, **Conflict of Interest:** None declared.