

Experience of Multiple Super-Selective Renal Angiographic Embolization (SRAE) After Minimally-Percutaneous Nephrolithotomy Haemorrhage: A Case Report

Liang Hu¹, Han Wu¹, Jiamin Wang², Yang Hu¹

¹Department of Urology, Affiliated Jinhua Hospital, Zhejiang University School of Medicine, Jinhua, People's Republic of China; ²Department of Intervention, Affiliated Jinhua Hospital, Zhejiang University School of Medicine, Jinhua, People's Republic of China

Correspondence: Yang Hu, Department of Urology, Affiliated Jinhua Hospital, Zhejiang University School of Medicine, Jinhua, People's Republic of China, Email yanghu2024@126.com

Abstract: Minimally invasive percutaneous nephrolithotomy (mini-PCNL) maintains a stone clearance rate similar to standard PCNL while reducing blood loss. Bleeding is a complex and serious complication that can arise after PCNL surgery. Pseudoaneurysm (PA) is an uncommon type of delayed bleeding problem, which affects less than 1% of patients after PCNL. The most effective treatment for severe post-PCNL hemorrhage is super-selective renal angiographic embolization (SRAE), but it can fail in some patients and require additional surgical intervention. This report details the case of a male patient, 55 years old, who experienced severe bleeding four times and had three SRAE procedures and one laparoscopic procedure after PCNL. The presence of a renal artery pseudoaneurysm was not initially identified during the first two attempts of angiography due to arterial spasm and a small, undeveloped lesion. This case report is intended to enhance awareness of tiny pseudoaneurysms, emphasizing the importance of avoiding oversight to improve the success rate of embolization.

Keywords: super-selective renal angiographic embolization, percutaneous nephrolithotomy, haemorrhage, case

Introduction

The primary postoperative complications of PCNL are bleeding, infection, and organ damage.¹ Compared to standard PCNL, minimally invasive percutaneous nephrolithotomy (mini-PCNL) can reduce blood loss while maintaining a similar stone clearance rate.² SRAE is the most effective means for severe post-PCNL hemorrhage, embolization of renal artery branches can be achieved by using microcatheters inserted coaxially in a guidewire. Different embolic agents are accessible to treat vascular injuries of PCNL counting coils, particulate agents, and liquid agents. The clinical observations outlined in this case report depict an uncommon scenario with challenging and hard-to-manage excessive bleeding following a mini-PCNL. These experiences can be utilized to provide information and aid in the management of comparable future occurrences.

Case Report

A 55-year-old male patient was admitted to the hospital, presenting with multiple calculi located in the left pelvis and lower calyx (Figure 1). The patient received a mini-PCNL (16Fr) procedure while under general anesthesia in the prone position. Earlier, a 6 Fr ureteral catheter was placed in the patient while they were in the prone leg-split posture. Normal saline was infused via the ureteral catheter to induce artificial hydronephrosis. Then, the middle calyx puncture was performed under ultrasound guidance. 16 Fr dilatation was performed over the guide wire with the help of dilators and a sheath was placed. Following the PCNL surgery, both an F14 nephrostomy tube and an F6 ureteral stent were

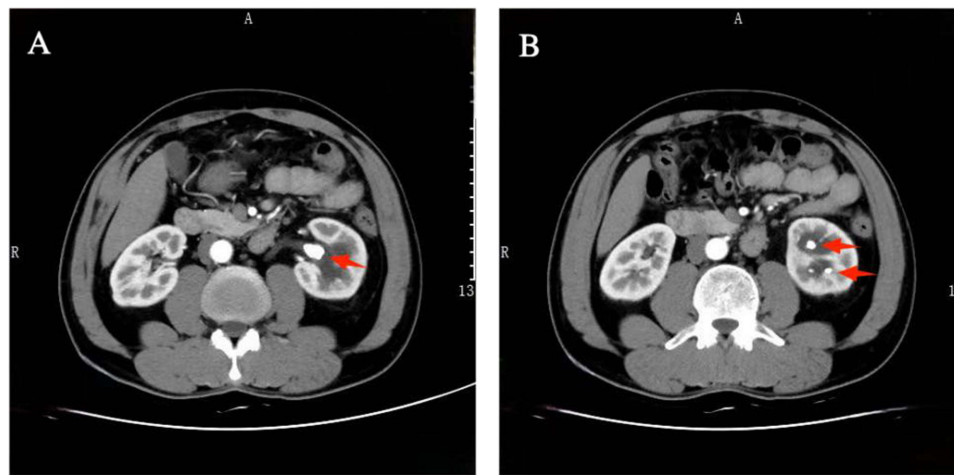


Figure 1 Preoperative CT images. **(A)** Showing calculi (red arrow) in the left pelvis. **(B)** Showing multiple calculi (red arrows) in lower calyx at a transverse plane.

successfully inserted. After the procedure, the catheter produced urine that was pink in color, and the nephrostomy tube was sealed. The second day after PCNL, the patient felt bursting pain in the left renal region, and fresh blood was observed in the nephrostomy tube. The Hb (hemoglobin concentration) decreased by 33 g/L, and the patient received a transfusion of 4 units of blood. The catheter produced urine of a pale yellow color, suggesting that the bleeding had been momentarily halted. On the day following the bleeding, the catheter produced pee that contained recently released blood. Renal angiography was promptly conducted, revealing uniform staining and intact renal outlines with no signs of persistent bleeding. However, the doctor found a suspicious artery besides the nephrostomy tube. A 2*3mm coil was used to embolize the suspicious artery (**Figure 2**). Gradually, the patient's urine turned pale yellow, and the cautious course of therapy was continued. When the bleeding returned two weeks after PCNL, emergency digital subtraction angiography was carried out. After closely examining the first arteriography data, the physician observed that the artery proximal to the nephrostomy tube, which had been embolized during the first renal angiography, was now open again. This led him to conclude that there might be a vascular involved. The intervention doctor attempted to use a coil to embolize the

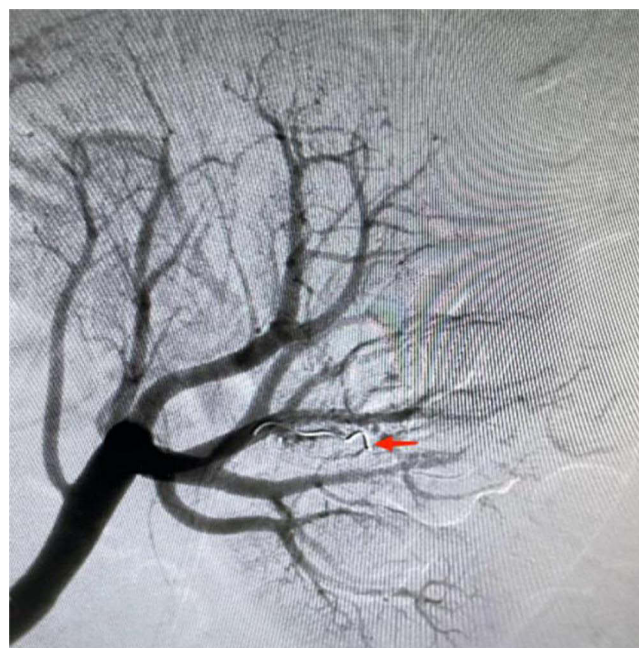

Figure 2 The first instance of SRAE showing the embolized artery with a coil (red arrow).

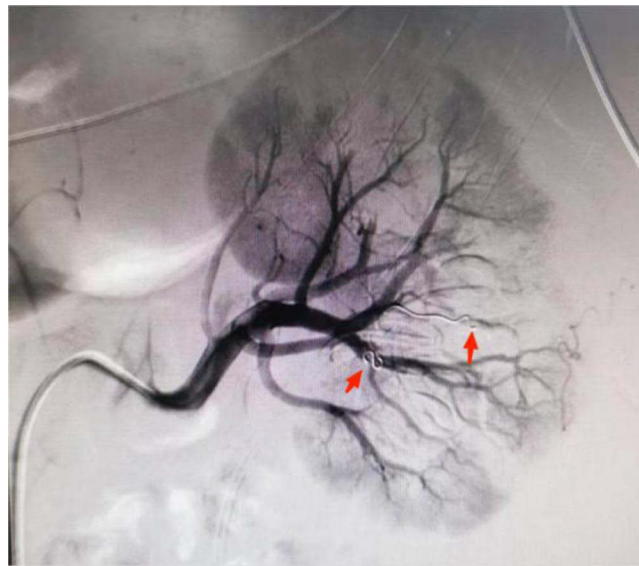


Figure 3 The second instance of SRAE showing the artery embolized with a gelatin sponge and an unobstructed lower polar artery (red arrows).

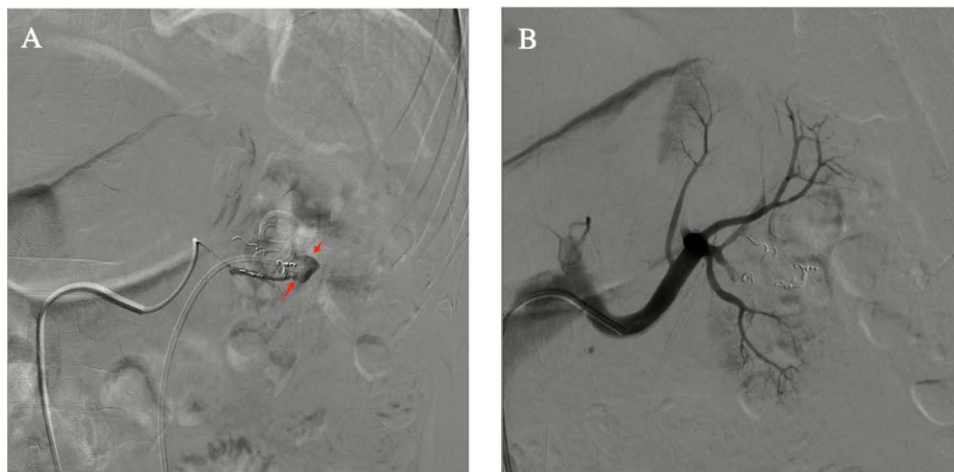

Figure 4 (A and B) DSA for the third time showing the presence of the pseudoaneurysm. **(A)** Showing the appearance of pseudoaneurysm (red arrows). **(B)** Showing the disappearance of the pseudoaneurysm after SRAE.

offending artery, but because the artery was too narrow, the coil fell into the lower polar artery. A gelatin sponge was used to embolize the offending artery (Figure 3). After the embolism, the patient still had extensive hematuria eight days later. To determine the cause of the bleeding, a general consultation was scheduled, and it was determined that laparoscopic renorrhaphy was the best option. Using a 2–0 barbed suture and a full-thickness monolayer, the puncture access site was located by laparoscopy.

There was a reappearance of severe bleeding three days following the laparoscopic procedure. A prompt and urgent third digital subtraction angiography (DSA) was conducted, revealing the presence of a cystic hyperdense lesion in the middle lower pole of the kidney, which strongly indicates the likelihood of a pseudoaneurysm (Figure 4). Super selective angiography was repeated, confirming that the pseudoaneurysm was the responsible lesion. Coils were employed to embolize the pseudoaneurysm to conduct embolization. Through maintaining the left kidney's residual vascularization and losing some parenchymal function, the pseudoaneurysm was effectively emboldened. After two days, hematuria vanished following embolization. At the three-month follow-up, the patient was still asymptomatic and no recurrence was discovered.

Discussion

PCNL is a well-established, commonly used procedure for treating large (>2 cm), complex upper urinary tract stones.³ The majority of complications that arise after PCNLs are minor; nonetheless, bleeding is among the most complex and potentially fatal. About 14% to 24% of individuals experience postoperative bleeding, and 0.8% of these patients need open surgery or angiographic embolization.⁴ Major causes of severe hemorrhage are pseudoaneurysm, arteriovenous fistula, and arterial laceration. Previous clinical experience has shown that delayed bleeding with vascular complications, such as pseudoaneurysm (PA) and arteriovenous fistula (AVF), occurs less than 1% after PCNL.⁵ Renal artery pseudoaneurysm (RAP) is a rare complication that can occur in patients who have undergone partial nephrectomy, renal biopsy, or trauma. It is also a very uncommon complication related to percutaneous nephrolithotomy. DSA, or digital subtraction angiography, is considered the most effective therapeutic option when conservative measures fail to address hematuria problems resulting after PCNL, or percutaneous nephrolithotomy. Several lines of evidence suggest that DSA should be performed as a diagnostic and therapeutic method.⁶ However, in certain cases, the first SRAE for severe post-PCNL hemorrhage fails, requiring additional surgical intervention. The bleeding was not noticed initially for some reason. Zhaohui et al⁷ identified a potential explanation for a lesion overlooked in the initial renal arteriography, suggesting it might be attributed to arterial spasm. Another such scenario could involve the slow decline in the wounded vessel's structural integrity. Alabat et al⁸ indicated that the major cause of unsuccessful initial renal artery embolization is missed embolization of tiny pseudoaneurysms and undetected arteriovenous fistula. Another important issue is the return of blood flow in embolized arteries. These authors stressed that in order to increase the success rate of hemostasis, it is critical to raise awareness of small pseudoaneurysms.

During the second renal angiography in this case, there was no sign of a renal artery pseudoaneurysm. We thoroughly examined the treatment data to determine why the minor inchoate lesion and arterial spasm caused us to miss the pseudoaneurysm. Furthermore, the radiologist's inexperience was regarded as an inevitable liability.

Despite the unsuccessful outcome of renorrhaphy in resolving the excessive bleeding in our situation, it nevertheless remains a viable option for treating patients who did not respond to initial superselective renal artery embolization. For instance, Aminsharifi et al⁹ performed partial nephrectomy or renorrhaphy in cases where angioembolization was unsuccessful following PCNL, to preserve kidney function.

This study provides a comprehensive description of the intricate treatment approach for a rare case involving a patient who had three cycles of angioembolization and laparoscopic surgery. Undergoing many surgical failures can cause significant trauma, even life-threatening worry, and severe psychological pressure on physicians as well as patients. Fortunately, we effectively managed the severe hemorrhage ultimately preserving the patient's life.

Conclusions

In summary, among the most complex and serious side effects of PCNL is bleeding. Hemorrhage can be treated by several techniques, including open surgery, SRAE, renorrhaphy, and conservative therapy. With a range of available drugs, an interventional radiologist with skill can successfully stop bleeding. The present clinical experience suggests that SRAE is a useful treatment for bleeding that occurs after PCNL and that the major reason embolization fails is because damaged arteries and small pseudoaneurysms were overlooked during renal arteriography. Improving the knowledge of small pseudoaneurysms and preventing lesion errors are intended to increase embolization success rates.

Data Sharing Statement

The data will be available from the corresponding author.

Ethics Approval and Consent to Participate

Ethical approval is not necessary because this is a case report based on the clinical data during the patient's hospitalization other than research and/or experiment. The patient has given his consent and authorized his clinical data in our report and signed the Patient Consent Form.

Consent for Publication

The patient has given his consent and authorized his clinical data in our report to be published.

Acknowledgments

The authors thank the patient for their commitment to this research.

Author Contributions

All authors made a significant contribution to the work reported, whether that is in the conception, study design, execution and interpretation, or in all these areas; took part in drafting, revising or critically reviewing the article; gave final approval of the version to be published; have agreed on the journal to which the article has been submitted; and agree to be accountable for all aspects of the work.

Funding

This case report was supported by the Key Project of Social Development of Jinhua Science and Technology Bureau of Zhejiang Province, China (No. 2021-3-079).

Disclosure

The authors declare that they have no competing interests in this work.

References

1. Seitz C, Desai M, Häcker A, et al. Incidence, prevention, and management of complications following percutaneous nephrolitholapaxy. *Europ Urol*. 2012;61(1):146–158. doi:10.1016/j.eururo.2011.09.016
2. Feng D, Hu X, Tang Y, Han P, Wei X. The efficacy and safety of miniaturized percutaneous nephrolithotomy versus standard percutaneous nephrolithotomy: a systematic review and meta-analysis of randomized controlled trials. *Invest Clin Urol*. 2020;61(2):115–126. doi:10.4111/icu.2020.61.2.115
3. Zeng G, Zhao Z, Mazzon G, et al. European association of urology section of urolithiasis and international alliance of urolithiasis joint consensus on retrograde intrarenal surgery for the management of renal stones. *Eur Urol Focus*. 2022;8(5):1461–1468. doi:10.1016/j.euf.2021.10.011
4. Kumar S, Pushkarna A, Ganesamoni R, Nanjappa B. Dengue hemorrhagic fever as a rare cause of bleeding following percutaneous nephrolithotomy. *Urol Res*. 2012;40(2):177–179. doi:10.1007/s00240-011-0394-6
5. Shadpour P, Yousefzadeh Kandevari N, Maghsoudi R, Etemadian M, Abian N. Introducing the POPVESL score for intrarenal vascular complications of percutaneous nephrolithotomy: experience from a single high-volume referral center. *Urol J*. 2020;18(3):277–283. doi:10.22037/uj.v16i7.5997
6. Kervancioglu S, Gelebek Yilmaz F, Erturhan S. Endovascular management of vascular complications after percutaneous nephrolithotomy. *VASA Z Gefasskrankheiten*. 2014;43(6):459–464. doi:10.1024/0301-1526/a000393
7. Zhaohui H, Hanqi L, Xiongbing L, Caixia Z, Shawpong W, Guohua Z. Analysis of repeated renal arteriography after percutaneous nephrolithotomy. *Urolithiasis*. 2017;45(5):495–499. doi:10.1007/s00240-016-0936-z
8. Alabat Roca A, Torrecilla Ortíz C, Cuadrado Campaña J, et al. Hemorrhagic complications after percutaneous nephrolithotomy: the importance of an early endovascular management. *Actas urológicas españolas*. 2021;45(10):635–641. doi:10.1016/j.acuroe.2021.10.002
9. Aminsharifi A, Irani D, Eslahi A. Massive hemorrhage after percutaneous nephrolithotomy: saving the kidney when angioembolization has failed or is unavailable. *Int J Surg*. 2014;12(8):872–876. doi:10.1016/j.ijssu.2014.07.004

Journal of Inflammation Research

Dovepress

Publish your work in this journal

The Journal of Inflammation Research is an international, peer-reviewed open-access journal that welcomes laboratory and clinical findings on the molecular basis, cell biology and pharmacology of inflammation including original research, reviews, symposium reports, hypothesis formation and commentaries on: acute/chronic inflammation; mediators of inflammation; cellular processes; molecular mechanisms; pharmacology and novel anti-inflammatory drugs; clinical conditions involving inflammation. The manuscript management system is completely online and includes a very quick and fair peer-review system. Visit <http://www.dovepress.com/testimonials.php> to read real quotes from published authors.

Submit your manuscript here: <https://www.dovepress.com/journal-of-inflammation-research-journal>