

# The relationships between the arrangement of teeth, root resorption, and dental maturity in bovine mandibular incisors

Jin-kyu An  
Yoshiro Matsumoto  
Takashi Ono

Department of Orthodontic Science,  
Division of Oral Health Sciences,  
Graduate School of Medical and Dental  
Sciences, Tokyo Medical and Dental  
University, Tokyo, Japan

**Objective:** The objective of this study is to investigate the eruption pattern and root resorption of the bovine anterior dentition in relation to growth-related parameters based on dental maturity. **Methods:** A cross-sectional study was conducted on 110 bovine anterior mandibles by using standard radiography, cone-beam computed tomography (CBCT), and actual measurements. We determined the relationships between the stages of dental maturity by using a modification of Demirjian's method and various growth-related parameters, such as the activity of the root-resorbing tissue and mobility of the deciduous teeth. The correlation of growth-related parameters with interdental spacing and distal unusual root resorption (DRR) of the deciduous fourth incisor was assessed. The cause of mesial unusual root resorption (MRR) of the deciduous fourth incisor was determined on the basis of the arrangement of the permanent third incisor. **Results:** An independent *t*-test and chi-square test indicated significant differences in growth-related parameters associated with dental arch length discrepancy and factors related to the shedding of deciduous teeth between the low and high dental maturity groups. The samples with interdental spacing and DRR showed a larger sum of mesiodistal permanent crown widths and higher dental maturity than did the respective controls. Samples with MRR tended to show a lingually rotated distal tip of the adjacent tooth crown. **Conclusions:** Dental maturity has relevance to the interdental spaces and unusual root resorption of mixed dentition. The position of the adjacent tooth crown on CBCT may be correlated with the occurrence of unusual root resorption of the incisor.

[Korean J Orthod 2017;47(6):365-374]

**Key words:** Growth and development, Root resorption, Ectopic eruption, Computed tomography

Received February 1, 2017; Revised May 2, 2017; Accepted May 26, 2017.

**Corresponding author:** Yoshiro Matsumoto.

Junior Associate Professor, Department of Orthodontic Science, Division of Oral Health Sciences, Graduate School of Medical and Dental Sciences, Tokyo Medical and Dental University, 1-5-45, Yushima, Bunkyo-ku, Tokyo 113-8549, Japan.

Tel +81-3-5803-5527 e-mail y.matsumoto.orts@tmd.ac.jp

The authors report no commercial, proprietary, or financial interest in the products or companies described in this article.

© 2017 The Korean Association of Orthodontists.

This is an Open Access article distributed under the terms of the Creative Commons Attribution Non-Commercial License (<http://creativecommons.org/licenses/by-nc/4.0>) which permits unrestricted non-commercial use, distribution, and reproduction in any medium, provided the original work is properly cited.

## INTRODUCTION

Assessment of patients' dental maturity and growth-related parameters is one of the most basic and important elements in orthodontic treatment.<sup>1</sup> Information about dental maturity and growth-related parameters in the mixed dentition plays a significant role in diagnosis, determination of treatment objectives, and selection of treatment methods.<sup>2,3</sup> Clinical decisions on orthodontic treatments, such as tooth extraction and the use of functional appliances, are based on the assessment of a patient's dental maturity.<sup>4</sup> Since dental maturity varies according to each person's unique biological clock, personalized assessment is necessary.<sup>5</sup>

For estimating dental maturity, using criteria based on tooth development is regarded as the most accurate method.<sup>6,7</sup> Demirjian's method, which takes into account tooth formation of seven teeth of the left mandible, is widely used and recognized as one of the best evaluation methods of dental maturity.<sup>7</sup>

Previous research on the analyses of deciduous dentition for predicting dental arch-length discrepancies and arrangement of teeth in the permanent dentition have indicated that the spacing of the deciduous anterior teeth is significantly related to the mesiodistal crown diameter and intercanine arch width.<sup>8-10</sup> A study by el-Nofely et al.<sup>10</sup> showed that the crowns are significantly broader and the arches significantly narrower in patients without interdental spaces than in those with interdental spaces. However, the association between dental maturity and tooth arrangement in the mixed dentition remains unclear.

In the mixed dentition, dental maturity and eruption path have been investigated as factors that predispose adjacent permanent lateral and central incisors to resorption caused by ectopic eruption of the maxillary canines<sup>11,12</sup> and transmigration of impacted mandibular canines.<sup>13</sup> A study by Ericson and Kurol<sup>11</sup> reported that compared to control cases, the resorption cases showed more advanced lateral incisor and canine development, more medial canine position in the dental arch, and slightly more mesial horizontal path of eruption. A study by Rozylo-Kalinowska et al.<sup>12</sup> showed that patients with impacted maxillary canines have significantly reduced dental maturity than do patients with erupted maxillary canines. Although mandibular canine impaction and transmigration are common, their etiologies remain unclear.<sup>13</sup> An additional investigation into the relationships between dental maturity, unusual root resorption, and eruption tooth angulation on cone-beam computed tomography (CBCT) is necessary.

The relationship between the various stages of tooth development and some growth-related parameters, such as hand-wrist bone growth, have been reported

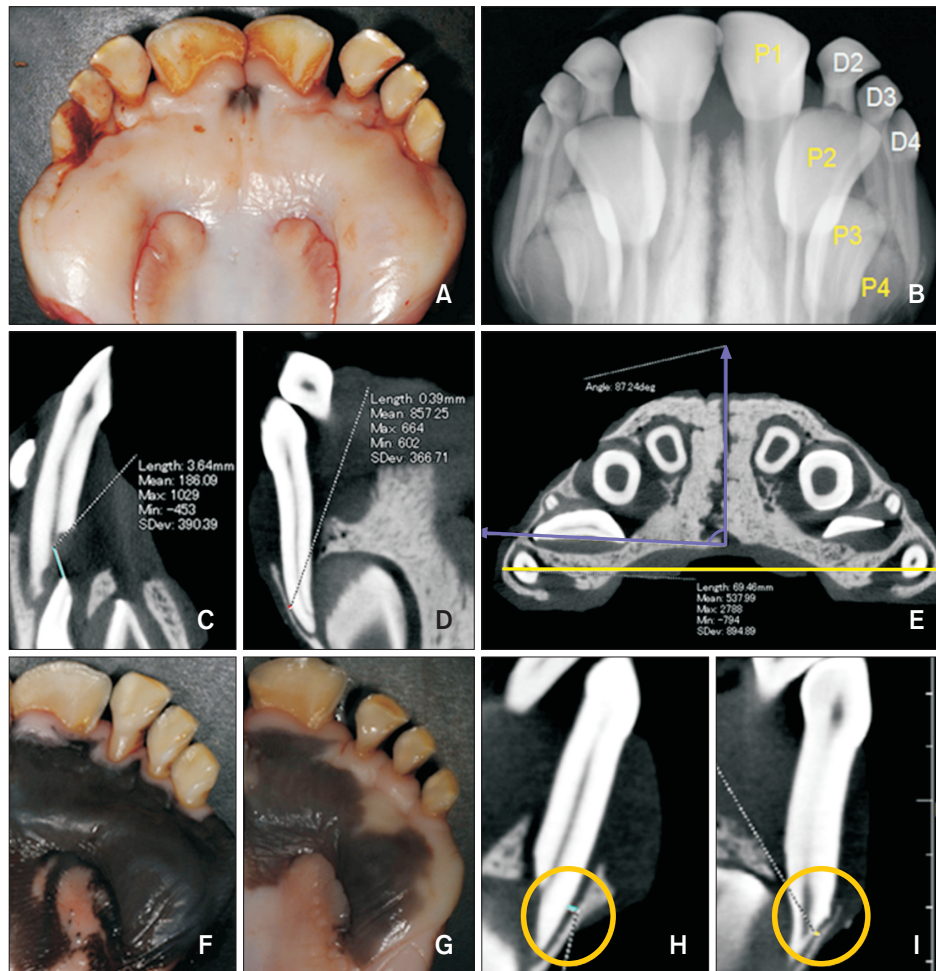
previously.<sup>5,6</sup> However, the role of other parameters, such as the activity of the root-resorbing tissue (RRT) and mobility of deciduous teeth, remains unclear.

Therefore, this study aimed to evaluate the relationships between the stages of dental maturity, aspect of interdental spaces, and unusual root resorption in bovine mixed dentition. In addition, we investigated the eruption pattern of permanent incisors in the alveolar bone and root resorption of the bovine anterior dentition.

## MATERIALS AND METHODS

The following experimental procedures were conducted according to the institutional guidelines of research ethics, even though these experimental designs did not require approval by the Institutional Animal Ethics Committee. A cross-sectional study was conducted on 110 bovine anterior mandibles by using standard radiography, CBCT, and actual measurements. The inclusion criteria were as follows: (1) Japanese male cattle aged 24 to 29 months old; (2) samples obtained within 12 hours of slaughter; (3) no history of congenital and systemic disorders; and (4) no missing permanent incisors. The samples of the anterior mandible consisted of two to three types of deciduous incisors and four types of permanent incisors: second deciduous incisor (D2), third deciduous incisor (D3), fourth deciduous incisor (D4), first permanent incisor (P1), second permanent incisor (P2), third permanent incisor (P3), and fourth permanent incisor (P4). During the investigation period, the D3 and D4 were not shed. However, the D2 was shed in about half of the samples.

Standard radiography was used to evaluate the relationship between the deciduous teeth and their subsequent teeth (Figure 1A and 1B). The radiographic settings for CBCT (FineCube; Yoshida, Inc., Tokyo, Japan) included a tube voltage of 90 kV and a tube current of 4 mA. The sagittal, coronal, and horizontal directions were set as references based on the methods described by Saka et al.<sup>14</sup> The sagittal and coronal directions consisted of the area perpendicular to the Frankfurt plane, and the horizontal directions consisted of the area parallel to the Frankfurt plane. The sagittal direction contained the plane that connected the widest contour point of the buccal and lingual cervical lines, and the coronal direction contained the plane that connected the mesioincisal and distoincisal angles of the tooth.<sup>14</sup> In our study, the position with the center axis of the dental pulp of D3 and D4 projected in the sagittal and coronal directions, and the thickest mandibular width was selected in the horizontal position. The shortest distance between the root surface of D3 and the crown of P3 was measured by setting sections in the sagittal



**Figure 1.** Anterior deciduous and permanent teeth of the cattle, measurements on cone-beam computed tomographic images, classification with respect to spaced dentition, and distal unusual root resorption of the fourth deciduous incisor root (DRR). A, Lingual view; B, standard radiographic image in the same position; C, section in the sagittal direction; D, section in the coronal direction; E, section in the horizontal direction; F, non-spacing group; G, spacing group; H, non-DRR group; I, DRR group.

In the sagittal direction, from the plane perpendicular to the Frankfurt plane, the shortest distance between the root surface of D3 and crown of P3 is measured (C). In the coronal direction, from the plane perpendicular to the Frankfurt plane, the narrowest thickness of the periodontal ligament space in the D4 distal root surface is measured (D). In the horizontal directions, in the area parallel to the Frankfurt plane, the longest mandibular bone width and angulation of the P3 crown are measured (E). Black line, mandibular bone width; vertical white line, median suture line; horizontal white line, mesio-distal line of the P3 crown; white angle, angulation of the P3 crown (E). Based on the aspect of spaced dentition, the samples are classified into two groups. The non-spacing group (F) shows no interdental spaces in the deciduous dentition. The spacing group (G) has interdental spaces between the deciduous teeth. Based on the occurrence of DRR, the samples are classified into two groups: non-DRR (H) and DRR groups (I). DRR occurs at the site wherein the distal root surface of D4 is in contact with the alveolar bone.

P1, First anterior permanent incisor; P2, second permanent incisor; P3, third anterior permanent incisor; P4, fourth anterior permanent incisor; D2, second deciduous incisor; D3, third deciduous incisor; D4, fourth deciduous incisor.

directions (Figure 1C). The thickness of the periodontal ligament (PDL) space at the distal root surface of D4 was measured by setting sections in the coronal directions (Figure 1D). Mandibular bone width was defined as the

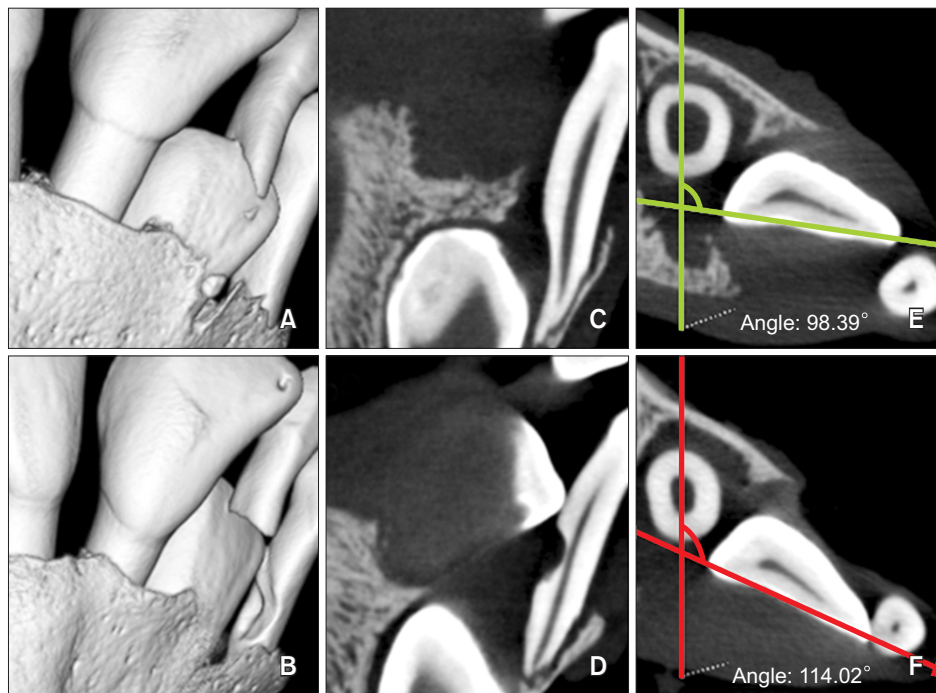
longest linear distance between the right and left sides of the alveolar bone surface in the horizontal section. The angulation of the P3 crown, defined as the angle formed by the median suture line and the mesiodistal

axis of the P3 crown, was measured in the position wherein the distal tip of the P3 crown was reflected by setting sections in the horizontal directions (Figure 1E). The linear and angular measurements were acquired using a computer software (FineCube 3D viewer, ver. 2.5.3.1; Yoshida, Inc.) linked with FineCube. Assessments of tooth mobility were performed according to Miller's classification. The RRT between the deciduous root and dental follicle of the permanent incisors was classified into two color groups, red and white, based on the color classification scheme described by Oguchi.<sup>15</sup> The permanent root lengths were measured using an electronic caliper after tooth extraction based on Lind's method.<sup>16</sup> Based on the remaining root length of the deciduous teeth, the resorption rate of D3 was evaluated and divided into two phases, i.e., above 2/3 resorption and below 2/3 resorption. The available arch length and the sum of the mesiodistal crown width were measured from the actual sample by using an electronic caliper. The available arch length is the sum of the left and right distances from the mesial tip of P1 to the distal tip of

D4, while the sum of the mesiodistal crown width is obtained by adding the widths of all permanent teeth from P1 to P4. The sum of the mesiodistal crown width of the deciduous teeth was calculated for only those samples with remaining D2s. The dental arch-length discrepancy was calculated by subtracting the sum of the mesiodistal crown width from the available arch length. The presence of unusual root resorption was determined through a radiographic examination and actual measurements.

#### Classification criteria

Based on Demirjian's method,<sup>7</sup> dental maturity was classified into eight stages ranging from A to H. In this study, based on the differences between the cattle and humans in crown-root height ratio, a modification of Demirjian's method was used, wherein the criterion of stage E was changed from "root length < crown height" to "root length < 1/2 the crown height" and the criterion of stage F was changed from "root length  $\geq$  crown height" to "root length  $\geq$  1/2 the crown height"



**Figure 2.** Comparison between the unaffected controls and the samples with mesial unusual root resorption of the fourth deciduous incisors (MRR) by using cone-beam computed tomographic three- and two-dimensional images.

The vertical position of the P3 crown and resorption degree of the D3 root are similar in both samples. The distal tip of the P3 crown is located on the labial side with respect to the D4 root in normal samples (A), and the lingual side in MRR samples (B). The contact between the distal tip of the P3 crown and the D4 root surface occurs only in MRR samples in the coronal section (C, D). Angulation of the P3 crown is higher in the samples with MRR (F) than in the normal samples (E) in the horizontal section.

Horizontal line in (E) and (F), mesio-distal line of the P3 crown; vertical line in (E) and (F), a line parallel to the median suture line.

in bovine incisors. The P3 and P4 were used in this analysis, since the P1 and P2 showed no variation in dental maturity (P1: stage G; P2: stage F). The low-maturity group ( $n = 50$ ) included samples with P3 in stage E and P4 in stage C, whereas the high-maturity group ( $n = 50$ ) included samples with P3 in stage F and P4 in stage D. Samples that did not meet the criteria of P3 or P4 were excluded.

Forty-three samples with D2 were classified into the following two groups based on the interdental space; the spacing group ( $n = 11$ ) with developing interdental spaces between all remaining deciduous incisors (D2, D3, and D4) and the non-spacing group ( $n = 32$ ) with no interdental space between the deciduous teeth (Figure 1F and 1G).

One hundred samples that were selected on the basis of dental maturity were classified into two groups based on the presence of the distal unusual root resorption of D4 (DRR) that faced toward the lateral alveolar bone instead of the dental follicle of P4. The samples with DRR were classified into the DRR group ( $n = 12$ ) and the rest into the non-DRR group ( $n = 88$ ) if only physiological root resorption had occurred. Two samples showed mesial unusual root resorption of D4 (MRR) that did not face the dental follicle of P4. Since the number of samples was too small to classify ( $n = 2$ ), they were analyzed on the basis of CBCT findings instead of an independent *t*-test (Figure 2).

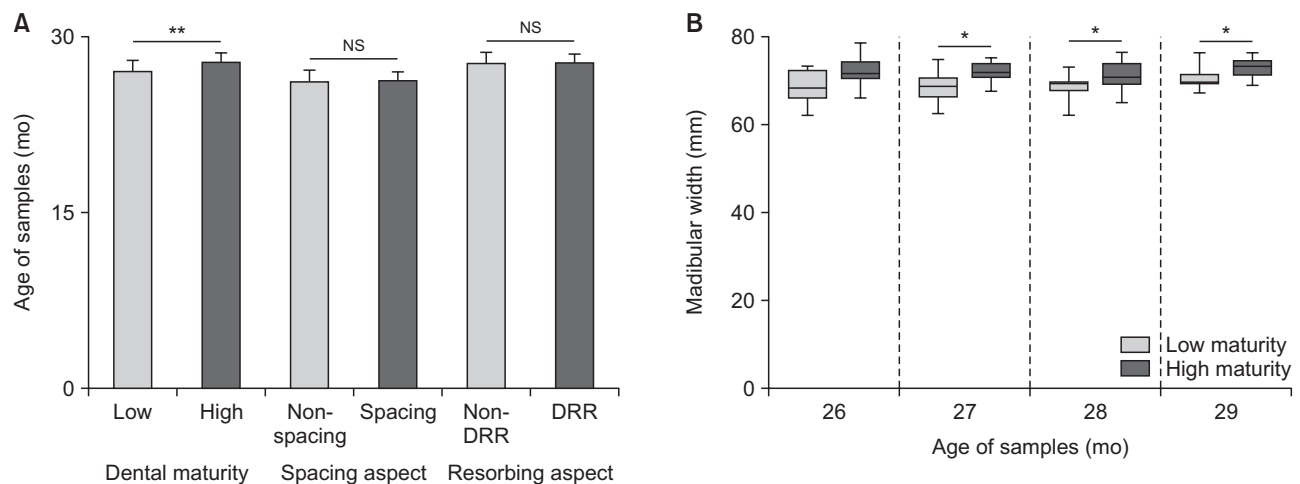
### Statistical analysis

Statistical analysis was performed using PASW Statistics for Windows, version 18.0 (IBM Co., Armonk, NY, USA). The relationships between dental maturity and growth-related parameters were analyzed. The relationships between growth-related parameters and spaced dentition and the presence of DRR were investigated using an independent *t*-test and chi-square test. The relationship between dental maturity and factors related to the shedding of deciduous incisors was analyzed using a chi-square test. A *p*-value less than 0.05 was considered statistically significant.

## RESULTS

No unusual root resorption was observed in the permanent teeth. In contrast, in the deciduous teeth, unusual root resorption was found in DRR ( $n = 12$ ) and MRR ( $n = 2$ ) (Figure 1H and 1I, and Figure 2). For classifying the samples based on the criteria of dental maturity, the mean ages of the low- and high-maturity groups were  $27.3 \pm 1.3$  months and  $28.3 \pm 1.1$  months, respectively. The independent *t*-test results indicated a significant difference in age between the groups ( $p < 0.001$ ). However, no significant differences in age were observed between the spacing and non-spacing groups, and between the DRR group and its unaffected control group (Figure 3A).

The relationships between dental maturity and gro-



**Figure 3.** Comparison of chronological age based on dental maturity, spacing aspect, and root-resorbing aspect (A), and comparison of mandibular bone width in the same age range (B). A significant difference between the low and high dental maturity groups is observed (low maturity,  $27.3 \pm 1.3$  months; high maturity,  $28.3 \pm 1.1$  months). However, no significant difference (NS) is observed between the spacing and non-spacing groups (non-spacing,  $26.5 \pm 1.3$  months; spacing,  $26.7 \pm 1.3$  months), and between the distal unusual root resorption (DRR) group and the non-DRR group (non-DRR,  $27.8 \pm 1.4$  months; DRR,  $28.1 \pm 1.0$  months). In the same age range, the mandibular width is higher in the high-maturity than low-maturity samples. The samples with high maturity show a tendency towards a high skeletal growth status ( $*p < 0.05$ ,  $**p < 0.001$ ).

**Table 1.** Comparison between the two groups based on differences in dental maturity, presence of interdental spaces among the incisors, and presence of DRR of D4

Variable	Dental maturity		p-value	Dentition		p-value	Distal surface of D4		p-value
	Low (n = 50)	High (n = 50)		Non-spacing (n = 32)	Spacing (n = 11)		Non-DRR (n = 88)	DRR (n = 12)	
Mandibular bone width	70.0 ± 3.3	73.0 ± 2.9	0.000 <sup>†</sup>	69.0 ± 3.1	71.6 ± 3.8	0.047*	71.6 ± 3.4	71.5 ± 4.3	NS
Available arch length	85.7 ± 5.9	94.1 ± 5.6	0.000 <sup>†</sup>	82.8 ± 5.1	90.2 ± 3.5	0.000 <sup>†</sup>	89.4 ± 7.4	93.7 ± 2.9	NS
Sum of mesiodistal crown width <sup>a</sup>	114.6 ± 6.4	116.7 ± 5.8	NS	113.0 ± 6.7	119.1 ± 3.1	0.006**	115.3 ± 6.3	119.2 ± 4.8	0.039*
Dental arch length discrepancy	-28.8 ± 6.1	-22.5 ± 7.1	0.000 <sup>†</sup>	-30.4 ± 5.7	-28.9 ± 3.0	NS	-25.7 ± 7.6	-25.5 ± 4.8	NS
Root length									
P1	21.6 ± 1.7	22.5 ± 1.9	0.011*	21.7 ± 1.7	22.7 ± 1.6	NS	22.1 ± 1.8	22.4 ± 1.9	NS
P2	17.6 ± 2.7	21.6 ± 2.0	0.000 <sup>†</sup>	16.9 ± 2.6	18.8 ± 2.2	NS	19.6 ± 3.2	20.5 ± 2.4	NS
P3	7.1 ± 2.5	12.8 ± 2.4	0.000 <sup>†</sup>	6.8 ± 3.0	8.3 ± 2.5	NS	9.9 ± 3.8	11.1 ± 3.2	NS
P4	0.0 ± 0.0	3.8 ± 1.4	0.000 <sup>†</sup>	0.8 ± 0.8	1.4 ± 1.8	NS	2.0 ± 2.0	2.8 ± 1.6	NS
PDL space width of D4 <sup>b</sup>	0.7 ± 0.1	0.6 ± 0.1	NS	0.7 ± 0.1	0.6 ± 0.1	NS	0.7 ± 0.1	0.4 ± 0.1	0.006**
Distance from D3 to P3 <sup>c</sup>	2.0 ± 1.4	1.2 ± 1.2	0.000 <sup>†</sup>	2.816	2.2 ± 1.2	NS	1.8 ± 1.5	1.5 ± 1.4	NS
Angle <sup>d</sup> of P3 crown	71.7 ± 10.1	83.9 ± 11.9	0.000 <sup>†</sup>	69.1 ± 8.7	69.0 ± 10.7	NS	76.2 ± 13.8	82.3 ± 10.3	NS

Values are presented as mean ± standard deviation (mm or degree).

DRR, Distal unusual root resorption; P1, first permanent incisor; P2, second permanent incisor; P3, third permanent incisor; P4, fourth permanent incisor; D3, third deciduous incisor; D4, fourth deciduous incisor; NS, not significant.

<sup>a</sup>Sum of the mesiodistal widths of all crowns in the permanent incisors; <sup>b</sup>the shortest width of the periodontal ligament (PDL) space between the distal root surface of apical D4 and the alveolar bone; <sup>c</sup>the shortest distance from the root surface of D3 to the crown of P3; <sup>d</sup>the angle formed by the median suture line and the axis of the P3 crown. The p-values are results of analysis using an independent t-test (\*p < 0.05, \*\*p < 0.01, <sup>†</sup>p < 0.001).

with-related parameters were observed by comparing the low- and high-maturity groups. Between the two groups, significant differences in mandibular bone width, dental arch-length discrepancy, root lengths of all permanent incisors, distance from the root surface of D3 to the dental follicle of P3, and angle of the P3 crown were observed. However, no significant differences were observed in the sum of the mesiodistal permanent crown width and PDL space width of D4 (Table 1). After adjusting the two groups to the same age range, the high-maturity group showed a larger mandibular bone width than did the low-maturity group (Figure 3B). The samples with interdental spaces showed a higher mandibular bone width, available arch length, and sum of mesiodistal permanent crown width than did the unaffected controls. However, the sum of mesiodistal deciduous crown widths showed no significant differences. The samples from the DRR group showed a higher sum of mesiodistal permanent crown widths and lower distal PDL space widths of D4 than did the unaffected controls (Table 1). Dental maturity showed a significant relationship with factors related to the shedding of deciduous teeth (Table 2). Samples with interdental spacing or DRR tended to show high dental maturity (Table 3). The distal tip of the P3 crown

**Table 2.** The relationship between dental maturity and the factors related to the shedding of deciduous incisors

Factor	Dental maturity		$\chi^2$ (p-value)
	Low (n = 50)	High (n = 50)	
Existence of D2			21.583 (0.000 <sup>†</sup> )
Persistence	33 (66.0)	10 (20.0)	
Shedding	17 (34.0)	40 (80.0)	
Resorption rate of D3			36.058 (0.000 <sup>†</sup> )
Below 2/3	41 (82.0)	11 (22.0)	
Above 2/3	9 (18.0)	39 (78.0)	
RRT color of P3			10.928 (0.001 <sup>**</sup> )
White	22 (44.0)	7 (14.0)	
Red	28 (56.0)	43 (86.0)	
Mobility of D3			30.133 (0.000 <sup>†</sup> )
M1	4 (8.0)	0 (0.0)	
M2	35 (70.0)	12 (24.0)	
M3	11 (22.0)	38 (76.0)	

Values are presented as number (%). D2, Second deciduous incisor; D3, third deciduous incisor; P3, third permanent incisor; RRT, root-resorbing tissue. M1, M2, and M3: mobility 1, 2, and 3, respectively, of Miller’s classification. The p-values are results of analysis using a chi-square test (\*\*p < 0.01, <sup>†</sup>p < 0.001).

was rotated relatively more lingually to the D4 crown in the MRR samples than in the normal samples (Table 4, Figure 2).

## DISCUSSION

Owing to the ethical problems associated with radiation exposure in humans, we designed the experiment to use bovine teeth and surrounding tissue that are similar to those of humans.

### Dental maturity assessment in the cattle

Dental maturity in mammals can be assessed using two methods, i.e., clinical visualization of erupting teeth<sup>17</sup> and radiographic investigation.<sup>6,7</sup> The use of

**Table 3.** The relationship between dental maturity and the aspect of resorbing or spacing

Factor	Dental maturity			$\chi^2$ (p-value)
	Low	High	Total	
Resorbing aspect				6.061 (0.014 <sup>*</sup> )
Non-DRR	48 (96.0)	40 (80.0)	88	
DRR	2 (4.0)	10 (20.0)	12	
Total	50 (100.0)	50 (100.0)	100	
Spacing aspect				5.213 (0.022 <sup>*</sup> )
Non-spacing	26 (83.9)	6 (50.0)	32	
Spacing	5 (16.1)	6 (50.0)	11	
Total	31 (100.0)	12 (100.0)	43	

Values are presented as number (%). DRR, Distal unusual root resorption of the fourth deciduous incisor. The p-values are results of analysis using a chi-square test (\*p < 0.05).

**Table 4.** The relevance of the crown position of the third mandibular permanent incisor and the occurrence of MRR of the root of D4

Factor	MRR(+) (n = 2)	MRR(-) (n = 108)	Total
Angle of P3 crown			
Below 100°	0 (0.0)	102 (94.4)	102
Above 100°	2 (100.0)	6 (5.6)	8
P3 follicle to root of D4*			
No contact	0 (0.0)	85 (78.7)	85
Contact	2 (100.0)	23 (21.3)	25

MRR, Mesial unusual root resorption; D4, fourth deciduous incisor; P3, third permanent incisor. \*Relationship of the P3 follicle to the root of D4.

the eruption stage of teeth, such as the maxillary first and second molars, is an economical method, since dental maturity can be evaluated without radiographic equipment.<sup>18</sup> Although eruption stages are useful for assessing dental maturity, a more accurate assessment is based on the stages of tooth formation in mammals.<sup>19,20</sup> In this study, we used the widely accepted dental maturation standard described in a study by Demirjian et al.<sup>7</sup> The dental maturation criteria in Demirjian's method are applicable to bovine teeth since the method is based on the proportion of root length, and uses its relative value to crown height rather than to absolute length.

### Eruption mechanisms in the cattle

The eruption of mandibular anterior deciduous dentition in cattle is completed by the age of approximately 24 months, and eruption of the permanent dentition is completed by the age of approximately 48 months. The tooth germs of the anterior permanent incisors of cattle are positioned lingually to their deciduous teeth and continue to move occlusally.<sup>20</sup> The eruption sequence in cattle consists of the eruption of a central incisor first and then a lateral incisor. The movement of the permanent teeth germs in cattle is also similar to that in humans, but the eruption mechanism is significantly different. The ratio of the completion period of deciduous anterior dentition eruption to that of permanent anterior dentition eruption is approximately 1:1 in cattle and 1:7 in humans.<sup>20</sup>

### Dental maturity and growth-related parameters

In Demirjian's method, the individual radiological appearance of the seven permanent teeth on the left side of the mandible was evaluated according to the dental maturity criteria for the different stages of calcification of the permanent teeth.<sup>7</sup> Using criteria based on a modification of Demirjian's method, we classified the samples into the low- and high-maturity groups. Although the difference in the average age of the two groups was not higher than 1 month, significant differences were observed in many growth-related parameters. This observation corresponded with the findings of a study by Boulanger,<sup>21</sup> which reported a correlation between root formation and skeletal development. The dental arch between both sides of the deciduous canines in humans and between both sides of the D4 in cattle is similar to a straight line.<sup>22</sup> Hence, the growth pattern of the intercanine width in humans corresponds with our findings on available arch-length width in cattle. A study by Saka et al.<sup>14</sup> reported the relationship between the position of the primary teeth and successive permanent teeth by utilizing the distance from the roots of the primary maxillary canine to the bony crypt of the canine. Their findings corresponded

with our findings.

In this study, we determined the factors related to the shedding of deciduous teeth. The rate of root resorption, persistent teeth, and tooth mobility were significantly correlated to dental maturity, corroborating Nanda's report on dental shedding in humans.<sup>23</sup> The RRT, which lies between the root of the deciduous tooth and its permanent tooth follicle, is responsible for root resorption of the deciduous tooth. Oguchi<sup>15</sup> described two phases of RRT in bovine teeth that included the active phase, which is reddish because of the rich blood supply, and the resting phase, which is whitish because of the poor blood supply. In this study, we further showed that the red color of the RRT was related to dental maturity.

### Spaced dentition

Spacing that occurs in the primary dentition is considered a common condition and constitutes an important feature of the dentition, since it is an indicator of favorable development of a permanent occlusion.<sup>24</sup> The incidence of spacing in the primary dentition varies from 42.9% to 98%. The most marked spaces, termed primate spaces, present mesial to canines in the maxilla and distal to canines in the mandible.<sup>25</sup> However, a study by Sriram et al.<sup>24</sup> reported the frequent occurrence of physiological spaces between the deciduous incisors in the primary dentition in humans.

Significant differences were found in the mandibular bone width, available arch length, and sum of mesiodistal crown width only in the permanent teeth between the spacing and non-spacing groups. The results on dental arch and mesiodistal crown width in the interdental spaced dentition corroborated with the findings of a study by el-Nofely et al.,<sup>10</sup> who reported significantly narrower dental arches in cases with no spaces compared to those with spaces, as well as the occurrence of deciduous arch spacing due to high mesiodistal crown diameters of the permanent successors. In general, the relationship between the two groups showed similarities to the relationship between the low- and high-maturity groups, but the spacing group showed a higher *p*-value in the sum of mesiodistal crown widths and a lower *p*-value in the sum of mandibular bone widths. These findings suggested that the physiological spaces between the deciduous incisors are potential evaluation criteria for prescribing an examination of the disproportion between the jaw and tooth size.

### Unusual root resorption

Two types of unusual root resorption, DRR and MRR, were observed in the distal and mesial surface of the D4 root. In DRR samples, the sum of mesiodistal crown



widths was larger and the PDL space in the D4 distal root surface was narrower. These findings corresponded with those of a study by Krishnan and Davidovitch,<sup>26</sup> which showed a narrowing of the PDL space and deformation of the alveolar bone on the side toward which the tooth is moved to as a result of the eruption pressure. Based on these findings, a crown width relatively larger than the mandibular bone width could generate an eruption pressure in the lateral direction. In addition, resorption of the distal root surface of a D4 occurs by a process similar to orthodontic root resorption. Collectively, this explains the occurrence of DRR on both sides in this study.

In the MRR samples, the distal tip of the P3 crown was inclined towards the lingual side and positioned close to the D4 root, corresponding to Ericson et al.'s report<sup>27</sup> that root resorption of the permanent maxillary incisors after the eruption of the maxillary canines is probably caused by physical contact between the incisor and the canine and by the eruption pressure exerted by the canine. MRR showed similarity to the unusual clinical root resorption cases of maxillary lateral incisors caused by an adjacent eruption of canines. A previously proposed method uses the angle formed by the impacted tooth axis on an orthopantomograph for detecting root resorption of the impacted maxillary canine adjacent teeth. Studies by Schindel and Sheinis<sup>28</sup> and Guarnieri et al.<sup>29</sup> used the angle formed by the canine inclination to the axis of the lateral incisor. The current study suggested the possibility of using the angle formed by the crown rotation of an adjacent erupting tooth on the horizontal section in CBCT as an indicator of unusual root resorption and should be confirmed in human study.

## CONCLUSION

This study showed that dental maturity has relevance to the interdental spaces and unusual root resorption of the mixed dentition. The position of an adjacent tooth crown on the horizontal section in CBCT could be a predictor of unusual root resorption caused by the adjacent tooth. However, further longitudinal studies are necessary for evaluating the application of this method in early orthodontic diagnosis and intervention.

## ACKNOWLEDGEMENTS

The authors express their gratitude to the staff members of our department for their kind advice. This study was financially supported by JSPS KAKENHI Grant Numbers 23593022 and 15K11344. There are no conflicts of interest to declare.

## REFERENCES

1. Hixon EH, Oldfather RE. Estimation of the sizes of unerupted cuspid and bicuspid teeth. *Angle Orthod* 1958;28:236-40.
2. Bagherpour A, Pousti M, Adelianfar E. Hand skeletal maturity and its correlation with mandibular dental development. *J Clin Exp Dent* 2014;6:e275-9.
3. Muller-Bolla M, Lupi-Pégurier L, Quatrehomme G, Velly AM, Bolla M. Age estimation from teeth in children and adolescents. *J Forensic Sci* 2003;48:140-8.
4. Green LJ. The interrelationships among height, weight and chronological, dental and skeletal ages. *Angle Orthod* 1961;31:189-93.
5. Palanisamy V, Rao A, Shenoy R, Baranya SS. Correlation of dental age, skeletal age, and chronological age among children aged 9-14 years: a retrospective study. *J Indian Soc Pedod Prev Dent* 2016;34:310-4.
6. Panchbhai AS. Dental radiographic indicators, a key to age estimation. *Dentomaxillofac Radiol* 2011;40:199-212.
7. Demirjian A, Goldstein H, Tanner JM. A new system of dental age assessment. *Hum Biol* 1973;45:211-27.
8. Bishara SE, Khadivi P, Jakobsen JR. Changes in tooth size-arch length relationships from the deciduous to the permanent dentition: a longitudinal study. *Am J Orthod Dentofacial Orthop* 1995;108:607-13.
9. Bishara SE, Jakobsen JR. Individual variation in tooth-size/ arch-length changes from the primary to permanent dentitions. *World J Orthod* 2006;7:145-53.
10. el-Nofely A, Sadek L, Soliman N. Spacing in the human deciduous dentition in relation to tooth size and dental arch size. *Arch Oral Biol* 1989;34:437-41.
11. Ericson S, Kurol J. Resorption of maxillary lateral incisors caused by ectopic eruption of the canines. A clinical and radiographic analysis of predisposing factors. *Am J Orthod Dentofacial Orthop* 1988;94:503-13.
12. Rozylo-Kalinowska I, Kolasa-Raczka A, Kalinowski P. Dental age in patients with impacted maxillary canines related to the position of the impacted teeth. *Eur J Orthod* 2011;33:492-7.
13. Dalessandri D, Parrini S, Rubiano R, Gallone D, Migliorati M. Impacted and transmigrant mandibular canines incidence, aetiology, and treatment: a systematic review. *Eur J Orthod* 2017;39:161-9.
14. Saka H, Koyama T, Tamatsu Y, Usami A, Ide Y. The morphological studies of root resorption of maxillary primary canines and their relation with the

- position of successive permanent teeth using Micro-CT. *Pediatr Dent J* 2011;21:145-53.
15. Oguchi H. In vitro studies of bone resorption by the root-resorbing tissue from the bovine deciduous tooth. *Bull Tokyo Med Dent Univ* 1975;22:175-83.
  16. Lind V. Short root anomaly. *Scand J Dent Res* 1972;80:85-93.
  17. Kumar CL, Sridhar MS. Estimation of the age of an individual based on times of eruption of permanent teeth. *Forensic Sci Int* 1990;48:1-7.
  18. Andrews AH. Eruption of the maxillary first and second molar teeth in cattle as a method of estimating age. *Br Vet J* 1983;139:355-60.
  19. Brown WAB, Chapman NG. Age assessment of red deer (*Cervus elaphus*): from a scoring scheme based on radiographs of developing permanent molariform teeth. *J Zoology* 1991;225:85-97.
  20. Brown WA, Christofferson PV, Massler M, Weiss MB. Postnatal tooth development in cattle. *Am J Vet Res* 1960;21:7-34.
  21. Boulanger G. La Calcification des premolaires et molaires et ses relations avec l'Age chronologique et squelettique chez les enfants de 6a 11 ans. Inaugural dissertation, University of Zurich, 1958.
  22. Barrow GV, White JR. Developmental changes of the maxillary and mandibular dental arches. *Angle Orthod* 1952;22:41-6.
  23. Nanda RS. Root resorption of deciduous teeth in Indian children. *Arch Oral Biol* 1969;14:1021-30.
  24. Sriram CH, Priya VK, Sivakumar N, Reddy KR, Babu PJ, Reddy P. Occlusion of primary dentition in preschool children of Chennai and Hyderabad: A comparative study. *Contemp Clin Dent* 2012;3:31-7.
  25. Vegesna M, Chandrasekhar R, Chandrappa V. Occlusal characteristics and spacing in primary dentition: a gender comparative cross-sectional study. *Int Sch Res Notices* 2014;2014:512680.
  26. Krishnan V, Davidovitch Z. Chapter 4 gene and tooth movement. In: Krishnan V, Davidovitch Z, eds. *Biological mechanisms of tooth movement*. New Jersey: Wiley-Blackwell; 2009. p. 56-7.
  27. Ericson S, Bjerklind K, Falahat B. Does the canine dental follicle cause resorption of permanent incisor roots? A computed tomographic study of erupting maxillary canines. *Angle Orthod* 2002;72:95-104.
  28. Schindel RH, Sheinis MR. Prediction of maxillary lateral-incisor root resorption using sector analysis of potentially impacted canines. *J Clin Orthod* 2013;47:490-3.
  29. Guarnieri R, Cavallini C, Vernucci R, Vichi M, Leonardi R, Barbato E. Impacted maxillary canines and root resorption of adjacent teeth: a retrospective observational study. *Med Oral Patol Oral Cir Bucal* 2016;21:e743-50.