

Intercondylar fracture of the distal humerus in a 7-year-old child

A case report and a review of the literature

Yuji Tomori, MD*, Yoshihiro Sudo, MD, PhD, Norishige Iizawa, MD, PhD, Mitsuhiro Nanno, MD, PhD, Shinro Takai, MD, PhD

Abstract

Rationale: Intercondylar fracture of the distal humerus is an extremely rare injury in children, especially in those under 8 years of age. To our best knowledge, there have been 55 reported cases of this fracture type in children in the English literature, 12 of which involved children under 8 years of age.

Patient Concerns: We report a case of intercondylar fracture of the distal humerus in a 7-year-old boy fell in a gymnasium, injuring his left elbow.

Interventions: Closed reduction was initially attempted under fluoroscopic guidance, but anatomic reduction could not be achieved because the fragments were extremely unstable and irreducible. Considering the displacement and the failure of closed reduction, ORIF through a posterior approach was performed. Open reduction and double cross-pinning across the medial and lateral condylar fragments were performed through a posterior approach.

Diagnoses: Plain radiographs showed a displaced intercondylar fracture of the distal humerus. Arthrography under general anesthesia showed a severely displaced intra-articular fracture, with rotational displacement of the lateral condyle.

Outcomes: Thirteen months after surgery, there was no functional disturbance or radiographic evidence of avascular necrosis or epiphyseal growth arrest.

Lessons: Open reduction and double cross-pinning through a posterior approach can be a reliable procedure for intercondylar fracture of the distal humerus in children.

Abbreviations: K-wires = Kirschner wires, MRI = magnetic resonance imaging, ORIF = open reduction and internal fixation, ROM = range of motion.

Keywords: child, humerus, intercondylar fracture, intercondylar T fracture, intra-articular elbow fracture

1. Introduction

Intercondylar fracture of the distal humerus is an uncommon injury in children.^[1–15] In 1958, Maylahn and Fahey^[3] reported that among 300 elbow injuries in children, 6 (2%) were intercondylar fracture of the distal humerus. Nonoperative treatment for displaced intercondylar fractures results in complications, including malunion, avascular necrosis, and

epiphyseal growth arrest. Therefore, open reduction and internal fixation (ORIF) is generally recommended for these fractures.^[1]

We report a case of intercondylar fracture of the distal humerus in a 7-year-old boy.

2. Case presentation

A 7-year-old boy fell in a gymnasium, injuring his left elbow. At his initial hospital visit, he complained of pain in the left humerus; the physical exam revealed no neurological findings or impaired blood flow. Plain radiographs showed a displaced intercondylar fracture of the distal humerus (Fig. 1). The patient's family provided informed consent to perform arthrography and surgery. They concurrently approved publication of the findings and clinical results. Arthrography under general anesthesia showed a severely displaced intra-articular fracture, with rotational displacement of the lateral condyle (Fig. 2). Closed reduction was initially attempted under fluoroscopic guidance, but anatomic reduction could not be achieved because the fragments were extremely unstable and irreducible. Considering the displacement and the failure of closed reduction, ORIF through a posterior approach was performed.

We made a straight posterior incision over the elbow to expose the triceps brachii muscle and ulnar nerve. With the ulnar nerve protected, the triceps brachii muscle was elevated. We approached the fracture site through the medial and lateral sides

Editor: Stuart Polisner.

The authors have no funding and conflicts of interest to disclose.

Department of Orthopaedic Surgery, Nippon Medical School Hospital, Tokyo, Japan.

* Correspondence: Yuji Tomori, Department of Orthopedic Surgery, Nippon Medical School 1-1-5 Sendagi, Bunkyo-ku, Tokyo 113-8603, Japan (e-mail: s4064@nms.ac.jp).

Copyright © 2017 the Author(s). Published by Wolters Kluwer Health, Inc. This is an open access article distributed under the terms of the Creative Commons Attribution-Non Commercial License 4.0 (CCBY-NC), where it is permissible to download, share, remix, transform, and build up the work provided it is properly cited. The work cannot be used commercially without permission from the journal.

Medicine (2017) 96:6(e6085)

Received: 9 December 2016 / Received in final form: 16 January 2017 /

Accepted: 16 January 2017

<http://dx.doi.org/10.1097/MD.0000000000006085>

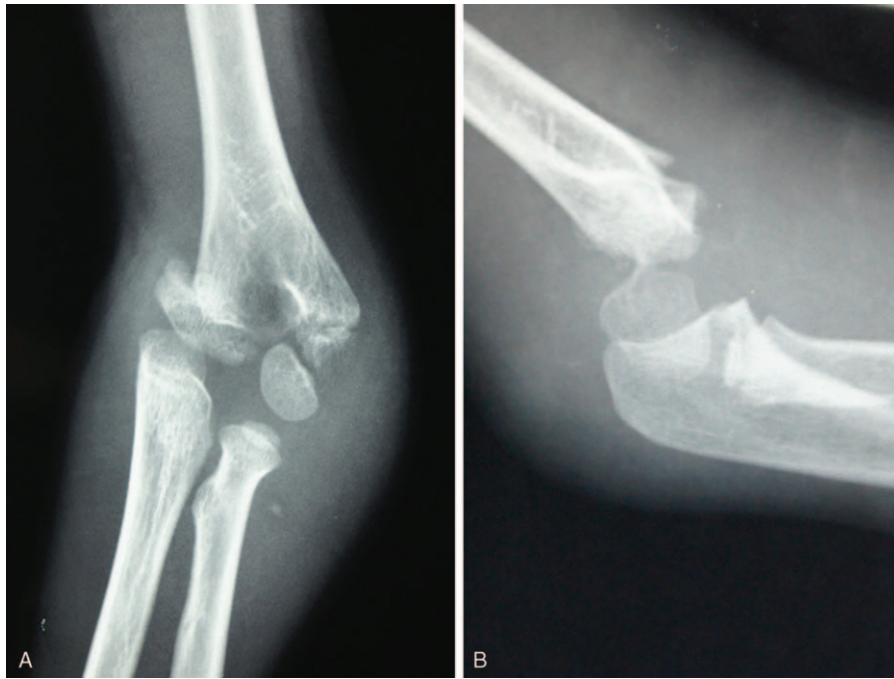


Figure 1. (A, B) Preoperative anteroposterior and lateral radiographs of the left elbow revealing a displaced intercondylar fracture.

of the triceps brachii muscle. We identified the fracture lines, which revealed a type C1.2 intercondylar fracture according to the Association for Osteosynthesis/Association for the Study of Internal Fixation fracture classification. Articular integrity was re-established. Initially, the medial condylar fragment was reduced and fixed to the proximal fragment with 2 Kirschner wires (K-wires). Next the lateral condylar fragment was reduced

to the proximal and medial condylar fragments with 2 K-wires (Fig. 3). Once the distal humeral intercondylar fracture was stabilized with 2 K-wires, the displacement could be reduced and stable fixation was achieved to maintain the alignment of the humerus (Fig. 4).

The elbow was protected in a long arm cast in the mid-prone position for 2 weeks. After 2 weeks, the cast was removed and a

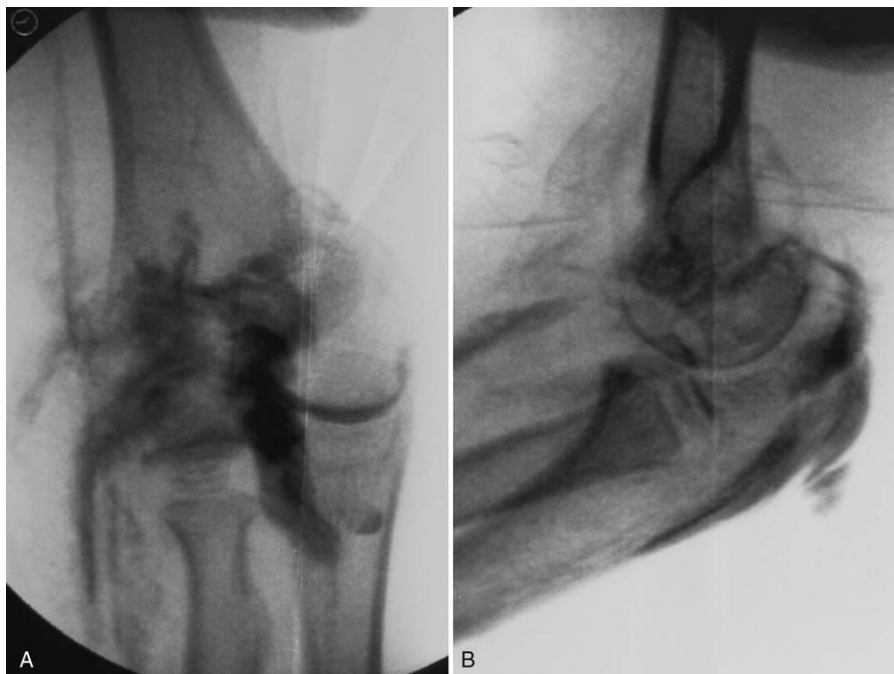

Figure 2. (A, B) Preoperative anteroposterior and lateral arthrograms of the left elbow showing an intra-articular fracture and severely displaced condylar fragments.

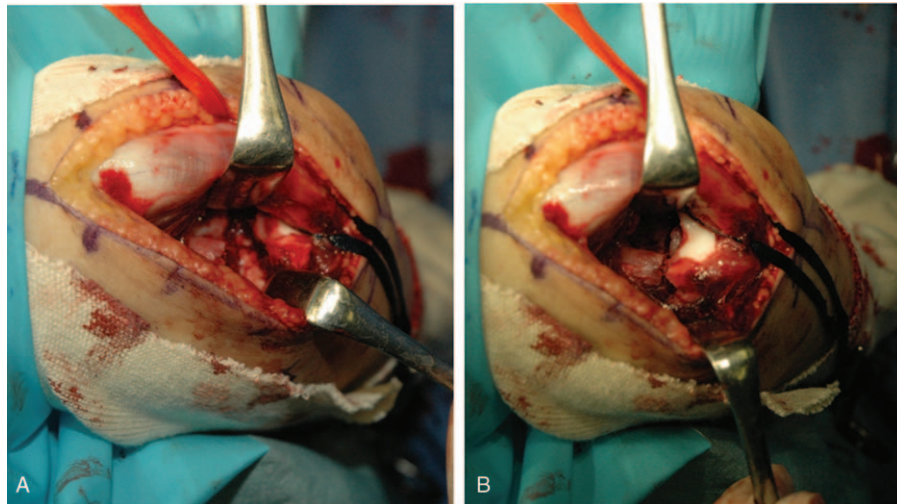


Figure 3. (A, B) Perioperative pictures. With the ulnar nerve protected, the triceps brachii muscle was elevated and the fracture site was approached through the medial and lateral sides of the triceps brachii muscle. We identified the fracture lines, which revealed a type C1.2 intercondylar fracture according to the AO/ASIF fracture classification. Articular integrity was re-established. AO/ASIF=association for osteosynthesis/association for the study of internal fixation.

removal splint was applied for 2 weeks. Simultaneously, range of motion (ROM) exercise was gradually started. The K-wires were removed 6 weeks postoperatively. The fracture showed radiographic healing at 2 months. At the final follow-up, 13 months postoperatively, plain radiographs showed adequate healing without any deformity of the elbow (Fig. 5). Baumann angle,^[16] carrying angle,^[17] and tilting angle were 75°, 2°, and 41°, respectively (the angles on the contralateral side were 71°, 7°, and 45°, respectively). The ROM of the elbow was 5° to 135°, and the

forearm rotation arc was 175°; these values were equal to those of the contralateral side. According to Flynn's criteria,^[18] the ultimate outcome was excellent (Fig. 5).

3. Discussion

Intercondylar fracture of the distal humerus is an uncommon injury in children.^[1-15] To our best knowledge, there have been 55 previously reported cases of this fracture type in children in the

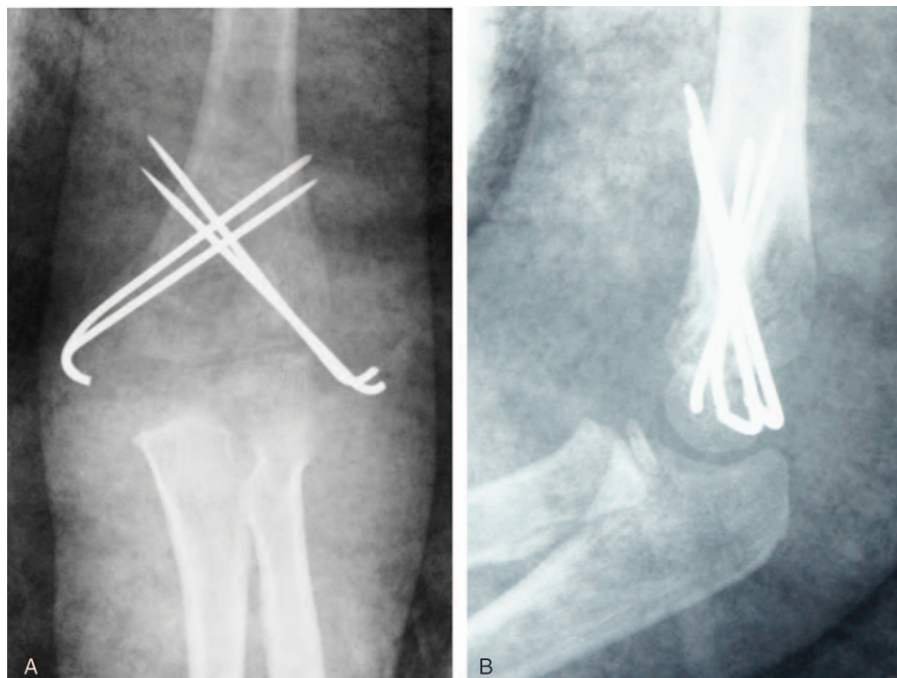


Figure 4. (A, B) Postoperative anteroposterior and lateral radiographs of the left elbow. Double cross-pinning provided stability for the intercondylar fracture of the elbow.

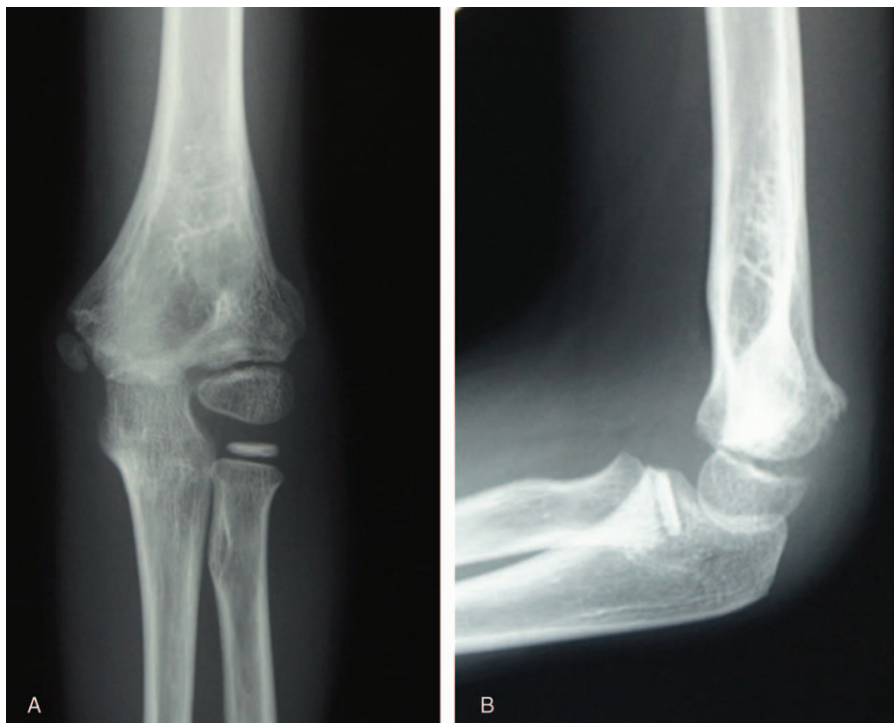


Figure 5. (A, B) Elbow anteroposterior and lateral radiographs taken 13 months postoperatively confirm fracture healing without any elbow deformity.

English literature, 12 of which involved children under 8 years of age (Table 1). Most case reports of this fracture have involved the treatment of children over 8 years of age and adolescents.^[1–15]

To explain the rarity of this kind of fracture, Beghin et al^[6] claim that it may often be overlooked because of the lack of ossification of the distal humerus. According to Ruiz et al,^[10] intercondylar fractures of the distal humerus are usually minimally displaced and are treated conservatively because

younger children have a thick layer of periosteum and greater cartilage component, which are more pliable than bone. Therefore, an articular fracture of the distal humerus may not involve much displacement.

Although diagnosis of this kind of fracture is occasionally difficult because of the skeletal immaturity of the elbow joint in children, the initial patient history can be helpful. Intercondylar fractures are usually caused by heavy impact to the hand or

Table 1

Reported cases of intercondylar fractures of the distal humerus in children (12 patients ≤ 8 years of age).

Author	Year	Total number of cases (patients ≤ 8 y)	Patients treated surgically	CR & pinning cases	ORIF cases	Surgical approach (number of cases)	Fixation method
Evans ^[2]	1953	1 (0)	0/1	0	0	—	Casting
Maylahn and Fahey ^[3]	1958	6 (unknown)	3/6	0	3	Post (3)	Kw, traction, casting
Javis and D'Astous ^[4]	1984	12 (1)	11/12	0	11	Post (11)	screw, plate, Kw
Papavasiliou and Beslikas ^[5]	1986	6 (1)	5/6	0	5	Post (3), Lat (2)	screw, plate, Kw
Beghin et al ^[6]	1986	2 (2)	2/2	0	2	Lat (1), Post (1)	Steinmann pin
Kasser et al ^[7]	1990	5 (0)	5/5	0	5	Post (5)	screw, plate, Kw
Sanders et al ^[8]	1992	1 (0)	1/1	0	1	Post (1)	plate
Re et al ^[9]	1999	10 (0)	8/10	2	6	Post (6)	screw, plate, Kw
Ruiz et al ^[10]	2001	3 (3)	3/3	3	0	—	Kw
Osada et al ^[11]	2004	1 (1)	1/1	0	1	Post (1)	Kw, screw
Kanellopoulos and Yiannakopoulos ^[12]	2004	2 (0)	2/2	2	0	—	Pin, 2.5-mm nail
Abraham et al ^[13]	2005	4 (3)	4/4	3	1	Unknown (1)	Kw, EF
Sharma H. et al ^[14]	2007	1 (0)	1/1	0	1	Med & Lat 1	Kw
Kanharajanna SB et al ^[15]	2013	1 (1)	1/1	0	1	Post 1	Kw

In the English literature: 55 cases of patients ≤ 14 y, 12 of patients ≤ 8 y.

Surgery performed in 47/55 cases (CR & pinning in 10; OR/IF in 37).

OR/IF approach used: Post, 32; Lat, 3; Med&Lat, 1; Unknown, 1).

CR & pinning = closed reduction and percutaneous pinning, EF = external fixation, Kw = Kirschner wire, Lat = lateral approach, Med = medial approach, ORIF = open reduction and internal fixation, Post = posterior approach (triceps split, Bryan–Morrey, olecranon osteotomy, etc.).

elbow.^[1,2] Regarding the mechanism of this fracture, Evans^[2] described the olecranon acting as a wedge between the humeral condyles, prying them apart and displacing them. This mechanism induces characteristic horizontal and vertical fracture lines in the distal humerus, which Maylahn and Fahey^[3] described in 1958; extension of the fracture line into the intercondylar region suggests these fractures. Complementary examinations, such as MRI and arthrography, are sometimes needed if the diagnosis is difficult. In the present case, because the vertical fracture line extended to the apex of the distal humerus and the condylar fragment was markedly displaced, intercondylar fracture of the humerus was obvious on radiographs and arthrographs.

Displaced intercondylar fractures result in complications, including malunion, avascular necrosis, and epiphyseal arrest; therefore, ORIF is generally recommended for these fractures.^[1] In 47 out of 55 reported cases, surgery was performed; 37 of these 47 patients underwent ORIF (Table 1). Although there were differences in the degree of displacement among the cases, open reduction was necessary for displaced intercondylar fractures of the distal humerus to reduce articular displacement.

Regarding the surgical approach for these fractures, the posterior approach was used in 32 out of 37 cases. The advantages of the posterior approach are better visualization of the fracture fragment and the feasibility of adequate ORIF. The disadvantage of this approach is the possibility of causing vascular insufficiency and epiphyseal growth disturbance of the distal humerus. In addition, postoperative elbow joint contracture has been reported in some cases.^[5,12] Papavasiliou and Beslikas^[5] described restricted elbow extension after surgery via a posterior approach. In addition, Gruber and Hudson^[19] reported an association between a posterior approach to the elbow joint and elbow joint contracture after surgery for supracondylar fractures in children.

Yamaguchi et al^[20] reported that the extraosseous blood supply of the lateral structures, including the capitellum and the lateral aspect of the trochlea, depends on the posterior perforating vessels, which are frequently dissected with a posterior approach. Therefore, the posterior approach might result in vascular insufficiency of the distal humerus and subsequent postoperative complications, such as aseptic necrosis and growth disorder of the humerus when ORIF is performed for articular fractures.

Almost all reported cases of intercondylar fractures of the distal humerus had good surgical outcomes after ORIF via a posterior approach.^[4-9,11,15] However, Papavasiliou and Beslikas^[5] reported 1 case of suspected aseptic necrosis of the trochlea of the humerus. In that case, the patient achieved near complete recovery with no functional disturbance or radiographic evidence of avascular necrosis or epiphyseal growth arrest at 13 months after surgery. However, the long-term follow-up is needed to evaluate clinical outcomes after a posterior approach.

4. Conclusion

Intercondylar fracture of the distal humerus is a very uncommon injury in children. ORIF should be the treatment of choice for these fractures to prevent postoperative complications. ORIF through a posterior approach can be the first choice for

intercondylar fracture of the distal humerus, and double cross-pinning can provide reliable fixation. However, long-term follow-up is needed to evaluate the clinical outcomes after ORIF via a posterior approach for intercondylar fracture of the distal humerus.

Acknowledgment

The authors would like to express our gratitude to all of the staff at Nippon Medical School Hospital.

References

- Beatty JH, Kasser JR. The elbow. Beatty JH, Kasser JR. Physeal fractures, apophyseal injuries of the distal humerus, avascular necrosis of the trochlea, and T-condylar fractures. *Rockwood & Wilkins' Fractures in Children* Lippincott Williams & Wilkins, Philadelphia:2001;pp.623-703.
- Evans EM. Supracondylar-Y fractures of the humerus. *J Bone Joint Surg Br* 1953;35:381-5.
- Maylahn DJ, Fahey JJ. Fractures of the elbow in children. *JAMA* 1958;166:220-8.
- Javis JG, D'Astous JL. The pediatric T-supracondylar fracture. *J Pediatr Orthop* 1984;4:697-9.
- Papavasiliou VA, Beslikas TA. T-condylar fractures of the distal humeral condyles during childhood: an analysis of six cases. *J Pediatr Orthop* 1986;6:302-5.
- Beghin JL, Buchholz RW, Wenger DR. Intercondylar fractures of the humerus in young children. *J Bone Joint Surg Am* 1982;64:1083-6.
- Kasser JR, Richards K, Millis M. The triceps-dividing approach to open reduction of complex distal humeral fractures in adolescents. *J Pediatr Orthop* 1990;10:93-6.
- Sanders RA, Raney EM, Pipkin S. Operative treatment of bicondylar intraarticular fractures of the distal humerus. *Orthop* 1992;15:159-63.
- Re PR, Waters PM, Hresko T. T-condylar fractures of the distal humerus in children and adolescents. *J Pediatr Orthop* 1999;19:313-8.
- Ruiz AL, Kealey WDC, Cowie HG. Percutaneous pin fixation of intercondylar fractures in young children. *J Pediatr Orthop* 2001;10:211-3.
- Osada D, Tamai K, Saotome K. T-condylar fracture of the distal humerus in a three-year-old child. *Hand Surg* 2005;10:125-9.
- Kanellopoulos AD, Yiannakopoulos CK. Closed reduction and percutaneous stabilization of pediatric T-condylar fractures of the humerus. *J Pediatr Orthop* 2004;24:13-6.
- Abraham E, Gordon A, Abdul-Hadi O. Management of supracondylar fractures of humerus with condylar involvement in children. *J Pediatr Orthop* 2005;25:709-16.
- Sharma H, Wilson N. T-condylar distal humeral fracture associated with irreducible anterior radial head dislocation in an 11-year-old child. A case report. *J Trauma* 2007;63:202-4.
- Kantharajanna SB, Goni V, Sudesh P, et al. T-condylar fracture delayed for 10 days in a 5-year-old boy: a case report and review of the literature. *Chin J Traumatol* 2013;16:58-60.
- Baumann E. Beiträge zur Kenntnis der Frakturen am Ellbogengelenk. Unter besonderer Berücksichtigung der Spätfolgen. I. Allgemeines und Fraktura supra condylica. *Bruns Beitr Klin Chir* 1929;146:1-50. [German].
- Keats TE, Teeslink R, Diamond AE. Normal axial relationship of the major joints. *Radiology* 1966;87:904-7.
- Flynn JC, Richards JF Jr. Blind pinning of displaced supracondylar fractures of the humerus. Sixteen years' experience with long term follow up. *J Bone Joint Surg Am* 1974;56:263-72.
- Gruber MA, Hudson OC. Supracondylar fracture of the humerus in children. End-result study of open reduction. *J Bone Joint Surg Am* 1964;46:1245-52.
- Yamaguchi K, Sweet FA, Bindra R, et al. The extraosseous and intraosseous arterial anatomy of the adult elbow. *J Bone Joint Surg Am* 1997;79:1653-62.