

Received: 2019.08.03  
Accepted: 2019.09.30  
Published: 2019.10.13

## Protective Effect of Alprostadil on Acute Pancreatitis in Rats via Inhibiting Janus Kinase 2 (JAK2)/STAT3 Signal Transduction Pathway

Authors' Contribution:  
Study Design A  
Data Collection B  
Statistical Analysis C  
Data Interpretation D  
Manuscript Preparation E  
Literature Search F  
Funds Collection G

AEG 1 **Shuke Fei**  
C 2 **Wei Li**  
BD 1 **Lei Xiang**  
F 1 **Xuwen Xie**  
A 3 **Liang Zhang**

1 Department of Hepatobiliary and Pancreatic Surgery, The Second Affiliated Hospital of University of South China, Hengyang, Hunan, P.R. China  
2 Department of Breast and Thyroid Surgery, The Second Affiliated Hospital of University of South China, Hengyang, Hunan, P.R. China  
3 Department of Rheumatism Immunology, Zhuzhou Central Hospital, Zhuzhou, Hunan, P.R. China

**Corresponding Author:** Liang Zhang, e-mail: 1474891359@qq.com

**Source of support:** This work was supported by a grant from Hunan Education Department Project (16B232)

**Background:** Alprostadil can inhibit inflammation and reduce inflammation-related injury in many inflammatory diseases. However, the anti-inflammatory effect of alprostadil in decreasing acute pancreatitis (AP) injury remains unknown. This study aimed to investigate the possible protective effects and mechanism of alprostadil against AP in rats.

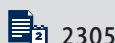**Material/Methods:** Forty healthy Sprague-Dawley rats were randomly divided into a control group, an AP group, an AP-alprostadil group, an AP-AG490 group, and an AP-(alprostadil+AG490) group. An animal model of acute pancreatitis was established. The pathological changes of the pancreases in each group were observed. We assessed levels of malondialdehyde (MDA), superoxide dismutase (SOD), and myeloperoxidase (MPO), as well as serum IL-1 $\beta$ , IL-6, IL-10, and TNF- $\alpha$ . TUNEL assay was used to detect apoptosis of pancreatic cells. The proteins p-Jak2 and p-Stat3 were investigated by Western blot.

**Results:** Compared with the control group, pancreatic pathological score, pancreatic apoptosis, MDA, MPO, serum IL-1 $\beta$ , IL-6, and TNF- $\alpha$  levels were significantly higher in the AP group, and SOD levels were significantly decreased. Compared with the AP group, after treatment with alprostadil, AG490, and alprostadil+AG490, respectively, the pancreatic pathological score, apoptosis, MDA, MPO, serum IL-1 $\beta$ , IL-6, and TNF- $\alpha$  were significantly decreased in AP rats, while SOD levels were significantly increased. The protein levels of p-JAK2 and p-STAT3 were significantly upregulated in the AP group compared with the control group, and the protein levels of p-JAK2 and p-STAT3 after treatment with alprostadil, AG490, and alprostadil+AG490 were significantly decreased, and the effect of alprostadil+AG490 was the strongest.

**Conclusions:** Alprostadil can reduce pancreatic tissue damage, delay pancreatic cell apoptosis, and reduce inflammation and anti-oxidative stress by inhibiting the JAK2/STAT3 signal pathway, thus protecting the pancreas.

**MeSH Keywords:** Alprostadil • Janus Kinase 2 • Pancreatitis • Signal Transduction • STAT3 Transcription Factor

**Full-text PDF:** <https://www.medscimonit.com/abstract/index/idArt/919148>



2305



1



5



23



## Background

Acute pancreatitis (AP) is an inflammatory disease caused by the digestive action of the pancreatic digestive enzyme on the pancreas itself and its surrounding organs. It is an abdominal emergency characterized by interstitial edema, vacuolization, and substantial necrosis, with multiple inflammatory cell infiltrations [1–4]. Although the precise mechanisms by which diverse etiological factors induce an attack remain unclear, once the disease process is initiated, patients have poor survival, despite major progress in AP treatment in recent years.

As a kind of prostaglandin, alprostadil is widely used to treat urinary system diseases. In recent years, it has been applied in cardio-cerebral vascular disease [5,6], peripheral vasculitis [7], and fundus lesions [8]. In these diseases, alprostadil mainly expands blood vessels by affecting the release of NO [9]. Recent studies have found that alprostadil combined with somatostatin can prevent acute liver injury after partial hepatectomy in rats by inhibiting inflammatory response, apoptosis, and endoplasmic reticulum stress [10]. Zhang et al. showed alprostadil can alleviate the inflammatory response and myocardial ischemia/reperfusion injury [11].

The clinical use of alprostadil can reduce the release of inflammatory factors in acute lung injury [12], and alprostadil can inhibit inflammation and leukocyte-related activities in inflammation to reduce inflammation-related effects through inhibiting the JAK2/STAT3 signaling pathway [13]. Previous studies have demonstrated that activation of JAK2 can cause STAT3 phosphorylation, ultimately leading to the massive expression of related inflammatory genes, and causes apoptosis and necrosis of pancreatic cells [4]. However, the anti-inflammatory effect of alprostadil in decreasing acute pancreatitis (AP) injury remains unknown. In addition, the precise mechanisms by which alprostadil participates in acute pancreatitis through the JAK2/STAT3 signal transduction pathway remain largely unknown. In this study, we established an AP rat model to investigate the possible protective effects of alprostadil against AP in rats. The potential mechanisms underlying the alprostadil anti-inflammatory effect via the JAK2/STAT3 signal pathway were also investigated.

## Material and Methods

### Animals and treatment

We used 40 male Sprague-Dawley rats weighing 200–300 g. The animals were purchased from Changsha Tianqin Biotechnology (Hunan, China). All operations were performed according to international guidelines concerning the care and treatment of experimental animals. Ethical approval for this study was

obtained from the Ethics Committee for Animal Research at the Second Affiliated Hospital of University of South China.

After acclimatization to a 12-h light/12-h dark cycle and after adaptive feeding at  $23\pm 3^{\circ}\text{C}$  for 1 week, 40 male rats were randomly divided into 5 equal groups: the Control group, the AP group, the AP-alprostadil group, the AP-AG490 group, and the AP-(alprostadil+AG490) group, with 8 rats in each group. The control group was intraperitoneally injected with the corresponding physiological saline, and the other groups of rats were prepared by the AP model by intraperitoneal injection of 20% L-arginine (sigma, USA) twice at a dose of 2.5 g/kg, at intervals of 1 h. The alprostadil group was intraperitoneally injected with alprostadil (Apexbio, USA) 5  $\mu\text{g}/\text{kg}$  30 min before AP modeling. To inhibit the JAK/STAT pathway inhibitor, we selected AG490, a specific inhibitor of Jak2, as a positive control. The AG490 group was intraperitoneally injected with AG490 (Apexbio, USA) 8 mg/kg 30 min before modeling. The alprostadil+AG490 group was given intraperitoneal injection of alprostadil 5  $\mu\text{g}/\text{kg}$  and AG490 8 mg/kg 30 min before AP modeling. Rats were sacrificed after 48 h in each group (pre-experimentally confirmed that pancreatic pancreatitis was highest at 48 h after administration of 20% L-arginine), SD rats were dissected, and pancreatic tissue was observed for general changes. Using 4% paraformaldehyde-fixed paraffin sections stained with hematoxylin-eosin (H&E), observed under a light microscope, a portion of fresh pancreatic tissue was stored at  $-20^{\circ}\text{C}$ . Blood was taken from the inferior vena cava, left to stand for 30 min, centrifuged at 4000 g for 10 min at  $4^{\circ}\text{C}$ , and the supernatant was taken for the 2 parts; one part was tested for lipase and amylase, and the other for ELISA.

### Histopathological analysis

The pancreatic tissues were stained with hematoxylin-eosin (H&E) by 2 trained pathologists. The morphologic evaluation of the tissues was performed by optical microscopy. The histological assessments of tissues were analyzed for AP severity based on edema, inflammation, hemorrhage, and necrosis. The pathological scores of pancreas grading were assigned as described by Schmidt et al. [14].

### Determination of serum amylase and lipase

All blood samples were collected from the inferior vena cava of each animal. The serum amylase and lipase levels were determined by an automatic analyzer in the lab of the second affiliated Hospital of University of South China.

### Enzyme linked immunosorbent assay (ELISA)

The serum levels of pro-inflammatory factors IL-1 $\beta$ , IL-6, and TNF- $\alpha$  were detected by ELISA. All samples were assessed in

duplicate according to the manufacturer's protocols. The absorbance was read at 450 nm. All ELISA kits were purchased from Wuhan Huamei Bioengineering Co.

### Measurement of MDA, MPO, and SOD levels

Rat serum was collected and measured for MDA, MPO, and SOD by spectrophotometry using commercial diagnostic kits according to the manufacturer's instructions. MDA, MPO, and SOD kits were purchased from Wuhan Huamei Bioengineering Co.

### TUNEL assay for apoptosis of pancreatic cells

Apoptosis was detected by terminal deoxynucleotidyl transferase-mediated dUTP nick-end labeling (TUNEL) assay using the In-Situ Cell Death Detection Kit (#BA2520, Nanjing, China). In the apoptotic index (AI) calculation method, 4 high-power fields were imaged, and the number of apoptotic cells in 250 acinar cells was calculated in each field of view, with  $AI = (\text{total number of apoptotic cells} / 1000) \times 100\%$ .

### Western blot

Tissues were homogenized in lysis buffer, and the total proteins were extracted by centrifugation. The protein concentration was determined using the BCA Protein Quantitation Kit (Thermo, USA). After boiling, tissue lysates were separated by SDS-polyacrylamide gel electrophoresis (PAGE) and transferred to polyvinylidene difluoride (PVDF) membranes (Bio-Rad). Membranes were blocked by 5% non-fat skim milk in TBS-T, and then incubated in primary antibody followed by incubation with secondary antibody diluted in 5% non-fat skim milk-TBS-T, with primary antibody, rabbit anti-rat p-JAK2 (1: 500) (#17670-1-AP, Chicago, USA), p-STAT3 monoclonal antibody (1: 1000) (#10253-2-AP, Chicago, USA), and rabbit anti-rat  $\beta$ -actin antibody (1: 5000) (#60008-1-Ig, Chicago, USA). HRP-labeled secondary antibody was purchased from Santa Cruz Biotechnology.

### Statistical analysis

The data were analyzed by SAS (version 6.12) statistical software package. All experiments were repeated 3 times or more to enhance the experimental repeatability. Data are expressed as  $\text{means} \pm \text{SD}$ . Differences between groups were compared using one-way analysis of variance (ANOVA) and followed by Bonferroni's multiple comparison test.  $P < 0.05$  was considered statistically significant.

## Results

### Alprostadil ameliorates L-arginine-induced pancreatic damages in Rats

As shown in Figure 1A, obvious interstitial edema, inflammatory cells infiltration, vascular congestion, local hemorrhage, and diffuse tissue necrosis were observed in the AP group. There were also differing degrees of damage in the AP-alprostadil group and AP-AG490 group, but damage was less severe than in the AP group. Furthermore, these pathological changes were largely alleviated in the AP-(alprostadil+AG490) group. No significant histopathologic changes were observed in the control groups (vehicle treatment). No statistically significant was observed between the AP-(alprostadil+AG490) group and the control groups. The histopathologic scores agreed with the above results (Figure 1B), suggesting that both alprostadil and AG490 can ameliorate L-arginine-induced pancreatic damage, and alprostadil can further enhance the inhibitory effect of AG490 on acute pancreatitis in rat.

### Serum levels of AMY and LPS in each group

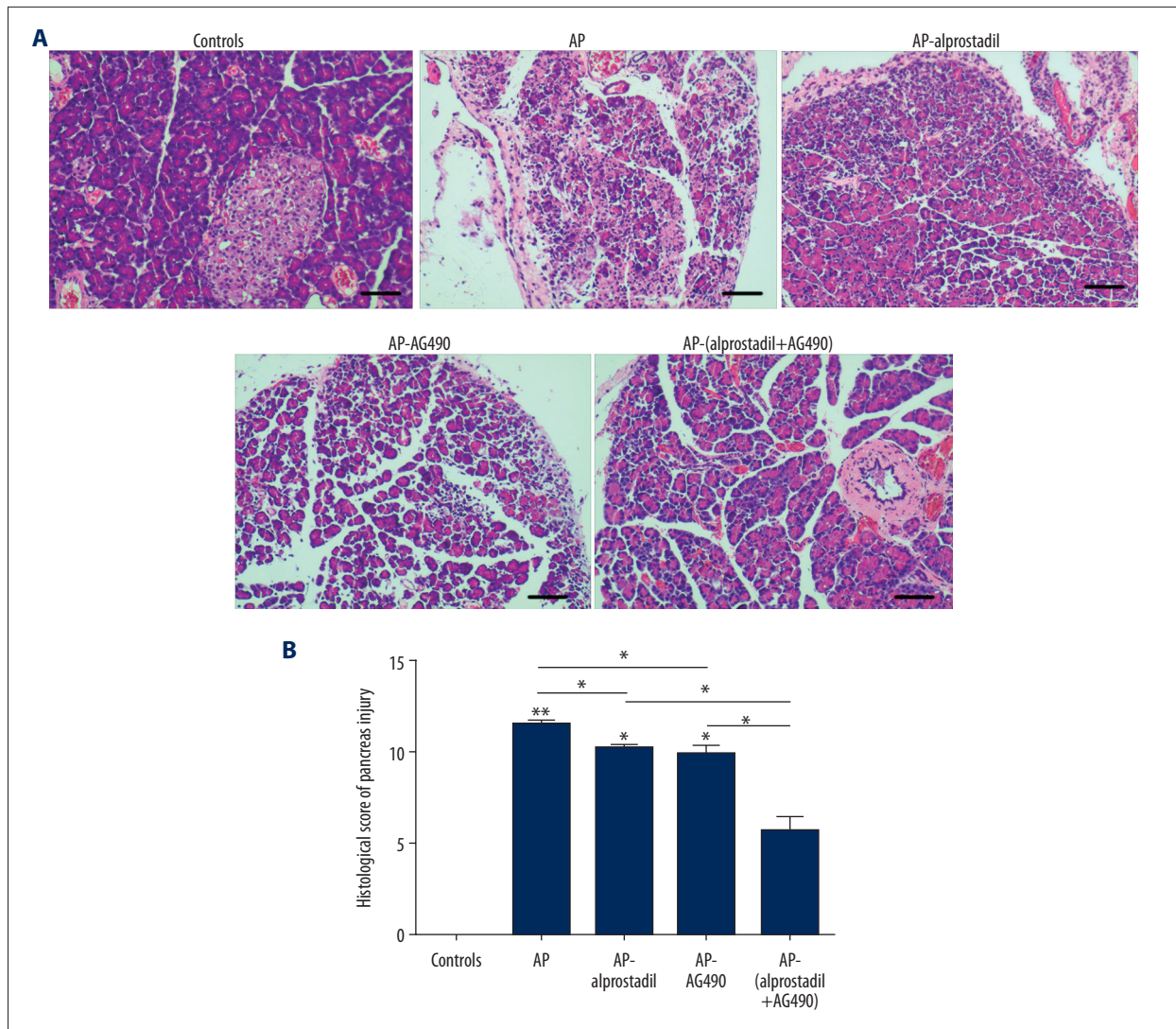
The activity levels of AMY and LPS in the AP groups were significantly higher compared with the AP-alprostadil group and AP-AG490 group ( $P < 0.05$ ). However, the AMY and LPS levels in the AP-(alprostadil+AG490) group were significantly lower than in the AP-alprostadil group and AP-AG490 group ( $P < 0.05$ ), and the AMY and LPS levels in the AP-(alprostadil+AG490) group were significantly higher than in the control groups (Table 1).

### Alprostadil could reduce oxidative stress and inhibits pro-inflammatory cytokine release

To understand whether alprostadil could reduce oxidative stress, the levels of MDA, SOD, and MPO in serum were detected. Compared with the control group, the levels of MPO, SOD, and MDA were significantly altered because of acute pancreatitis in rats. Alprostadil treatment could alleviate these changes and reduce oxidative stress (Figure 2A–2C). Serum IL-1 $\beta$ , IL-6, and TNF- $\alpha$  in the control group were not significantly changed. However, serum IL-1 $\beta$ , IL-6, and TNF- $\alpha$  levels were significantly elevated in the AP group, and alprostadil treatment significantly reduced serum IL-6, IL-1 $\beta$ , and TNF- $\alpha$  levels in the AP-alprostadil group and the AP-(alprostadil+AG490) group (Figure 3A–3C).

### Effects of alprostadil on apoptosis of pancreatic acinar cells induced by L-arginine in AP rats

Apoptosis of pancreatic acinar cells is also one of the typical features of AP. TUNEL assay was used to detect apoptosis of pancreatic acinar cells.



**Figure 1.** Histopathological changes in the pancreas of rats from control group, AP group, AP-alprostadil group, AP-AG490 group, and AP-(alprostadil+AG490) group (magnification, 100×). **(A)** Representative H&E staining images of pancreas tissues from each group of rats. **(B)** Histological score of pancreas injury. \*\*  $P < 0.01$ , and \*  $P < 0.05$ .

**Table 1.** Serum levels of AMY and LPS in the different groups (U/ml, n=8, x±s).

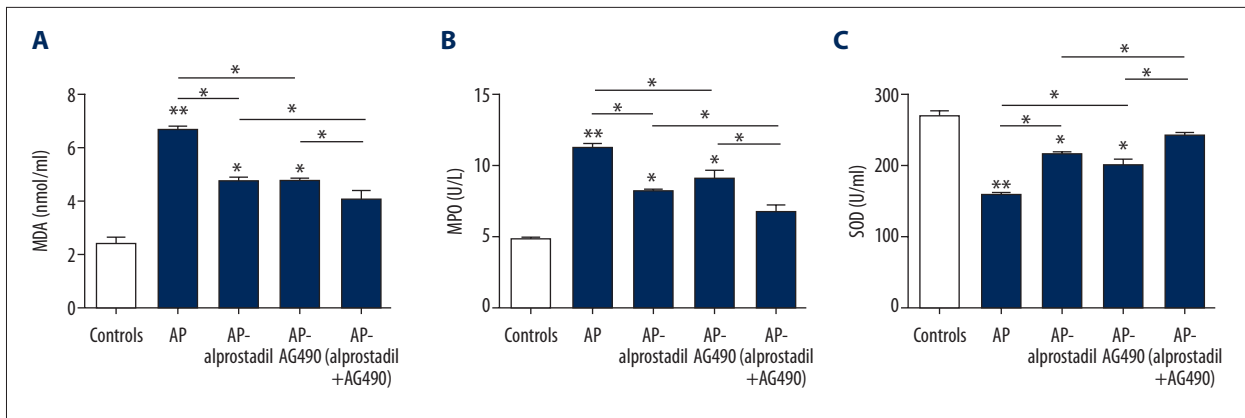
Group	AMY	LPS
Control	890.21±13.03	6.19±0.34
AP	4125.12±45.87*	109.21±10.04*
AP-alprostadil	2850.36±43.88**	69.93±7.43**
AP-AG490	2718.34±32.20*	51.03±5.19*
AP-(alprostadil+AG490)	1709.11±21.03*	21.12±1.19*

AMY – amylase; LPS – lipase; AP – acute pancreatitis;  
\*  $P < 0.05$  vs. control groups; \*\*  $P < 0.05$  for AP-(alprostadil+AG490)  
vs. AP-alprostadil or AP-AG490.

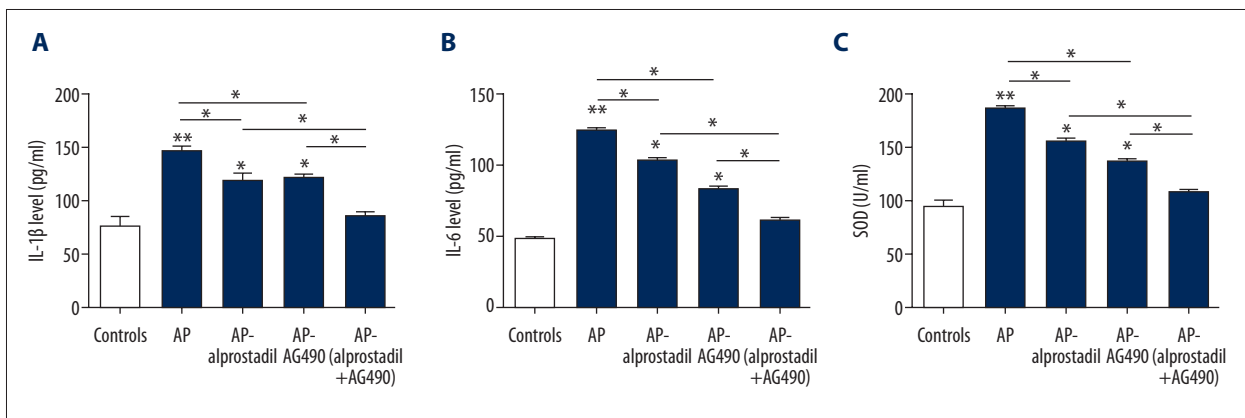
Compared with the control group, the apoptosis of pancreatic acinar cells in the AP group was significantly increased ( $P < 0.01$ ). Alprostadil treatment significantly decreased apoptosis of pancreatic acinar cells in the AP-alprostadil group and the AP-(alprostadil+AG490) group ( $P < 0.05$ ) (Figure 4).

#### Effect of alprostadil on JAK2/STAT3 signaling pathway

Moreover, to confirm the effect of alprostadil on the JAK2/STAT3 signaling pathway, we investigated the levels of proteins such as p-JAK2 and p-STAT3 by Western blot. As shown in Figure 5, the expressions of p-JAK2 and p-STAT3 protein levels in the AP groups increased significantly compared with the AP-alprostadil group and AP-AG490 group ( $P < 0.05$ ). Furthermore, the expressions levels of p-STAT3 and p-JAK2 in



**Figure 2.** Alprostadil reduced oxidative stress and inhibited pro-inflammatory cytokine release. (A) Levels of MDA in serum of the control group, AP group, AP-alprostadil group, AP-AG490 group, and AP-(alprostadil+AG490) group. (B) The levels of MPO in serum of each group. (C) The levels of SOD in serum of each group. \*\*P<0.01, and \*P<0.05.



**Figure 3.** Expressions of IL-1β, IL-6, and TNF-α in serum were detected by ELISA from each group of rats. (A) IL-1β; (B) IL-6; (C) TNF-α. \*\*P<0.01, and \*P<0.05.

the AP-(alprostadil+AG490) group were significantly lower than in the AP-alprostadil group and AP-AG490 group (P<0.05). No statistically significant difference was observed in the expressions of p-JAK2 and p-STAT3 protein levels between the AP-(alprostadil+AG490) group and the control groups.

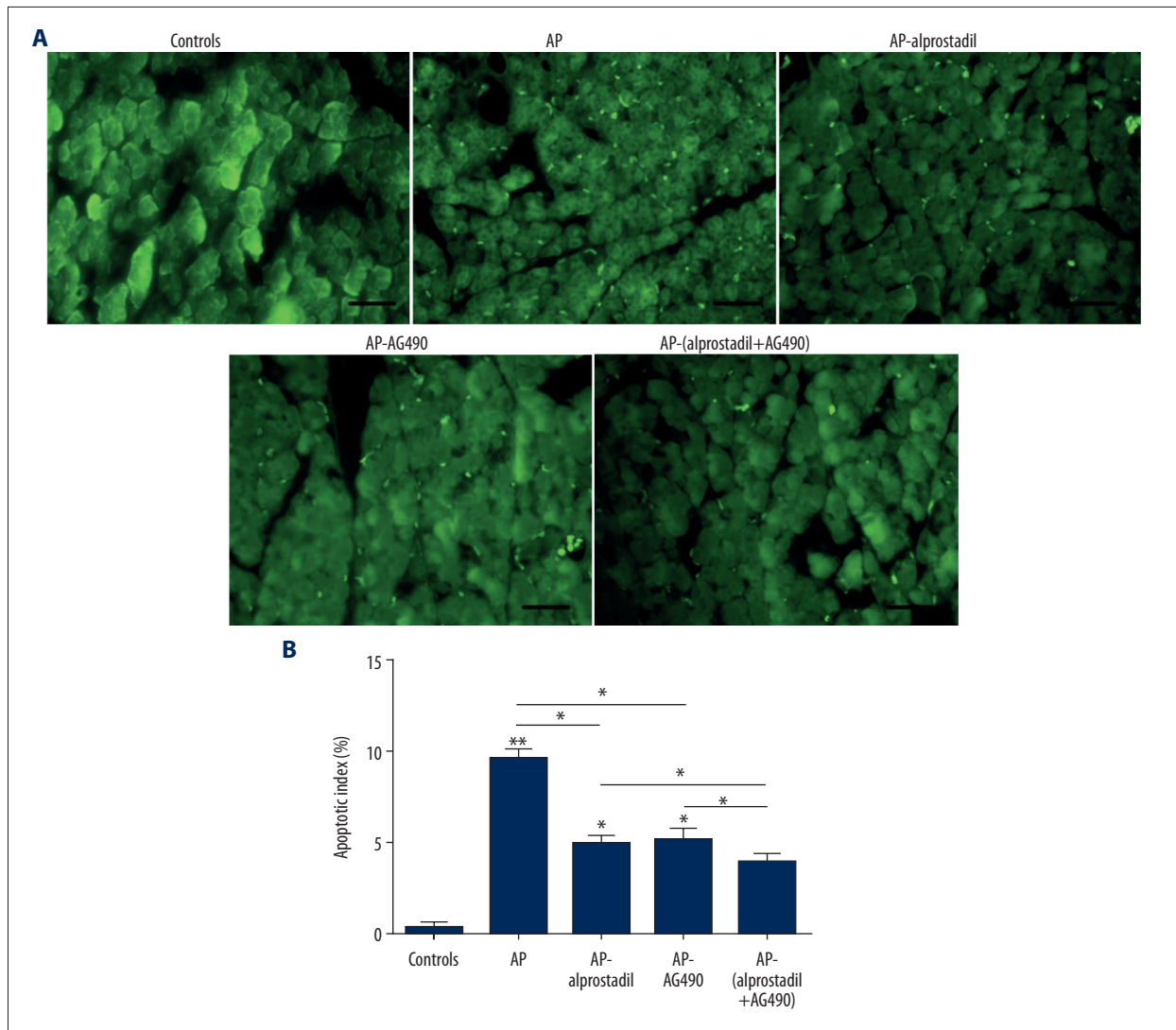
## Discussion

AP is a common surgical disease with high morbidity and mortality. The pathogenesis of AP is closely related to pancreatic enzyme self-digestion, inflammatory mediator cascade amplification, and leukocyte overactivation, oxidative stress, and calcium overload. Oxidative stress and cytokines play an important role. Therefore, controlling inflammatory response and oxidative stress as soon as possible is of great significance for the treatment of AP.

Alprostadil is an exogenous prostaglandin E (PGE1), a typical vasodilator with high activity. Alprostadil has been used

clinically in treatment of AP. It appears that its main role is to improve microcirculatory disorders in pancreatic tissue, and to significantly inhibit pancreatic secretion induced by endogenous and exogenous stimuli, thereby reducing AP [15]. In the present study, compared with control group, obvious interstitial edema, inflammatory cells infiltration, vascular congestion, local hemorrhage, and diffuse tissue necrosis were observed in the AP group, and the activity levels of AMY and LPS in the AP groups were increased significantly, indicating successful modeling. Furthermore, it was found that alprostadil treatment significantly reduced pancreatic pathological damage, as well as serum AMY and LPS levels, indicating that alprostadil can reduce pancreatic tissue damage and that it has a significant protective effect on AP in rats.

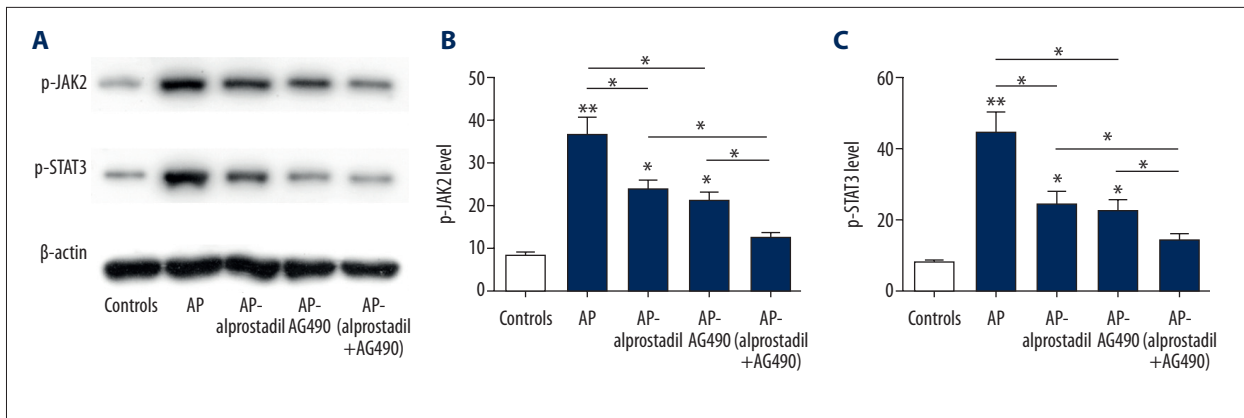
Oxidative stress is considered to be an important regulator in the pathogenesis of AP. MPO is a peroxidase produced by neutrophils, which is used as a biomarker to study the infiltration of neutrophils in AP, which can reflect the severity of inflammation [16]. MDA is a product of oxygen free radicals acting



**Figure 4.** Effects of alprostadil on apoptosis of pancreatic acinar cells induced by L-arginine in AP rats. **(A)** Detection of apoptosis in control group, AP group, AP-alprostadil group, AP-AG490 group, and AP-(alprostadil+AG490) group through TUNEL staining. Representative images of apoptosis by microscopy (400×) are shown. **(B)** The apoptosis index of pancreas tissues in each group. \*\* P<0.01, and \* P<0.05.

on the body's lipid peroxidation. The content of MDA can indirectly reflect the content of oxygen free radicals in the body and the degree of damage to the body [17]. SOD is a kind of metalloenzyme widely distributed in living organisms. It can catalyze superoxide anion to hydrogen peroxide and oxygen, remove oxidative free radicals in the body, maintain the dynamic balance of free radical generation and elimination in the body, and play an important role in antioxidant activity [18]. The increase of MPO and MDA activity and the down-regulated SOD level in AP group indicates that the infiltration of neutrophils in pancreatic tissue and the damage of pancreatic tissue gradually worsen due to decreased antioxidant enzyme system activity. However, alprostadil treatment could alleviate these changes and decrease oxidative stress.

IL-1 $\beta$ , IL-6, and TNF- $\alpha$  are the most typical indicators of inflammatory stress diseases, and they mainly participate in the regulation and amplification of AP-induced inflammatory response [19]. Related experimental studies have shown that blocking the pro-inflammatory cytokine cascade after the onset of pancreatitis leads to a significant reduction in the severity of AP [20–22]. IL-1 $\beta$ , TNF- $\alpha$ , and IL-6 have been shown to promote inflammation and acinar necrosis in different acute pancreatitis models. In the present study, serum IL-1 $\beta$ , IL-6, and TNF- $\alpha$  levels were significantly elevated in AP rats, while IL-6, TNF- $\alpha$ , and IL-1 $\beta$  levels were significantly reduced via alprostadil treatment. Therefore, our results showed that the release of pro-inflammatory factors was significantly decreased via alprostadil treatment in AP rats.



**Figure 5.** Effect of alprostadil on Jak2/Stat3 signaling pathway. (A) Western blot analysis was utilized to detect the level of p-JAK2 and p-STAT3 from control group, AP group, AP-alprostadil group, AP-AG490 group, and AP-(alprostadil+AG490) group. (B) The quantification of p-JAK2 was statistically analyzed. (C) The quantification of p-Stat3 was statistically analyzed. \*\*  $P < 0.01$ , and \*  $P < 0.05$ .

Studies have confirmed that when acute pancreatitis occurs, the mechanism of apoptosis of pancreatic cells participates in its pathophysiological changes and plays an important role [23]. However, it is unfortunate that the drug recommendation for delaying apoptosis of pancreatic cells has not been clearly defined. Therefore, the TUNEL method was used to detect the apoptosis of pancreatic cells in our study. Our results showed the apoptosis of pancreatic acinar cells in the AP group was significantly increased, and alprostadil treatment could significantly decrease apoptosis of pancreatic acinar cells in AP modeling.

Recent studies have shown that alprostadil may inhibit JAK2/STAT3, the major inflammatory transduction pathway [13], but whether alprostadil inhibits the systemic inflammatory response of AP through the JAK2/STAT3 signal transduction pathway remains unclear. AG490 is a specific inhibitor of JAK2. We found that the expressions of p-STAT3 and p-JAK2 protein levels in AP groups were significantly increased

compared with the AP-alprostadil group and AP-AG490 group. Furthermore, the expression levels of p-STAT3 and p-JAK2 in the AP-(alprostadil+AG490) group were significantly lower than in the AP-alprostadil group and AP-AG490 group, which suggests that alprostadil inhibits the JAK2/STAT3 signaling pathway and is similar to AG490 suppression of the JAK2/STAT3 signaling pathway.

## Conclusions

In summary, alprostadil reduces pancreatic damage and pancreatic cell apoptosis, and has significant anti-inflammatory and anti-oxidative stress effects, which may be associated with inhibition of the JAK2/STAT3 signaling pathway.

## Conflict of interest

None.

## References:

- Yang CJ, Chen J, Phillips AR et al: Predictors of severe and critical acute pancreatitis: a systematic review. *Dig Liver Dis*, 2014; 46: 446–51
- Banks PA, Bollen TL, Dervenis C et al: Acute Pancreatitis Classification Working Group (2013) Classification of acute pancreatitis – 2012: Revision of the Atlanta classification and definitions by international consensus. *Gut*, 2013; 62: 102–11
- Chen J, Cai QP, Shen PJ et al: Netrin-1 protects against L-Arginine-induced acute pancreatitis in mice. *PLoS One*, 2012; 7: e46201
- Marina Lesina, Sonja Maria Wörmann. Interleukin-6 in inflammatory and malignant diseases of the pancreas. *Seminars in Immunology*, 2014;26: 80–87.
- Jingxiang W, Jingli N: [Effect of alprostadil on cardiac function and ischemic symptoms in patients with acute myocardial infarction.] *Shandong Medicine*, 2015; 55(41): 49–50 [in Chinese]
- Dai W, Kong Y: [Effect of alprostadil combined with butyl phenyl peptide on serum inflammatory factors and coagulation function in patients with ischemic stroke.] *Journal of Hainan Medical College*, 2016; 22(12): 1276–78+1282 [in Chinese]
- Cacione DG, Baptista-Silva JC, Macedo CR: Pharmacological treatment for Buerger's disease. *Cochrane Database Syst Rev*, 2016; 2: CD011033
- Asahi MG, Chou C, Gallemore RP: Acute macular edema following intracorporeal prostaglandin injection for erectile dysfunction. *Int Med Case Rep J*, 2015; 8: 141–44
- Fang W, Li H: The effect of alprostadil on isolated vascular endothelium and its mechanism. *Chinese Journal of Hospital Pharmacy*, 2010; (30): 573–76
- Changjun J, Chaoliu D, Xianmin B et al: Co-administration of prostaglandin E1 with somatostatin attenuates acute liver damage after massive hepatectomy in rats via inhibition of inflammatory responses, apoptosis and endoplasmic reticulum stress. *Int J Mol Med*, 2013; 30: 416–22

11. Zhang L, Zhang Y, Yu X et al: Alprostadil attenuates myocardial ischemia/reperfusion injury by promoting antioxidant activity and eNOS activation in rats. *Acta Cir Bras*, 2018; 33(12): 1067–77
12. Zhang L: [Clinical study of alprostadil in the treatment of patients with ventilator-associated lung injury.] *Pharmaceutical and Clinical Research*, 2015; 23(2): 185–86 [in Chinese]
13. de Freitas Soares BL, Lopes de Freitas MA, Frasson de Souza Montero E et al: Alprostadil attenuates inflammatory aspects and leucocytes adhesion on renal ischemia and reperfusion injury in rats. *Acta Cir Bras*, 2014; (29): 55–60
14. Mandavilli U, Knoefel WT, Warshaw AL: A better model of acute pancreatitis for evaluating therapy. *Ann Surg*, 1992; 215: 44–56
15. Luan ZG, Zhang J, Yin XH et al: Ethyl pyruvate significantly inhibits tumour necrosis factor- $\alpha$ , interleukin-1 $\beta$  and high mobility group box 1 releasing and attenuates sodium taurocholate-induced severe acute pancreatitis associated with acute lung injury. *Clin Exp Immunol*, 2013; 172(3): 417–26
16. Chooklin S, Pereyaslov A: Pathogenic role of myeloperoxidase in acute pancreatitis. *Hepatobiliary Pancreat Dis Int*, 2009; 8(6): 627–31
17. Wang S, Chu Y, Huo Y et al: [Effect of astragalus injection on peripheral serum oxidative substances in rats with severe acute pancreatitis.] *Chinese Journal of Medicine*, 2014; 26(12): 5–7 [in Chinese]
18. Xiaotian Z, Xiaoyu Z: [Oxidative free radical scavenger superoxide dismutase and disease.] *Chinese Public Health*, 2014; 30(10): 1349–52 [in Chinese]
19. Manohar M, Verma AK, Venkateshaiah SU et al: Pathogenic mechanisms of pancreatitis. *World J Gastrointest Pharmacol Ther*, 2017; 8(1): 10–25
20. Mirmalek SA, Gholamrezaei Boushehrinejad A, Yavari H et al: Antioxidant and anti-inflammatory effects of coenzyme Q10 on L-Arginine-induced acute pancreatitis in Rat. *Oxid Med Cell Longev*, 2016; 2016: 5818479
21. Zhang FH, Sun YH, Fan KL et al: Protective effects of heme oxygenase-1 against severe acute pancreatitis via inhibition of tumor necrosis factor- $\alpha$  and augmentation of interleukin-10. *BMC Gastroenterol*, 2017; 17: 100
22. Rao SA, Kunte AR: Interleukin-6: An early predictive marker for severity of acute pancreatitis. *Indian J Crit Care Med*, 2017; 21: 424–48
23. Xu P, Lou XL, Chen C: Apoptotic mechanisms of peroxisome proliferator activated receptor- $\gamma$  activation in acinar cells during acute pancreatitis. *Pancreas*, 2016; 45(2): 179–86