

Significance of Diffusion Tensor Imaging of Vastus Medialis Oblique in Recurrent Patellar Dislocation

Li-Si Liu¹, Zhuo-Zhao Zheng², Hui-Shu Yuan¹

¹Department of Radiology, Peking University Third Hospital, Beijing 100191, China

²Department of Radiology, Tsinghua Changgung Hospital, Beijing 102218, China

Abstract

Background: Numerous studies have investigated the influence of osseous factors on patellofemoral joint instability, but research on the influence of dynamic muscle factors *in vivo* is still in the exploratory stage. This study aimed to use magnetic resonance imaging (MRI) and diffusion tensor imaging (DTI) to evaluate vastus medialis oblique (VMO) fiber bundles in patients with recurrent patellar dislocation to explore the changes in muscle morphology and function.

Methods: This prospective study involved 30 patients (7 males and 23 females; average age, 21.4 ± 3.8 years) clinically diagnosed with recurrent patellar dislocation in Peking University Third Hospital and 30 healthy volunteers matched for age, sex, and body mass index in our medical school between January 2014 and October 2014. None of the patients had a recent history of traumatic patellar dislocation or transient patellar dislocation. All patients underwent conventional MRI and DTI of the knee. The cross-sectional area of the VMO on MRI and the fractional anisotropy (FA), apparent diffusion coefficient (ADC), and primary (λ_1), secondary (λ_2), and three-level characteristic (λ_3) values on DTI were measured. The independent-samples *t*-test was used to compare these parameters between the two groups.

Results: Compared with the control group, the patient group showed significantly higher FA values (0.39 ± 0.05 vs. 0.33 ± 0.03) and significantly lower ADC (1.51 ± 0.13 vs. 1.58 ± 0.07), λ_2 (4.96 ± 0.13 vs. 5.04 ± 0.07), and λ_3 values (4.44 ± 0.14 vs. 4.58 ± 0.07 ; $t = 5.99$, $t = -2.58$, $t = -3.02$, and $t = -4.88$, respectively; all $P < 0.05$). Cross-sectional VMO area and λ_1 values did not differ between the two groups ($t = -1.82$ and $t = 0.22$, respectively; both $P > 0.05$).

Conclusions: The functional status of the VMO is closely associated with recurrent patellar dislocation. MRI, especially DTI (FA, ADC, λ_2 , and λ_3), can detect early changes in VMO function and might facilitate the noninvasive monitoring of the functional status of the VMO in patients with recurrent patellar dislocation.

Key words: Diffusion Tensor Imaging; Magnetic Resonance Imaging; Patellar Dislocation; Vastus Medialis Oblique

INTRODUCTION

Patellofemoral joint instability is one of the most common causes of knee pain and/or dysfunction in adolescents. The etiology of this condition is multifactorial. Congenital dysplasia, for example, femoral trochlear dysplasia, patella alta, increased Q angle, and increased patellar tilt angle, is an important factor leading to patellofemoral joint instability. An imbalance between the vastus medialis oblique (VMO) and vastus lateralis muscles as well as weakened medial support to the patella can lead to an increase in lateral patellar displacement.^[1-3]

Numerous studies have investigated the influence of osseous factors on patellofemoral joint instability, but research on the influence of dynamic muscle factors *in vivo* is still in

the exploratory stage.^[4,5] Conventional magnetic resonance imaging (MRI) and diffusion tensor imaging (DTI) can noninvasively reveal macroscopic and microscopic changes in muscle fibers, respectively. In this study, we compared the morphology and function of the VMO between patients with recurrent patellar dislocation and healthy volunteers, using MRI and DTI examination.

Address for correspondence: Dr. Hui-Shu Yuan,
Department of Radiology, Peking University Third Hospital,
Beijing 100191, China
E-Mail: huishuy@bjmu.edu.cn

This is an open access article distributed under the terms of the Creative Commons Attribution-NonCommercial-ShareAlike 3.0 License, which allows others to remix, tweak, and build upon the work non-commercially, as long as the author is credited and the new creations are licensed under the identical terms.

For reprints contact: reprints@medknow.com

© 2017 Chinese Medical Journal | Produced by Wolters Kluwer - Medknow

Received: 29-11-2016 **Edited by:** Yuan-Yuan Ji
How to cite this article: Liu LS, Zheng ZZ, Yuan HS. Significance of Diffusion Tensor Imaging of Vastus Medialis Oblique in Recurrent Patellar Dislocation. Chin Med J 2017;130:642-6.

Access this article online

Quick Response Code:



Website:
www.cmj.org

DOI:
10.4103/0366-6999.201607

METHODS

Subjects

This prospective study was conducted on patients with recurrent patellar dislocation that was clinically diagnosed in Peking University Third Hospital between January 2014 and October 2014. The study protocol was approved by the Ethics Committee at our institution (Peking University Third Hospital) (No. 2014165) and written informed consent was obtained from each patient. Patients were eligible for inclusion in this study if they met the following criteria: multiple episodes of patellar dislocation (more than twice); no knee joint fracture, ligamentous injury, or rupture; no history of knee joint trauma within the past month; and nonathletes without a history of strenuous exercise of the lower extremities within the past month.

Healthy controls were recruited from volunteers in our medical school who had no history of knee-joint trauma, operation, or pain. The controls' history, age, height, and weight were recorded, and the individuals were included in the study if their age, sex, and body mass index (BMI) could be matched with those of the patients. All matched healthy volunteers were nonathletes who had no history of strenuous exercise of the lower extremities during the past month. Informed consent was obtained from both patients and controls.

Imaging method

All patients underwent scanning of the knee joint from the superior border of the patella to the tibial tubercle in a supine position with the knee extended. All scans were obtained using a 3.0-T superconductive MRI Scanner (Signa HDxt, GE Medical Systems, LLC, Milwaukee, WI, USA). A special eight-channel knee-joint coil was used during the scanning. The scanning sequences have been listed below.

1. Axial fast spin echo (FSE) T1-weighted imaging: repetition time (TR), 380 ms; echo time (TE), min full; slice thickness, 4 mm; slice gap, 0.8 mm; field of view (FOV), 150 mm × 150 mm; and matrix, 288 × 256.
2. Axial FSE proton density-weighted imaging (PDWI): TR, 2840 ms; TE, 32 ms; slice thickness, 4 mm; slice gap, 0.8 mm; FOV, 150 mm × 150 mm; and matrix, 288 × 256.
3. Sagittal FSE PDWI: TR, 2840 ms; TE, 32 ms; slice thickness, 3.5 mm; slice gap, 0.4 mm; FOV, 160 mm × 160 mm; and matrix, 320 × 256.
4. Coronal FSE PDWI: TR, 2840 ms; TE, 32 ms; slice thickness, 3.5 mm; slice gap, 0.4 mm; FOV, 160 mm × 160 mm; and matrix, 320 × 256.
5. DTI sequence: Array spatial sensitivity encoding technique; TR, 6000 ms; TE, minimum; $b = 500 \text{ s/mm}^2$; gradient directions, 6; slice thickness, 3.0 mm; slice gap, 0.6 mm; FOV, 180 mm × 180 mm; and matrix, 128 × 128.

Evaluation of imaging data

All images were transmitted to a PACS System (Centricity RIS CE 3.0, GE Medical Systems) on an image workstation (Centricity Radiology RA 600, GE Medical Systems). The PACS system was used to measure the cross-section of the VMO on the FSE PDWI scans of the knee joint. The FuncTool software (GE Medical Systems) was used for the postprocessing of DTI data. We evaluated multiple cross-sectional images of the VMO, starting from the superior border of the patella and moving downward until the muscle fiber bundle disappeared (generally 5 or 6 levels). We delineated the region of interest (i.e., the VMO) on every cross-section. We also measured the fractional anisotropy (FA), apparent diffusion coefficient (ADC), and primary (λ_1), secondary (λ_2), and three-level characteristic values (λ_3) of the VMO on each image. The measurement accuracy was to two decimal places. The average values of the measurements taken for different cross-sections were used in the final analysis. All measurements were repeated after an interval of 3 months, by the same researcher.

Statistical analysis

SPSS 19.0 software (SPSS, IBM, NY, USA) was used for statistical analysis. All measurement data were expressed as mean ± standard deviation (SD). The independent-samples *t*-test was used for comparisons between the two groups. A $P < 0.05$ was considered statistically significant. Interclass correlation coefficients (ICCs) were used to check the consistency of the measurements taken at the baseline and 3 months. ICC values of <0.40 indicated poor consistency, values of $0.40\text{--}0.75$ indicated fair consistency, and values of >0.75 indicated good consistency.

RESULTS

General information

We enrolled 30 patients and 30 matched controls in this study. All patients underwent routine MRI and DTI of the knee joint. The patient group consisted of 7 males (3 left knees, 4 right knees) and 23 females (11 left knees, 12 right knees). The average age of the patients was 21.4 ± 3.8 years (range, 15–29 years), and their average BMI was $21.2 \pm 3.2 \text{ kg/m}^2$. The control group also included 7 males (3 left knees, 4 right knees) and 23 females (11 left knees, 12 right knees). The average age of the controls was 21.9 ± 3.1 years (range, 15–29 years), and their average BMI was $20.8 \pm 2.6 \text{ kg/m}^2$. There were no statistically significant differences in age and BMI between the two groups ($t = -0.64$ and $t = 0.50$, respectively; both $P > 0.05$).

Cross-sectional area of the vastus medialis oblique

The average cross-sectional area of the VMO was $3.79 \pm 1.03 \text{ cm}^2$ in the patient group and $4.41 \pm 1.57 \text{ cm}^2$ in the control group. No significant difference was present in this area between the two groups ($t = -1.82$, $P = 0.07$).

Diffusion tensor imaging findings

Good consistency was observed between the baseline and 3-month measurements ($ICC > 0.9$). We, therefore, used the average of the two values for the final analysis. The DTI findings are presented in Table 1. The FA value was significantly higher and the ADC, λ_2 , and λ_3 values were significantly lower among the patients than among the controls [Figures 1-3]. The λ_1 value was higher among the patients than among the controls, but the difference was not statistically significant.

DISCUSSION

The present study revealed that the ADC, λ_2 , and λ_3 values of the VMO were significantly lower while the FA value was significantly higher in patients with recurrent patellar dislocation than that in healthy matched controls.

Dynamic factors related to recurrent patellar dislocation

The stability of the patellofemoral joint depends on the underlying morphology and the balance of static and

dynamic soft-tissue forces that interact in a complex way. Ligamentous and bony anatomy of the knee is the primary stabilizer, and the quadriceps musculature is the secondary stabilizer. The influence of dynamic soft-tissue constraints on the stability at the patellofemoral joint remains controversial.^[4]

The vastus medialis muscle can be divided into a long head and the VMO. The VMO originates from the medial part of the distal end of the femur and adductor tubercle and attaches to the medial patellar retinaculum and superomedial border of the patella. The VMO is considered to be the main dynamic patellar-stability device against the acting force of the vastus lateralis muscle. Dysfunction of the VMO can reduce the binding force of the medial patella and forms part of the pathological basis of recurrent lateral patellar dislocation.^[5-7] However, due to the complex etiology of patellar dislocation, with abnormal bony structure considered as the main responsible factor, it is unclear whether or not structural and functional abnormalities of the VMO are causally linked to recurrent patellar dislocation.^[8-10]

Skeletal muscle consists of multinucleated fiber cells. Muscle atrophy leads to the geometric distortion of the cell membrane and decreases the diameter of the muscle fiber, eventually resulting in a reduced muscle cross-sectional area. In this study, the cross-sectional area of the VMO in patients with recurrent patellar dislocation showed a decreasing trend but was not significantly different from the area in healthy volunteers. It has been speculated that early changes in the muscle fibers are mainly manifested as changes in muscle strength; gross structural abnormalities only occur once the early changes have accumulated to a certain degree.^[11] As conventional MRI is unable to quantitatively assess

Table 1: Results of diffusion tensor imaging of the vastus medialis oblique in patients with patellofemoral instability ($n = 30$) and matched healthy controls ($n = 30$)

| Items | Disease | Control | <i>t</i> | <i>P</i> |
|-------------|-----------------|-----------------|----------|----------|
| FA | 0.39 ± 0.05 | 0.33 ± 0.03 | 5.99 | <0.01 |
| ADC | 1.51 ± 0.13 | 1.58 ± 0.07 | -2.58 | 0.01 |
| λ_1 | 5.63 ± 0.14 | 5.62 ± 0.10 | 0.22 | 0.83 |
| λ_2 | 4.96 ± 0.13 | 5.04 ± 0.07 | -3.02 | 0.01 |
| λ_3 | 4.44 ± 0.14 | 4.58 ± 0.07 | -4.88 | <0.01 |

Data were shown as mean \pm SD. FA: Fractional anisotropy; ADC: Apparent diffusion coefficient; λ_1 : Primary characteristic value; λ_2 : Secondary characteristic value; λ_3 : Three-level characteristic value. SD: Standard deviation.

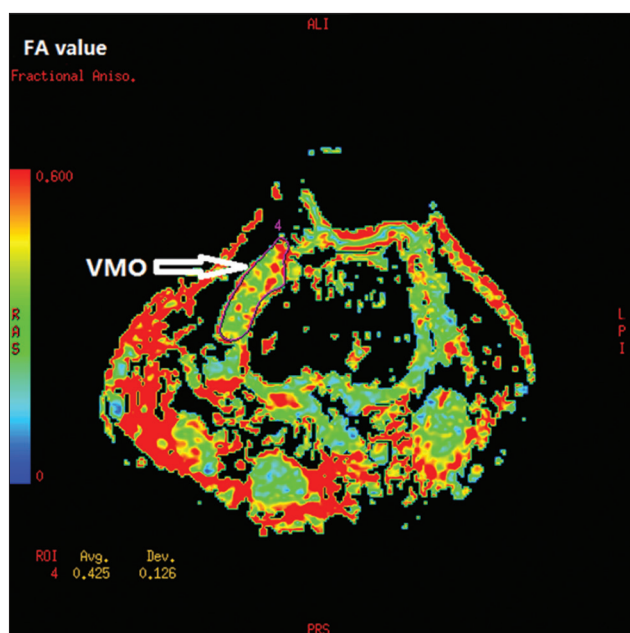


Figure 1: Diffusion tensor imaging of the left knee in a 21-year-old woman with patellofemoral instability. Pseudocolor cross-sectional images show fractional anisotropy (FA) values of the vastus medialis oblique (VMO).

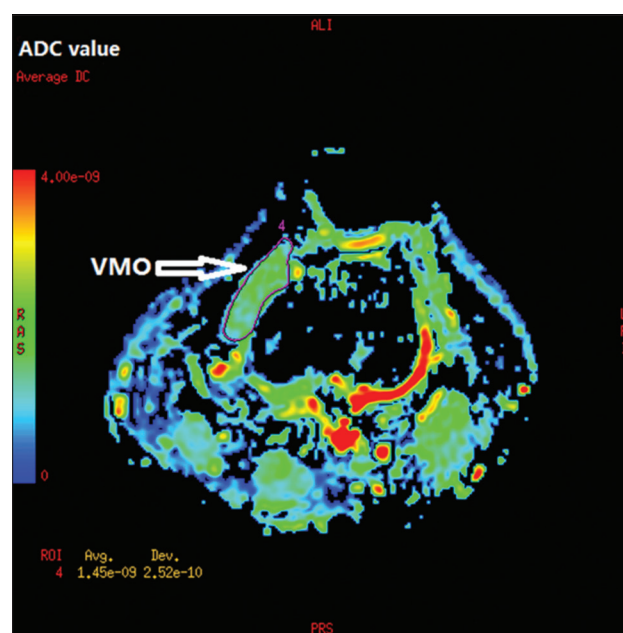


Figure 2: Diffusion tensor imaging of the left knee in a 21-year-old woman with patellofemoral instability. Pseudocolor cross-sectional images show apparent diffusion coefficients (ADC) of the vastus medialis oblique (VMO).

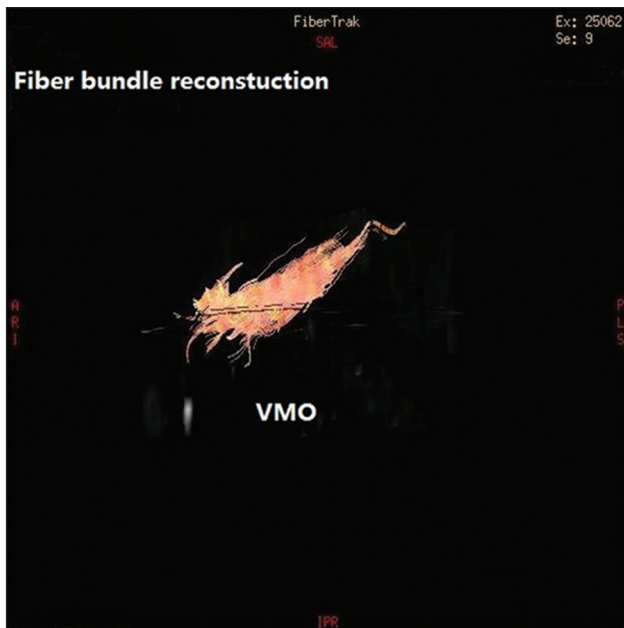


Figure 3: Vastus medialis oblique (VMO) fiber bundle reconstruction of the left knee in a 21-year-old woman with patellofemoral instability.

changes in muscle strength, and as DTI parameters show some correlation with these changes,^[12] we speculated that changes in relevant DTI parameters would be more sensitive than changes in the cross-sectional area of VMO.

Sensitivity of diffusion tensor imaging in detecting muscle fiber changes

Since muscle fiber bundles have high anisotropy, the muscle microenvironment can cause changes in the microstructure of muscle fibers, which lead to further changes in DTI parameters; therefore, DTI can have good diagnostic value.^[13,14] The FA values of muscles vary with conditions such as edema, muscle damage, and tears; therefore, it is feasible to quantitatively assess the internal micromolecular pathological changes in skeletal muscles by calculating DTI parameters such as FA and ADC values. These values can be used to evaluate skeletal muscle damage, denervation atrophy, ischemia, nutritional disorders, inflammatory lesions, etc., and can sensitively detect changes in the tissue microstructure.^[15-17]

FA values range from 0 to 1. An FA value of 0 represents an absolute isotropic tensor, like a ball, while a value of 1 indicates absolute linear tensors that only spread in one vector direction. ADC values have been associated with cell morphology and mainly reflect diffusion across the cell membrane in the skeletal muscle fibers. The ADC value is decreased when diffusion is limited. The λ_1 , λ_2 , and λ_3 values represent diffusivity along the long axis of a muscle fiber, along the muscle bundle in the direction of the endomysium, and along the cross-section of the muscle fiber, respectively.^[18,19] Okamoto *et al.*^[20] explored the diffusion properties of motion-related changes in calf muscle structure using DTI technology and found changes in ADC, λ_1 , λ_2 , and λ_3 values among different muscle groups. The authors believed that these changes were caused by cell

deformation due to increased intracellular space as well as extracellular components.

Diffusion tensor imaging parameters related to changes in vastus medialis oblique in recurrent patellar dislocation

Muscle relaxation and VMO weakness are congenital factors leading to recurrent patellar dislocation. Human skeletal muscles are mainly divided into two types: Type-1 fibers, which maintain permanent endurance mainly through aerobic metabolism, and Type-2 fibers, which provide maximal mechanical power mainly through anaerobic metabolism. The two types of fibers have different diameters and intracellular microstructures. Type-2 fiber bundles have a larger radius and lower mitochondrial density than Type-1 fiber bundles. Under physiological conditions, the number of muscle fibers in the axial plane and the average diffusivity increase as the muscle contracts; the λ_2 and λ_3 values decrease as the muscle relaxes. The muscle size and strength gradually decrease with age, mainly due to changes in muscle fiber type and diameter. Type-2 rapid-contraction fibers will begin to atrophy first, leading to decreased muscle fiber diameter and increased extracellular components.^[12,18]

This study showed that in patients with recurrent patellar dislocation, the ADC, λ_2 , and λ_3 values of the VMO were decreased, while the FA value was increased. The λ_2 and λ_3 values represent the diffusion tensor perpendicular to the long axis of muscle fiber bundles. Thus, these values are directly proportional to the diffusion direction of the muscle fiber diameter. A decrease in muscle strength may result in the reduction of these two parameters, especially λ_3 , because it reflects the cross-sectional diffusion tensor of water molecules within individual muscle fibers.^[18,19] In addition, the decrease in ADC values observed in this study was mainly attributable to lower λ_2 and λ_3 values, further illustrating that muscle fibers with a smaller diameter, fewer internal components, and increased extracellular tissue can lead to limited diffusion. Decreased λ_2 and λ_3 values can result in asymmetric diffusion, reduced radial dispersion coefficient, and higher anisotropy, eventually leading to higher FA values.

Studies have shown that DTI parameters are closely associated with the pathology of muscle lesions and internal tissue structure changes. Scheel *et al.*^[12] reported that FA values are negatively correlated with maximal muscle strength: the weaker is the muscle strength, the greater is the FA value, and the corresponding muscle fiber type also changes. These results are consistent with the findings of the present study. Saotome *et al.*^[21] evaluated mice in which skeletal muscle atrophy was induced by denervation; the authors found that in atrophic muscle tissue, FA values were increased, while λ_2 and λ_3 values were decreased. This is because λ_2 and λ_3 reflect the sparse muscle fiber density in the cross-sectional direction, which is caused by a decrease in the diameter of the muscle fibers. The λ_1 values were not obviously changed, as λ_1 represents the anisotropy of the muscle fibers in the long axis direction. These results are consistent with the findings of the present study.

Muscle atrophy is manifested as reduced muscle volume, increased connective tissue, or fat components among muscle bundles on histomorphology, as well as weakened muscle tension. Changes in relevant anisotropy and diffusion function parameters on DTI might be caused by changes in muscle fiber diameter and intracellular diffusion coefficients. In addition, different types of fiber composition, number of water molecules in the intercellular space, and cell membrane permeability also affect DTI parameters.^[22,23]

The study had two deficiencies. First, the sample size was not large enough. The cross-sectional area of the VMO showed a decreasing trend in patients with recurrent patellar dislocation but without significant differences from healthy volunteers; this result might be different when the sample size is increased. Second, muscle atrophy, in addition to reducing the muscle volume, can also lead to increased connective tissue or fat components among the muscle bundles. Quantitative measurement of the fat components in the intramuscular spaces would have improved the quality of this study and should be pursued in future experiments.

In conclusion, when compared with healthy volunteers, patients with patellofemoral joint instability showed increased FA values and decreased ADC, λ_2 , and λ_3 values in the VMO muscle, implying that a decrease in the diameter of the muscle fibers resulted in decreased muscle strength, which might be a factor causing patellofemoral joint instability. In addition, the cross-sectional area of the VMO showed a decreasing trend, but the difference was not significant. This finding might imply that microstructural changes in the muscle fibers precede morphological changes in the muscles. Thus, relevant DTI parameters can be used to assess the early microstructural changes in skeletal muscles in patients with patellofemoral instability.

Financial support and sponsorship

Nil.

Conflicts of interest

There are no conflicts of interest.

REFERENCES

- Diederichs G, Issever AS, Scheffler S. MR imaging of patellar instability: Injury patterns and assessment of risk factors. *Radiographics* 2010;30:961-81. doi: 10.1148/rg.304095755.
- Smith TO, Davies L, Toms AP, Hing CB, Donell ST. The reliability and validity of radiological assessment for patellar instability. A systematic review and meta-analysis. *Skeletal Radiol* 2011;40:399-414. doi: 10.1007/s00256-010-0961-x.
- Salzmann GM, Weber TS, Spang JT, Imhoff AB, Schöttle PB. Comparison of native axial radiographs with axial MR imaging for determination of the trochlear morphology in patients with trochlear dysplasia. *Arch Orthop Trauma Surg* 2010;130:335-40. doi: 10.1007/s00402-009-0912-y.
- Mulford JS, Wakeley CJ, Eldridge JD. Assessment and management of chronic patellofemoral instability. *J Bone Joint Surg Br* 2007;89:709-16. doi: 10.1302/0301-620X.89B6.19064.
- Senavongse W, Amis AA. The effects of articular, retinacular, or muscular deficiencies on patellofemoral joint stability: A biomechanical study *in vitro*. *J Bone Joint Surg Br* 2005;87:577-82. doi: 10.1302/0301-620X.87B4.14768.

- Fitzpatrick CK, Steensen RN, Tumuluri A, Trinh T, Bentley J, Rullkoetter PJ. Computational analysis of factors contributing to patellar dislocation. *J Orthop Res* 2016;34:444-53. doi: 10.1002/jor.23041.
- Raimondo RA, Ahmad CS, Blankevoort L, April EW, Grelsamer RP, Henry JH. Patellar stabilization: A quantitative evaluation of the vastus medialis obliquus muscle. *Orthopedics* 1998;21:791-5. doi: 10.3928/0147-7447-19980701-08.
- Kan JH, Heemskerk AM, Ding Z, Gregory A, Mencio G, Spindler K, et al. DTI-based muscle fiber tracking of the quadriceps mechanism in lateral patellar dislocation. *J Magn Reson Imaging* 2009;29:663-70. doi: 10.1002/jmri.21687.
- Balcarek P, Oberthür S, Frosch S, Schüttrumpf JP, Stürmer KM. Vastus medialis obliquus muscle morphology in primary and recurrent lateral patellar instability. *Biomed Res Int* 2014;2014:326586. doi: 10.1155/2014/326586.
- Pattyn E, Verdonk P, Steyaert A, Vanden Bossche L, Van den Broecke W, Thijs Y, et al. Vastus medialis obliquus atrophy: Does it exist in patellofemoral pain syndrome? *Am J Sports Med* 2011;39:1450-5. doi: 10.1177/03635465114101183.
- Froeling M, Oudeman J, Strijkers GJ, Maas M, Drost MR, Nicolay K, et al. Muscle changes detected with diffusion-tensor imaging after long-distance running. *Radiology* 2015;274:548-62. doi: 10.1148/radiol.14140702.
- Scheel M, Prokscha T, von Roth P, Winkler T, Dietrich R, Bierbaum S, et al. Diffusion tensor imaging of skeletal muscle – Correlation of fractional anisotropy to muscle power. *Rofo* 2013;185:857-61. doi: 10.1055/s-0033-1335911.
- Heemskerk AM, Strijkers GJ, Vilanova A, Drost MR, Nicolay K. Determination of mouse skeletal muscle architecture using three-dimensional diffusion tensor imaging. *Magn Reson Med* 2005;53:1333-40. doi: 10.1002/mrm.20476.
- Budzik JF, Le Thuc V, Demondion X, Morel M, Chechin D, Cotten A. *In vivo* MR tractography of thigh muscles using diffusion imaging: Initial results. *Eur Radiol* 2007;17:3079-85. doi: 10.1007/s00330-007-0713-z.
- Oudeman J, Nederveen AJ, Strijkers GJ, Maas M, Luijten PR, Froeling M, et al. Techniques and applications of skeletal muscle diffusion tensor imaging: A review. *J Magn Reson Imaging* 2016;43:773-88. doi: 10.1002/jmri.25016.
- Zhang J, Zhang G, Morrison B, Mori S, Sheikh KA. Magnetic resonance imaging of mouse skeletal muscle to measure denervation atrophy. *Exp Neurol* 2008;212:448-57. doi: 10.1016/j.expneurol.2008.04.033.
- Ha DH, Choi S, Kang EJ, Park HT. Diffusion tensor imaging and T2 mapping in early denervated skeletal muscle in rats. *J Magn Reson Imaging* 2015;42:617-23. doi: 10.1002/jmri.24818.
- Galbán CJ, Maderwald S, Uffmann K, de Greiff A, Ladd ME. Diffusive sensitivity to muscle architecture: A magnetic resonance diffusion tensor imaging study of the human calf. *Eur J Appl Physiol* 2004;93:253-62. doi: 10.1007/s00421-004-1186-2.
- Froeling M, Nederveen AJ, Heijtel DF, Lataster A, Bos C, Nicolay K, et al. Diffusion-tensor MRI reveals the complex muscle architecture of the human forearm. *J Magn Reson Imaging* 2012;36:237-48. doi: 10.1002/jmri.23608.
- Okamoto Y, Kemp GJ, Isobe T, Sato E, Hirano Y, Shoda J, et al. Changes in diffusion tensor imaging (DTI) eigenvalues of skeletal muscle due to hybrid exercise training. *Magn Reson Imaging* 2014;32:1297-300. doi: 10.1016/j.mri.2014.07.002.
- Saotome T, Sekino M, Eto F, Ueno S. Evaluation of diffusional anisotropy and microscopic structure in skeletal muscles using magnetic resonance. *Magn Reson Imaging* 2006;24:19-25. doi: 10.1016/j.mri.2005.09.009.
- Li K, Dortch RD, Welch EB, Bryant ND, Buck AK, Towse TF, et al. Multi-parametric MRI characterization of healthy human thigh muscles at 3.0 T-relaxation, magnetization transfer, fat/water, and diffusion tensor imaging. *NMR Biomed* 2014;27:1070-84. doi: 10.1002/nbm.3159.
- Hara Y, Ikoma K, Kido M, Sukenari T, Arai Y, Fujiwara H, et al. Diffusion tensor imaging assesses triceps surae dysfunction after achilles tenotomy in rats. *J Magn Reson Imaging* 2015;41:1541-8. doi: 10.1002/jmri.24707.