

# The Vectra M3 3-dimensional digital stereophotogrammetry system: A reliable technique for detecting chin asymmetry

Stina Hansson<sup>1</sup>, Emil Östlund<sup>1</sup>, Farhan Bazargani<sup>1,\*</sup>

<sup>1</sup>Department of Orthodontics, Postgraduate Dental Education Center and School of Medical Sciences, Faculty of Medicine and Health, Örebro University, Örebro, Sweden

## ABSTRACT

**Purpose:** The aim of this study was to evaluate the reliability of the Vectra M3 (3D Imaging System; Canfield Scientific, Parsippany, NJ, USA) in detecting chin asymmetry, and to assess whether the automatic markerless tracking function is reliable compared to manually plotting landmarks.

**Materials and Methods:** Twenty subjects (18 females and 2 males) with a mean age of  $42.5 \pm 10.5$  years were included. Three-dimensional image acquisition was carried out on all subjects with simulated chin deviation in 4 stages (1-4 mm). The images were analyzed by 2 independent observers through manually plotting landmarks and by Vectra software auto-tracking mode. Repeated-measures analysis of variance and the Tukey post-hoc test were performed to evaluate the differences in mean measurements between the 2 operators and the software for measuring chin deviation in 4 stages. The intraclass correlation coefficient (ICC) was calculated to estimate the intra- and inter-examiner reliability.

**Results:** No significant difference was found between the accuracy of manually plotting landmarks between observers 1 and 2 and the auto-tracking mode ( $P=0.783$  and  $P=0.999$ , respectively). The mean difference in detecting the degree of deviation according to the stage was  $<0.5$  mm for all landmarks.

**Conclusion:** The auto-tracking mode could be considered as reliable as manually plotted landmarks in detecting small chin deviations with the Vectra<sup>®</sup> M3. The effect on the soft tissue when constructing a known dental movement yielded a small overestimation of the soft tissue movement compared to the dental movement (mean value  $<0.5$  mm), which can be considered clinically non-significant. (*Imaging Sci Dent* 2022; 52: 43-51)

**KEY WORDS:** Photogrammetry; Imaging, Three-Dimensional; Facial Asymmetry

## Introduction

Methods that enable the objective assessment of facial form are becoming increasingly important for research in dysmorphology, genetics, orthodontics, and surgical disciplines, among others.<sup>1</sup> Stereophotogrammetry is a technology that uses at least 2 cameras at different angles to capture pictures simultaneously and create a 3-dimensional (3D) image.<sup>2</sup>

The safety, speed, and reliability of data acquisition that

3D camera systems offer are particularly helpful when working with young children, for whom quantification of facial features can be challenging.<sup>3</sup> Because these systems do not require any ionizing radiation, they have been used both to evaluate treatment in infants with cleft lip and palate and to assess healthy newborns.<sup>1,4</sup> There are different kinds of imaging modalities, and some have been compared before;<sup>5,6</sup> however, as new technologies reach operators, they need to be validated for clinical and research purposes. In orthodontics, 3D camera technology has been used foremost for orthognathic patients who undergo maxillofacial surgery,<sup>7-9</sup> but it could also be useful for evaluating the outcomes of less extensive orthodontic treatment.

Facial asymmetry is common,<sup>10,11</sup> mostly in the mid-face and the chin.<sup>11</sup> A pronounced deviation of the chin has been

Received July 2, 2021; Revised October 3, 2021; Accepted October 11, 2021

Published online November 18, 2021

\*Correspondence to : Prof. Farhan Bazargani

Department of Orthodontics, P.O. Box 1126, SE-701 11 Örebro, Sweden and School of Medical Sciences, Faculty of Medicine and Health, Örebro University, Örebro SE-701 82, Sweden

Tel) 46-19-602-4050, E-mail) farhan.bazargani@regionorebrolan.se

Copyright © 2022 by Korean Academy of Oral and Maxillofacial Radiology

This is an Open Access article distributed under the terms of the Creative Commons Attribution Non-Commercial License (<http://creativecommons.org/licenses/by-nc/3.0>) which permits unrestricted non-commercial use, distribution, and reproduction in any medium, provided the original work is properly cited.

Imaging Science in Dentistry · pISSN 2233-7822 eISSN 2233-7830

considered less attractive by both laypersons and clinicians,<sup>12</sup> and the perceptive threshold is a chin deviation of 5-6 mm.<sup>13</sup> It has been argued that untreated posterior cross-bite, which is a common malocclusion in children, can induce facial asymmetry with positional deviation of the mandible,<sup>14</sup> and consequently, the chin.

Evaluations of lateral deviation of the chin have previously been conducted using 3D computed tomography;<sup>15</sup> however, there is an essential need to explore the advantages of systems that do not require ionizing radiation.

The 3dMDface system (3dMD Inc, Atlanta, GA, USA) has been evaluated extensively in the literature.<sup>6,10,16-18</sup> However, not many studies have evaluated the accuracy of the Vectra<sup>®</sup> M3 (3D Imaging System; Canfield Scientific, Parsippany, NJ, USA), which is a 3D imaging system for the face and neck that is smaller than the Vectra XT full-body imaging system, one of the largest 3D imaging systems in the market. Vectra<sup>®</sup> M3 is a stationary 3D digital imaging system for the face and neck. It consists of 3 pods with 2 cameras each, for a total of 6 cameras capturing the face simultaneously. The esthetic simulation software Face Sculptor<sup>®</sup> (Canfield Scientific, Parsippany, NJ, USA) and the Vectra<sup>®</sup> 3D Analysis Module (VAM; Canfield Scientific, Parsippany, NJ, USA) can be used when analyzing images. The Vectra<sup>®</sup> M3 has been used for evaluating areas around the nose and eyes in the fields of plastic and orthognathic surgery,<sup>8,19-22</sup> but it has not yet been used to estimate deviation of the chin area, which is a subject of interest when treating young patients with posterior crossbite. Camera manufacturers provide suggestions for device set-up and calibration, although limited information is available on the practical issues that inevitably confront new users of this technology. However, these issues can adversely impact the reliability of data collection, and consequently, influence

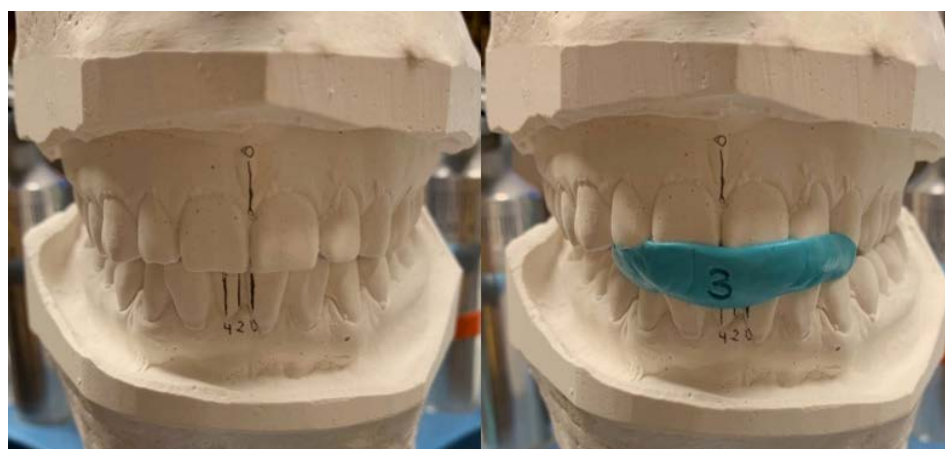the results in both clinical settings and research studies. To ensure optimal interpretation of the study results, all aspects of data collection should be rigorously evaluated.<sup>23</sup> Manually placing landmarks on 3D images is challenging, as a precise location is required in a multiplanar reconstruction. There is extensive variability in the nasolabial and mentolabial areas that needs to be treated with discretion with regard to the issue of intra-examiner repeatability.<sup>24</sup> Automation of the procedure using a robust system with good reproducibility and minimal false identifications would enable consistent landmark identification and subsequent derivation of measurements and angles.<sup>25</sup>

Thus, the aims of this prospective study were 2-fold. The primary aim was to validate the Vectra<sup>®</sup> M3 imaging system and whether the automatic markerless tracking function in the Face Sculptor<sup>®</sup> software was reliable compared to manually plotting landmarks in VAM. The secondary aim was to investigate to what extent the dental midline deviation affected the facial asymmetry and deviation of the chin.

## Materials and Methods

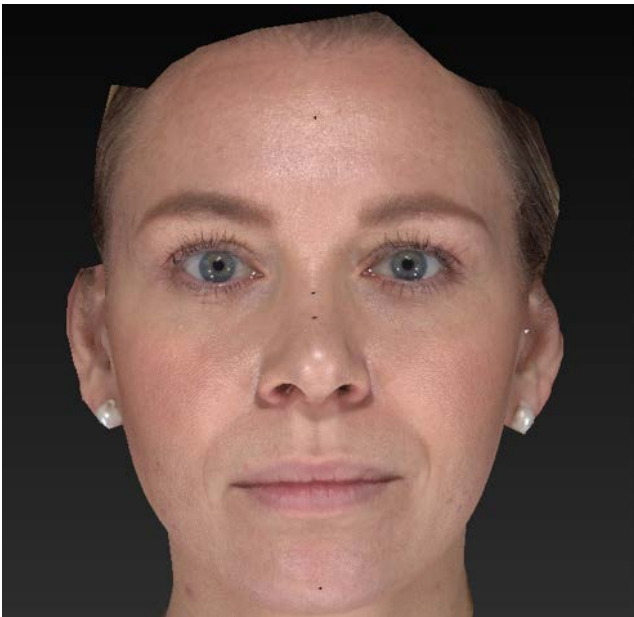Twenty adult subjects were prospectively recruited to participate in this study. All subjects were volunteers recruited from the staff of the Department of Orthodontics in Region Örebro, Sweden. All participants provided written informed consent before taking part. Image acquisition using Vectra<sup>®</sup> M3 was carried out in spring 2020. The Regional Ethical Review Board in Uppsala, Sweden, which followed the guidelines of the Declaration of Helsinki, approved the study protocol (Dnr: 2018/308).

The inclusion criterion was the ability to take an alginate imprint, and subjects with excessive facial hair were



**Fig. 1.** Individually performed index in putty and midline deviation measured on the cast.

excluded.<sup>1</sup> In order to generate chin deviations, alginate impressions (Cavex Orthotrace, Haarlem, The Netherlands) were performed on all subjects. Dental casts were mounted on an articulator (Dentatus, Stockholm, Sweden), and 5 different indices were made in putty (Provil Novo Putty, Kulzer, Germany) to set the jaws with a defined amount of dental deviation, as follows: 0, no deviation/centric occlusion; 1: 1-mm dental midline deviation to the left, 2: 2-mm dental midline deviation to the left, 3: 3-mm dental midline deviation to the left, and 4: 4-mm dental midline deviation to the left (Fig. 1). The deviation (1-4 mm) was created irre-



**Fig. 2.** Four dots, with an eyeliner, was marked in the midline of the subjects faces before taking the pictures. Three point are placed as a control at the more stable part of the face; one in the forehead, two on the nose ridge. The last point is placed on the chin, soft pogonion (sPg) which is used as the point to measure the movement of the chin.

spective of whether there was any dental midline deviation to begin with.

### Three-dimensional image acquisition

Using eyeliner (Inliner Kajal Waterline Black, IsaDora, Malmö, Sweden), 4 dots were marked in the midline of the subjects' faces before taking the images. Three points were marked as a control at the more stable part of the face: 1 on the forehead, and 2 on the nose ridge. The last point was placed on the chin - specifically, on the soft pogonion (sPg) - to measure the movement of the chin (Fig. 2).


The individually created indices were then placed between the teeth, and during the image acquisition the participants were instructed to relax and maintain as natural a facial expression as possible. Five 3D images were obtained with Vectra<sup>®</sup> M3, version 6.2.3, 1 with each index: 1 in centric occlusion and the other 4 having a dental midline deviation of 1-4 mm.

### Image measurements

To investigate whether the measurements made in VAM (version 6.2.3) were comparable to the automatic superpositioning and markerless tracking made by the Face Sculptor<sup>®</sup> software (version 6.2.3), the images were analyzed in both programs.

### Using VAM

The image in centric occlusion was registered as a baseline 3D image on an axis grid (Fig. 3), using VAM, in accordance with the manual. It is essential to register a baseline 3D image to the axis grid. This established the permanent reference to which all of the patient's future images were registered. The other 4 images were then registered subsequent to the baseline image using image contouring. The area chosen for registration was the forehead and nose



**Fig. 3.** The registration to the axis grid using Vectra Analys Module (VAM).

ridge (Fig. 4).

After registration, the baseline and the subsequent images were measured by manually plotting landmarks on the eyeliner-marked sPg on both images (Fig. 5). The coordinates (x, y, z) and the distance between the points were then calculated.

Each individual's 4 images (with deviations of 1 mm, 2 mm, 3 mm, and 4 mm) were measured independently by 2 operators. Half of the individuals were randomized to be measured twice on 2 separate occasions at a minimum interval of 2 weeks in order to evaluate the inter- and intra-examiner reliability.

#### Using Face Sculptor®

The original images, which had not been preprocessed in any way, were automatically paired (0 mm with 1 mm, 0

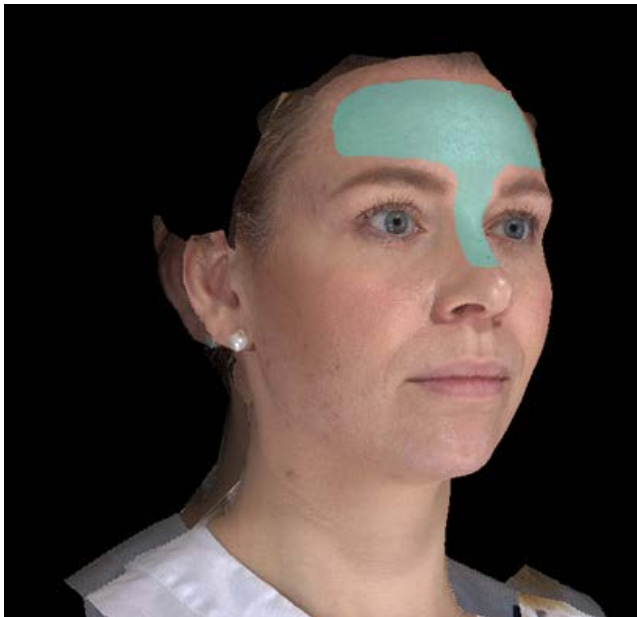

Fig. 4. Image contour. Area chosen for registration.

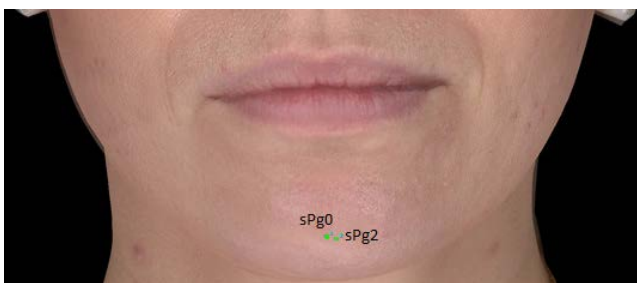

Fig. 5. Manually landmarking on the eyeliner dots the soft pogonion (sPg) on the registered baseline picture (sPg0) and on the registered subsequent picture (sPg2). The distance between the landmarks are then measured.

mm with 2 mm, 0 mm with 3 mm, and 0 mm with 4 mm) and opened with the markerless tracking feature. Markerless tracking automatically aligned a pair of 3D images, and the skin surfaces were tracked and mapped. Color-coded arrows and a scale in millimeters, displayed to the left, visualized the measurements (Fig. 6). The color of the arrow closest to the eyeliner point on the soft tissue pogonion was translated into a millimeter measure; if the color was between 2 gradients, the mean value was registered. Using a color-coded map to show measurements has previously been demonstrated.<sup>6</sup>

#### Sample size calculation

The calculated sample size for the study group was based on a significance level of 0.05 and a power of 80% to detect a difference of 0.5 mm (standard deviation [SD]  $\pm 0.5$ ) in chin deviation. The sample size calculation indicated that 20 participants would be required.

#### Statistical analysis

Repeated-measures analysis of variance (ANOVA) and the Tukey post-hoc test were performed to evaluate differences in the mean measurements between the 2 operators and the software measuring the chin deviations in 4 stages. The intraclass correlation (ICC) was calculated to estimate the inter- and intra-examiner reliability with a 95% confi-

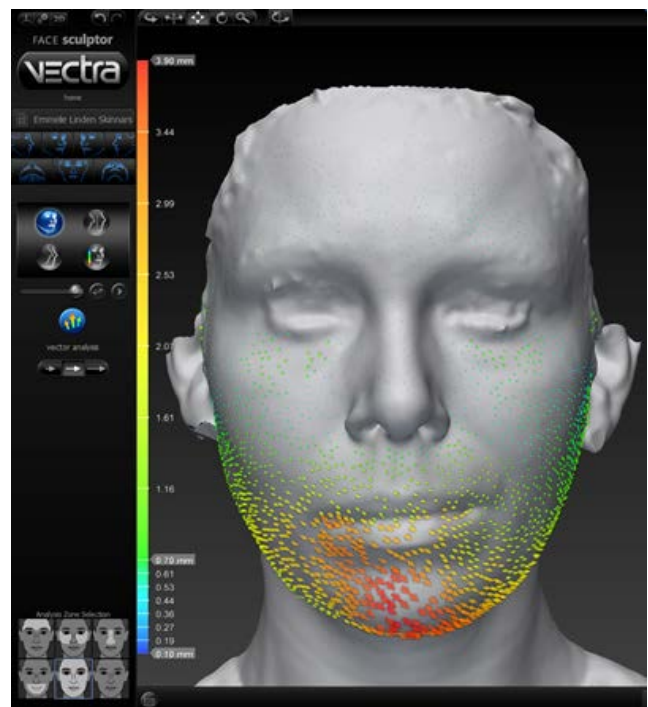


Fig. 6. Face sculptor® and markerless tracking with vector analysis uses color-coded arrows.

**Table 1.** Measurements of all 20 subjects with 4 different indices, with dental midline deviations of 1–4 mm. All measurements are given in millimeters

Dental midline deviation with index			Examiner 1 Manual plot	Examiner 2 Manual plot	Vectra® M3 auto tracking
1 mm	N	Valid	20.0	20.0	20.0
		Missing	0.0	0.0	0.0
	Mean		1.5	1.4	1.4
	Median		1.5	1.3	1.4
	Standard deviation		0.6	0.6	0.5
	Range		2.4	2.5	2.0
	Minimum		0.7	0.6	0.5
	Maximum		3.1	3.1	2.5
2 mm	N	Valid	20.0	20.0	20.0
		Missing	0.0	0.0	0.0
	Mean		2.2	2.2	2.2
	Median		2.2	2.3	2.4
	Standard deviation		0.6	0.6	0.5
	Range		2.1	2.2	1.9
	Minimum		1.0	0.9	1.0
	Maximum		3.2	3.1	2.8
3 mm	N	Valid	20.0	20.0	20.0
		Missing	0.0	0.0	0.0
	Mean		3.4	3.5	3.4
	Median		3.3	3.3	3.6
	Standard deviation		0.9	0.9	0.8
	Range		4.0	4.2	3.5
	Minimum		1.8	1.7	1.8
	Maximum		5.9	6.0	5.3
4 mm	N	Valid	20.0	20.0	20.0
		Missing	0.0	0.0	0.0
	Mean		4.3	4.3	4.2
	Median		4.3	4.2	4.2
	Standard deviation		1.0	0.9	0.9
	Range		4.0	3.0	3.6
	Minimum		2.2	3.0	2.5
	Maximum		6.2	6.0	6.1

dence interval (CI). A *P*-value below 0.05 was considered to indicate statistical significance, and the analyses were performed with SPSS version 25 (IBM Corp., Armonk, NY, USA). Descriptive statistics were calculated for examiner 1, examiner 2, and the markerless tracking, divided into dental midline shifts of 1 mm, 2 mm, 3 mm, and 4 mm.


## Results

Twenty subjects (18 females and 2 males) with a mean age of  $42.5 \pm 10.5$  years were included in this study. The des-

criptive data, as presented in Table 1, included the median, mean, range, SD, and minimum and maximum values from the measurements of both examiners and the Face Sculptor® markerless tracking (auto tracking) in the Vectra software. The data were normally distributed. The mean difference in detecting the degree of deviation according to the index was  $<0.5$  mm for all configurations.

There were also no statistically significant differences between the 3 measurements and 4 indices regarding detection of the degree of chin deviation. The range and individual differences in how the dental midline deviation affected





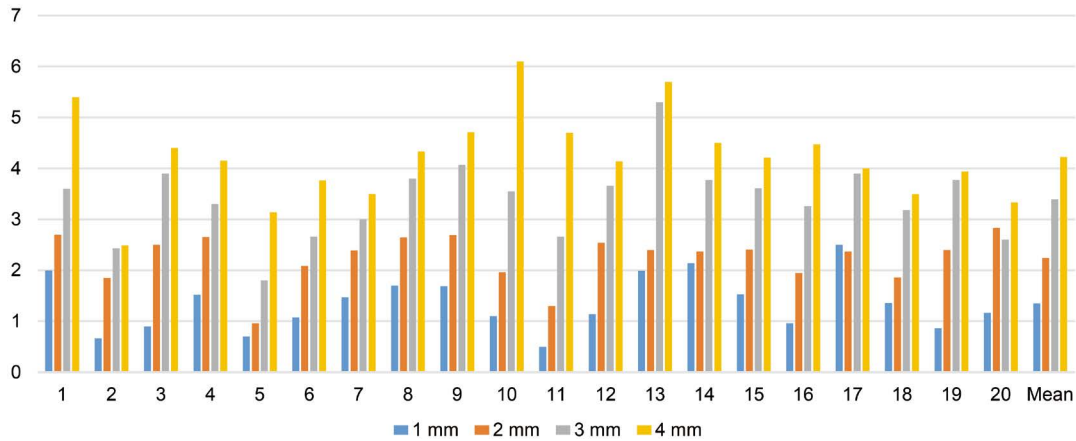
**Fig. 7.** Markerless tracking of the 3 mm deviation of the dental midline superimposed on no deviation.

the soft tissue are visualized in Figure 7 and also described in Figure 8. The effect of the sPg when the dental midline was deviated by 1 mm yielded a mean 40% overestimation (0.4 mm) compared to the index, while a 2-mm dental midline deviation resulted in a mean 10% overestimation (0.2 mm), a 3-mm dental midline deviation led to a 13% overestimation (0.4 mm), and a 4-mm dental midline deviation resulted in a 5% (0.2 mm) overestimation compared to the

index.

No significant difference was found between the accuracy of manually plotted landmarks between observers 1 and 2 and the auto-tracking mode ( $P=0.783$  and  $P=0.999$ , respectively).

The ICC for inter-examiner reliability of the manually plotted landmarks was 0.993 (95% CI, 0.990-0.996), and those for the intra-examiner reliability for examiners 1 and



**Fig. 8.** Soft tissue changes of the soft pogonion with deviations of the dental midline using indices of 1-4 mm. The values are based on VECTRA<sup>®</sup> M3 auto tracking.

2 were 0.988 (95% CI, 0.977-0.994) and 0.996 (95% CI, 0.993-0.998), respectively. All values were  $>0.9$ , indicating excellent reliability.

## Discussion

To the authors' knowledge, this is the first study to evaluate the reliability of the Vectra system in detecting chin asymmetry. No significant differences were found between the examiners and the auto-tracking method by Face Sculptor<sup>®</sup> in the Vectra software. This indicates that auto-tracking with color mapping is as reliable as manually plotted measurements. The movement of the chin (sPg) compared to the dental displacement using an index was slightly higher, but the mean values overall differed by less than 0.5 mm. This overestimation could be explained by the vertical movement of the chin area caused by cuspid guidance when deviating the mandible to the left. Earlier studies of the Vectra XT, a full-body image system from Vectra, concluded that the reliability of the image system was 0.15 mm (SD: 0.15 mm), with a 95th percentile of 0.45 mm.<sup>6</sup>

Previous studies have evaluated the reproducibility of the 3dMDface<sup>™</sup> image system (3dMD, Atlanta, GA, USA), a similar imaging system, which also consists of 6 cameras with 190° full-face, "ear-to-ear" coverage. Hong et al.<sup>16</sup> performed a study on a mannequin, while Nord et al.<sup>26</sup> analyzed human subjects. They concluded that the 3dMD system had a high level of technical precision with overall good reproducibility, but in human subjects, some landmarks were harder to reproduce with the same precision. For example, the sPg showed a moderate reproducibility.<sup>26</sup> In the present study, the problem with reproducibility was solved by marking the sPg point with eyeliner on the sub-

jects before image acquisition, as de Menezes et al.<sup>27</sup> also suggested. In the present study, the auto-tracking and color-mapping system produced reliable results and could be used as a method for objectively calculating differences in soft tissue changes after orthodontic or orthognathic treatment in regard to chin asymmetry. Hence, the use of eyeliner in future studies might not be necessary.

A previous study suggested that it is considered normal to have a total face asymmetry of 2 to 5 mm, but the chin was not evaluated separately in that study.<sup>10</sup> Severt et al.<sup>11</sup> concluded that the lower third of the face was by far the most common area of asymmetry, as 74% of subjects had an observable deviation of the chin (more than 2 mm); however, the population in that study were consecutively registered when seeking orthognathic surgery consultations and might not be considered representative of the general population.

Researchers have also explored the question of how much midline deviation is necessary to give rise to facial asymmetry.<sup>28</sup> Five millimeters or less was considered not noticeable, according to Choi,<sup>29</sup> but it is worth mentioning that those studies used 2-dimensional images and Photoshop to generate chin deviations.<sup>29,30</sup> When the mandible shifts in reality, it is reasonable to believe that it has more extensive effects than can be simulated with an adjusted 2-dimensional picture; in particular, there are expected to be alterations in other areas of the face beyond just the chin. In the present study, the authors were able to notice chin deviation visible to the eye even with 3 mm of midline deviation in most subjects.

The results of the soft tissue changes upon deviation of the dental midline have provided insights into the individual differences by the masking or magnification of such devia-

tions (Fig. 8). One subject only had a just above 2-mm detectable asymmetry with a 4-mm dental midline deviation, while some others had a detectable asymmetry of about 6 mm with the same dental midline deviation. In the entire study group, the mean value of sPg movement was only slightly higher than that of the actual dental movement. As mentioned earlier, this study was conducted on patients without a true mandibular shift, and some of the effect was likely due to the cuspid guidance, which probably would not exist in a patient with a posterior crossbite due to dental adaptation over time.

Unlike traditional 2-dimensional images, which are taken by 1 camera in a single view, the Vectra® M3 imaging system consists of 6 cameras that simultaneously capture the face from different angles to render a 3D image that offers new possibilities for planning and evaluating treatments. As new techniques develop, the validation of present techniques and systems is essential. In orthodontics, especially, clinicians do not only treat the dentition, but also consider the effects of treatment on the extraoral soft tissue. Therefore, this instrument could be used, for instance, to evaluate treatment effects when correcting mandibular shift, such as that seen in children with posterior unilateral crossbite. This study concluded that the Vectra® M3 has excellent intra- and inter-examiner reliability and the auto-tracking mode of the software can be considered reliable for detecting small chin deviations. The soft tissue effect when constructing dental midline deviations gave a small over-estimation of soft tissue movement compared to the index, but with a mean value less than 0.5 mm.

**Conflicts of Interest:** None

## References

1. Heike CL, Upson K, Stuhaug E, Weinberg SM. 3D digital stereophotogrammetry: a practical guide to facial image acquisition. *Head Face Med* 2010; 6: 18.
2. Capitán L, Simon D, Capitán-Cañadas F. Facial feminization surgery and facial gender confirmation surgery. In: Ferrando C. *Comprehensive care of the transgender patient*. Philadelphia: Elsevier; 2020. p. 54-72.
3. Farkas LG. Accuracy of anthropometric measurements: past, present, and future. *Cleft Palate Craniofac J* 1996; 33: 10-8.
4. Brons S, Meulstee JW, Loonen TG, Nada RM, Kuijpers MA, Bronkhorst EM, et al. Three-dimensional facial development of children with unilateral cleft lip and palate during the first year of life in comparison with normative average faces. *PeerJ* 2019; 7: e7302.
5. Gibelli D, Pucciarelli V, Cappella A, Dolci C, Sforza C. Are portable stereophotogrammetric devices reliable in facial imaging? A validation study of Vectra H1 device. *J Oral Maxillofac Surg* 2018; 76: 1772-84.
6. Verhulst A, Hol M, Vreeken R, Becking A, Ulrich D, Maal T. Three-dimensional imaging of the face: a comparison between three different imaging modalities. *Aesthet Surg J* 2018; 38: 579-85.
7. Hajeer MY, Ayoub AF, Millett DT. Three-dimensional assessment of facial soft-tissue asymmetry before and after orthognathic surgery. *Br J Oral Maxillofac Surg* 2004; 42: 396-404.
8. Silva AM, Magri LV, Osborne PR, Trivelatto AE, Svezut CE, Silva MA. Three-dimensional nasal alterations in Le Fort I advancement: linear measurements, angles, nasal indices, and volume differences. *J Craniofac Surg* 2019; 30: 1125-30.
9. van Loon B, van Heerbeek N, Bierenbroodspot F, Verhamme L, Xi T, de Koning MJ, et al. Three-dimensional changes in nose and upper lip volume after orthognathic surgery. *Int J Oral Maxillofac Surg* 2015; 44: 83-9.
10. Lum V, Goonewardene MS, Mian A, Eastwood P. Three-dimensional assessment of facial asymmetry using dense correspondence, symmetry, and midline analysis. *Am J Orthod Dentofacial Orthop* 2020; 158: 134-46.
11. Severt TR, Proffit WR. The prevalence of facial asymmetry in the dentofacial deformities population at the University of North Carolina. *Int J Adult Orthodon Orthognath Surg* 1997; 12: 171-6.
12. Meyer-Marcotty P, Stellzig-Eisenhauer A, Bareis U, Hartmann J, Kochel J. Three-dimensional perception of facial asymmetry. *Eur J Orthod* 2011; 33: 647-53.
13. Wang TT, Wessels L, Hussain G, Merten S. Discriminative thresholds in facial asymmetry: a review of the literature. *Aesthet Surg J* 2017; 37: 375-85.
14. Langberg BJ, Arai K, Miner RM. Transverse skeletal and dental asymmetry in adults with unilateral lingual posterior crossbite. *Am J Orthod Dentofacial Orthop* 2005; 127: 6-16.
15. Choi HW, Kim B, Kim JY, Huh JK, Park KH. Three-dimensional computed tomography evaluation of craniofacial characteristics according to lateral deviation of chin. *Maxillofac Plast Reconstr Surg* 2019; 41: 57.
16. Hong C, Choi K, Kachroo Y, Kwon T, Nguyen A, McComb R, et al. Evaluation of the 3dMDface system as a tool for soft tissue analysis. *Orthod Craniofac Res* 2017; 20 Suppl 1: 119-24.
17. Naini FB, Akram S, Kepinska J, Garagiola U, McDonald F, Wertheim D. Validation of a new three-dimensional imaging system using comparative craniofacial anthropometry. *Maxillofac Plast Reconstr Surg* 2017; 39: 23.
18. Knoops PG, Beaumont CA, Borghi A, Rodriguez-Florez N, Breakey RW, Rodgers W, et al. Comparison of three-dimensional scanner systems for craniomaxillofacial imaging. *J Plast Reconstr Aesthet Surg* 2017; 70: 441-9.
19. Guo Y, Schaub F, Mor JM, Jia R, Koch KR, Heindl LM. A simple standardized three-dimensional anthropometry for the periocular region in a European population. *Plast Reconstr Surg* 2020; 145: 514e-23e.
20. Hyer JN, Murta F, Juniat VA, Ezra DG. Validating three-dimensional imaging for volumetric assessment of periorbital soft tissue. *Orbit* 2021; 40: 9-17.
21. Mattox AR, Behshad R, Sepe DJ, Armbrecht ES, Maher IA. Three-dimensional modeling and comparison of nasal flap designs. *Arch Dermatol Res* 2020; 312: 575-9.



22. Liu J, Guo Y, Arakelyan M, Rokohl AC, Heindl LM. Accuracy of areal measurement in the periocular region using stereophotogrammetry. *J Oral Maxillofac Surg* 2021; 79: 1106.e1-9.
23. Ozsoy U, Demirel BM, Yildirim FB, Tosun O, Sarikcioglu L. Method selection in craniofacial measurements: advantages and disadvantages of 3D digitization method. *J Craniomaxillofac Surg* 2009; 37: 285-90.
24. Andrade LM, Rodrigues da Silva AM, Magri LV, Rodrigues da Silva MA. Repeatability study of angular and linear measurements on facial morphology analysis by means of stereophotogrammetry. *J Craniofac Surg* 2017; 28: 1107-11.
25. Baksi S, Freezer S, Matsumoto T, Dreyer C. Accuracy of an automated method of 3D soft tissue landmark detection. *Eur J Orthod* (in press).
26. Nord F, Ferjencik R, Seifert B, Lanzer M, Gander T, Matthews F, et al. The 3dMD photogrammetric photo system in cranio-maxillofacial surgery: validation of interexaminer variations and perceptions. *J Craniomaxillofac Surg* 2015; 43: 1798-803.
27. de Menezes M, Rosati R, Ferrario VF, Sforza C. Accuracy and reproducibility of a 3-dimensional stereophotogrammetric imaging system. *J Oral Maxillofac Surg* 2010; 68: 2129-35.
28. Thiesen G, Kim KB. Criteria for determining facial asymmetries. *Am J Orthod Dentofacial Orthop* 2016; 150: 910.
29. Choi KY. Analysis of facial asymmetry. *Arch Craniofac Surg* 2015; 16: 1-10.
30. Silva BP, Jiménez-Castellanos E, Martínez-de-Fuentes R, Greenberg JR, Chu S. Laypersons' perception of facial and dental asymmetries. *Int J Periodontics Restorative Dent* 2013; 33: e162-71.