

Bilateral Cytomegalovirus Retinitis in a Patient with Systemic Lupus Erythematosus

Masaya Haze^a Takatoshi Kobayashi^a Keigo Kakurai^a Hiromi Shoda^a
Nanae Takai^a Sayako Takeda^{a, b} Rei Tada^{a, c} Kouichi Maruyama^{a, d}
Teruyo Kida^a Tsunehiko Ikeda^a

^aDepartment of Ophthalmology, Osaka Medical College, Takasuki City, Japan; ^bTakeda Eye Clinic, Osaka City, Japan; ^cTada Eye Clinic, Ikeda City, Japan; ^dMaruyama Eye Clinic, Takatsuki City, Japan

Keywords

Systemic lupus erythematosus · Cytomegalovirus retinitis · Retinal detachment · Vitrectomy

Abstract

Purpose: The purpose of this study was to report the case of a patient who underwent vitrectomy for bilateral rhegmatogenous retinal detachment caused by cytomegalovirus (CMV) retinitis while undergoing steroid and immunosuppressant therapy for systemic lupus erythematosus (SLE). **Case Report:** We report on a 29-year-old female who was undergoing steroids and immunosuppressants treatment for SLE at Osaka Medical College Hospital, Takatsuki City, Japan. Examination of the patient due to prolonged and worsening diarrhea revealed positive test results for C7-HRP, and she was diagnosed with CMV colitis. She was subsequently admitted to the hospital and started on intravenous ganciclovir for treatment. Approximately 1.5 months later, her primary complaint was deterioration of the upper visual field in her left eye, and she was then referred to the Department of Ophthalmology. Numerous granular exudative spots were found around the lower retinal area of her left eye with retinal breaks that had developed in an area of retinal necrosis that resulted in retinal detachment. After time was allowed for the patient's general condition to improve, a vitrectomy was performed on that eye. The patient subsequently developed a similar retinal detachment in her right eye, for which she underwent a vitrectomy. Although the patient required multiple surgeries on both eyes, her retinas currently remain reattached and the inflammation has

subsided. **Conclusion:** The findings of this study show that strict attention must be paid to SLE patients on immunosuppressive therapy due to the possible association of CMV retinitis.

© 2016 The Author(s)
Published by S. Karger AG, Basel

Introduction

Cytomegalovirus (CMV) is a DNA virus of the *Herpesviridae* family that commonly affects individuals during childhood [1]. In fact, 50–85% of adults in the United States have CMV antibodies, and the virus is said to latently infect mononuclear cells in bone marrow and peripheral blood. Generally, CMV infections are opportunistic infections that commonly develop in immunocompromised patients, such as patients with acquired immunodeficiency syndrome (AIDS), malignant tumors, and those that have recently undergone organ transplantation [2, 3]. In recent years, however, there have been scattered reports of CMV infections appearing in patients with both connective tissue and blood diseases [4–8]. In this study, we report the case of a patient who underwent vitrectomy for bilateral rhegmatogenous retinal detachment caused by CMV retinitis while undergoing steroid and immunosuppressant therapy for systemic lupus erythematosus (SLE).

Case Report

We report the case of a 29-year-old female patient who presented with deterioration of the upper visual field in the left eye.

The patient was diagnosed with SLE at the age of 22 years and was undergoing oral administration of immunosuppressants such as dexamethasone, tacrolimus, and mycophenolate mofetil for treatment. Family history included rheumatoid arthritis in the patient's grandmother.

History of Present Condition

Due to prolonged and worsening diarrhea, the patient was admitted to the Department of Internal Medicine and Connective Tissue Disorders at Osaka Medical College Hospital, Takatsuki City, Japan, in mid-July 2010 to undergo further tests. A blood sample obtained from the patient tested positive on a CMV pp65 antigen test (hereafter referred to as 'C7-HRP'), and she was diagnosed with CMV colitis. Subsequently, the patient was administered intravenous ganciclovir in parallel with the immunosuppressant and steroid treatment for SLE. The patient's C7-HRP eventually tested negative and the intravenous ganciclovir was temporarily stopped; however, she later occasionally tested positive for C7-HRP and was administered intravenous ganciclovir each time for treatment. While still hospitalized in late August 2010, the patient suddenly became aware of a deterioration of the upper visual field in her left eye and was sent to the Department of Ophthalmology for examination.

Findings on Initial Examination

Upon initial examination, the patient's visual acuity (VA) was 0.05 ($1.2 \times S-5.0D = C-2.75DA \times 5^\circ$) OD and 0.04 ($1.2 \times S-5.5D = C-1.75DA \times 180^\circ$) OS. Intraocular pressure was 13 mm Hg in both eyes. Mild iritis in the anterior segment was observed in her left eye. Rhegmatogenous retinal detachment was found in the lower second quadrant of her left eye with obstructions of the blood vessels in the lower area of that eye, thus resulting in retinal thin-

ning and necrosis (fig. 1b). Yellowish-white granular exudate was also found in the retina around an area of necrosis. Yellowish-white granular exudate was also found in the retinal area of the right eye, yet with no retinal detachment (fig. 1a). The patient was diagnosed with bilateral CMV retinitis based on the observations of her overall condition and ocular fundus findings.

Clinical Course

Although the retinal detachment in the patient's left eye was encroaching on the macular area, internal medical treatment took priority, and we planned to perform a vitrectomy after the patient's overall condition had improved. Pars plana lensectomy and pars plana vitrectomy were performed on the patient's left eye on September 14, 2010, as the retinal detachment had already reached the macular area. The posterior vitreous had not yet detached and the vitreoretinal adhesion in the lower CMV retinitis area was robust. We therefore created an artificial posterior vitreous detachment using bimanual techniques (fig. 2). Pneumatic retinal reattachment surgery, intraocular laser photocoagulation, a peripheral encircling procedure, and a silicone oil tamponade were later performed to complete the operation. Polymerase chain reaction (PCR) testing of the vitreous fluid obtained during surgery revealed CMV DNA.

In July 2011, the patient experienced rhegmatogenous retinal detachment in her right eye, and as with that for the left eye, pars plana lensectomy and pars plana vitrectomy, along with a silicone oil tamponade, were performed for treatment. A macular pucker formed in the patient's left eye, and in September 2011, she underwent silicone oil removal and secondary insertion of an intraocular lens (IOL), removing the macular pucker at the same time. However, the retinal detachment reoccurred after surgery, and in October 2011, the IOL was removed and silicone oil was once again injected. Silicone oil removal and secondary insertion of an IOL were performed on the patient's right eye in January 2012, and her postoperative progress has been favorable. As of March 2015, the patient's corrected VA was 0.8 OD and 0.15 OS.

Discussion

CMV retinitis commonly manifests in patients who are in an immunocompromised state, such as patients with AIDS, malignant tumors, or those who have recently undergone organ transplantation [1–3]. However, there have been scattered reports in recent years of CMV retinitis developing in patients suffering from connective tissue diseases, such as SLE and chronic rheumatoid arthritis, while on immunosuppressive therapy [4–8]. Compromised immunity arises from pancytopenia stemming from SLE itself along with the side effects of steroid and immunosuppressant therapy, often accompanied by infectious diseases. There have been numerous reports of CMV infections such as pneumonia and nephritis associated with SLE [9, 10]. Although reports of retinitis have been few in comparison, it has been on the rise in recent years. There have been numerous past reports of CMV retinitis associated with SLE due to treatment with multiple steroids and immunosuppressants, such as in the present case [5–8]. Although there are reports from other institutions investigating CMV infections occurring in patients with connective tissue disorders including, most notably, SLE [4], there have been no extensive reports on cases of patients exhibiting CMV retinitis. Thus, we await the findings of future research on this topic.

In many cases, CMV retinitis can be diagnosed from characteristic observations in the ocular fundus. It can be categorized as fulminant, in which case it develops in the posterior fundus and is often accompanied by retinal bleeding, or granular, in which case the retinitis develops in surrounding regions and often progresses slowly. In the case shown in this present study, there was a high likelihood that progression of the infection was steady, as the granular surrounding area of the lesion was the primary agent, and although retinal detachment occurred in the course of the infection, the patient was not examined by an ophthalmologist until she became aware of the loss in her field of vision, thus leading to the delayed diagnosis.

Dry eye, scleritis, and retinopathy are known to be among the ocular complications associated with SLE [11, 12]. Retinopathy is characterized by soft exudate and bleeding and may be associated with obstruction of the retinal blood vessels. If vasculitis progresses, it may be accompanied by proliferative retinopathy or neovascular glaucoma. CMV retinitis is generally characterized by granular exudate and bleeding along the blood vessels, however, and in the initial stages, it can be difficult to distinguish from SLE retinitis. PCR testing using aqueous humor from the anterior chamber is a simple and effective method for diagnosing CMV retinitis.

If CMV retinitis is discovered, the patient should be started on systemic administration of antiviral drugs. Even after the retinitis subsides, necrosis may develop in the outer layer of the retina, commonly leading to thinning of the retina. It has also been reported that the adhesion between the retina and vitreous body strengthens after the inflammation subsides [13], which necessitates a vitrectomy if it progresses into rhegmatogenous retinal detachment accompanied by the advance of posterior vitreous detachment. In the case presented in this study, the creation of an artificial posterior vitreous detachment on the site of the lesion was a challenge. As the retinal detachment in the left eye was delayed in this case, the patient's corrected vision remains at 0.15. However, we were able to operate on the retinal detachment in the patient's right eye which developed during the course of the infection at an early stage, thus allowing us to be able to maintain a relatively favorable VA of 0.8. In terms of the prognosis for retinal detachment with CMV retinitis, the recovery rate is approximately 80%; i.e., a very positive prognosis [14]. Had the patient undergone an eye test at the time she was diagnosed with CMV colitis, the chances are high that the CMV retinitis would have been discovered at an earlier stage.

SLE patients who undergo long-term treatment with steroids and immunosuppressants, such as in the present case, should be observed with great care over the course of the illness, and there should be an awareness that such patients are at high risk for opportunistic CMV infections.

Acknowledgements

The authors wish to thank John Bush for editing the manuscript.

Statement of Ethics

This case study has been approved by the Ethics Committee of the Osaka Medical College.

Disclosure Statement

The authors have no conflicts of interest to report.

References

- 1 Wiegand TW, Young LH: Cytomegalovirus retinitis. *Int Ophthalmol Clin* 2006;46:91–110.
- 2 Jeon S, Lee WK, Lee Y, Lee DG, Lee JW: Risk factors for cytomegalovirus retinitis in patients with cytomegalovirus viremia after hematopoietic stem cell transplantation. *Ophthalmology* 2012;119:1892–1898.
- 3 Bhat V, Joshi A, Sarode R, Chavan P: Cytomegalovirus infection in the bone marrow transplant patient. *World J Transplant* 2015;5:287–291.
- 4 Takizawa Y, Inokuma S, Tanaka Y, Saito K, Atsumi T, Hirakata M, Kameda H, Hirohata S, Kondo H, Kumagai S, Tanaka Y: Clinical characteristics of cytomegalovirus infection in rheumatic diseases: multicentre survey in a large patient population. *Rheumatology* 2008;47:1373–1378.
- 5 Kelkar A, Kelkar J, Kelkar S, Bhirud S, Biswas J: Cytomegalovirus retinitis in a seronegative patient with systemic lupus erythematosus on immunosuppressive therapy. *J Ophthalmic Inflamm Infect* 2011;1:129–132.
- 6 Lee JJ, Teoh SC, Chua JL, Tien MC, Lim TH: Occurrence and reactivation of cytomegalovirus retinitis in systemic lupus erythematosus with normal CD4(+) counts. *Eye* 2006;20:618–621.
- 7 Shahnaz S, Choksi MT, Tan IJ: Bilateral cytomegalovirus retinitis in a patient with systemic lupus erythematosus and end-stage renal disease. *Mayo Clin Proc* 2003;78:1412–1415.
- 8 Schlingemann RO, Wertheim-van Dillen P, Kijlstra A, Bos PJ, Meenken C, Feron EJ: Bilateral cytomegalovirus retinitis in a patient with systemic lupus erythematosus. *Br J Ophthalmol* 1996;80:1109–1110.
- 9 Gutsche M, Rosen GD, Swigris JJ: Connective tissue disease-associated interstitial lung disease: a review. *Curr Respir Care Rep* 2012;1:224–232.
- 10 Koutsokeras T, Healy T: Systemic lupus erythematosus and lupus nephritis. *Nat Rev Drug Discov* 2014;13:173–174.
- 11 Davies JB, Rao PK: Ocular manifestations of systemic lupus erythematosus. *Curr Opin Ophthalmol* 2008;19:512–518.
- 12 Giorgi D, Pace F, Giorgi A, Bonomo L, Gabrieli CB: Retinopathy in systemic lupus erythematosus: pathogenesis and approach to therapy. *Hum Immunol* 1999;60:688–696.
- 13 Brar M, Kozak I, Freeman WR, Oster SF, Mojana F, Yuson RM: Vitreoretinal interface abnormalities in healed cytomegalovirus retinitis. *Retina* 2010;30:1262–1266.
- 14 Mathur G, Ratra D, Bhuibhar SS, Roy R: Clinical outcomes of retinal detachment surgery following cytomegalovirus retinitis in patients on highly active anti-retroviral therapy for acquired immune deficiency syndrome. *Ocul Immunol Inflamm* 2015;23:400–404.

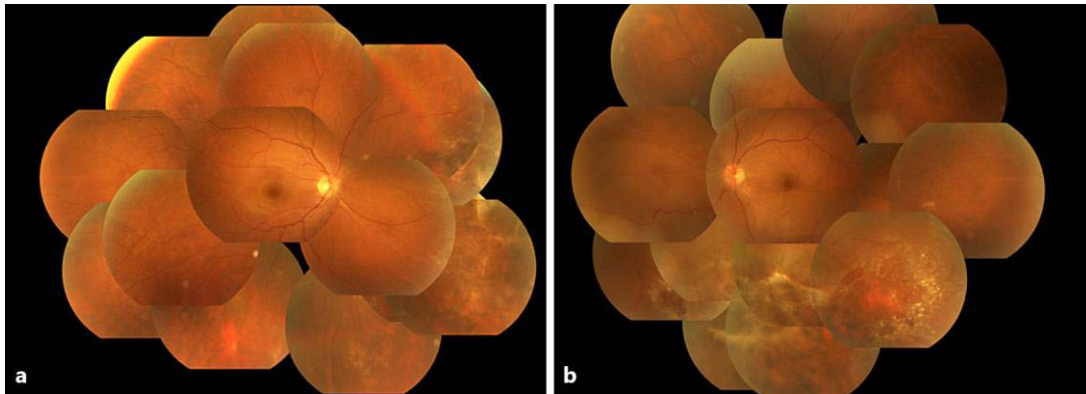


Fig. 1. Preoperative fundus photographs obtained on initial examination. **a** Right eye. **b** Left eye. **a** Yellowish-white granular exudate was found in the retinal area of the right eye, even though no retinal detachment had occurred. **b** Image showing the occurrence of rhegmatogenous retinal detachment in the lower second quadrant of the patient's left eye, with obstruction of the blood vessels in the lower area of that eye, thus resulting in retinal thinning and necrosis.

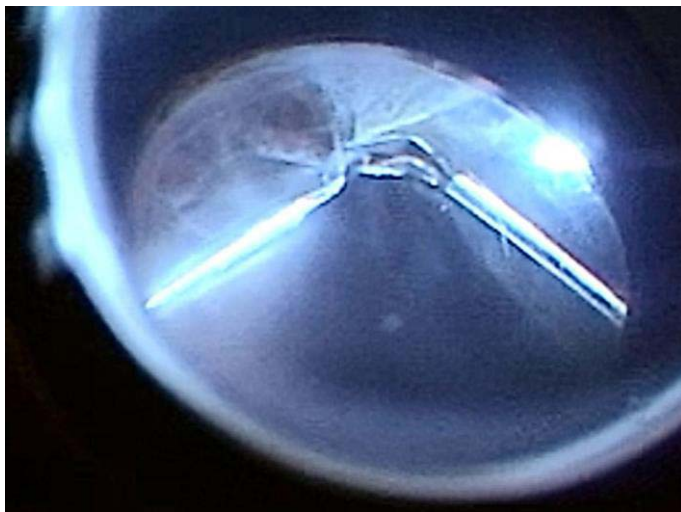


Fig. 2. Intraoperative findings in the patient's left eye. The vitreoretinal adhesion in the lower cytomegalovirus retinitis area was robust. Hence, an artificial posterior vitreous detachment was created with the use of a bimanual technique.