

## A child with soft-tissue infection and lymphadenitis

N. J. Froböse<sup>1</sup>, K. Masjosthusmann<sup>2</sup>, S. Huss<sup>3</sup>,  
C. L. Correa-Martinez<sup>4</sup>, A. Mellmann<sup>4</sup>, F. Schuler<sup>1</sup>, B. C. Kahl<sup>1</sup>,  
H. Wittkowski<sup>5</sup> and F. Schaumburg<sup>1</sup>

1) Institute of Medical Microbiology, University Hospital Münster, 2) General Paediatrics, University Children's Hospital Münster, 3) Gerhard-Domagk-Institute of Pathology, 4) Institute for Hygiene, University Hospital Münster and 5) Department of Paediatric Rheumatology and Immunology, University Children's Hospital Münster, Münster, Germany

### Abstract

We report a case of a soft-tissue infection with *Francisella philomiragia*, a rare opportunistic pathogen in individuals with chronic granulomatous disease.

© 2020 The Author(s). Published by Elsevier Ltd.

**Keywords:** Chronic granulomatous disease, *Francisella philomiragia*, genetic relation, lymphadenitis, soft-tissue infections

**Original Submission:** 28 October 2020; **Revised Submission:** 11 November 2020; **Accepted:** 11 November 2020

**Article published online:** 18 November 2020

**Corresponding author:** N.J. Froböse, Institute of Medical Microbiology, University Hospital Münster, Domagkstrasse 10, 48149 Münster, Germany.

**E-mail:** [Neelejudith.Froboese@ukmuenster.de](mailto:Neelejudith.Froboese@ukmuenster.de)

### Case report

A 12-year-old boy with chronic granulomatous disease (genetic defect in CYBB exon) was admitted to our infectious disease unit with high fever >39°C and dry cough, but in stable condition (infection prophylaxis: trimethoprim/sulfamethoxazole (160 mg once a day by mouth) and posaconazole (alternating 300 or 200 mg once a day by mouth); antimicrobial treatment: amoxicillin/clavulanic acid (875/125 mg twice a day by mouth)).

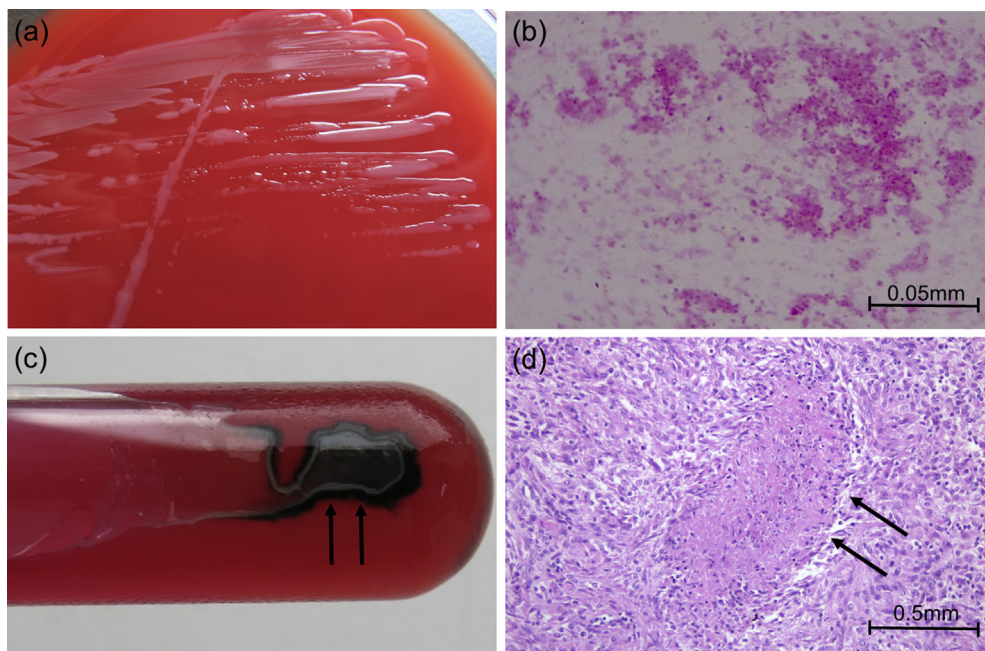
He had a history of axillar skin lesions caused by abrasions received while surfing during vacation. One week later, he was admitted to the University Children's Hospital (normal care) because of an abscessing lymphadenitis in the right axillar, which was incised. A swab was sent for microbiological analysis (no growth on Columbia blood and chocolate blood agars after enrichment in thioglycollate broth, all BD, Heidelberg, Germany). He was empirically treated with piperacillin/tazobactam (3.6 g three times daily intravenously) for 9 days, followed by amoxicillin/clavulanic acid (875/125 mg twice a day by mouth, ongoing at current admission), and was discharged 3 days before the current admission.

On physical examination, an enlarged pressure-sensitive lymph node was palpable in the right axilla. C-reactive protein was elevated (2.8 mg/dL (normal <0.5 mg/dL)).

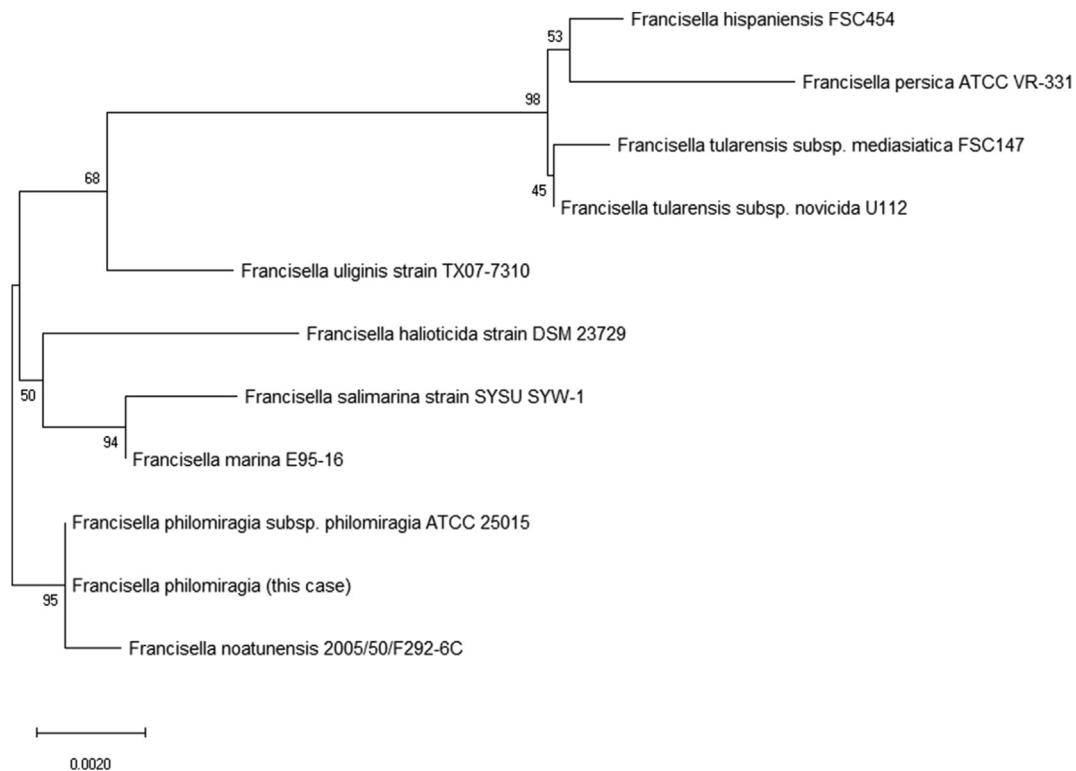
Chest CT scan revealed multiple consolidated round lesions in both lungs and an enlarged lymph node in the right axilla.

A CT-guided biopsy of the pulmonary round lesions and bronchoalveolar lavage were performed and the enlarged axillar lymph node was surgically removed for microbiological and histopathological analysis. Therapy with meropenem (720 mg three times a day intravenously), clindamycin (300 mg three times a day intravenously), trimethoprim/sulfamethoxazole (160 mg twice a day by mouth) and voriconazole (200 mg twice a day intravenously) was started.

For microbiological investigation, the lymph node was homogenized and plated on (a) Columbia blood agar, (b) chocolate blood agar, (c) Sabouraud–glucose agar and (d) Schaedler KV selective agar (Thermofisher, Oxoid, Hennigsdorf, Germany). After 48 h of incubation at 35°C, no bacterial growth was detected. After incubation in thioglycollate broth (35°C for 48 h), 10 µL of thioglycollate broth enrichment culture was streaked on chocolate blood agar and incubated at 35°C. Punctiform to circular, greyish, translucent colonies of Gram-negative coccobacillary bacteria grew after 24 h under aerobic conditions (Fig. 1a,b) and produced hydrogen sulphide in triple sugar iron agar (Fig. 1c). Species identification (using matrix-assisted laser desorption/ionization time-of-flight mass spectrometry; Bruker Daltonics, Bremen, Germany) revealed *Francisella philomiragia* (identification score: 2.02), which was confirmed by 16S RNA gene sequence comparison (100% coverage, 100% identity with *Francisella philomiragia* subsp. *philomiragia* ATCC 25015, GenBank accession no. NR\_114925). The 16S rRNA sequence from our isolates is available at NCBI (NBioProject number PRJNA668170). The most closely related species of *F. philomiragia* were identified using BLASTN and the corresponding 16S RNA gene sequences were used to construct a neighbour-joining tree (Fig. 2). The



**FIG. 1.** Microbiological and histopathological aspects of *Francisella philomiragia*. (a) Greyish, translucent colonies of *F. philomiragia* on Columbia blood agar; (b) Gram-stain showing uneven Gram-negative coccobacilli; (c) hydrogen sulphide production (arrows) on triple sugar iron agar; (d) haematoxylin & eosin stain of axillar lymph node tissue showing granuloma with focal necrosis (arrows).



**FIG. 2.** Neighbour-joining tree of *Francisella philomiragia* and closely related species based on 16S RNA gene sequences. The bootstrap values (500 replicates) are shown next to the branches. There were 980 positions in the final data set. Evolutionary analyses were conducted in MEGA [16].

closest species of *F. philomiragia* is *Francisella noatunensis* based on the 16S RNA gene sequencing (Fig. 2).

Respiratory specimens (biopsy, bronchoalveolar lavage) and a blood culture (BD Bactec Peds Plus Culture Vials; BD) remained negative.

Analyses using PCR to detect fungi (ITS1/ITS2 region), *Bartonella henselae*, *Mycobacterium* sp., *Leishmania* sp. and *Toxoplasma gondii* were negative from both the lymph node and lung biopsy.

A serum sample was IgG positive (ELISA, cut-off value >0.25 absorbance units; Seramun Diagnostica GmbH, Heidesee, Germany) for *Francisella tularensis* but the serum sample did not react with Western blot.

Histopathology revealed confluent and necrotizing granuloma in the lung biopsy and confluent epithelioid cell granuloma with focal necrosis in lymph node tissue (Fig. 1d).

Antimicrobial susceptibility testing was done with Etests (bioMérieux, Marcy l'Étoile, France) and MICs were interpreted according to EUCAST pharmacokinetic/pharmacodynamic clinical breakpoints [1] and CLSI MIC breakpoints for other non-*Enterobacterales* [2]. The isolate was resistant to trimethoprim/sulfamethoxazole (MIC 12 mg/L) and susceptible to meropenem (MIC 0.094 mg/L) and ciprofloxacin (MIC 0.012 mg/L).

Antibiotic therapy was de-escalated to meropenem (1 g three times a day intravenously) and ciprofloxacin (500 mg three times a day by mouth) and switched to ciprofloxacin monotherapy (500 mg three times a day by mouth) after 14 days.

A follow-up chest X-ray showed persisting round lesions but no evidence for progression or new formation of granuloma. The patient was discharged after 18 days in good clinical condition.

## Discussion

*Francisella philomiragia* is a halophilic Gram-negative coccobacillus. It is considered an opportunistic pathogen, causing pneumonia and lymphadenitis, meningitis, peritonitis and sepsis in immunosuppressed individuals, especially those with compromised neutrophil function [3–5].

Known risk factors for *F. philomiragia* infection are chronic granulomatous disease, near-drowning accidents in saltwater and haematological malignancies [3,6–9].

The natural habitat of *F. philomiragia* is brackish water or saltwater [10,11]. It has been detected in wild and farmed fish [10,11] and was able to infect aquatic amoebae in a co-culture experiment [12]. Most published cases of human infection (18 of 21) report previous direct contact with saltwater (8 of 21) or sojourn within 50 miles of coastline (10 of 21) [3,5,7–9]. Our patient was surfing in the Danish North Sea 1 week before the start of symptoms. He reported minor abrasion injuries in the

right axillar region from the surfing equipment. A cutaneous inoculation of *F. philomiragia* in our case is therefore the most likely route of infection.

The phylogenetically closest related species of *F. philomiragia* is *F. noatunensis*, which is known to cause disease in fish raised in fresh water or aquaculture [13].

*Francisella philomiragia* (oxidase- and catalase-positive) can be distinguished from *F. tularensis* (oxidase-negative and weakly catalase-positive) by applying standard microbiological analyses.

Detection of anti-*F. tularensis* IgG is suggestive for a cross-reactivity between *F. tularensis* and *F. philomiragia*, which is also supported by the non-detection of specific antibodies in the Western blot. This cross-reactivity and a delayed oxidase reaction of *F. philomiragia* may result in its wrong identification as *F. tularensis*.

Specimens from lung biopsy remained diagnostically negative. The persistence of granuloma after antimicrobial therapy combined with the histopathological results may suggest that the lung granuloma originated from chronic granulomatous disease [14].

Antimicrobial susceptibility testing of *F. philomiragia* is not standardized, but ciprofloxacin seems to be effective [3,8] and was also successfully combined with meropenem in our case. Production of  $\beta$ -lactamases and treatment failure of third-generation cephalosporins, despite antimicrobial susceptibility *in vitro*, have been reported [15].

In conclusion, *F. philomiragia* should be considered in immunocompromised patients if there is a history of saltwater or brackish water exposure.

## Authors contribution

The study was conceived by NJF and FSchaumburg, methodology was by NJF, SH, AM and FSchaumburg, and formal analysis was by NJF, CC-M and FSchaumburg. NJF, FSchuler and FSchaumburg wrote the original draft, which was reviewed and edited by KM, HW, AM and BCK. Visualization was by NJF, Frieder Schaumburg and SH, and FSchaumburg supervised the study.

## Conflicts of interest

Authors declare that there is no conflict of interest.

## References

- [1] European committee on antimicrobial susceptibility testing breakpoints tables for interpretation of MICs and zone diameters. 2020-01-01. Vol. 10.0. Växjö: EUCAST; 2020. p. 107–10.

- [2] [Internet] M100—Performance standards for antimicrobial susceptibility testing. Clinical and Laboratory Standards Institute; 2020. <https://www.clsi.org/standards/products/microbiology/documents/m100/>.
- [3] Mailman T, Schmidt MH. *Francisella philomiragia* adenitis and pulmonary nodules in a child with chronic granulomatous disease. *Can J Infect Dis Med Microbiol* 2005;16.
- [4] Hollis D, Weaver R, Steigerwalt A, Wenger J, Moss C, Brenner D. *Francisella philomiragia* comb. nov.(formerly *Yersinia philomiragia*) and *Francisella tularensis* biogroup *novicida* (formerly *Francisella novicida*) associated with human disease. *J Clin Microbiol* 1989;27:1601–8.
- [5] Wenger JD, Hollis DG, Weaver RE, Baker CN, Brown GR, Brenner DJ, et al. Infection caused by *Francisella philomiragia* (formerly *Yersinia philomiragia*) a newly recognized human pathogen. *Ann Intern Med* 1989;110:888–92.
- [6] Sicherer SH, Asturias EJ, Winkelstein JA, Dick JD, Willoughby RE. *Francisella philomiragia* sepsis in chronic granulomatous disease. *Pediatr Infect Dis J* 1997;16:420–2.
- [7] Polack FP, Harrington SM, Winkelstein JA, Merz WG, Willoughby RE. Recurrent *Francisella philomiragia* sepsis in chronic granulomatous disease. *Pediatr Infect Dis J* 1998;17:442–3.
- [8] Robles-Marhuenda A, Vaca M, Romero P, Ferreira A, López-Granados E, Arnalich F. *Francisella philomiragia*: think of chronic granulomatous disease. *J Clin Immunol* 2018;38:257–9.
- [9] Kreitmann L, Terriou L, Launay D, Caspar Y, Courcol R, Maurin M, et al. Disseminated infection caused by *Francisella philomiragia*, France, 2014. *Emerg Infect Dis* 2015;21:2260.
- [10] Relich RF, Humphries RM, Mattison HR, Miles JE, Simpson ER, Corbett IJ, et al. *Francisella philomiragia* bacteremia in a patient with acute respiratory insufficiency and acute-on-chronic kidney disease. *J Clin Microbiol* 2015;53:3947–50.
- [11] Propst CN, Pylypko SL, Blower RJ, Ahmad S, Mansoor M, van Hoek ML. *Francisella philomiragia* infection and lethality in mammalian tissue culture cell models, *Galleria mellonella*, and BALB/c mice. *Front Microbiol* 2016;7:696.
- [12] Verhoeven AB, Durham-Colleran MW, Pierson T, Boswell WT, Van Hoek ML. *Francisella philomiragia* biofilm formation and interaction with the aquatic protist *Acanthamoeba castellanii*. *Biol Bull* 2010;219:178–88.
- [13] Ramirez-Paredes JG, Larsson P, Thompson KD, Penman DJ, Busse H-J, Ohrman C, et al. Reclassification of *Francisella noatunensis* subsp. *orientalis* Ottem et al. 2009 as *Francisella orientalis* sp. nov., *Francisella noatunensis* subsp. *chilensis* subsp. nov. and emended description of *Francisella noatunensis*. *Int J Syst Evol Microbiol* 2020;70:2034–48.
- [14] Mortaz E, Azempour E, Mansouri D, Tabarsi P, Ghazi M, Koenderman L, et al. Common infections and target organs associated with chronic granulomatous disease in Iran. *Int Arch Allergy Immunol* 2019;179:62–73.
- [15] Friis-Møller A, Lemming L, Valerius NH, Bruun B. Problems in identification of *Francisella philomiragia* associated with fatal bacteremia in a patient with chronic granulomatous disease. *J Clin Microbiol* 2004;42:1840–2.
- [16] Kumar S, Stecher G, Li M, Knyaz C, Tamura K. MEGA X: molecular evolutionary genetics analysis across computing platforms. *Mol Biol Evol* 2018;35:1547–9.