



## Case report

# Split-thickness skin graft as a treatment for voluminous vaginal fluid discharge after surgery due to vesico-intestino-vaginal fistulation: A case report and review of the literature

E. Lydrup<sup>a,\*</sup>, C. Freccero<sup>b</sup>, ML. Lydrup<sup>c</sup>

<sup>a</sup> Department of Plastic Surgery and Breast Surgery, Zealand University Hospital, Sygehusvej 10, 4000 Roskilde, Denmark

<sup>b</sup> Department for the Clinical Sciences, Unit for Plastic and Reconstructive Surgery, Skåne University Hospital, S-205 02 Malmö, Sweden

<sup>c</sup> Department of Surgery, Colorectal Unit, Skåne University Hospital, S-205 02 Malmö, Sweden

## ARTICLE INFO

## Keywords

Vaginal rupture  
Vaginal cuff dehiscence  
Vaginal evisceration  
Vaginal discharge post radiation  
Vaginal fistulation

## 1. Introduction

Vaginal cuff dehiscence after hysterectomy is a rare but potentially morbid complication which can lead to vaginal evisceration with serious consequences, including peritonitis, necrosis, and sepsis. Treatment to replace the prolapsed structures and reconstruct the vaginal vault is required (Nezhat et al., 2018). In this report, we describe a rare case of vaginal dehiscence with vesico-intestino-vaginal fistulation, troublesome amount of fluid discharge and an unusual yet successful treatment.

## 2. Case

A 45-year old patient, II gravid II para, was diagnosed with cervical cancer FIGO IIIA in 2008. Treatment included cisplatinbased chemotherapy and 60 Gy external radiotherapy combined with brachytherapy. At follow-up three months after completed treatment, a residual tumor was detected and verified with biopsy. The patient accepted surgical treatment including radical hysterectomy and abdominoperineal rectal excision saving the urinary bladder which was performed in 2009. Histopathological examination showed radically removed tumor with smallest resection margin 6 mm, and the surgery was considered curative.

Three months after surgery, the patient suffered from urinary leakage, both with and without urinary catheter. Cystoscopy showed

explicit irritation, interpreted as a side effect of the radiotherapy. Two months later, repeated cystoscopy showed a vesico-vaginal fistula and another month later an intestino-vaginal fistula, indicating a complex vesico-intestino-vaginal fistulation. Extended surgery including cystectomy, resection of the small intestine involved in the intestino-vaginal fistula and construction of a urinary conduit was conducted. The vaginal cuff could not be closed due to extensive fibrosis. The omentum was too thin to fill out the cavity. A muscular vertical rectus abdominis myocutaneous flap (VRAM) without the fasciocutaneous component or a gracilis flap could have been options during this operation but were unfortunately not considered. Postoperatively the patient reported up to 1-liter fluid secretion from the vagina. Urinary leakage was excluded, and the fluid was interpreted as secretion from the radiation-affected pelvic cavity (shown in Fig. 1), including lymphatic secretion through the open vaginal cuff. Based on the hostile abdomen at the previous operation both surgeons and the patient were hesitant to an abdominal treatment with an omental flap and/or a myocutaneous flap. After thorough discussion and 2 years expectation, in close collaboration of colo-rectal and plastic-reconstructive surgeons, the decision was made to transplant a split-thickness skin graft (STSG) on the peritonealised small intestines above the disrupted vaginal cuff. To facilitate graft healing to the peritonealised small intestines, vacuum-assisted closure was placed inside the vaginal cavity and left for 4 days (Fig. 2). Graft take was good and the patient was successively mobilized.

\* Corresponding author at: Dept of Plastic Surgery and Breast Surgery, Zealand University Hospital, Sygehusvej 10, DK-4000 Roskilde, Denmark.  
E-mail address: [erikalydrup@hotmail.com](mailto:erikalydrup@hotmail.com) (E. Lydrup).

<https://doi.org/10.1016/j.gore.2021.100753>

Received 29 January 2021; Received in revised form 13 March 2021; Accepted 16 March 2021

Available online 22 March 2021

2352-5789/© 2021 The Author(s).

Published by Elsevier Inc.

This is an open access article under the CC BY-NC-ND license

(<http://creativecommons.org/licenses/by-nc-nd/4.0/>).

During the aftermath, when several antibiotic treatments and irrigations were applied, secretion diminished little by little. After one year, fluid per day was less than 50 ml. Due to shrinkage of the STSG, the enormously large vaginal cavity and the large recessi at both sides had diminished in size.

Due to peripheral radiation effects, the patient's introitus had transformed into a rigid ring that was painful in regards to sitting and hygiene, constantly open, and made sexual intercourse impossible. Fat grafting had previously been reported to have positive effects on radiation-damaged tissue (Coleman, 2006; Fukuba et al., 2020) and was therefore applied to the labia, vaginal walls, and perineum 9 years after the abdominal surgery. After injection of 200 cc tumescence solution (Klein, 1988), adipose tissue was harvested with a blunt 4 ml cannula from the inside of the right thigh by means of manual liposuction. After centrifugation at 1800 rpm for 3 min, the harvested tissue stratifies in a bottom layer of liquid, an oily top layer, and a middle layer consisting of intact adipocytes. The latter consisted of 20 ml and was injected drop-wise with a Coleman-I7-cannula in a fan-like pattern in several layers into the radiation-damaged tissue in the vulva and vaginal wall. This procedure was repeated after 11 months with advantageous outcome. Elasticity improved markedly, labia minora closed up in the midline and skin quality was softer and less prone for irritation. Today the patient is in good health without relapse and working fulltime.

### 3. Discussion

Vaginal rupture and evisceration is a rare complication after hysterectomy, and refers to ejection of intraperitoneal content through the ruptured vaginal cuff. It typically starts with vaginal cuff dehiscence, defined as a separation of the anterior and posterior edges of the vaginal cuff (Nezhat et al., 2018).

Risk factors for vaginal dehiscence with evisceration include surgical factors like mode of incision and closure of the cuff, as well as patient-related factors affecting tissue quality and wound healing, including previous irradiation, vaginal atrophy, obesity, tobacco use, diabetes, and long use of corticosteroids or immunosuppressant. Chronical conditions such as asthma, chronic obstructive pulmonary disease, gastroesophageal reflux disease and chronic constipation may also increase the risk of evisceration, due to a chronically increased intraabdominal pressure (Nezhat et al., 2018).

Vaginal fistulation has a tremendous impact on the patient's quality of life. Fistulas may occur as a consequence of advanced staged disease, radiotherapy, trauma, infection, and especially as a complication to extended surgery after previous irradiation (Narayanan et al., 2009). It was reported that in 15 of 20 patients, the fistula occurred as a complication after radiotherapy alone or in combination with recurrent disease (Narayanan et al., 2009).

Vesico-vaginal and entero-vaginal fistulas are the most common types of fistulas seen in patients with gynecological malignancies.

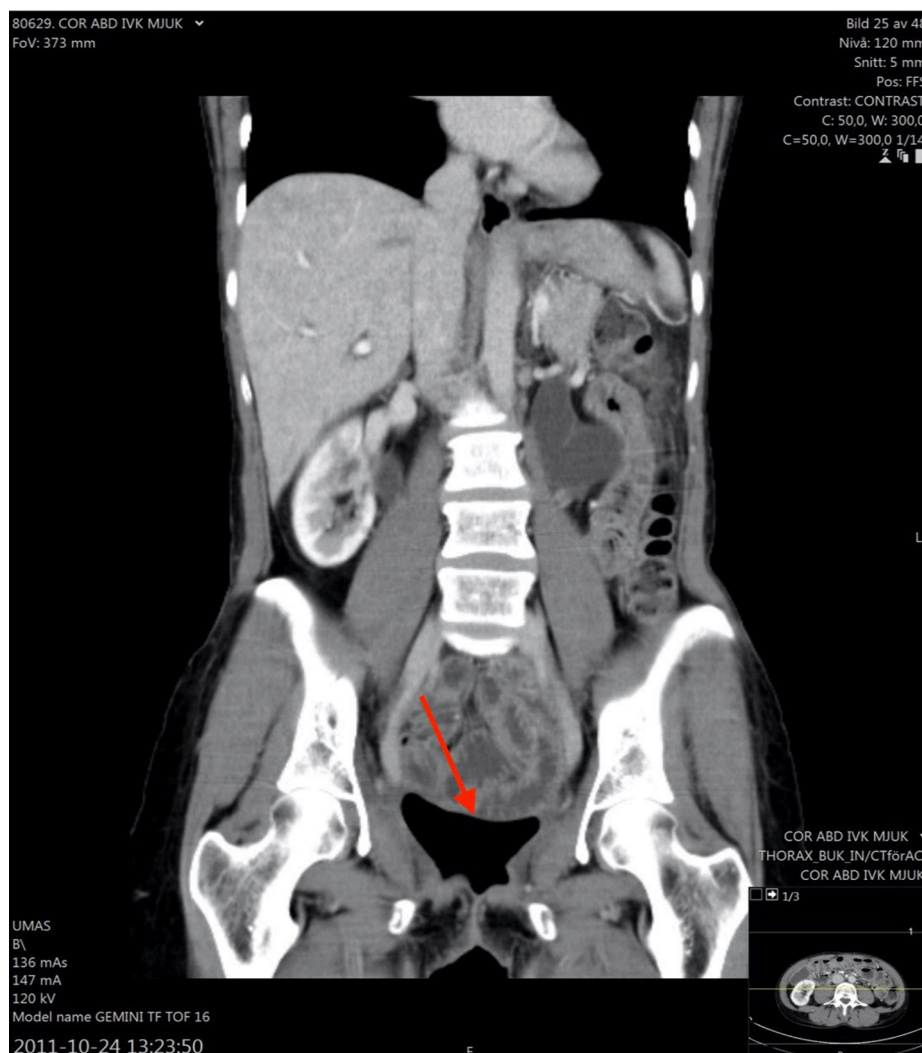
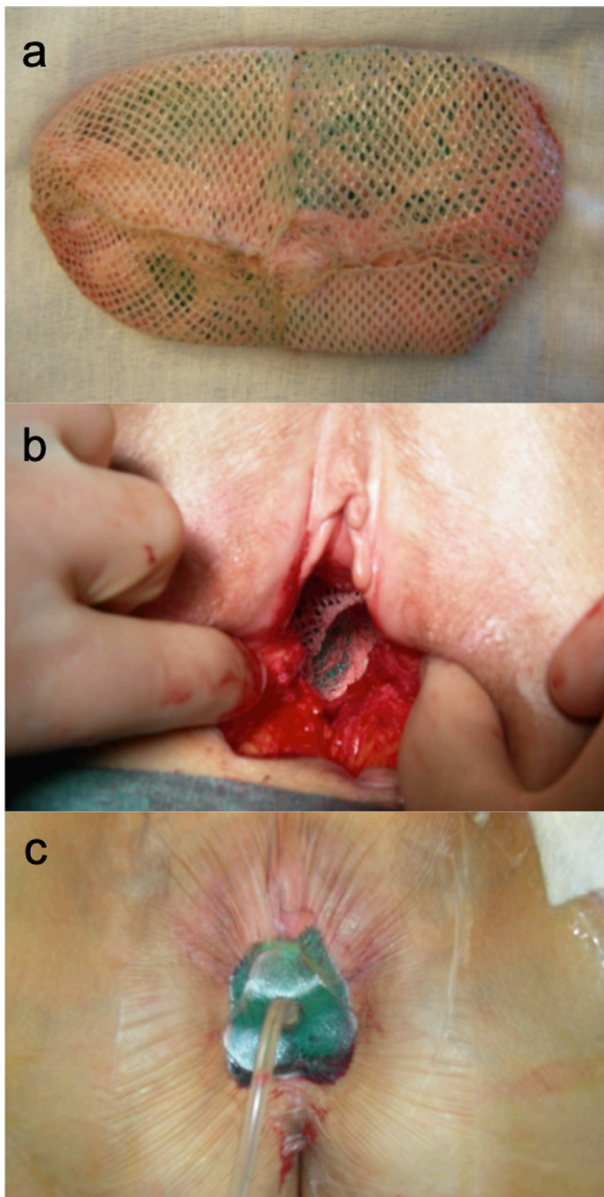


Fig. 1. CT scan showing the pelvic cavity, in close relationship to the vaginal introitus. Arrow indicating the cavity.



**Fig. 2.** Clinical photos (a) Stent covered with split skin graft, (b) Stent in place inside the vaginal cavity and (c) Stent covered with vacuum-assisted closure (donor site visible on patient's left leg).

Usually, the type of fistula can be diagnosed on a thorough patient history and physical examination, with the clinical finding of urinary leakage or faeces and mucus through the vagina. MR imaging may help to identify the precise location and complexity of the fistulas. (Narayanan et al., 2009). Treatment of postoperative vesico-, intestinal-, or vaginal fistulation in the irradiated patient is demanding and requires interposition of healthy tissue.

Early recognition and treatment of vaginal dehiscence with evisceration is critical. The closure of the vaginal defect can be challenging due to shrinkage, fibrosis and poor vascularization of the vagina and there is no consensus regarding the optimal approach (Narayanan et al., 2009). The crucial components are inspection of the bowel and mesentery, in case of evisceration, lavage of the peritoneal cavity, and closure of the vagina with reconstruction of the vaginal vault.

In the case reported here no involvement of the urinary bladder was suspected at time of diagnosis of the recurrence and thus only a posterior exenteration was performed. Based on the high dose of radiotherapy the patient had received it could in retrospect be argued that a total

exenteration including cystectomy should have been performed instead to prevent complications.

There are different methods for vaginal reconstruction. In our case, the determining factor for the method of choice was the continuous discharge of considerable amount of fluid. Since STSG are meshed, fluid is drained through the holes instead of gathering under the graft, ensuring good contact of the STSG and underlying tissue; a necessity for graft healing. VAC treatment, as used in our case, is a promising method for facilitating healing of skin grafts, especially in vaginal reconstructions, where evacuation of fluid is a crucial part of the healing process (Hallberg and Holmström, 2003).

STSG is probably the most simple method for vulvo-vaginal reconstructions, both in patients with vaginal atresia, and in patients with gynecological malignancies (de la Garza et al., 2009). An STSG is very thin and graft take usually good also on recipient beds with impaired vascularity. One feature of STSG is later contraction which in our case was an advantage in order to shrink the large post-radiation vaginal cavity, but could in other cases possibly result in stenosis and contraction of the neovagina (de la Garza et al., 2009; Hallberg and Holmström, 2003).

Other options for vaginal reconstructions are myocutaneous flaps (e.g. gracilis myocutaneous flaps, VRAM flaps, pudendal thigh flap), a bowel segment (Abd El-Aziz, 2006), omental J-flap with/without biological mesh or full-thickness skin grafts (FTSG). A myocutaneous flap requires complex surgery in an area with impaired healing after previous surgery and radiation. It would have filled the void but unlikely solve the amount of fluid. Interposition of bowel segment implies complex surgery and has a tendency to secretion. In addition the patient was reluctant to go into another abdominal operation. Taking all factors into consideration, none of the methods mentioned above was a realistic alternative in this case. FTSG resist contracture and have better aesthetic result than STSG, but there is limited supply of donor sites that can be closed directly.

#### 4. Conclusion

The extensive complication involving both urinary and intestinal fistulation described in our case is very rare and probably occurred as a consequence of repeated pelvic surgery in irradiated tissue. Surgical closure of the vaginal defect was not possible, due to extended fibrosis and due to the heavy secretion from the cavity which impeded delayed closure by secondary healing. Taking all impinging factors into consideration, STSG in combination with VAC offered a technically simple and safe solution.

Even though STSG is often utilized for vulvo-vaginal reconstructions we have not found any case describing STSG in combination with VAC treatment as a successful treatment in patients with vaginal rupture.

#### Informed consent

Informed consent has been obtained from the patient.

#### Author contributions

All authors made substantial contribution to all of the following: (1) conception and design of the work, (2) drafting the work or revising it critically for important intellectual content, (3) final approval of the version to be published, and (4) agreement to be accountable for all aspects of the work in ensuring that questions related to the accuracy or integrity of any part of the work are appropriately investigated and resolved.

#### Declaration of Competing Interest

The authors declare that they have no known competing financial interests or personal relationships that could have appeared to influence

the work reported in this paper.

## References

- Abd El-Aziz, S., 2006. Vaginal reconstruction using the ileocecal segment after resection of pelvic malignancy. *J. Egypt. Natl. Canc. Inst.* 18, 1–7.
- Coleman, S.R., 2006. Structural fat grafting: More than a permanent filler. *Plast. Reconstr. Surg.* 118, 108–120. <https://doi.org/10.1097/01.prs.0000234610.81672.e7>.
- de la Garza, J., Wilson, S.S., Behbakht, K., 2009. Total pelvic exenteration with a split-thickness skin graft neovagina, continent orthotopic neobladder and rectal reanastomosis, resulting in no external ostomies and adequate sexual function. *Gynecol. Oncol.* 115, 312–313. <https://doi.org/10.1016/j.ygyno.2009.07.002>.
- Fukuba, M., Uozaki, H., Komuro, Y., 2020. Effectiveness of the combination of fat grafting and injection on radiation ulcer healing. *J. Plast. Surg. Hand Surg.* 54, 24–28. <https://doi.org/10.1080/2000656X.2019.1657436>.
- Hallberg, H., Holmström, H., 2003. Vaginal construction with skin grafts and vacuum-assisted closure. *Scand. J. Plast. Reconstr. Surg. hand Surg.* 37, 97–101. <https://doi.org/10.1080/02844310310005621>.
- Klein, J.A., 1988. Anesthesia for liposuction in dermatologic surgery. *J. Dermatol. Surg. Oncol.* 14, 1124–1132. <https://doi.org/10.1111/j.1524-4725.1988.tb03469.x>.
- Narayanan, P., Nobbenhuis, M., Reynolds, K.M., Sahdev, A., Reznek, R.H., Rockall, A.G., 2009. Fistulas in malignant gynecologic disease: Etiology, imaging, and management. *Radiographics* 29, 1073–1083. <https://doi.org/10.1148/rg.294085223>.
- Nezhat, Camran, Burns, M.K., Wood, M., Nezhat, Ceana, Nezhat, A., Nezhat, F., 2018. Vaginal cuff dehiscence and evisceration. *Obstet. Gynecol.* 132, 972–985. <https://doi.org/10.1097/AOG.0000000000002852>.