

Access this article online

Quick Response Code:



Website:
www.e-tjo.org

DOI:
10.4103/tjo.tjo_49_21

Fabrication of a facial prosthesis for a 13-year-old child by using a point-and-shoot three-dimensional scanner and CAD/CAM technology

Ming-Hui Sun^{1,2}, Chieh-Hung Yen^{1,2}, Yueh-Ju Tsai^{1,2}, Yi-Lin Liao^{1,2*}, Shu-Ya Wu^{3*}

Abstract:

Patients cannot wear ocular prostheses after undergoing orbital exenteration. They require a facial prosthesis to obtain a more favorable appearance, which greatly affects their social life and psychological health. In addition, conventional prosthesis-making processes require substantial time and expense. The economic burden is particularly heavy on children, who may require many prosthesis replacements as they mature. We report a method of fabricating a facial prosthesis by three-dimensional (3D) facial scanning and 3D printed for a 13-year-old girl who underwent partial orbital exenteration for malignant ciliary body medulloepithelioma 2 years ago. The patient's facial contour was captured with a hand-held, point-and-shoot 3D scanner. A facial prosthesis was designed using a mirror image technique with 3D modeling software and 3D printed. The prosthesis was then postprocessed and cast in silicone rubber. An ocular prosthesis was integrated into the facial prosthesis. The prosthesis was retained by prosthetic adhesives. This digitally assisted, impression-free method may lower the cost and effort of making facial prostheses and improve patient comfort, especially for children.

Keywords:

Facial prosthesis, orbital exenteration, three-dimensional printing, three-dimensional scanning

Introduction

Orbital exenteration is a disfiguring procedure that is often reserved for progressive malignancies or infections that are otherwise uncontrollable. Patients undergoing orbital exenteration often experience substantial psychological stress and have difficulties in their social life and work. Prosthesis rehabilitation plays a crucial role in restoring patients' quality of life.^[1,2]

Conventional prosthesis fabrication involves making an impression and, subsequently, a series of molds through manual sculpting. Therefore, prosthesis-making is expensive and time-consuming. For pediatric patients, fabrication may be difficult because of

insufficient cooperation. In addition, the economic burden of fabrication is particularly heavy for families with small children who require replacements as they mature.

Three-dimensional (3D) scanning and printing of the prosthesis may reduce the expenses associated with prosthesis fabrication by replacing several steps with digital processes.^[3-6]

Case Report

An 11-year-old girl presented with a thoroughly vascularized mass protruding from the upper nasal sclera of her right eye accompanied by visual loss. Orbital computed tomography and a biopsy confirmed the diagnosis of a ciliary body

¹Department of Medicine, Chang Gung Memorial Hospital, Linkou Medical Center, Taoyuan, Taiwan, ²School of Medicine, Chang Gung University, Taoyuan, Taiwan, ³Department of Ophthalmology, Taipei Tzu Chi Hospital, Buddhist Tzu Chi Medical Foundation, New Taipei City, Taiwan

*Address for correspondence:

Dr. Shu-Ya Wu,
Department of Ophthalmology, Taipei Tzu Chi Hospital, Buddhist Tzu Chi Medical Foundation, No. 289, Jianguo Road, Xindian District, New Taipei City 231, Taiwan.
E-mail: cgmheye@gmail.com

Submission: 12-06-2021
Accepted: 16-10-2021
Published: 21-01-2022

This is an open access journal, and articles are distributed under the terms of the Creative Commons Attribution-NonCommercial-ShareAlike 4.0 License, which allows others to remix, tweak, and build upon the work non-commercially, as long as appropriate credit is given and the new creations are licensed under the identical terms.

For reprints contact: WKHLRPMedknow_reprints@wolterskluwer.com

How to cite this article: Sun MH, Yen CH, Tsai YJ, Liao YL, Wu SY. Fabrication of a facial prosthesis for a 13-year-old child by using a point-and-shoot three-dimensional scanner and CAD/CAM technology. Taiwan J Ophthalmol 2022;12:219-22.

medulloepithelioma. Parotid lymph node metastasis was detected upon whole-body survey. She underwent partial exenteration and adjuvant radiotherapy to the orbital tumor bed and, subsequently, the right preauricular area. Six months later, the tumor recurred, with intracranial invasion. The patient underwent radiosurgery and salvage chemotherapy. She continued to receive oral chemotherapy after radiosurgery and salvage chemotherapy.

We scanned the patient's face with a hand-held, point-and-shoot, 3D scanner (SCANIFY, Fuel3D Technologies, Ltd., United Kingdom) [Figure 1a]. Multiple scans were cropped and stitched together to form an upper face model, which contains the geometric shapes and the surface details of the healthy side and the diseased side [Figure 1b and c]. The design of the prosthesis was performed by ophthalmologists and was based on the mirror image of the healthy side of her face [Figure 2a]. The mirrored healthy side surface would become the basis of anterior surface of the prosthesis, while the diseased side surface defined the posterior surface of the prosthesis. We used the tools in 3D sculpting software (Zbrush, Pixologic, Inc., United States) to tweak the position and contour of the mirrored surface to alter the shape and size of the prosthesis. By changing the elevation and contour of the mirrored surface, the ophthalmologist could determine the curved line at which the two surfaces intersect, determining the edge of the prosthesis [Figure 2b]. An acrylic ocular prosthesis which was custom-made for the patient by an oculist with conventional manual molding and painting process was 3D scanned. The 3D model of the ocular prosthesis was imported into the software and aligned with the facial prosthesis. The details on the 3D model of the prosthesis were




Figure 1: The acquisition of three-dimensional facial contour data. (a) The portable three-dimensional scanner. (b) A single scan captured by the SCANIFY scanner. The area circled by dots and lines is an example of selecting an area for cropping. (c) A three-dimensional model created by stitching fragments being cropped from multiple scans

enhanced with 3D sculpting tools. The whole set of 3D models was transferred to another 3D modeling software (Meshmixer, Autodesk, Inc., United States) to become subjects of Boolean functions (combinations and subtractions between overlapping 3D models) to create the final prosthesis 3D model. Solid volumes were created by extruding (adding thickness to) the anterior surface and the posterior surface. The volume of the posterior surface was used as a tool to subtract part of the volume created by the anterior surface. The part intersecting with the posterior surface volume was removed, and the remaining volume would be the prosthesis. The recess required to house the ocular prosthesis was carved out with similar Boolean subtraction method [Figure 2c]. After the shape of the prosthesis was determined, a trial prosthesis was printed with a stereolithography printer. Then, a trial fitting was conducted. Visible gaps between the inner surface of the prosthesis and the patient's face were eliminated by creating an updated version of the prosthesis. The final facial prosthesis model was printed, postprocessed, and cast into silicone rubber, and the paint was added manually. The eyelashes and brow were implanted manually, using the patient's own hair [Figure 2d]. The silicone part weighted about 4 g.

The first step of the prosthesis fitting was to align and integrate the ocular prosthesis and the facial prosthesis. Temporary adhesive was applied between the silicone facial prosthesis and the acrylic ocular prosthesis. After the position of the ocular prosthesis was confirmed, excessive volume at the edge of the ocular prosthesis was trimmed and the ocular prosthesis was integrated

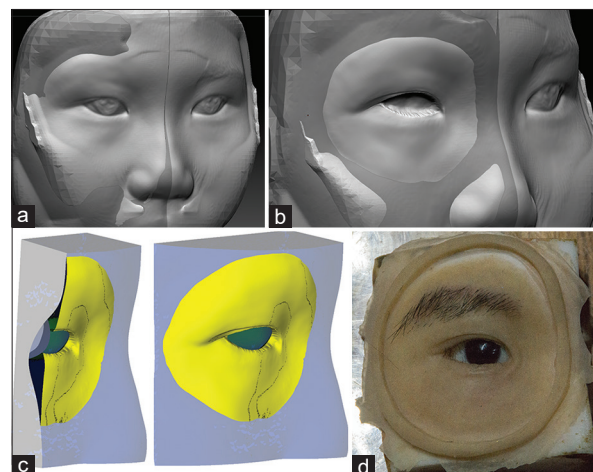


Figure 2: The design and fabrication processes of the facial prosthesis. (a) The mirrored healthy side surface being aligned with the diseased side. (b) The shape of the prosthesis defined by adjusting and reshaping the mirrored surface. The diseased side surface is shown in darker gray color. (c) A schematic of the relationship among the diseased side surface (blue), the anterior surface of the prosthesis created according to the mirrored image (yellow), and the three-dimensional model of ocular prosthesis (green). (d) The silicone facial prosthesis before the removal of excessive material at its edge. The ocular prosthesis is not yet integrated with the facial prosthesis

into the facial prosthesis by adding a thin layer of fast curing silicone rubber onto its posterior surface, sealing up the posterior opening of the recess. The completed prosthesis was attached to the patient's skin with a water-based prosthetic adhesive which contains acrylic emulsion, glycerol, guar gum, and sorbitol [Figure 3].

Discussion

There are different types of 3D capture devices available for facial prosthesis fabrication. Structured light and laser scanners which would continue to update geometry over the scanning process are often sensitive to motion and deformation, limiting their use in living people, particularly children.^[4] The scanner we use provides acquisition within a fraction of a second by combining stereoscopic and photometric technology, eliminating the problems of motion and deformation and thus increasing image quality. The scanner we used could preserve many fine details on the face, such as lid creases and wrinkles, without requiring external fixation to stabilize the patient's head. This reduced the work of designing a periocular facial prosthesis. The main disadvantage of this type of scanner is its reduced accuracy on the area with steep angles and undercuts.^[6] According to our experience, this type of error could be mitigated by carefully stitching multiple scans taken from different angles and by a (mockup) trial fitting with subsequent manual adjustment in the software. The trial-fitting strategy has also been adopted by another team using a highly accurate scanner, which is more expensive than what we have used on this case.^[7]

The ocular prosthesis we used in this case was (conventionally) custom-made for the patient and 3D scanned. The workflow could be further simplified in future cases by replacing the 3D scanning process of the ocular prosthesis with the utilization of prebuilt ocular prosthesis models in the software, since such patients have already lost their conjunctiva sac and no custom geometry would be needed. The fabrication of the acrylic ocular prostheses can be based on 3D-printed ocular prosthesis molds.

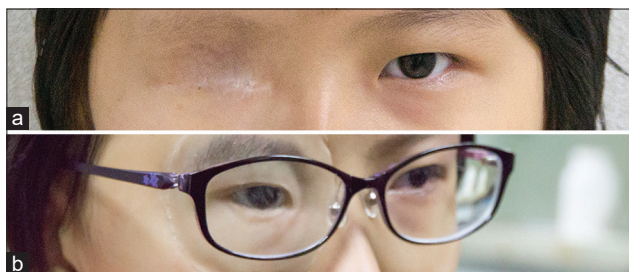

Figure 3: Result of prosthetic fitting. (a) Photograph before fabrication of the facial prosthesis. A 13-year-old girl with ciliary body medulloepithelioma underwent partial extirpation and radiotherapy of the orbital tumor bed 2 years ago. (b) Result after applying the facial prosthesis with prosthetic adhesive

An adhesive-retained prosthesis does not require any preplaced implant; therefore, it has a lower risk of complication than, for example, a magnetic-retained prosthesis, particularly on a postradiotherapy patient whose local microvasculature is compromised. A soft silicone prosthesis can stretch with the patient's facial expression when adhered firmly to the skin, which improves cosmesis. The main disadvantages of adhesive-retained prostheses, compared with implant-retained ones, are the complex and lengthy process to apply them and sometimes the strength of retention, particularly when perspiring or sneezing, depending on the adhesive used.^[8] Since the digitally assisted fabrication process does not limit retaining method, similar workflow may be implemented in the fabrication of easier-to-use magnetic-retained prostheses.

Ethics approval and consent to participate

This case report had received approval from our Institutional Review Board of Chang Gung Memorial Hospital (201700501B0).

Declaration of patient consent

The authors certify that they have obtained all appropriate patient consent forms. In the form, the patient's parents have given consent for images and other clinical information to be reported in the journal. The patient's parents understand that her names and initials will not be published and due efforts will be made to conceal identity, but anonymity cannot be guaranteed.

Financial support and sponsorship

This work was supported by the grant from the Chang Gung Memorial Hospital (Grant number CMRPG3G1681) to Ming-Hui Sun.

Conflicts of interest

Dr. Ming-Hui Sun and Dr. Yueh-Ju Tsai are editorial board members at *Taiwan Journal of Ophthalmology*, had no role in the peer review process of or decision to publish this article.

References

1. Fingeret MC, Teo I, Epner DE. Managing body image difficulties of adult cancer patients: Lessons from available research. *Cancer* 2014;120:633-41.
2. Newton JT, Fiske J, Foote O, Frances C, Loh IM, Radford DR. Preliminary study of the impact of loss of part of the face and its prosthetic restoration. *J Prosthet Dent* 1999;82:585-90.
3. Nuseir A, Hatamleh M, Watson J, Al-Wahadni AM, Alzoubi F, Murad M. Improved construction of auricular prosthesis by digital technologies. *J Craniofac Surg* 2015;26:e502-5.
4. Grant GT, Aita-Holmes C, Liacouras P, Garnes J, Wilson WO Jr. Digital capture, design, and manufacturing of a facial prosthesis: Clinical report on a pediatric patient. *J Prosthet Dent* 2015;114:138-41.

5. He Y, Xue GH, Fu JZ. Fabrication of low cost soft tissue prostheses with the desktop 3D printer. *Sci Rep* 2014;4:6973.
6. Bi Y, Wu S, Zhao Y, Bai S. A new method for fabricating orbital prosthesis with a CAD/CAM negative mold. *J Prosthet Dent* 2013;110:424-8.
7. Weisson EH, Fittipaldi M, Concepcion CA, Pelaez D, Grace L, Tse DT. Automated noncontact facial topography mapping, 3-dimensional printing, and silicone casting of orbital prosthesis. *Am J Ophthalmol* 2020;220:27-36.
8. Chang TL, Garrett N, Roumanas E, Beumer J 3rd. Treatment satisfaction with facial prostheses. *J Prosthet Dent* 2005;94:275-80.