

Video available on:  
www.e-tjo.org

Access this article online

Quick Response Code:



Website:  
www.e-tjo.org

DOI:  
10.4103/tjo.tjo\_64\_20

# Removal of massive subretinal organized blood clot with fragmatome

San-Ni Chen<sup>1,2,3\*</sup>, Alice C. Wu<sup>1</sup>

## Abstract:

The purpose of the study was to describe using fragmatome in removing subretinal organized blood clot in eyes of age-related macular degeneration and massive subretinal hemorrhage. This study was an interventional, consecutive case series. Patients with massive subretinal hemorrhage with total or subtotal retinal detachment from age-related macular degeneration and organized subretinal blood clot were managed by creating large retinectomy. The less organized blood was removed with vitrector. The subretinal organized blood clot was removed by fragmatome. The retina was reattached with perfluorocarbon liquid, and laser was applied at the margin of retinectomy. Silicon oil was infused at the end of surgery. All patients had subretinal blood totally or subtotally removed. The organized blood clot, which was difficult to be removed by vitrector was easily and efficiently removed by fragmatome. Visual acuity improved in all eyes, and retina was well attached under silicon oil. Fragmatome offers a more efficient way in removing organized blood clot, which will much shorten the duration of operation.

## Keywords:

Exudative age-related macular degeneration, fragmatome, organized blood clot

## Introduction

Subretinal hemorrhage is a serious complication of exudative age-related macular degeneration. For the fresh subretinal hemorrhage, intravitreal injection of gas with or without tissue plasminogen activator (t-PA) and a prone position postoperatively to displace the submacular blood had been widely used.<sup>[1-4]</sup> Recently, subretinal t-PA with expansile gas in eyes with larger subretinal hemorrhage was reported to be more efficient in displacing the hematoma.<sup>[5]</sup> For eyes with massive subretinal hemorrhage and total or subtotal serosanguinous retinal detachment, subretinal injection of t-PA and perfluorocarbon liquid-assisted drainage of subretinal hemorrhage from retinotomy has been reported.<sup>[6]</sup> However, it is difficult to evacuate the blood from the subretinal space in eyes with organized blood clot and

massive subretinal pigment epithelial blood. Thus, some authors used large retinectomy to remove subretinal blood clot totally or subtotally through the retinectomy.<sup>[7,8]</sup> In this report, we used a novel technique using fragmatome for a more efficient removal of organized subretinal blood clot.

## Material and Methods

A retrospective study on consecutive cases of age-related macular degeneration with massive subretinal hemorrhage and organized blood clot and a visual acuity of hand motion or worse who underwent vitrectomy for removal of subretinal blood. All patients had informed consent. The study was conducted in accordance with the Declaration of Helsinki and was approved by the local ethics committee of the institute Changhua Christian Hospital:191203. Informed written consent was obtained from all patients before their enrollment in this study.

<sup>1</sup>Department of  
Ophthalmology,

Changhua Christian  
Hospital, Changhua City,

<sup>2</sup>Department of Medicine,  
Chung-Shan Medical  
University, Taichung,

<sup>3</sup>Department of Optometry,  
Da-Yeh University,  
Changhua, Taiwan

\*Address for  
correspondence:

Dr. San-Ni Chen,  
Department of  
Ophthalmology, Changhua  
Christian Hospital, No.  
135, Nanxiao Street,  
Changhua City, Taiwan.  
E-mail: 108562@cch.org.tw

Submission: 07-07-2020

Accepted: 22-09-2020

Published: 09-03-2021

This is an open access journal, and articles are distributed under the terms of the Creative Commons Attribution-Non Commercial-ShareAlike 4.0 License, which allows others to remix, tweak, and build upon the work non-commercially, as long as appropriate credit is given and the new creations are licensed under the identical terms.

For reprints contact: WKHLRPMedknow\_reprints@wolterskluwer.com

**How to cite this article:** Chen SN, Wu AC. Removal of massive subretinal organized blood clot with fragmatome. Taiwan J Ophthalmol 2021;11:395-7.

## Surgical techniques

A 23G vitrectomy system (Constellation, Alcon Company) was used for vitrectomy. A chandelier light was inserted at an inferior aspect to facilitate a better illumination at the removal of subretinal blood. After core vitrectomy, induction of posterior vitreous detachment, and trimming of peripheral vitreous skirt, the retina near pars plana at the aspect where subretinal blood most flocculated, most of the time was inferior retina, was coagulated around 180° with endodiathermy and was incised with vitrector along the coagulation. The retina then was lifted and turned over to expose the subretinal space. The subretinal blood clot was removed with a vitrector with caution. The organized blood, which was difficult to be removed by the vitrector, was pulled over to the preretinal space. The submacular scar tissue was also removed by intraocular forceps. Choroidal hemorrhage related to the scar tissue was stopped by either diathermy or elevating intraocular pressure. Perfluorocarbon liquid was then applied to stabilize the retina and the organized blood clot, and scar tissue was floating above the surface of perfluorocarbon liquid and removed by fragmatome with the setting of 30% ultrasound energy and vacuum of 200 mmHg. For the fibrotic scar, vitrector was used with a low cutting rate and high suction (cutting speed: 500 cuts/min, vacuum: 600 mmHg). After the removal of organized blood clot, perfluorocarbon liquid was further instilled to completely attach the retina, followed by laser retinopexy, air-perfluorocarbon liquid exchange, and silicone oil tamponade. To apply laser at the margin of retinectomy, complete removal of blood under the retinectomy site is necessary for an effective laser retinopexy to prevent retinal detachment [Video].

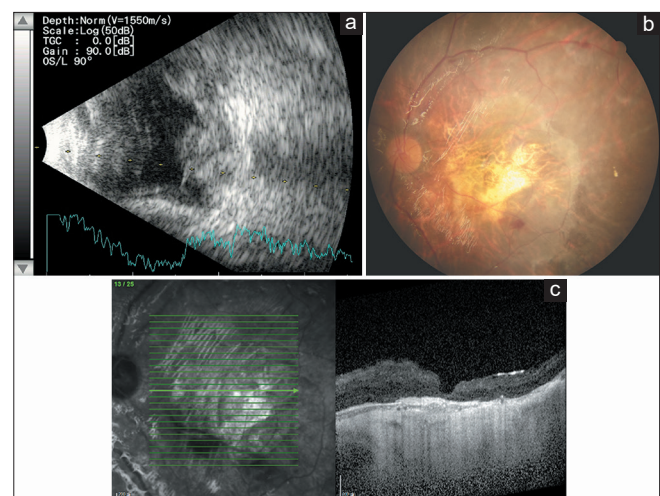
## Results

One surgeon (S.N.C) performed this technique in four consecutive eyes with massive subretinal hemorrhage and organized blood clot. All four cases had the previous vitrectomy with subretinal t-PA, with or without subretinal gas injection and gas tamponade without successful displacement of submacular hemorrhage. Cases 2 and 4 had postoperative complications of total hyphema and elevated intraocular pressure after the initial vitrectomy because of the displaced subretinal blood flowing into anterior chamber after prone position. Cases 1 and 2 were pseudophakic before the reoperation of vitrectomy; cases 3 and 4 had concomitant phacoemulsification and placement of posterior chamber intraocular lens at the reoperation of vitrectomy. All eyes had total or subtotal removal of subretinal blood, and the fibrotic scar was removed in cases 1 and 2. The organized blood clot was removed by

fragmatome, the nonorganized blood clot, and fibrotic scar was removed by vitrector. Fibrotic scar removal associated with choroidal hemorrhage was noted in two eyes (cases 1 and 2) and was immediately stopped by transiently elevating the intraocular pressure. The retina was well attached and improved. Best-corrected visual acuity was noted in all eyes postoperatively. Figure 1 shows the preoperative B-Scan, postoperative color fundus, and optical coherence tomography in case 1. The demographic data of the consecutive patients were listed in Table 1.

## Discussion

Complete removal of subretinal hemorrhage around the margin of retinotomy site for drainage of subretinal blood is important for laser retinopexy to avoid the complication of retinal detachment. However, for eyes with organized subretinal blood which could not be lysed by t-PA, the blood clot under the drainage retinotomy may not be removed completely, thus preventing the laser application. Isizaki *et al.* proposed using an intentional giant tear for a more complete removal of the subretinal blood clot and organized blood.<sup>[7]</sup> This would mostly solve the problem of incomplete removal of subretinal blood and facilitate laser application. Unfortunately, the organized blood clot, which is hard in consistency, often is difficult to be chipped away with



**Figure 1:** A 77-year-old female (case 1) patient, a victim of bilateral exudative age-related macular degeneration, suffered from submacular hemorrhage in the left eye. Despite monthly injection of antivascular endothelial growth factor agents, intravitreal injection of C3F8, and gas tamponade, her vision kept on deteriorating from 0.02 to light perception because of recurrent submacular hemorrhage 6 months later. We then proceeded to perform vitrectomy, subretinal injection of tissue plasminogen activator inhibitor, and intravitreal gas tamponade on her. However, her vision did not improve and deteriorated to no light perception later. B-scan after the first vitrectomy showed massive subretinal hematoma and subretinal hemorrhage (a). After deliberate discussion with the patient and her family, another vitrectomy was performed 2 months later. The postoperative color fundus (b) and optical coherence tomography (c) showed complete clearance of subretinal hemorrhage and atrophic patch at the macular area. The patients had visual acuity in the left eye improved to counting finger

**Table 1: Demographic data of patients**

<i>n</i>	Age/sex/eye	Predisposing condition	Initial/final BCVA	Intra/postoperative complications	Follow-up duration
1	78/female/OS	N-AMD	NLP/CF	Choroidal hemorrhage	13 months
2	71/female/OS	N-AMD	LP/0.02	Choroidal hemorrhage	10 months
3	54/male/OD	PCV	HM/0.02	None	8 months
4	65/male/OD	PCV	LP/0.02	None	6 months

BCVA=Best-corrected visual acuity, OS=Left eye, OD=Right eye, N-AMD=Neovascular age-related macular degeneration, PCV=Polypoidal choroidal vasculopathy, NLP=No light perception, CF=Counting finger, LP=Light perception, HM=Hand motion

the vitrector. Generally, a long, tedious process is needed for a complete removal.

Ultrasound has been applied as an adjunct to thrombolytic therapy, which improves the recanalization of occluded vessels.<sup>[9]</sup> Through the energy of ultrasound, we noted that the hard, organized blood clot could be fragmented into small pieces and aspirated from the fragmatome easily. During the operation, we also noted that fragmatome, though very efficient in removing organized blood clot, is of no use for removing the fibrotic scar, which is different in the physical property as organized blood clot. Vitrector, on the other hand, is more suitable for removal of soft tissue by aspirating and cutting the tissue within the opening of the vitrector.

## Conclusion

Ultrasound energy offered by fragmatome is efficient for the removal of organized blood clot and may help to eradicate the massive subretinal hemorrhage. It is reasonable to expect that hypersonic vitrectomy, which is now in market, may also be more efficient than the traditional vitrectomy in managing the organized blood clot.

## Declaration of patient consent

The authors certify that they have obtained all appropriate patient consent forms. In the form the patient has given her consent for her images and other clinical information to be reported in the journal. The patient understands that her name and initial will not be published and due efforts will be made to conceal her identity, but anonymity cannot be guaranteed.

## Financial support and sponsorship

Nil.

## Conflicts of interest

The authors declare that there are no conflicts of interests of this paper.

## References

- Ohji M, Saito Y, Hayashi A, Lewis JM, Tano Y. Pneumatic displacement of subretinal hemorrhage without tissue plasminogen activator. *Arch Ophthalmol* 1998;116:1326-32.
- Hesse L, Schmidt J, Kroll P. Management of acute submacular hemorrhage using recombinant tissue plasminogen activator and gas. *Graefes Arch Clin Exp Ophthalmol* 1999;237:273-7.
- Hassan AS, Johnson MW, Schneiderman TE, Regillo CD, Tornambe PE, Poliner LS, *et al.* Management of submacular hemorrhage with intravitreal tissue plasminogen activator injection and pneumatic displacement. *Ophthalmology* 1999;106:1900-6.
- Hillenkamp J, Surguch V, Framme C, Gabel VP, Sachs HG. Management of submacular hemorrhage with intravitreal versus subretinal injection of recombinant tissue plasminogen activator. *Graefes Arch Clin Exp Ophthalmol* 2010;248:5-11.
- Sharma S, Kumar JB, Kim JE, Thordsen J, Dayani P, Ober M, *et al.* Pneumatic displacement of submacular hemorrhage with subretinal air and tissue plasminogen activator: Initial United States experience. *Ophthalmol Retina* 2018;2:180-6.
- Kamei M, Tano Y, Maeno T, Ikuno Y, Mitsuda H, Yuasa T. Surgical removal of submacular hemorrhage using tissue plasminogen activator and perfluorocarbon liquid. *Am J Ophthalmol* 1996;121:267-75.
- Isizaki E, Morishita S, Sato T, Fukumoto M, Suzuki H, Kida T, *et al.* Treatment of massive subretinal hematoma associated with age-related macular degeneration using vitrectomy with intentional giant tear. *Int Ophthalmol* 2016;36:199-206.
- Choi YJ, Hyun J, Choi KS, Rhee MR, Lee SJ. Bullous hemorrhagic retinal detachment because of massive subretinal hemorrhage in patients with age-related macular degeneration. *Retina* 2013;33:1365-74.
- Zhou Y, Ramaswami R. Comparison of sonothrombolysis efficiencies of different ultrasound systems. *J Stroke Cerebrovasc Dis* 2014;23:2730-5.