

MINI-FOCUS ISSUE: CHEST WOUNDS

INTERMEDIATE

CASE REPORT: CLINICAL CASE

Gunshot-Related Pediatric Left Ventricular Apical Aneurysm



Achala Donuru, MBBS,^a David Saul, MD,^b Maansi Parekh, MBBS, DNB,^a Maruti Kumaran, MD,^c Vinay Kandula, MBBS,^b Rami Kharouf, MD^d

ABSTRACT

Penetrating injuries of the thorax and abdomen, such as gunshot and stabbing, are rare in children. We present the case of a pediatric patient with a history of remote gunshot injury presenting with a late aneurysm in the left ventricle. (**Level of Difficulty: Intermediate.**) (J Am Coll Cardiol Case Rep 2021;3:26-30) © 2021 The Authors. Published by Elsevier on behalf of the American College of Cardiology Foundation. This is an open access article under the CC BY-NC-ND license (<http://creativecommons.org/licenses/by-nc-nd/4.0/>).

A 9-year-old male patient presented to his primary care physician with abdominal pain. In view of the history of gunshot wound (GSW) 5 years earlier, a chest radiograph (CXR) was obtained. The CXR demonstrated an abnormal bulge along the left heart border with a curvilinear calcification. He was referred to a cardiologist for further evaluation.

PAST MEDICAL HISTORY

The patient had a past medical history of GSW at the age of 4 years during a domestic dispute. Additional information from the outside hospital notes revealed that the patient was taken to the emergency department after sustaining the gunshot. He had a wound in the left parasternal region in the fourth intercostal space with an additional wound in the left axilla. CXR showed a large left hemothorax (Figure 1). The patient had desaturation and worsening hypotension, so was taken to the operating room. The surgeon performed a left thoracotomy and noted the bullet trajectory from the left parasternal region, superficial to the pleura, and exiting from the left axilla. Contusion of the left upper lobe and small hemopericardium were noted. There was severe contusion to the left ventricle (LV). There was no visible penetration of

LEARNING OBJECTIVES

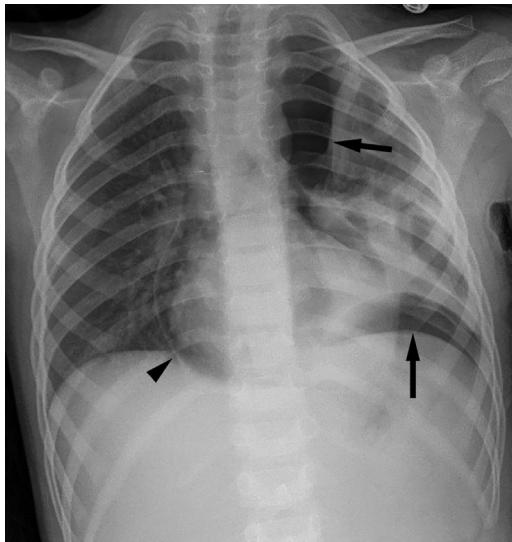
- To be able to make a diagnosis of true versus pseudoaneurysm of the LV on multimodality imaging.
- LVA, despite being rare in the pediatric population, warrants an index of suspicion based on clinical background as well as appropriate follow-up.

From the ^aDepartment of Radiology, Thomas Jefferson University Hospitals, Philadelphia, Pennsylvania, USA; ^bDepartment of Medical Imaging, A.I. DuPont Hospital for Children, Wilmington, Delaware, USA; ^cDepartment of Radiology, Temple University, Philadelphia, Pennsylvania, USA; and the ^dDepartment of Cardiology, A.I. DuPont Hospital for Children, Wilmington, Delaware, USA.

The authors attest they are in compliance with human studies committees and animal welfare regulations of the authors' institutions and Food and Drug Administration guidelines, including patient consent where appropriate. For more information, visit the [Author Center](#).

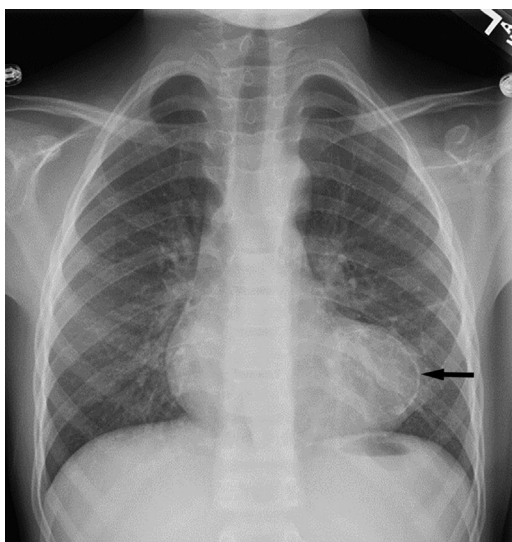
Manuscript received July 21, 2020; revised manuscript received September 30, 2020, accepted October 19, 2020.

FIGURE 1 Chest Radiograph Following Gunshot



Chest radiograph at presentation shows a moderate pneumopericardium (**arrowhead**), moderate left hemopneumothorax (**arrows**) and partial collapse of the left lung.

FIGURE 2 Chest Radiograph 5 Years Later



Chest radiograph at the age of 9 years (5 years after initial presentation) shows a bulge along the left heart border and curvilinear calcification (**arrow**).

the left pleura or pericardium by the bullet. A pericardial window was made. Cardiac enzymes were elevated, thought to be related to contusion. Inpatient recovery was uneventful and the patient was discharged home subsequently. The patient was lost to follow-up.

DIFFERENTIAL DIAGNOSIS

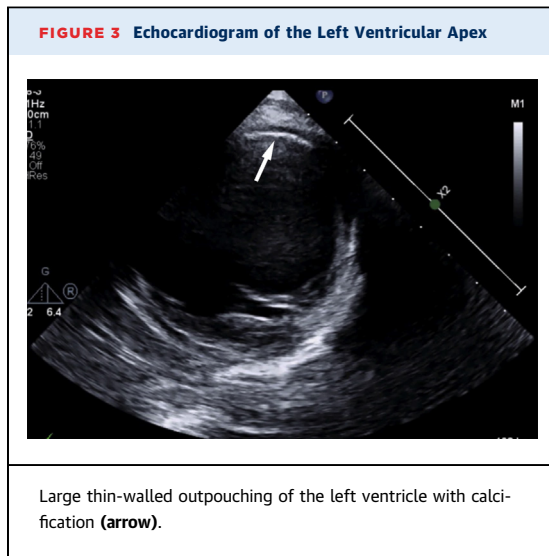
True left ventricular aneurysm (LVA), left ventricular pseudoaneurysm. Left ventricular pseudoaneurysm formation results from rupture of the myocardial free wall and the rupture is contained by adherent pericardium or scar tissue. This tends to be situated in the posterior and lateral wall segments. Compared with true aneurysms, pseudoaneurysms have a characteristically narrow neck. The true aneurysm is thinner than the wall of the rest of the LV and is usually composed of fibrous tissue as well as necrotic muscle. True aneurysms typically have a wide neck.

INVESTIGATIONS

Because LVA may be associated with a risk of sustained monomorphic ventricular tachycardia, the patient was evaluated for arrhythmias using exercise stress testing and 24-h electrocardiogram Holter monitor. The CXR demonstrated an abnormal bulge along the left heart border with a curvilinear peripheral calcification (**Figure 2**). An echocardiogram revealed a large 40 × 40-mm anterior/apical aneurysm of the LV that was completely akinetic with no obvious thrombus (**Figure 3**, **Videos 1 and 2**). LV ejection fraction (EF) was 37% with normal right ventricular EF. No pulmonic insufficiency. There was trivial tricuspid regurgitation. The patient was diagnosed with stage B heart failure based on classification by the American College of Cardiology and the American Heart Association. To further evaluate the LVA and assess biventricular function, further imaging was advised. Cardiac magnetic resonance imaging (MRI) was favored over computed tomography (CT) because of lack of ionizing radiation and better accuracy in measuring LV volume and LVEF. The patient was deemed safe for MRI because the bullet had exited the chest, with no fragments seen at thoracotomy or on CXR. The cardiac MRI confirmed the findings from echocardiogram (**Figure 4A to 4C**) and showed no thrombus on 4-chamber fast *imaging* employing steady-state

ABBREVIATIONS AND ACRONYMS

CT = computed tomography
CXR = chest radiograph
EF = ejection fraction
FIESTA = fast imaging employing steady-state acquisition
LV = left ventricle
LVA = left ventricular aneurysms
MRI = magnetic resonance imaging



acquisition (FIESTA), cine FIESTA, or delayed myocardial images (Videos 3 and 4).

MANAGEMENT (MEDICAL/INTERVENTIONS)

The patient was classified as New York Heart Association Heart Failure Severity Class I and International Society for Heart and Lung Transplantation Heart Failure Stage B (1). Cardiothoracic surgery was consulted, but surgery was deferred (preference of both the patient's parents and the surgical team) in view of the large size of the aneurysm and high risk of

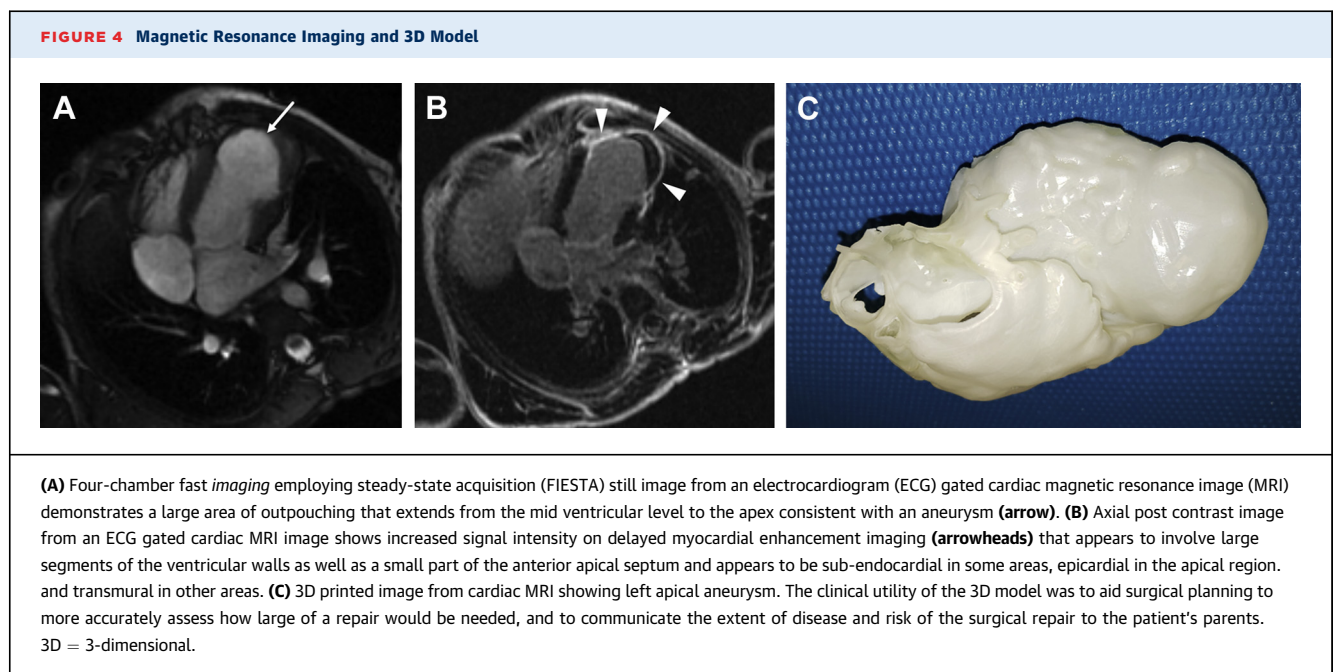
operative mortality. He was started on anti-coagulation and was restricted from isometric activity and competitive sports (2).

DISCUSSION

Penetrating injuries of the thorax and abdomen, such as gunshot and stabbing, are rare in children (3-5). The most commonly affected organs by penetrating firearm injury in children are the small bowel, colon, liver, and stomach followed by the spleen, kidney, and pancreas (6).

Trauma is the leading cause of death and long-term disability in the pediatric population. Recent studies have shown that mortality due to thoracic trauma was greater than for abdominal trauma, and thoracic trauma was second only to head injuries as a cause of death in children (7). Penetrating thoracic trauma can cause hemothorax and/or pneumothorax. Initial evaluation can include electrocardiogram, echocardiogram, and contrast-enhanced CT. Injury to the great vessels can be associated with significant complications and should be monitored closely for ischemic complications.

Although CT is the gold standard for initial imaging after ballistic injury, cardiac MRI may be performed to assess the extent of complications, such as pseudoaneurysm, and for follow-up imaging to decrease ionizing radiation. MRI is not absolutely contraindicated in patients with retained ballistic fragments, but must be used with caution.



LVAs are rare in the pediatric population, and those arising from prior traumatic myocardial injury are even more so. True aneurysms can be congenital or acquired. Congenital causes include intrinsic abnormalities in the embryogenesis of the muscular ventricular wall, ischemia secondary to congenital coronary stenosis or hypoplasia, or viral infection. Acquired causes include blunt trauma, myocardial infarction, infection, and as a complication of cardiovascular surgery. The most common cause of acquired aneurysms in pediatrics is blunt-force trauma. Most aneurysms following blunt-force trauma are true aneurysms, whereas pseudoaneurysms typically occur following penetrating trauma. Typical findings of a true ventricular aneurysm using cardiac MRI include intact epicardial fat, a neck/body-width ratio >0.9 , and hyperenhancement within the wall of the aneurysm on delayed gadolinium enhancement (8).

Pseudoaneurysm is an encapsulated pulsating hematoma that develops secondary to a local defect in the arterial wall. LV pseudoaneurysms occur rarely, especially during childhood. The most common causes are myocardial infarction, cardiac surgery, trauma, and endocarditis. A pseudoaneurysm contains no endocardium or myocardium and has a high risk of rupture. The natural history of pseudoaneurysm is continuous expansion and eventually rupture. Other than rupture, late complications of untreated pseudoaneurysm include mass effect on adjacent structures or, less commonly, infection and peripheral embolism (9).

Echocardiography is often the first-line imaging test used to evaluate LVAs. It is inexpensive, quick, can be performed portably, and has excellent temporal resolution; however, evaluation can be difficult if acoustic windows are limited. Both true and false aneurysms will appear as thin-walled, dilated anechoic outpouchings which lack contractility. Compared with true aneurysms, pseudoaneurysms have a characteristically narrow neck. A neck-to-aneurysm diameter ratio of >0.5 is suggestive of a true aneurysm, whereas a narrow neck-to-aneurysm ratio <0.5 is more suggestive of a pseudoaneurysm, although this single parameter should not be solely relied on in isolation (10). The true aneurysm is thinner than the wall of the rest of the LV and is usually composed of fibrous tissue as well as necrotic muscle. True aneurysms typically have a wide neck.

There are limited data regarding long-term outcomes and management of traumatic LVAs in children, with most of the studies in patients with LVA having been performed in the adult population (11). Complications of LVA are generally more common with large aneurysms. They include ventricular arrhythmias, congestive heart failure, angina pectoris, and thromboembolism. Rupture of LV true aneurysm is extremely rare unless reinfarction occurs at the border of the aneurysm. The incidence of spontaneous true aneurysm rupture in the adult literature is low in comparison with pseudoaneurysms, which have up to a 30% to 45% chance of rupture and require more urgent surgical intervention (12). Arrhythmia can be seen in one-third of patients with LVA. Congestive heart failure occurs in 29% of patients with LVA. Recurrent MI can occur in approximately 25% of patients with LVA (13).

FOLLOW-UP

The patient is asymptomatic from a cardiovascular standpoint according to the most recent visit with the pediatric cardiologist, and does not have any exercise intolerance.

CONCLUSIONS

We present a very uncommon case of delayed LVA formation from a gunshot wound in a young child. This case illustrates the typical imaging findings of ventricular aneurysms in children. In cases of penetrating ballistic thoracic trauma such as this, the radiologist should be involved in the discussion of how to image the patient safely and effectively. Clinical management is often challenging, and discussions with the patient's family need to take into account the high rates of both operative and nonoperative delayed mortality.

AUTHOR DISCLOSURES

The authors have reported that they have no relationships relevant to the contents of this paper to disclose.

ADDRESS FOR CORRESPONDENCE: Dr. Achala Donuru, Department of Radiology, Thomas Jefferson University Hospitals, 132 S. 10th Street, 1079 Main Building, Philadelphia, Pennsylvania 19107, USA. E-mail: achala.donuru@jefferson.edu.

REFERENCES

1. Hunt SA. ACC/AHA 2005 guideline update for the diagnosis and management of chronic heart failure in the adult: a report of the American College of Cardiology/American Heart Association Task Force on Practice Guidelines (Writing Committee to Update the 2001 Guidelines for the Evaluation and Management of Heart Failure). *J Am Coll Cardiol* 2005;46:e1-82.
2. Pelliccia A, Fagard R, Bjørnstad HH, et al. Recommendations for competitive sports participation in athletes with cardiovascular disease: a consensus document from the Study Group of Sports Cardiology of the Working Group of Cardiac Rehabilitation and Exercise Physiology and the Working Group of Myocardial and Pericardial Diseases of the European Society of Cardiology. *Eur Heart J* 2005;26:1422-45.
3. Eber GB, Annet JL, Mercy JA, Ryan GW. Nonfatal and fatal firearm-related injuries among children aged 14 years and younger: United States, 1993-2000. *Pediatrics* 2004;113:1686-92.
4. Powell EC, Jovtis E, Tanz RR. Incidence and circumstances of nonfatal firearm-related injuries among children and adolescents. *Arch Pediatr Adolesc Med* 2001;155:1364-8.
5. Miller M, Azrael D, Hemenway D, Vriniotis M. Firearm storage practices and rates of unintentional firearm deaths in the United States. *Accid Anal Prev* 2005;37:661-7.
6. Renz BM, Feliciano DV. Gunshot wounds to the right thoracoabdomen: a prospective study of nonoperative management. *J Trauma* 1994;37:737-44.
7. Cooper A, Barlow B, DiScala C, String D. Mortality and truncal injury: the pediatric perspective. *J Pediatr Surg* 1994;29:33-8.
8. Kumbasar B, Wu KC, Kamel IR, Lima JAC, Bluemke DA. Left ventricular true aneurysm: diagnosis of myocardial viability shown on MR imaging. *AJR Am J Roentgenol* 2002;179:472-4.
9. Hulten EA, Blankstein R. Pseudoaneurysms of the heart. *Circulation* 2012;125:1920-5.
10. Bisoyi S, Dash AK, Nayak D, Sahoo S, Mohapatra R. Left ventricular pseudoaneurysm versus aneurysm a diagnosis dilemma. *Ann Card Anaesth* 2016;19:169.
11. Brock MA, Co-Vu J, Bleiweis MS, Reyes K, Shih RS. Left ventricular aneurysm following blunt-force trauma in a child. *CASE (Phila)* 2019;3:39.
12. Inayat F, Ghani AR, Riaz I, et al. Left ventricular pseudoaneurysm: an overview of diagnosis and management. *J Investig Med High Impact Case Rep* 2018;6:2324709618792025.
13. Ba'albaki HA, Clements SD Jr. Left ventricular aneurysm: a review. *Clin Cardiol* 1989;12:5-13.

KEY WORDS echocardiography, left ventricular pseudoaneurysm, true left ventricular aneurysm

APPENDIX For supplemental videos, please see the online version of this paper.