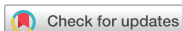

Case Report
Infectious Disease



Acute-onset respiratory signs in a Labrador Retriever with a positive SARS-CoV-2 rapid antigen test and infection confirmed by RT-PCR analysis: a case report

Mark Gosling *, Jessica Bacon 

Wear Referrals, Bradbury, Stockton-on-Tees, County Durham, TS21 2ES, England

 OPEN ACCESS

Received: Apr 27, 2022

Revised: Jul 31, 2022

Accepted: Aug 16, 2022

Published online: Sep 6, 2022

*Corresponding author:

Mark Gosling

Wear Referrals, Bradbury, Stockton-on-Tees,
County Durham, TS21 2ES, England.

Email: markgosling1@googlemail.com

<https://orcid.org/0000-0001-9197-9741>

ABSTRACT

A 10-year-old male neutered Labrador Retriever presented with a history of acute-onset tachypnoea, lethargy and anorexia. The dog was pyrexia, tachypnoeic and dyspnoeic on examination. A rapid antigen test for severe acute respiratory syndrome coronavirus-2 (SARS-CoV-2) was performed on an oropharyngeal swab and yielded a positive result. SARS-CoV-2 infection was subsequently confirmed by reverse transcription polymerase chain reaction (RT-PCR) analysis. Both of the dog's owners had positive rapid antigen test and RT-PCR analysis results for SARS-CoV-2. Additional diagnostics included computed tomography. Resolution of the dog's clinical signs was achieved with symptomatic treatment.

Keywords: SARS-CoV-2; antigen; dog; case report

INTRODUCTION

The ongoing pandemic of severe acute respiratory syndrome coronavirus-2 (SARS-CoV-2) was first reported in humans in Wuhan, China, in 2019 [1] and at the time of writing has caused in excess of six million fatalities in people [2]. Dogs can be infected with SARS-CoV-2 and human-to-canine transmission of the virus is a recognised route of infection [3-5]. Clinical signs in dogs can include respiratory abnormalities such as coughing and dyspnoea [5]. Tools for the diagnosis of SARS-CoV-2 infection in humans include rapid antigen testing and reverse transcription polymerase chain reaction (RT-PCR) analysis, with the latter representing the current diagnostic test of choice for confirming infection [6].

CASE PRESENTATION

A 10-year-old male neutered Labrador Retriever presented in October 2021 for non-elective re-examination four weeks following surgical excision of an invasive thymoma. On the day of examination acute-onset tachypnoea and lethargy had been observed by the owners, preceded by a 24-hour history of hyporexia. Prior to this, the dog had been recovering uneventfully from surgery. The only current medication was meloxicam. Both of the dog's

© 2022 The Korean Society of Veterinary Science

This is an Open Access article distributed under the terms of the Creative Commons Attribution Non-Commercial License (<https://creativecommons.org/licenses/by-nc/4.0>) which permits unrestricted non-commercial use, distribution, and reproduction in any medium, provided the original work is properly cited.

ORCID iDs

Mark Gosling

<https://orcid.org/0000-0001-9197-9741>

Jessica Bacon

<https://orcid.org/0000-0002-2217-1500>**Author Contributions**

Writing - original draft: Gosling M; Writing - review & editing: Bacon J.

Conflict of Interest

The authors declare no conflicts of interest.

owners volunteered the information that they had tested positive that day for SARS-CoV-2 on rapid antigen testing, and this infection was subsequently confirmed via RT-PCR analysis.

On presentation the dog was subdued and tachypnoeic (respiratory rate 60 breaths/min) with mild dyspnoea. He was also pyrexia (rectal temperature 40.8°C). Thoracic auscultation was unremarkable and no additional concerns were identified on physical examination. Intermittent coughing was observed following admission to the hospital.

The dog was anaesthetised and an oropharyngeal swab was obtained for a rapid SARS-CoV-2 antigen test (Xiamen Biotime Biotechnology Co., Ltd., China). This test result was positive (**Fig. 1**). Computed tomography (CT) of the thorax was performed and showed multifocal increased attenuation of the pulmonary parenchyma, pleural effusion and pleuritis. Thoracocentesis and cytologic examination of the pleural fluid was most consistent with a non-septic inflammatory effusion. Oropharyngeal, conjunctival and rectal swabs were submitted for SARS-CoV-2 RT-PCR testing. The oropharyngeal swab was positive for SARS-CoV-2 RNA (E and RdRp genes) (**Fig. 2**).

Following diagnostics the patient was hospitalised in an isolation ward. Initially the following products were administered intravenously: Hartmann's solution (2.5 mL/kg/h), paracetamol (10 mg/kg q8h), dexamethasone (0.1 mg/kg q24h), clavulanate amoxicillin (20 mg/kg q8h), omeprazole (1 mg/kg q12h). Within 12 h of commencing this treatment the pyrexia had resolved (rectal temperature consistently in the range of 38.4–38.7°C). By 36 h post-admission the tachypnoea was persistent (44–60 breaths/min) but the dyspnoea had resolved. The patient was discharged from hospital approximately 48 h following admission. A graph showing the changes in respiratory rate and rectal temperature from the point of admission to the time of discharge is displayed in **Fig. 3**. At the time of discharge the patient had been transitioned onto oral medications: paracetamol (12.5 mg/kg q8h for five days), fenbendazole (47 mg/kg q24h for five days), clavulanate amoxicillin (18.75 mg/kg q8h for three weeks), omeprazole (1 mg/kg q12h for three days).



Fig. 1. Positive severe acute respiratory syndrome coronavirus-2 rapid antigen test from oropharyngeal swab.

APHA ID	Sample	SARS-CoV-2 E gene Cq-values	SARS-CoV-2 RdRp gene Cq-values	Outcome
M011-21-01	Pharyngeal swab in media 29/10	24.29 and 24.33	30.32 and 30.28	Positive
M011-21-02	Rectal swab	No Cq and No Cq	No Cq and No Cq	Negative
M011-21-03	Rectum swab 29/10	No Cq and No Cq	No Cq and No Cq	Negative
M011-21-04	Conjunctival swab 29/10	No Cq and No Cq	No Cq and No Cq	Negative

Fig. 2. Reverse transcription polymerase chain reaction results from oropharyngeal, rectal and conjunctival swab analysis. SARS-CoV-2, severe acute respiratory syndrome coronavirus-2.

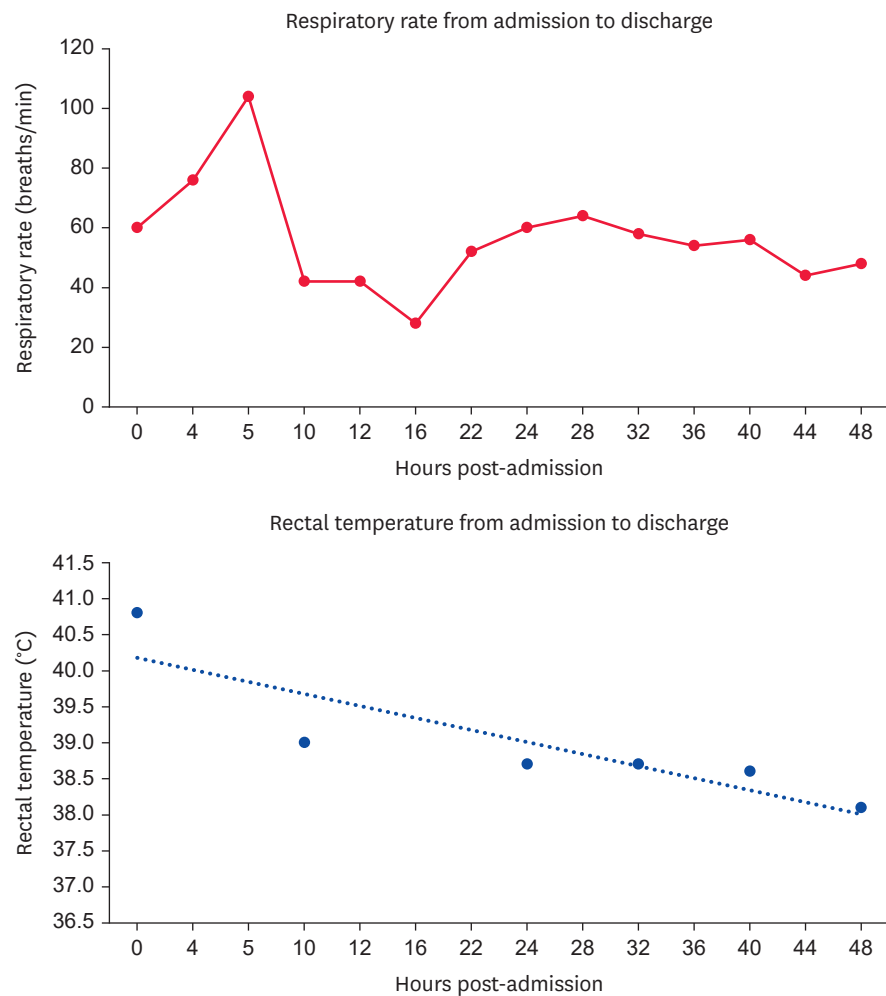


Fig. 3. Trends in respiratory rate and rectal temperature from the point of admission to discharge from the hospital.

At four days following discharge from hospital the owner reported a significant improvement in the dog's tachypnoea and general demeanour. By six days the tachypnoea had resolved and the frequency of coughing was reduced. At one month following discharge the dog's respiratory rate and effort were sustainably normal and only occasional episodes of coughing were reported by the owner.

The dog presented for orthopaedic examination four and a half months following discharge, at which time the owners reported that the respiratory signs had fully resolved. Auscultation of the thorax was unremarkable. Thoracic CT was performed as part of staging investigations for a potential joint neoplasm; the previously identified pulmonary parenchymal changes had resolved, the pleural effusion had resolved and there was a small soft tissue mass in the caudoventral mediastinum.

DISCUSSION

This case report describes a dog with a household history of SARS-CoV-2 infection, acute respiratory signs and a positive rapid antigen test subsequently confirmed by RT-PCR analysis.

The dog reported here presented with non-specific clinical signs. Given the history of recent surgery (thymoma excision via median sternotomy) the most likely differential at that time was a clinically-significant volume of septic or aseptic pleural effusion. Other differentials for acute onset tachypnoea and dyspnoea include but are not limited to; infectious bronchopneumonia, non-cardiogenic pulmonary oedema, pulmonary thromboembolism, pulmonary hypertension, cardiogenic pulmonary oedema, pneumothorax and neoplasia. A rapid antigen test for SARS-CoV-2 was performed predominantly because the owners of the dog volunteered the information that they were symptomatic for SARS-CoV-2 and had both yielded positive rapid antigen tests that day. Informed owner consent was obtained to perform a diagnostic test on the dog that was not validated for use in this species.

Rapid antigen tests are readily available in the UK and have been validated in humans as a quick and relatively accurate method for screening for SARS-CoV-2 infection [7]. An early diagnosis of SARS-CoV-2 in this case had the potential to avoid unnecessary further tests for the patient and to clarify the requirement for ongoing barrier nursing and isolation to protect veterinary staff. Although the role of animal-to-human transmission of SARS-CoV-2 is unclear, the potential for human infection from an actively infected dog cannot be excluded. RT-PCR testing was only performed following discussion with an advisor from the UK Animal & Plant Health Agency, who issue advice to UK veterinarians on testing for SARS-CoV-2 in animals [8]. The reporting virologist commented that the result in this case most likely reflected active infection rather than contamination from the dog's immediate environment.

Possible risk factors for infection with SARS-CoV-2 in this dog included older age and having a history of recent major surgery, as well as close contact with infected humans in the household [3-5].

Interpretation of the CT scans for this patient was complicated by the history of recent surgery. Given the invasive nature of the previously-excised thymoma and the degree of pleuritis identified at surgery it was felt that the pleural effusion present at the time of the first recheck scan (which was subjectively a mild-moderate volume) was most likely secondary to resolving pleuritis. Potential causes of the pulmonary parenchymal changes included SARS-CoV-2 infection, fibrosis following the recent surgery, pneumonia or atelectasis. These pulmonary changes had resolved at the time of the last CT scan. In this patient coughing was reported as one of the presenting signs at the time of thymoma diagnosis, though this was noted to have resolved over the initial four weeks following surgery.

One of the limitations of this case report was that screening tests for more common inflammatory and infectious causes of canine respiratory disease were not performed. Given the household history, the positive rapid antigen test, it was not felt that extensive further testing would have likely changed the treatment plan.

The treatment for this dog was supportive/symptomatic and included anti-pyretic and antibiotic medications. A beta lactam antimicrobial was prescribed based upon previous recommendations for the treatment of suspected bacterial pneumonia in dogs without evidence of systemic sepsis [9]. Dexamethasone was administered as use of this drug has been associated with a reduced 28-day mortality rate in hospitalised people with SARS-CoV-2 infection [10]. A course of fenbendazole was also prescribed as a therapeutic trial in

case parasitic pulmonary disease was contributing to the clinical signs. Omeprazole was administered due to the short time interval between cessation of meloxicam therapy and the start of corticosteroid therapy.

The limited number of canine cases reported in the veterinary literature means that the prognosis for dogs with respiratory signs caused by SARS-CoV-2 has not been well-defined. This patient had a significant improvement in clinical signs over the 48 h of hospital treatment and a resolution of clinical signs by the time of the last follow-up four and a half months later.

In conclusion, the use of a SARS-CoV-2 rapid antigen test led to changes in the diagnostic and management plans for this dog with acute-onset respiratory signs and SARS-CoV-2 positive owners. This had potential benefits for both the patient and for the veterinary staff caring for the dog. Generalised advice and conclusions regarding the use of rapid antigen testing in dogs cannot be drawn from a single case report, but the information presented here may be interesting for veterinarians in clinical practice who find themselves presented with similar cases.

ACKNOWLEDGEMENTS

The authors would like to acknowledge the diagnostic advice and assistance given by the UK Animal and Plant Health Agency (One Health Advice Service).

REFERENCES

1. Zhu N, Zhang D, Wang W, Li X, Yang B, Song J, et al. A novel coronavirus from patients with pneumonia in China, 2019. *N Engl J Med*. 2020;382(8):727-733.
[PUBMED](#) | [CROSSREF](#)
2. World Health Organization. WHO Coronavirus (COVID-19) Dashboard [Internet]. Geneva: World Health Organization; <https://covid19.who.int>. Updated 2022. Accessed 2022 April 4.
3. Calvet GA, Pereira SA, Ogrzewalska M, Pauvolid-Corrêa A, Resende PC, Tassinari WS, et al. Investigation of SARS-CoV-2 infection in dogs and cats of humans diagnosed with COVID-19 in Rio de Janeiro, Brazil. *PLoS One*. 2021;16(4):e0250853.
[PUBMED](#) | [CROSSREF](#)
4. Sit TH, Brackman CJ, Ip SM, Tam KW, Law PY, To EM, et al. Infection of dogs with SARS-CoV-2. *Nature*. 2020;586(7831):776-778.
[PUBMED](#) | [CROSSREF](#)
5. Miró G, Regidor-Cerrillo J, Checa R, Diezma-Díaz C, Montoya A, García-Cantalejo J, et al. SARS-CoV-2 infection in one cat and three dogs living in COVID-19 positive households in Madrid, Spain. *Front Vet Sci*. 2021;8:779341.
[PUBMED](#) | [CROSSREF](#)
6. Kevadiya BD, Machhi J, Herskovitz J, Oleynikov MD, Blomberg WR, Bajwa N, et al. Diagnostics for SARS-CoV-2 infections. *Nat Mater*. 2021;20(5):593-605.
[PUBMED](#) | [CROSSREF](#)
7. Peto T, Affron D, Afrough B, Agasu A, Ainsworth M, Allanson A, et al. COVID-19: rapid antigen detection for SARS-CoV-2 by lateral flow assay: a national systematic evaluation of sensitivity and specificity for mass-testing. *EClinicalMedicine*. 2021;36:100924.
[PUBMED](#) | [CROSSREF](#)
8. Animal & Plant Health Agency. APHA Briefing Note 09/21. SARS-CoV-2 in Animals - Case Definition, Testing and International Reporting Obligations [Internet]. <http://apha.defra.gov.uk/documents/ov/Briefing-Note-0921.pdf>. Updated 2021. Accessed April 4, 2022.

9. Lappin MR, Blondeau J, Boothe D, Breitschwerdt EB, Guardabassi L, Lloyd DH, et al. Antimicrobial use guidelines for treatment of respiratory tract disease in dogs and cats: antimicrobial guidelines working group of the International Society for Companion Animal Infectious Diseases. *J Vet Intern Med.* 2017;31(2):279-294.
[PUBMED](#) | [CROSSREF](#)
10. Horby P, Lim WS, Emberson JR, Mafham M, Bell JL, Linsell L, et al. Dexamethasone in hospitalised patients with COVID-19. *N Engl J Med.* 2021;384(8):693-704.
[PUBMED](#) | [CROSSREF](#)