

THERAPEUTIC HOTLINE

Combination of everolimus and tacrolimus: a potentially effective regimen for recalcitrant psoriasis

KAI-CHE WEI* & PING-CHIN LAI†‡

**Department of Dermatology, Kaohsiung Veterans General Hospital, Kaohsiung, †Department of Nephrology, Kidney Institute, Chang Gung Memorial Hospital, Linkou and ‡College of Medicine, Chang Gung University, Taoyuan, Taiwan*

ABSTRACT: Severe forms of psoriasis that are refractory to conventional therapies are often difficult to manage. The mammalian target of rapamycin (mTOR) inhibitors potentially have versatile effects toward putative psoriatic pathologic pathways. Therefore, mTOR inhibitors may offer a range of new therapeutic options for patients with psoriasis. We describe a 55-year-old male renal transplant patient with refractory psoriasis. We adjusted his antirejection regimen and put him on everolimus (Certican®; Novartis, Basel, Switzerland; a semisynthetic macrolide, belonging to the mTOR inhibitors family) with low-dose tacrolimus. This combination regimen maintained his graft function and successfully controlled his psoriasis. His skin lesions never recurred in the next 18 months. To our knowledge, this is the first report showing that the combination of everolimus and tacrolimus could be used to treat recalcitrant psoriasis. The relative benefit–risk profiles of such therapies worth further investigation.

KEYWORDS: everolimus, mTOR inhibitor, psoriasis, tacrolimus

Introduction

Psoriasis is a common chronic relapsing papulosquamous inflammatory skin disease with complex pathophysiology (1–3). Systemic thera-

peutic agents used for the management of psoriasis commonly target the underlying inflammation pathways. Phototherapy, retinoids, and immunosuppressive agents (such as methotrexate and cyclosporine), have all been prescribed clinically in the treatment of psoriasis with variable adverse effects. However, severe forms of psoriasis that are refractory to these therapies are often difficult to manage.

In recent years, biologic agents that selectively block steps in the inflammatory cascade (such as tumor necrosis factor- α , interleukin (IL)-22/23, Th-17) have provided additional therapeutic options for psoriasis treatment. These new developments have led to a better understanding of immunologic and pathophysiologic mechanisms underlying psoriasis. However, severe

Address correspondence and reprint requests to: Ping-Chin Lai, M.D. Ph.D., Consultant Physician, Department of Nephrology, Kidney Institute, Chang Gung Memorial Hospital, No.5 Fu-Shing Street, Gueishan, Taoyuan 333, Taiwan, or email: pclai@adm.cgmh.org.tw.

Both authors have no conflict of interest.

This is an open access article under the terms of the Creative Commons Attribution-NonCommercial-NoDerivs License, which permits use and distribution in any medium, provided the original work is properly cited, the use is non-commercial and no modifications or adaptations are made.

infections and the formation of antidrug auto-antibodies are not uncommon (4–6). The long-term safety of these biologic agents is still unresolved. Therefore, exploring novel treatment is worth trying.

Everolimus (Certican[®], Novartis, Basel, Switzerland), is a semisynthetic macrolide, belonging to the mammalian target of rapamycin (mTOR) inhibitors family. Although structurally similar to tacrolimus, it has different immunosuppressive mechanisms. It exerts its antiproliferative and immunosuppressive activities by inhibiting the IL-2 receptor-mediated signal transduction pathway with no effect on calcineurin activity. Clinically, mTOR inhibitors have been used in antirejection regimen in solid organ transplant as well as in anticancer therapy. The action of mTOR and calcineurin inhibitors, including cyclosporine and tacrolimus, is complementary and synergistic. The mTOR inhibitors have been used to treat dermatologic diseases, such as tuberous sclerosis, Kaposi sarcoma, neurofibromatosis, and Muir-Torre syndrome (7,8). Moreover, their effect in psoriasis has been described in several sporadic case reports (9–11).

Herein, we describe a renal transplant patient with refractory psoriasis, who was unresponsive to topical steroid therapies. We adjusted his antirejection regimen and put him on everolimus with low-dose tacrolimus. This combination regimen not only maintained his graft function, but also successfully controlled his psoriasis.

Case report

A 55-year-old man had a 37-year history of psoriasis and gouty arthritis, and a 4-year history of diabetes mellitus and chronic kidney disease. He received cadaveric kidney transplantation after 3 years of regular hemodialysis. Post-transplantation, his graft functioned immediately under immunosuppressive regimen composed of tacrolimus 0.08 mg/kg/day and prednisolone 5 mg/day. There was no acute rejection episode. One month after operation, his serum creatinine (sCr) was 0.99 mg/dL and his blood urea nitrogen was 11.2 mg/dL.

His psoriasis was diagnosed when he was 18 years old and the symptoms were off and on, but became severe and refractory to topical treatment including steroid and polytar after he gained weight (body mass index: 27.1). Oral steroid and retinoid acid treatments were prescribed to

control his psoriatic lesions. Before transplantation, his psoriasis was in complete remission. Two months after transplantation, multiple irritating erythematous nodules appeared on his trunk and limbs (FIG. 1a). Psoriasis relapse was diagnosed and topical corticosteroid was applied. This treatment was continued for 1 month. No further immunosuppressive agent was suggested as he was already on antirejection regimen for kidney transplantation. However, his lesions progressed. At that time, his laboratory data were as follows: white blood cell count 3900/L, hemoglobin 11.0 g/dL, platelet 171000/L, blood urea nitrogen 23.9 mg/dL, sCr 1.22 mg/dL, fasting sugar 91 mg/dL, aspartate aminotransferase (AST) 22U/L, alanine aminotransferase (ALT) 15 U/L, serum potassium 4.6 meq/L, uric acid 5.6 mg/dL, and plasma tacrolimus 4.8 ng/mL. We thus decided to change his immunosuppressive regimen from tacrolimus to everolimus base. To do this, tacrolimus dosage was reduced by 50% overnight and everolimus 1.5 mg/day was added on the same day. His tacrolimus dosage was tapered gradually to 0.5 mg/day over the next 2 months and prednisolone dosage was kept at 5 mg/day throughout the course. Two weeks after this regimen adjustment, his skin lesions subsided gradually. Importantly, his renal graft function returned to his baseline and sCr was 0.99 mg/dL. The plasma everolimus level was 3.06 ng/mL. His skin lesions never recurred in the next 18 months during regular follow-up (FIG. 1b).

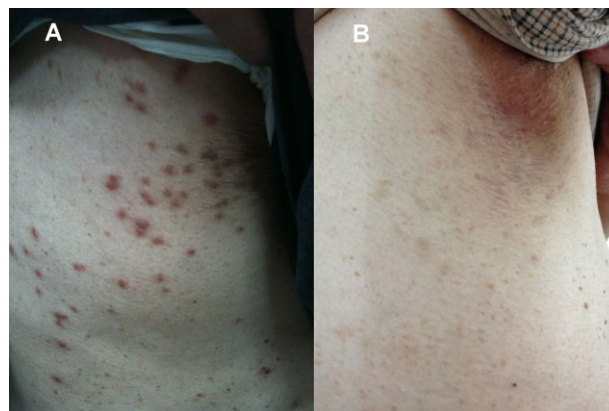


FIG. 1. (A) Multiple recalcitrant well-demarcated erythematous nodules were found in the patient, who had received kidney transplantation 2 months ago. (B) Skin lesions rapidly subsided and never recurred in the following 18 months after antirejection regimen changing to everolimus with low-dose tacrolimus.

Discussion

From a clinical perspective, in this case, everolimus led to the resolution of the recalcitrant psoriatic manifestations. It is well known that tacrolimus alone could be used to treat psoriasis, but its effectiveness is no better than that of conventional approach (12). In this patient, the psoriasis relapsed in spite of standard dose tacrolimus treatment for 2 months. More interestingly, it resolved after adding everolimus to the immunosuppressive regimen. We speculated that this could be a result of the synergistic effect of everolimus and tacrolimus. On the other hand, it could also be suggested that everolimus has a more potent therapeutic effect than tacrolimus in controlling psoriatic symptoms.

Unlike other reagents, mTOR inhibitors could potentially have versatile effects toward putative psoriatic pathologic pathways. For example, the mTOR inhibitor is able to reduce keratinocyte proliferation and neutrophilic infiltration in a dose-dependent manner (9). It could also decrease vascular endothelial growth factor concentration in the blood and vascular fetal liver kinase 1/kinase insert domain receptor (Flk-1/KDR) receptor on endothelium (13). In keratinocyte culture, mTOR inhibitor partially inhibits tumor necrosis factor- α -induced cytokine production (14). Thus, it is not surprising that mTOR inhibitors could have therapeutic potential on psoriasis treatment. In a psoriatic study, Reitamo, et al. showed that sirolimus combined with subtherapeutic levels of cyclosporine would yield better clinical outcome, but limited nephrotoxicity (9).

Pathologically, tacrolimus inhibits the upstream signal of IL-2-mediated cell proliferation, and mTOR inhibitor blocks it downstream. Therefore, this combination therapy is a logical regimen pharmacologically, and may have a synergistic therapeutic effect. Beneficially, with this combination, we were able to reduce the dose of both everolimus and tacrolimus, thus resulting in less adverse effects while achieving better therapeutic effects. To our knowledge, this is the first report showing that the combination of everolimus and tacrolimus could be used to treat recalcitrant psoriasis.

Conclusion

Compared with other immunosuppressants, mTOR inhibitors have demonstrated less risk for

lymphoproliferative, neurologic, hepatic, and renal complications. mTOR inhibitors may offer a range of new therapeutic options for patients with psoriasis; and, the relative benefit–risk profiles of such therapies worth further investigation.

References

1. Griffiths CE, Barker JN. Pathogenesis and clinical features of psoriasis. *Lancet* 2007; **370**: 263–271.
2. Nestle FO, Kaplan DH, Barker J. Psoriasis. *N Engl J Med* 2009; **361**: 496–509.
3. Nakajima K. Critical role of the interleukin-23/T-helper 17 cell axis in the pathogenesis of psoriasis. *J Dermatol* 2012; **39**: 219–224.
4. Grijalva CG, Chen L, Delzell E, et al. Initiation of tumor necrosis factor- α antagonists and the risk of hospitalization for infection in patients with autoimmune diseases. *JAMA* 2011; **306**: 2331–2339.
5. Perrier C, Rutgeerts P. Cytokine blockade in inflammatory bowel diseases. *Immunotherapy* 2011; **3**: 1341–1352.
6. Igarashi A, Kato T, Kato M, et al. Efficacy and safety of ustekinumab in Japanese patients with moderate-to-severe plaque-type psoriasis: long-term results from a phase 2/3 clinical trial. *J Dermatol* 2012; **39**: 242–252.
7. Foster RS, Bint LJ, Halbert AR. Topical 0.1% rapamycin for angiofibromas in paediatric patients with tuberous sclerosis: a pilot study of four patients. *Australas J Dermatol* 2012; **53**: 52–56.
8. Paghдал KV, Schwartz RA. Sirolimus (rapamycin): from the soil of Easter Island to a bright future. *J Am Acad Dermatol* 2007; **57**: 1046–1050.
9. Reitamo S, Spuls P, Sassolas B, et al. Efficacy of sirolimus (rapamycin) administered concomitantly with a subtherapeutic dose of cyclosporin in the treatment of severe psoriasis: a randomized controlled trial. *Br J Dermatol* 2001; **145**: 438–445.
10. Ormerod AD, Shah SA, Copeland P, et al. Treatment of psoriasis with topical sirolimus: preclinical development and a randomized, double-blind trial. *Br J Dermatol* 2005; **152**: 758–764.
11. Frigerio E, Colombo MD, Franchi C, et al. Severe psoriasis treated with a new macrolide: everolimus. *Br J Dermatol* 2007; **156**: 372–374.
12. Jegasothy BV, Ackerman CD, Todo S, et al. Tacrolimus (FK 506) – a new therapeutic agent for severe recalcitrant psoriasis. *Arch Dermatol* 1992; **128**: 781–785.
13. Guba M, von Breitenbuch P, Steinbauer M, et al. Rapamycin inhibits primary and metastatic tumor growth by antiangiogenesis: involvement of vascular endothelial growth factor. *Nat Med* 2002; **8**: 128–135.
14. Young CN, Koepke JI, Terlecky LJ, et al. Reactive oxygen species in tumor necrosis factor- α -activated primary human keratinocytes: implications for psoriasis and inflammatory skin disease. *J Invest Dermatol* 2008; **128**: 2606–2614.