

# BMJ Open A diagnostic cohort study on the accuracy of 18-fluorodeoxyglucose (<sup>18</sup>FDG) positron emission tomography (PET)-CT for evaluation of malignancy in anterior mediastinal lesions: the DECiMaL study

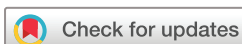Chiara Proli,<sup>1</sup> Paulo De Sousa,<sup>1</sup> Simon Jordan,<sup>1</sup> Vladimir Anikin,<sup>1</sup> Anand Devaraj,<sup>1</sup> Susannah M Love,<sup>2</sup> Michael Shackcloth,<sup>2</sup> Nikolaos Kostoulas,<sup>3</sup> Kostas Papagiannopoulos,<sup>3</sup> Yama Haqzad,<sup>4</sup> Mahmoud Loubani,<sup>4</sup> Francesco Sellitri,<sup>5</sup> Felice Granato,<sup>5</sup> Alexander Bush,<sup>6</sup> Adrian Marchbank,<sup>6</sup> Swetha Iyer,<sup>7</sup> Marco Scarci,<sup>7</sup> Eric Lim,<sup>1</sup> on behalf of the UK Thoracic Surgery Research Collaborative

**To cite:** Proli C, De Sousa P, Jordan S, *et al*. A diagnostic cohort study on the accuracy of 18-fluorodeoxyglucose (<sup>18</sup>FDG) positron emission tomography (PET)-CT for evaluation of malignancy in anterior mediastinal lesions: the DECiMaL study. *BMJ Open* 2018;**8**:e019471. doi:10.1136/bmjopen-2017-019471

► Prepublication history for this paper is available online. To view these files, please visit the journal online (<http://dx.doi.org/10.1136/bmjopen-2017-019471>).

IASLC 17th World Conference on Lung Cancer, 4-7 December 2016, Vienna, Austria and the 2017 Annual Meeting of the Society for Cardiothoracic Surgery, 12-14 March 2017, Belfast, UK

Received 6 September 2017  
Revised 11 December 2017  
Accepted 14 December 2017



For numbered affiliations see end of article.

**Correspondence to**  
Eric Lim;  
[eric.lim@imperial.ac.uk](mailto:eric.lim@imperial.ac.uk)

## ABSTRACT

**Objectives** The aim of this study is to collate multi-institutional data to determine the value by defining the diagnostic performance of fluorodeoxyglucose positron emission tomography (FDG PET)/CT for malignancy in patients undergoing surgery with an anterior mediastinal mass in order to ascertain the clinical utility of PET/CT to differentiate malignant from benign aetiologies in patients presenting with an anterior mediastinal mass

**Setting** DECiMaL Study is a multicentre, retrospective, collaborative cohort study in seven UK surgical sites.

**Participants** Between January 2002 and June 2015, a total of 134 patients were submitted with a mean age (SD) of 55 years (16) of which 69 (51%) were men. We included all patients undergoing surgery who presented with an anterior mediastinal mass and underwent PET/CT. PET/CT was considered positive for any reported avidity as stated in the official report and the reference was the resected specimen reported by histopathology using WHO criteria.

**Primary and secondary outcome measures** Sensitivity, specificity, positive and negative predicted values of [<sup>18</sup>F]-FDG PET in determining malignant aetiology for an anterior mediastinal mass.

**Results** The sensitivity and specificity of PET/CT to correctly classify malignant disease were 83% (95% CI 74 to 89) and 58% (95% CI 37 to 78). The positive and negative predictive values were 90% (95% CI 83% to 95%) and 42% (95% CI 26% to 61%).

**Conclusions** The results of our study suggest reasonable sensitivity but no specificity implying that a negative PET/CT is useful to rule out the diagnosis of malignant disease whereas a positive result has no value in the discrimination between malignant and benign diseases of the anterior mediastinum.

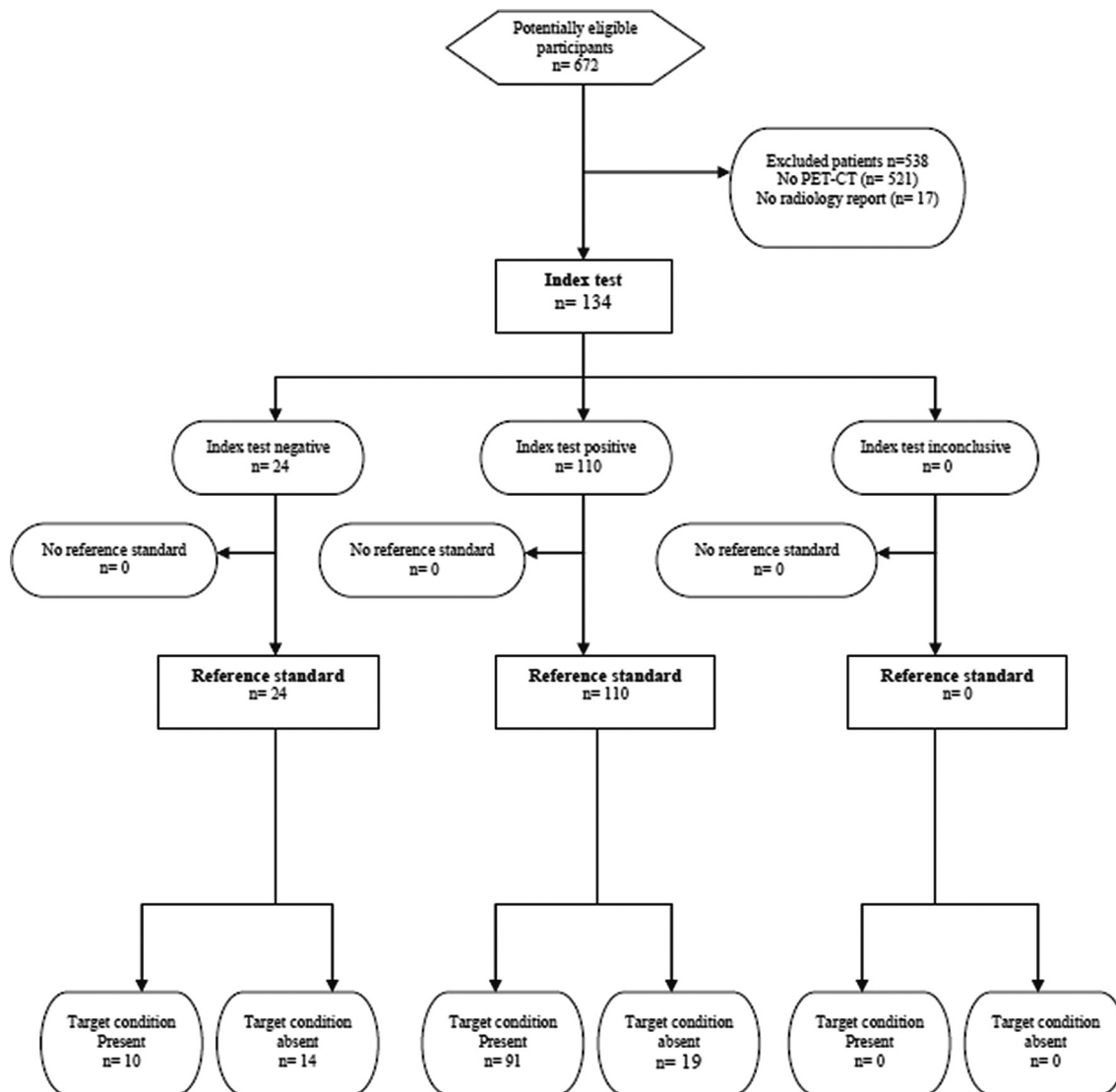
## Strengths and limitations of this study

- To our knowledge, this is the largest study to date (essential to ensure narrow CIs for estimates) versing this subject.
- We were able to obtain an estimate of test performance relatively quickly through an established research collaborative.
- The study did not include the entire spectrum of the anterior mediastinal masses, in particular the small masses that were only kept under surveillance or discharged.

## INTRODUCTION

Abnormalities in the anterior mediastinum are often discovered as an incidental finding. When detected, they often present as a diagnostic challenge as few radiological features are sufficiently discriminatory to guide clinicians on the best course of management. One of the principal considerations is the probability of malignancy, as the perceived risk of cancer guides the recommendation for invasive tissue sampling or excision. Although positron emission tomography (PET)/CT is widely used in this regard, little is known on the diagnostic and clinical test performance of 18F fluorodeoxyglucose ([<sup>18</sup>F]-FDG) PET-CT as no large published series have been reported in the literature.

The aim of our study was to determine the diagnostic accuracy by defining the sensitivity and specificity of <sup>18</sup>FDG PET-CT scans to



**Figure 1** Flow diagram. STARD, Standards for Reporting Diagnostic Accuracy; PET, positron emission tomography.

identify malignancy in patients who have presented with an anterior mediastinal mass.

## METHODS

We conducted a UK-wide multicentre retrospective study under the auspices of the UK Thoracic Surgery Research Collaborative. Formal application was made to the Research Ethics Committee (15/SS/0185) and the outcome was that the study did not require National Health Service ethics review.

We included patients who have undergone surgery for an anterior mediastinal abnormality and received  $^{18}\text{F}$ FDG PET-CT as part of their preoperative workup. We excluded patients in whom a formal histological diagnosis was not obtained or did not have a formal  $^{18}\text{F}$ FDG PET-CT report.

Consecutive patients from January 2002 to June 2015 were identified from seven participating institutions of the UK Thoracic Surgery Research Collaborative through interrogation of electronic records. As a pragmatic study, the index test of  $^{18}\text{F}$ FDG PET-CT was conducted

by consultant radiologists and nuclear medicine physicians according to UK Royal College of Radiologists recommendations.<sup>1</sup> A positive test result was defined as a formally worded 'positive' uptake for the anterior mediastinal mass. The reference standard was the histology of the resected anterior mediastinal mass as conducted by pathologists in accordance with the UK Royal College of Pathologists guidelines and reported according to WHO criteria. Malignancy was defined in accordance with what would influence surgical management including thymic carcinoma, thymoma, lymphoma and any other malignant tumours, and the following diseases were classified as non-malignant: thymic hyperplasia, thymic cyst and 'no malignancy' per histology report.

As the study was undertaken retrospectively, we assumed the results of the histopathology (reference test) would not be available for the readers of the  $^{18}\text{F}$ FDG PET-CT (index test) as surgical resection only occurs after the preoperative investigations. We also have no reason to believe that the reporting pathologists would have access

**Table 1** Demographic characteristics of the cohort and diagnosis classification per histology report

	(n=134)
Mean age (SD)	55 (16)
Male, n (%)	69 (51)
<b>Histology</b>	
Benign, n (%)	33 (25)
Thymic hyperplasia	10 (8)
Thymic cyst	8 (6)
No malignancy	15 (11)
Malignant, n (%)	101 (75)
Thymoma	55 (41)
Other malignant tumours	38 (28)
Thymic carcinoma	8 (6)

to the preoperative  $^{18}\text{F}$ FDG PET-CT reports (although they may have had access to this information on the request forms).

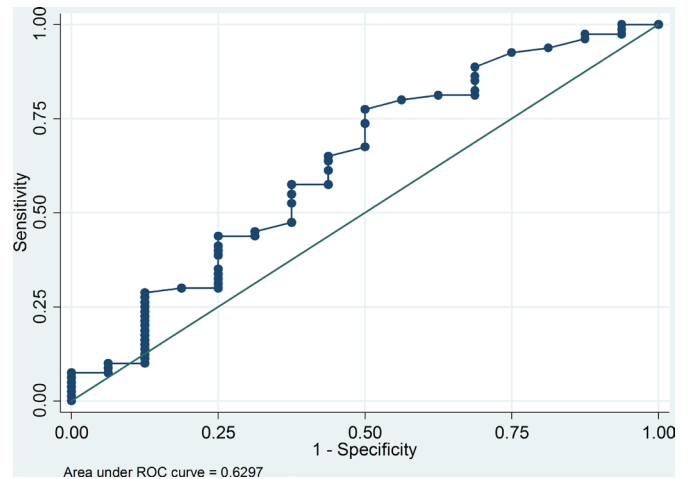
Categorical data were summarised as frequency (%), continuous data summarised as mean (SD) or median (IQR) as appropriate to the data distribution. The primary outcome is the calculated sensitivity, specificity, and positive and negative predictive values with corresponding 95% CIs. We specified a priori estimates around 50% would be considered none, around 75% moderate and around 100% to have excellent clinical test performance and favour interpretation on sensitivity and specificity (considered robust estimates) rather than positive or negative predictive values (that can be altered by disease prevalence). We also conducted secondary analysis of receiver operating characteristic (ROC) curve analyses to explore the influence of SUVmax (where available) on the diagnosis of malignancy.

We estimated a sample size of 70 patients based on estimated sensitivity of 0.90 with a lowest acceptable CI of 0.75 using sample size calculations detailed by Flahault *et al.*<sup>2</sup> Statistical analyses were conducted on Stata V.13 (College Station, Texas, USA).

**Table 2** Diagnostic test performance for PET-CT evaluation of malignancy in an anterior mediastinal mass

	$^{18}\text{F}$ FDG PET-CT positive	$^{18}\text{F}$ FDG PET-CT negative
Benign histology	19	14
Malignant histology	91	10
<b>Test performance (with 95% CI)</b>		
Sensitivity	82.7	74.3 to 89.3
Specificity	58.3	36.6 to 77.9
Positive predictive value	90.1	82.5 to 95.1
Negative predictive value	42.4	25.5 to 60.8

FDG, fluorodeoxyglucose; PET, positron emission tomography.


**Figure 2** Receiver operating characteristic (ROC) plot of SUVmax versus malignancy.

## RESULTS

From January 2002 to June 2015, a total of 672 patients were included of which 521 were excluded due to not having a PET-CT and 17 excluded due to not having radiology report, leaving 134 patients for analysis (figure 1). The mean age (SD) was 55 (16) years (with a range of 18–88 years) of which 69 (51%) were men. The baseline and demographic characteristics of the cohort are summarised in table 1.

Of the 134 patients, 110 had a positive and 24 had a negative  $^{18}\text{F}$ FDG PET-CT report. A malignant diagnosis was reported in 101 patients and a non-malignant diagnosis in 33 patients (table 2).

The sensitivity and specificity of PET-CT to correctly classify malignant disease for anterior mediastinal masses were 83% (95% CI 74 to 89) and 58% (95% CI 37 to 78), respectively, and the corresponding positive and negative predictive values were 90% (95% CI 83 to 95) and 42% (95% CI 26% to 61%), respectively (table 2).

Data from SUVmax were available in 96 patients and the calculated ROC area under the curve was 0.63 (95% CI 0.45 to 0.79) (figure 2).

## DISCUSSION

The results of our study, to our knowledge, are the largest to date (essential to ensure narrow CIs for estimates), and suggest that  $^{18}\text{F}$ FDG PET-CT is moderately useful to rule out the diagnosis of malignancy when the test result is negative (good sensitivity), however, it is not able to rule in the diagnosis of malignancy when the result is positive.

Once an anterior mediastinal mass is diagnosed on imaging, downstream management is predicated on the risk of malignancy to stratify patients for management, with high-risk patients assigned to invasive biopsy or surgery, intermediate-risk patients assigned to surveillance and low-risk patients assigned to discharge. In a recent survey, up to 50% of centres reported the use of PET for this purpose.

In published cohort series, it was reported that thymic tumours represent 50% of anterior mediastinal lesions, followed by lymphomas (25%) and less commonly a mixture of other aetiologies such as teratoma.<sup>3</sup> A definitive diagnosis can only be achieved after invasive biopsy<sup>4</sup> or surgical resection. The reported specificity of fine needle aspiration is limited (57%–82%)<sup>5–7</sup> and the diagnostic values of CT and PET are not well known as few studies have been conducted and with very small sample sizes, typically less than 60.<sup>8</sup> Decisions regarding direct surgical resection of anterior mediastinal masses can be challenging as the morphological features of thymic lesions overlap and a definite differentiation between histological subtypes of thymic pathology by CT can be difficult.<sup>9,10</sup> Previous studies have shown promising results for SUVmax values in the differentiation between malignant and benign lesions.<sup>11</sup> However, the results of our analyses suggested that discrimination by SUVmax was relatively poor.

With moderately high sensitivity, the results from our study suggest that <sup>18</sup>F PET-CT has moderate utility to ruling out malignancy in patients where the test is negative. There is still an appreciable proportion (17%) test negative despite the presence of disease. From a clinical perspective, it remains to individual judgement whether this is an acceptable proportion that balances against the consequences of missing a potentially invasive tumour.

It is difficult to define the clinical utility when faced with an ‘abstract’ figure for sensitivity of 83%; to help clinicians understand how this would fit in the clinical setting, it would be pertinent to look at more developed guidelines on perceived clinical utility of <sup>18</sup>F PET-CT for the solitary pulmonary nodule to assess cancer risk. The results from a 2008 meta-analysis<sup>12</sup> reported a sensitivity of 95% for PET to diagnose malignancy in pulmonary nodules, considerably higher than 83% for anterior mediastinal mass. Despite higher levels of sensitivity, there is still a reluctance for experts to discharge a patient with a negative <sup>18</sup>F PET-CT, as in the 2013 American College of Chest Physicians guidelines<sup>13</sup> the authors recommended serial CT monitoring when the <sup>18</sup>F PET-CT is negative despite low clinical probability of lung cancer.

Currently, there are no established risk models for malignancy in anterior mediastinal masses, and therefore numeric quantification of risk is not possible. In the circumstance where the pretest probability for malignancy is very low (eg, if the CT appearance suggests diffuse enlargement of the thymus only) then it would be reasonable to reassure the patient (a negative <sup>18</sup>F PET-CT would not alter clinical management). If the pretest probability is very high (eg, a large lobulated mass in anterior mediastinum) it would be reasonable to proceed to invasive biopsy or resection (a negative <sup>18</sup>F PET-CT would not reassure). In the most difficult subgroup where the pretest probability for malignancy is intermediate, given that serial CT imaging is recommended for lung cancer (despite sensitivity of

95%) then it would be reasonable to default to the time tested method of screening for growth by CT for anterior mediastinal masses as well. If that is the case, then there is clearly no clinical utility for <sup>18</sup>F PET-CT (a negative test does not prevent serial CTs and a positive test is not reliable to rule in malignancy).

The limitation of our study, aside from that associated with retrospective conduct, is that we did not include the entire spectrum of the anterior mediastinal masses, in particular the small masses that were only kept under surveillance or discharged. On the other hand, we have included the larger lesions that are more worrying and in whom <sup>18</sup>F PET-CT is usually requested. We were able to obtain an estimate of test performance relatively quickly through an established research collaborative as prospective conduct of a validation study is likely to require significant funding, more centres and time as anterior mediastinal lesions are not common. Certainly, we would welcome and encourage international efforts to address this important issue, ideally with reference of clinical effectiveness and cost-effectiveness.

## CONCLUSIONS

<sup>18</sup>F PET-CT is moderately useful to rule out the diagnosis of malignancy when the test result is negative (good sensitivity), however, it is not able to rule in the diagnosis of malignancy when the result is positive (poor specificity). At the existing levels of sensitivity a negative test is insufficient to reassure and obviate the need for serial CT surveillance of indeterminate masses in the anterior mediastinum. Therefore, we conclude that <sup>18</sup>F PET-CT does not have a role in routine clinical practice to assess the malignant potential of an anterior mediastinal mass.

## Author affiliations

<sup>1</sup>Imperial College and the Academic Division of Thoracic Surgery, Royal Brompton and Harefield NHS Foundation Trust, London, UK

<sup>2</sup>Department of Thoracic Surgery, Liverpool Heart and Chest Hospital NHS Trust, Liverpool, UK

<sup>3</sup>Department of Thoracic Surgery, Leeds Teaching Hospitals NHS Trust, Leeds, UK

<sup>4</sup>Department of Thoracic Surgery, Hull and East Yorkshire Hospitals NHS Trust, Hull, UK

<sup>5</sup>Department of Cardiothoracic Surgery, Royal Devon and Exeter NHS Foundation Trust, Exeter, UK

<sup>6</sup>Department of Thoracic Surgery, Plymouth Hospitals NHS Trust, Plymouth, UK

<sup>7</sup>Thoracic Services, Papworth Hospital NHS Foundation Trust, Cambridge, UK

Twitter @ekslim

**Contributors** CP, PDS and EL designed the work, acquired and analysed the data, and drafted the work. EL interpreted the data. SJ, VA, AD, SML, MS, NK, KP, YH, ML, FS, FG, AB, AM, SI and MS acquired and analysed the data, and revised the work critically. All authors approved the version to be published and agreed to be accountable for all aspects of the work in ensuring that questions related to the accuracy or integrity of any part of the work are appropriately investigated and resolved.

**Funding** This research received no specific grant from any funding agency in the public, commercial or not-for-profit sectors.

**Competing interests** Outside this work, EL reports personal fees from Abbott Molecular, personal fees from Glaxo Smith Kline, personal fees from Pfizer, personal

fees from Novartis, personal fees from Covidien, personal fees from Roche, personal fees from Lilly Oncology, personal fees from Boehringer Ingelheim, personal fees from Medela, grants and personal fees from ScreenCell, personal fees from Ethicon, outside the submitted work, and is the founder of Informative Genomics, a blood-based molecular diagnostic company in London.

**Patient consent** Not required.

**Ethics approval** South East Scotland Research Ethics Service.

**Provenance and peer review** Not commissioned; externally peer reviewed.

**Data sharing statement** Anonymised individual patient data that underlie the results reported in this article will be available to researchers who provide a methodologically sound proposal. Proposals should be directed to the corresponding author.

**Open Access** This is an Open Access article distributed in accordance with the Creative Commons Attribution Non Commercial (CC BY-NC 4.0) license, which permits others to distribute, remix, adapt, build upon this work non-commercially, and license their derivative works on different terms, provided the original work is properly cited and the use is non-commercial. See: <http://creativecommons.org/licenses/by-nc/4.0/>

© Article author(s) (or their employer(s) unless otherwise stated in the text of the article) 2018. All rights reserved. No commercial use is permitted unless otherwise expressly granted.

## REFERENCES

1. The Royal College of Radiologists. The Royal College of Radiologists PET-CT in the UK. 2005. [http://www.bnms.org.uk/~bnms/images/stories/downloads/documents/rcr\\_petct\\_final.pdf](http://www.bnms.org.uk/~bnms/images/stories/downloads/documents/rcr_petct_final.pdf)
2. Flahault A, Cadilhac M, Thomas G. Sample size calculation should be performed for design accuracy in diagnostic test studies. *J Clin Epidemiol* 2005;58:859–62.
3. Liu Y. Characterization of thymic lesions with F-18 FDG PET-CT: an emphasis on epithelial tumors. *Nucl Med Commun* 2011;32:554–62.
4. Luzzi L, Campione A, Gorla A, *et al.* Role of fluorine-fluorodeoxyglucose positron emission tomography/computed tomography in preoperative assessment of anterior mediastinal masses. *Eur J Cardiothorac Surg* 2009;36:475–9.
5. Assaad MW, Pantanowitz L, Otis CN. Diagnostic accuracy of image-guided percutaneous fine needle aspiration biopsy of the mediastinum. *Diagn Cytopathol* 2007;35:705–9.
6. Desai F, Shah M, Patel S, *et al.* Fine needle aspiration cytology of anterior mediastinal masses. *Indian J Pathol Microbiol* 2008;51:88.
7. Powers CN, Silverman JF, Geisinger KR, *et al.* Fine-needle aspiration biopsy of the mediastinum. A multi-institutional analysis. *Am J Clin Pathol* 1996;105:168–73.
8. Ahn JM, Lee KS, Goo JM, *et al.* Predicting the histology of anterior mediastinal masses: comparison of chest radiography and CT. *J Thorac Imaging* 1996;11:265–71.
9. Treglia G, Sadeghi R, Giovanella L, *et al.* Is (18)F-FDG PET useful in predicting the WHO grade of malignancy in thymic epithelial tumors? A meta-analysis. *Lung Cancer* 2014;86:5–13.
10. Kaira K, Sunaga N, Ishizuka T, *et al.* The role of [18F] fluorodeoxyglucose positron emission tomography in thymic epithelial tumors. *Cancer Imaging* 2011;11:195–201.
11. Tatci E, Ozmen O, Dadali Y, *et al.* The role of FDG PET/CT in evaluation of mediastinal masses and neurogenic tumors of chest wall. *Int J Clin Exp Med* 2015;8:11146–52.
12. Cronin P, Dwamena BA, Kelly AM, *et al.* Solitary pulmonary nodules: meta-analytic comparison of cross-sectional imaging modalities for diagnosis of malignancy. *Radiology* 2008;246:772–82.
13. Gould MK, Donington J, Lynch WR, *et al.* Evaluation of individuals with pulmonary nodules: when is it lung cancer? Diagnosis and management of lung cancer, 3rd ed: American College of Chest Physicians evidence-based clinical practice guidelines. *Chest* 2013;143:e93S–120.