

Pseudohypoparathyroidism as a rare cause of bilateral slipped capital femoral epiphysis

Karthikeyan R Somasundaram, Senthilkumar Sankararaman¹, Athar Siddiqui, Hamid Zadeh

ABSTRACT

Slipped capital femoral epiphysis (SCFE) is a disorder of adolescent age. Presentation of SCFE earlier than the expected age range should prompt the clinician to consider the presence of an underlying endocrinopathy. Early recognition and aggressive management of the predisposing endocrine disorder is crucial to prevent treatment failure and associated morbidity. We report the clinical presentation and treatment of an 8-year-old girl with bilateral slipped capital femoral epiphysis. The unusual age, persistent hypocalcemia, and associated distal femoral physeal deformities prompted further evaluations, which led to the diagnosis of pseudohypoparathyroidism type 1b. PHP type 1b is an extremely rare cause of SCFE and only a few cases have been reported. A delay in diagnosis in such case is not uncommon.

Key words: Hypocalcemia, pseudohypoparathyroidism type 1b, slipped capital femoral epiphysis

INTRODUCTION

Slipped capital femoral epiphysis (SCFE) commonly affects the overweight and obese adolescents. SCFE classically presents in the age group of 10–15 years.¹ The peak age for this condition is 13 years in boys and 11.5 years in girls. In approximately one-third of the cases, SCFE is associated with an underlying endocrine disorder.² Presentation of SCFE earlier than the expected age range should be considered as a significant risk factor for an underlying endocrinopathy.³ We hereby report the clinical presentation and treatment of an 8-year-old female with simultaneous bilateral SCFE predisposed by pseudohypoparathyroidism (PHP) type 1b. To the best of our knowledge, only one prior case of PHP type 1b predisposing to SCFE that required combined medical and surgical management has been reported in the literature.⁴

Department of Orthopaedics, West Middlesex University Hospital Isleworth, TW7 6AF, United Kingdom, ¹Department of Pediatrics, Louisiana State University Health Sciences Center, Shreveport, LA, USA

Address for correspondence: Dr. Senthilkumar Sankararaman, Department of Pediatrics, Louisiana State University Health Sciences Center, Shreveport, LA, USA. E-mail: drsskumar@gmail.com

CASE REPORT

An 8-year-old female presented to the emergency department with a 4 day history of right hip pain and limping. The pain was of spontaneous onset without any history of trauma. She achieved normal milestones till the age of 6 years. Her past medical history was significant for psoriasis, controlled by topical medications. Dietary history revealed a normal intake of a balanced nonvegetarian diet.

On examination, she was noted to have skin lesions due to mild psoriasis. There were no phenotypic features of Albright’s hereditary osteodystrophy (AHO) which is PHP type 1a. Her weight was 25.8 kg (50th percentile for age and sex), height 131 cm (75th percentile for age and sex), with a height velocity of 4.25 cm/year. Examination of her lower limbs showed a painful right hip with minimal shortening and restricted external rotation. Biochemical investigations revealed low serum calcium and high alkaline phosphatase [Table 1]. The liver enzymes, coagulation screen, renal function tests, serum phosphorus, serum albumin, and serum magnesium were all within normal limits. Radiological investigations showed grade 2 SCFE on the right side and grade 1 on the left side according to Southwick’s classification^{1,2,5} [Figures 1 and 2]. Clinically, she had stable slips according to Loder’s classification.¹

The operative treatment planned was *in situ* pinning of both hips using cannulated screws. The right hip was operated on within 24 h of presentation and the asymptomatic left hip was operated 2 weeks later. Due to her small bony anatomy, 5 mm cannulated screws were used for fixation

Access this article online	
Quick Response Code:	Website: www.ijoonline.com
	DOI: 10.4103/0019-5413.104223

on both sides. The procedure was otherwise similar to the technique described by Loder.¹ The early postoperative recovery was uneventful and postoperative radiographs were satisfactory. The patient was discharged with advice to eat a calcium rich diet and to take calcium supplements and vitamin D₃ (cholecalciferol). As the patient was feeling better, she did not come for the followup appointments. At the 4th postoperative month, she presented with the complaint of pain in her left knee. Clinically her left knee

had 5° more valgus than her asymptomatic right knee. Radiographs of both knees showed widening of the lateral distal femoral physis with abnormal ossification within the metaphysis [Figure 3]. Radiographs of the hips revealed a similar appearance to the postoperative radiographs.

At this stage, the bone profile showed persistent low calcium levels with elevated alkaline phosphatase, in spite of treatment with calcium and vitamin D₃ [Table 1]. This persistent hypocalcemia prompted us to carry out further endocrinologic evaluation. Her parathyroid hormone (PTH) level was 172 pg/mL (normal range is 10–60 pg/mL). Further investigations revealed normal thyroid function.

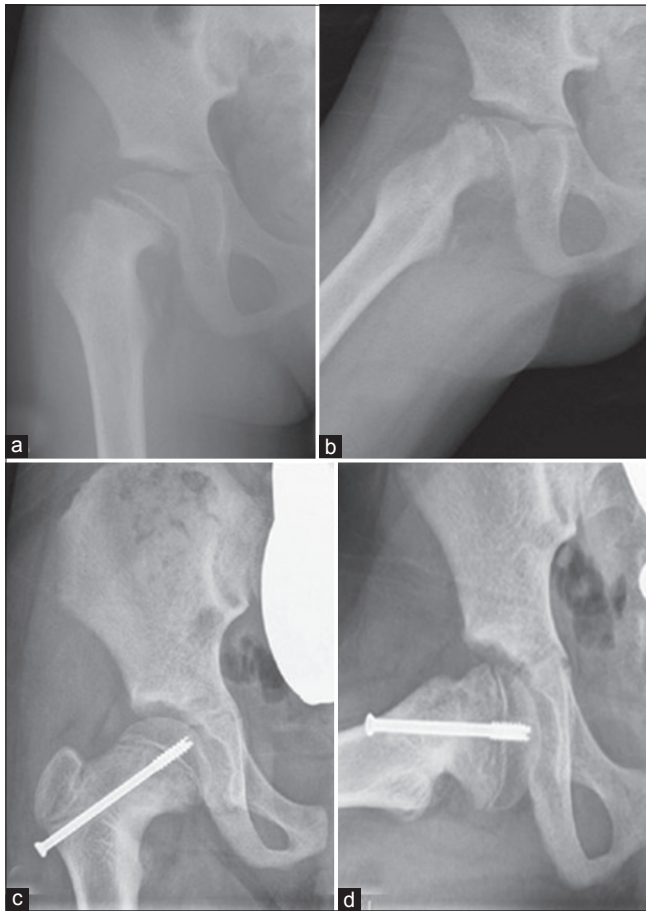


Figure 1: Radiographs (anteroposterior & frog leg lateral views) showing slipped capital femoral epiphysis (Rt) (a,b) in 8-year-old female child at the initial presentation; (c,d) radiographs (anteroposterior and frog leg lateral showing good remodeling of the head of the femur after the surgical fixation and alfacalcidol treatment during follow up (2 years after initial presentation)

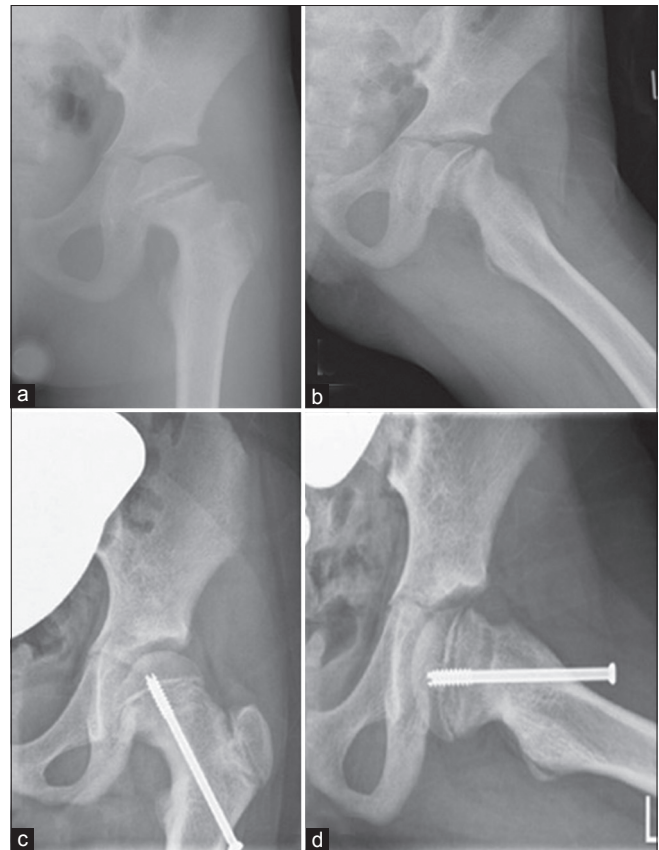


Figure 2: Radiographs (anteroposterior and frog leg lateral) in 8-year-old female showing (a,b) slipped capital femoral epiphysis (c,d) good remodeling of the head of the femur at 2 years followup

Table 1: Biochemical investigations of the patient

Investigations	Parameters on her first presentation	Parameters on her second presentation (4 months later)	One month of treatment with alfacalcidol (5 months later)	After treatment with high dose alfacalcidol (24 months later)
Calcium (2.2–2.65 mmol/L)	1.70	1.72	1.94	2.24
Phosphate (1.29–2.26 mmol/L)	1.87	1.88	1.74	1.79
Alkaline phosphatase (69–325 IU/L)	650	662	563	394
25 (OH) Vitamin D (20–100 ng/mL)	ND	26	35	103
Parathyroid hormone (10–60 pg/mL)	ND	172	126	66
Urea (1.8–6.4 mmol/L)	2.7	2.8	2.8	4.2
Creatinine (32–94 μmol/L)	51	51	53	65

Normal levels shown within parenthesis. ND, Not done

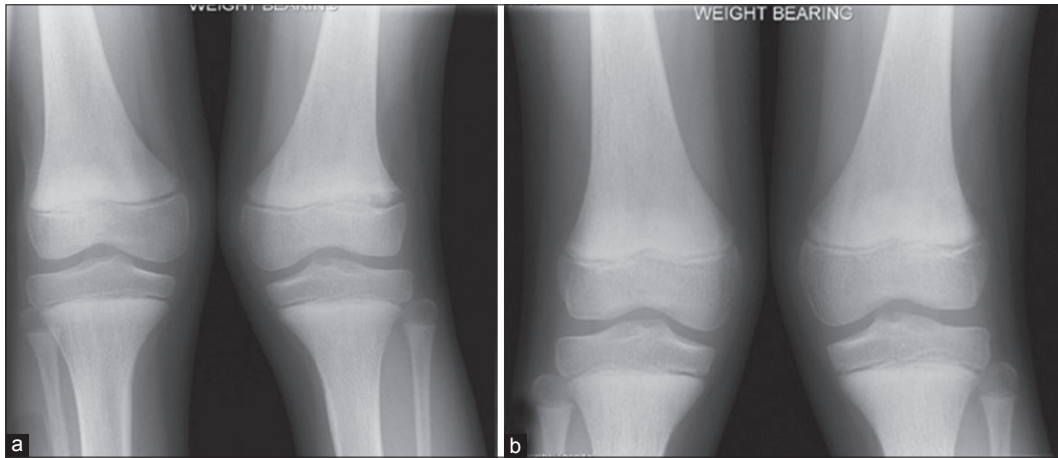


Figure 3: Radiograph of knee joint (anteroposterior view) showing (a) widening of distal femoral physis and ossification of metaphysis with valgus deformity in left knee at 4 months after the initial presentation (b) disappearance of the distal femoral physal changes after the treatment with alfacalcidol

The combination of high PTH and low calcium with no possible explanation led us to suspect end organ resistance to PTH, which is known as PHP. The absence of AHO phenotype favoured the diagnosis of PHP type 1b.⁴ The patient was referred to a geneticist and an endocrinologist for further evaluation. Genetic testing revealed *GNAS1* methylation defects, confirming the diagnosis of PHP type 1b. She was started on calcium carbonate supplements and alfacalcidol (1- α -hydroxyvitamin D₃) 0.5 μ g once daily. In a week, her sense of general well being improved and there was a marked reduction in the left lower limb pain. Her serum calcium and vitamin D level increased, and at the same time, serum alkaline phosphatase and PTH levels decreased [Table 1]. The alfacalcidol dose was slowly increased at weekly increments of 0.5 μ g to a final dose of 1.5 μ g once daily. She was allowed to bear weight in 1 month.

At her last follow up, 2 years after the *in situ* fixation, the patient remained without symptoms. Radiographs of the hips showed good remodeling of the proximal femur with no evidence of avascular necrosis [Figure 1c,d and 2 c,d]. Radiographs of her distal femur showed improved ossification and narrowing of the distal femoral physis [Figure 3]. The valgus deformity in her left knee had also improved, but correction with hemiepiphysiodesis may be required in the future. The patient was advised to continue calcium carbonate and alfacalcidol lifelong. Followup till skeletal maturity was planned, but unfortunately the family was lost to followup.

DISCUSSION

Slipped capital femoral epiphysis (SCFE) is a well known disorder commonly seen in adolescent age group. The exact etiology of SCFE is still unknown, but the commonly associated risk factors include obesity, adolescent growth

spurt, mechanical abnormalities, trauma, and endocrine abnormalities.^{2,4} An underlying endocrinopathy accounts for at least one-third of the cases of SCFE, and the common endocrinopathies associated with SCFE include hypothyroidism, hyperparathyroidism, growth hormone deficiency, and hypogonadism.²

Pseudohypoparathyroidism (PHP) is a heterogeneous group of rare metabolic disorders characterized by end organ resistance to the action of parathyroid hormone (PTH). In PHP, kidney consistently demonstrate resistance to the action of PTH, but the skeletal resistance is variable.⁴ Renal resistance to PTH results in biochemical hypoparathyroidism (hypocalcemia, hyperphosphatemia) along with elevated PTH.^{2,3} PHP is further classified as PHP 1 and 2.⁶⁻⁸ Patients with type 1 PHP show no increase in urinary cyclic adenosine monophosphate (cAMP) after intravenous administration of exogenous PTH due to end organ resistance, but patients with type 2 retain this ability. PHP type 2 is an extremely uncommon subtype.

PHP type 1 is further classified as types 1a, 1b, and 1c. PHP type 1a accounts for majority of the cases and the prototype of all subtypes. PHP type 1a was first described by Albright in 1942 and is also known as Albright's hereditary osteodystrophy (AHO).⁹ The characteristic phenotype includes short stature, obesity, round facies, brachydactyly, hyperparathyroid bone disease (osteitis fibrosa), and subcutaneous calcifications. Type 1c is rare but phenotypically similar to type 1a. Patients with type 1b have normal G protein activity and a normal phenotype. The pathophysiology of type 1b is caused by paternal disomy of chromosome 20q and subsequent *GNAS1* methylation.^{7,8} The loss of the maternal *GNAS1* gene results in PTH resistance in the proximal renal tubules, which leads to hypocalcemia and hyperphosphatemia. The absence

of the conspicuous AHO features in PHP type 1b and its rarity frequently cause a delay in diagnosis and treatment.⁴

In PHP type 1b, the bones remains sensitive to the effects of PTH, which results in the bony resorption of calcium in an attempt to maintain the serum calcium.¹⁰⁻¹² The bony effects due to PTH described in PHP are similar to the bony changes seen in hyperparathyroidism.^{4,13} SCFE is well documented in renal osteodystrophy due to hyperparathyroidism.¹⁴ PTH impairs the normal enchondral ossification and diminishes the collagen content of the growth plates.⁴ Similarly in PHP, the upper femoral metaphyseal resorption due to elevated PTH is thought to be the reason for slippage in SCFE.^{4,15} In addition to surgical fixation, medical treatment with active vitamin D analogs is therefore required to suppress the PTH and to prevent subsequent treatment failure. In our patient, the distal femoral physal changes were seen due to the effects of increased PTH, which has been documented in previously reported cases of PHP.^{4,11-13} Treatment with calcitriol (1,25-dihydroxyvitamin D₃) is generally recommended to normalize the elevated PTH because calcitriol does not require PTH for its activation.⁴

Alfacalcidol (1-alpha-hydroxyvitamin D₃) is a synthetic analog of vitamin D, which is converted in the liver to the active metabolite 1,25-dihydroxyvitamin D₃. Similar to calcitriol, alfacalcidol has a rapid onset of action and a relatively short half-life.¹⁶⁻¹⁸ Calcium supplementation is also recommended to increase the serum calcium levels. Generally a PTH level of <200 pg/mL and serum alkaline phosphatase >500 IU/L is recommended with vitamin D therapy.¹⁴ In our patient, PTH levels normalized quickly with the use of alfacalcidol and demonstrated no recurrence of symptoms in the follow up period.

PHP should be considered as an extremely rare cause for SCFE, especially if the age of presentation is earlier than the expected range.³ We conducted a literature search in Medline using the terms “slipped capital femoral epiphysis” and “pseudohypoparathyroidism” and found only three case reports.^{4,11,13} Review of the citations in these articles revealed another pertinent article,¹² increasing the total number of PHP patients with SCFE to five (including the patient reported here). All of these patients were females. The youngest patient was reported by Aggarwal *et al.* in a 3-year-old who also required surgical fixation similar to our patient. All the other patients required medical management only. In the absence of AHO phenotype, all the previous patients were believed to have PHP type 1b.⁴

As SCFE predominantly affects the obese and overweight population,¹⁹ the occurrence of SCFE in children with

normal or lower body mass index may provide another clue to search for an underlying endocrinopathy. Further endocrinologic evaluation is usually required to confirm the diagnosis. As illustrated in our case, this could be difficult and take considerable time if this possibility is not considered in the diagnosis. We emphasize that clinicians should have a high index of suspicion as early initiation of medical treatment prevents treatment failure and reduces the morbidity.

Our case is unique due to the following reasons. To the best of our knowledge, the patient we described is the second patient with PHP type 1b predisposing to SCFE and required both medical and surgical treatments.⁴ The patient described by Aggarwal *et al.* presented with PHP and was started on calcitriol and calcium supplements. Due to medication noncompliance, she developed bilateral SCFE 6 months later, which required surgical pinning and continuation of medical treatment. Interestingly, our patient presented with SCFE requiring surgical fixation, but her manifestations of SCFE and later distal femoral physal changes improved only after treatment with alfacalcidol and calcium supplementation, further supporting the importance of aggressive medical management. Even though calcitriol is the preferred choice, alfacalcidol may be used as an alternative if the PTH levels are not highly elevated.

In conclusion, we would like to highlight that PHP, although rare, should be considered as a possible cause for SCFE in children younger than the expected age group. Clinicians need to have high index of suspicion as diagnosis may be delayed due to the extreme rarity. Further investigations are required to establish the diagnosis. With appropriate medical and surgical treatment, satisfactory outcome should be expected.

REFERENCES

1. Loder RT, Aronsson DD, Dobbs MB, Weinstein SL. Slipped capital femoral epiphysis. Instr Course Lect 2001;50:555-70.
2. Loder RT, Wittenberg B, DeSilva G. Slipped capital femoral epiphysis with endocrine disorders. J Pediatr Orthop 1995;15:349-56.
3. Wells D, King JD, Roe TF, Kaufman FR. Review of slipped capital femoral epiphysis associated with endocrine disease. J Pediatr Orthop 1993;13:610-4.
4. Agarwal C, Siegle R, Agarwal S, Bilezikian JP, Hyman JE, Oberfield SE. Pseudohypoparathyroidism: A rare cause of bilateral slipped capital femoral epiphysis. J Pediatr 2006;149:406-8.
5. Rao JP, Francis AM, Siwek CW. The treatment of chronic slipped capital femoral epiphysis by biplane osteotomy. J Bone Joint Surg Am 1984;66:1169-75.
6. Spiegel AM, Weinstein LS, Shenker A. Abnormalities in G protein-coupled signal transduction pathways in human

- disease. *J Clin Invest* 1993;92:1119-25.
7. Jüppner H, Bastepe M. Different mutations within or upstream of the GNAS locus cause distinct forms of pseudohypoparathyroidism. *J Pediatr Endocrinol Metab* 2006;19:641-6.
 8. Bastepe M, Jüppner H. GNAS locus and pseudohypoparathyroidism. *Horm Res* 2005;63:65-74.
 9. Albright F, Burnett CH, Smith CH, Parson W. Pseudohypoparathyroidism: An example of "Seabright-Bantam syndrome." *Endocrinology* 1942;30:922-32.
 10. Levine MA, Speigel AM. Pseudohypoparathyroidism. *Endocrinology*. Philadelphia:WB Saunders; 1995. p. 1136-50.
 11. Hall FM, Segall-Blank M, Genant HK, Kolb FO, Hawes LE. Pseudohypoparathyroidism presenting as renal osteodystrophy. *Skeletal Radiol* 1981;6:43-6.
 12. Dabbagh S, Chesney RW, Langer LO, DeLuca HF, Gilbert EF, DeWeerd JH Jr. Renal-nonresponsive, bone responsive pseudohypoparathyroidism. A case with normal vitamin D metabolite levels and clinical features of rickets. *Am J Dis Child* 1984;138:1030-3.
 13. Burnstein MI, Kottamasu SR, Pettifor JM, Sochett E, Ellis BI, Frame B. Metabolic bone disease in pseudohypoparathyroidism: Radiologic features. *Radiology* 1985;155:351-6.
 14. Oppenheim WL, Bowen RE, McDonough PW, Funahashi TT, Salusky IB. Outcome of slipped capital femoral epiphysis in renal osteodystrophy. *J Pediatr Orthop* 2003;23:169-74.
 15. Kirkwood JR, Ozonoff MB, Steinbach HL. Epiphyseal displacement after metaphyseal fracture in renal osteodystrophy. *Am J Roentgenol Radium Ther Nucl Med* 1972;115:547-54.
 16. Halabe A, Arie R, Mimran D, Samuel R, Liberman UA. Hypoparathyroidism-a long term followup experience with 1 alpha-vitamin D3 therapy. *Clin Endocrinol (Oxf)* 1994;40:303-7.
 17. Mantovani G. Clinical review: Pseudohypoparathyroidism: Diagnosis and treatment. *J Clin Endocrinol Metab* 2011;96:3020-30.
 18. Furukawa Y, Sohn H, Unakami H, Yumita S. Treatment of pseudohypoparathyroidism with 1 alpha-hydroxyvitamin D3. *Contrib Nephrol* 1980;22:68-73.
 19. Manoff EM, Banffy MB, Winell JJ. Relationship between Body Mass Index and slipped capital femoral epiphysis. *J Pediatr Orthop* 2005;25:744-6.

How to cite this article: Somasundaram KR, Sankararaman S, Siddiqui A, Zadeh H. Pseudohypoparathyroidism as a rare cause of bilateral slipped capital femoral epiphysis. *Indian J Orthop* 2012;46:705-9.

Source of Support: Nil, **Conflict of Interest:** None.

ERRATUM

Indian Journal of Orthopaedics July-August 2012; Vol 46; Issue 4

Title: Augmented osteosynthesis with tensor fascia latae muscle pedicle bone grafting in neglected femoral neck fracture

Page 439-446; Authors: Basant Kumar Bhuyan

Table 4

The article by Baksi DP cited in table 4 is 26

The article by Day B *et.al.* cited in table 4 is 20

Should read as

Table 4

(i) The article by Baksi DP should be read as 12

(ii) The article by Day B *et.al.* cited in table 4 as 20 may be treated as deleted and be referred to following article

Leung PC, Shen WY. Fracture of the femoral neck in younger adults. A new method of treatment for delayed and nonunions. *Clin Orthop Relat Res* 1993;295:156-60.

The error is regretted

- Chief Editor, Indian Journal of Orthopaedics