



## Chloropsia in the Charles Bonnet syndrome

Anshul Bhatnagar<sup>a,\*</sup>, Rhys Ishihara<sup>b</sup>, Mohammad Pakravan<sup>b</sup>, Chaow Charoenkijajorn<sup>b</sup>, Andrew G. Lee<sup>b,c,d,e,f,g</sup>

<sup>a</sup> School of Medicine, Baylor College of Medicine, Houston, TX, USA

<sup>b</sup> Department of Ophthalmology, Blanton Eye Institute, Houston Methodist Hospital, Houston, TX, USA

<sup>c</sup> Departments of Ophthalmology, Neurology, and Neurosurgery, Weill Cornell Medicine, New York, NY, USA

<sup>d</sup> Department of Ophthalmology, University of Texas Medical Branch, Galveston, TX, USA

<sup>e</sup> University of Texas MD Anderson Cancer Center, Houston, TX, USA

<sup>f</sup> Texas A and M College of Medicine, Bryan, TX, USA

<sup>g</sup> Department of Ophthalmology, The University of Iowa Hospitals and Clinics, Iowa City, IA, USA

### ARTICLE INFO

#### Keywords:

Charles bonnet syndrome  
Chloropsia  
Chromatopsia  
Color perception

### ABSTRACT

**Purpose:** Chloropsia (green-colored vision) is an extremely uncommon and relatively unstudied clinical finding. We report a case where cerebral chloropsia was the presenting symptom of the Charles Bonnet syndrome.

**Observations:** A 66-year-old male physician with a previous ocular history of advanced bilateral primary open-angle glaucoma presented with acute, diffuse chloropsia, which he described as “light green and oval-shaped.” The patient was not taking any drugs that commonly cause altered color perception and did not have a previously diagnosed psychiatric disorder. Ophthalmic examination findings showed poor visual acuity, central visual field loss, and altered color perception in both eyes. Common laboratory tests and visual imaging showed no abnormalities that could be associated with the patient’s symptoms.

**Conclusions and Importance:** Our patient meets all diagnostic criteria for Charles Bonnet syndrome, even though, to the best of our knowledge, chloropsia has never been previously associated with this disorder. Physicians should monitor patients for altered color perception, which cannot be explained by other ocular, psychiatric, or systemic mechanisms, as this could be a sign of Charles Bonnet syndrome.

### 1. Introduction

Charles Bonnet syndrome (CBS) is a relatively common but often under-recognized cause of visual hallucinations in visually impaired patients. The diagnostic criteria include loss of visual acuity/visual field; insight into the unreal nature of the hallucinations; and absence of hallucinogen use or other medical (e.g., seizure) or psychiatric disorders that could better explain the symptoms.<sup>1</sup>

Changes in color vision (chromatopsia) include perception of different colors in the visual field. Xanthopsia (yellow colored vision), cyanopsia (blue colored vision), and erythropsia (red colored vision) are well described chromatopsias that result in altered color perception and have been observed in various disorders.<sup>2–8</sup> These chromatopsias often occur due to damage to photoreceptors or retinal ganglion cells.<sup>2</sup> However, central chloropsia, which causes green tinged vision is rare. We describe a unique case of cerebral chloropsia as the presenting symptom of CBS secondary to primary open-angle glaucoma.

### Case Report

A 66 year old Asian male physician presented with acute simultaneous, diffuse altered color in the visual environment of both green and pink. The patient became consciously aware of his changing color perception five months prior after driving by an ambulance and noting its color to be pinkish-purple instead of red. The patient then noticed alternating, yet inconsistent, green and pink colors in both his peripheral and central visual fields. The patient initially attributed these changes to variation in ambient light but, refuting his hypothesis, realized that his altered color perception did not follow a predictable pattern.

Past ocular history was significant for advanced bilateral primary open-angle glaucoma, cataract extraction with intraocular lens placement in both eyes (OU), and convergence insufficiency that was treated with prism. The patient underwent color vision testing as a child without issue. Past medical history included hypercholesterolemia and migraine without visual aura. He had no known psychiatric disorder and had no

\* Corresponding author. Baylor College of Medicine, 1 Baylor Plaza, Houston, TX, 77030, USA.

E-mail address: [Anshul.Bhatnagar@bcm.edu](mailto:Anshul.Bhatnagar@bcm.edu) (A. Bhatnagar).

<https://doi.org/10.1016/j.ajoc.2022.101703>

Received 27 February 2022; Received in revised form 26 August 2022; Accepted 3 September 2022

Available online 10 September 2022

2451-9936/© 2022 Published by Elsevier Inc. This is an open access article under the CC BY-NC-ND license (<http://creativecommons.org/licenses/by-nc-nd/4.0/>).

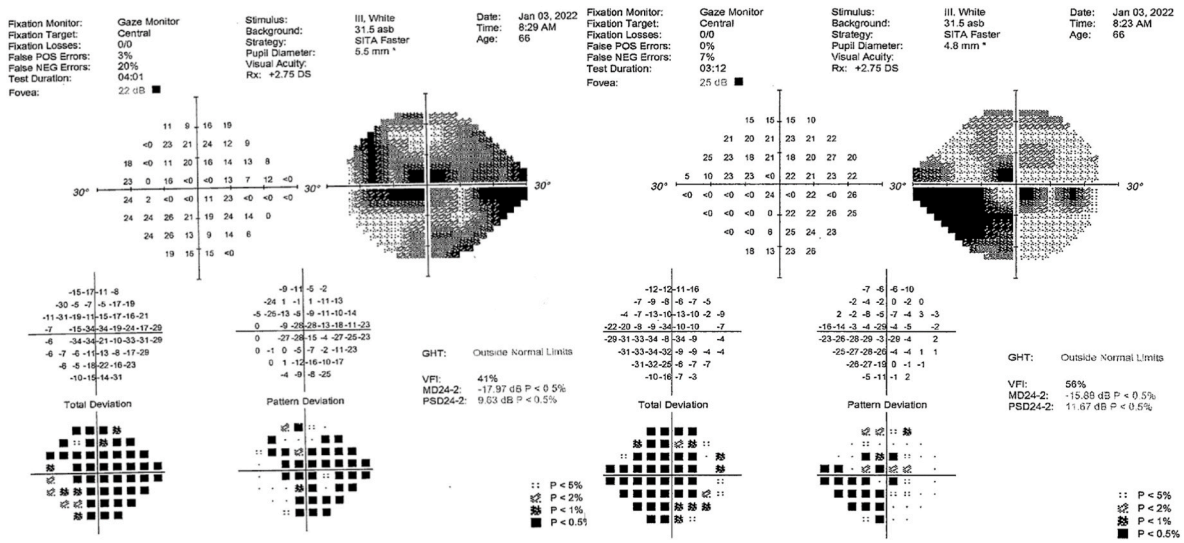


Fig. 1. Automated perimetry (Humphrey 24-2) demonstrates ceccentral scotomas in both eyes.

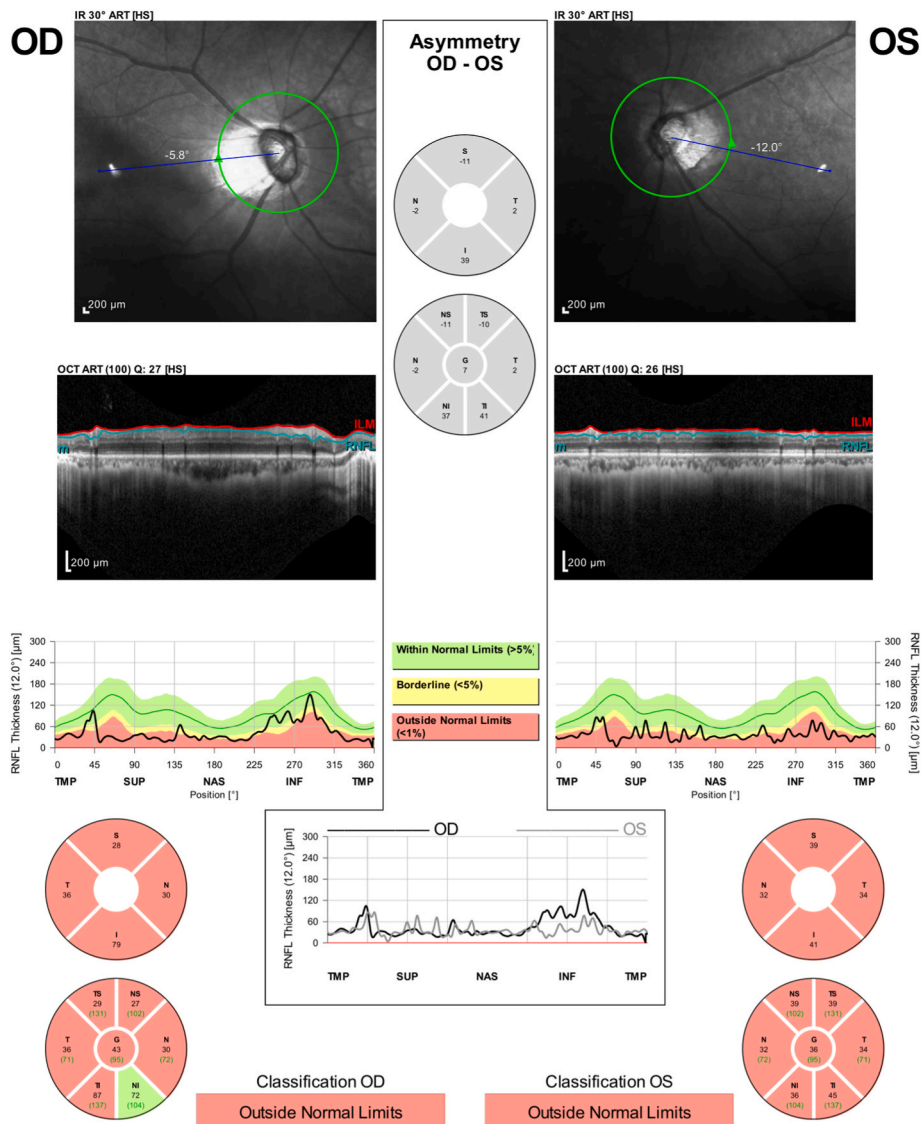


Fig. 2. Optical coherence tomography of the patient's retinal fiber nerve layer (RNFL) shows significant thinning in both eyes.

hallucinogen exposure. His medications included oral pravastatin and allopurinol, and topical dorzolamide, timolol, and travoprost. The patient was not taking digoxin or any other medications that can cause chromatopsia. Family history was noncontributory.

The patient was referred to our neuro-ophthalmology service. On examination, the patient had visual acuity of 20/40 in the right eye (OD) and 20/50 in the left eye (OS). He identified 1/14 Ishihara color plates OU. Intraocular pressure measurements were 18 mm Hg OD and 14 mm Hg OS. Slit-lamp examination showed pseudophakia OU and otherwise unremarkable. Fundus examination showed tilted myopic configuration, peripapillary myopic crescents, and a cup-to-disc ratio of 0.9 with sloping to the temporal rim OU. Humphrey visual field 24-2 showed glaucomatous visual field loss OU with an inferior and superior paracentral and peripheral arcuate defect OD and a dense superior altitudinal field defect and inferior arcuate defect OS encroaching on fixation OS (Fig. 1).

On an Amsler grid, the patient drew out an example of his bilateral, paracentral colorful phenomenon, which he described as “light green and oval shaped”. Optical coherence tomography of the retinal fiber nerve layer (RFNL) was consistent with significant RFNL thinning in both eyes with average RFNL thickness of 43  $\mu$ m OD and 36  $\mu$ m OS (Fig. 2).

Laboratory tests including complete blood count, rapid plasma regain, C-reactive protein, fluorescent treponemal antibody absorption, erythrocyte sedimentation rate, vitamin B12, folate, methylmalonic acid, and homocysteine levels were within normal limits. Magnetic resonance imaging (MRI) with and without contrast of the head and orbit showed no intracranial or intraorbital abnormalities. An electroencephalogram (EEG) was normal.

## 2. Discussion

Our patient presented with an unusual gain-of-color green and pink chromatopsia OU consistent with chloropsia. The patient did not have congenital male pattern color blindness and meets many generally-accepted diagnostic criteria for Charles Bonnet syndrome (CBS).<sup>1</sup> First, the patient experienced hallucinatory phenomenon in the visual sense and not in any other sensory modality. Second, the patient had normal intellectual functioning and possessed insight into the false nature of the hallucinations. Third, like most CBS patients, our patient suffered from some visual impairment with the hallucinatory content primarily occurring in areas of visual field loss; importantly, however, not all CBS patients experience notable visual dysfunction. Fourth, CBS typically occurs in elderly individuals like our patient. Fifth, systematic history-taking, ophthalmic examination, and laboratory testing and imaging ruled out other potential psychiatric, traumatic, and pharmacologic causes of the patient’s altered color perception.

Descriptions of CBS and its clinical presentation among patients vary widely across literature. Visual hallucinatory content can vary from simple geometric shapes to complex, intricate images of faces and objects.<sup>1,9</sup> One study found that most CBS hallucinations tended to be centrally located and colored.<sup>10</sup> Hallucinations also tend to be transient, but recurrent, and can vary in frequency and duration, all features demonstrated by the visual phenomenon of our patient. Hallucinations often occur in areas where the patient has experienced visual field loss, but this is not always the case. Indeed, a minority of patients with CBS-induced hallucinations have relatively good visual acuity, despite some visual impairment.<sup>10,11</sup> A case series on patients with CBS-induced hallucinations secondary to glaucoma, much like the one described in this report, described multiple individuals with visual acuities between 20/20 and 20/40.<sup>11</sup> Similar findings have prompted some controversy over whether visual impairment is required for CBS diagnosis.<sup>1,11</sup> Thus, our patient’s presentation of CBS with relatively preserved visual acuity, while somewhat uncommon, is not unprecedented.

Systemic, non-hallucinogenic medications can cause chromatopsia.<sup>4,7,8</sup> Digoxin may cause yellowing of the optic media and has been

associated with xanthopsia.<sup>7</sup> Phosphodiesterase type 5 inhibitors can inhibit cone-specific phosphodiesterase and induce cyanopsia.<sup>2,8</sup> Erythroptosis, while not associated with medication, has been linked to retinal hemorrhages, which cause heme-mediated oxidative cone damage.<sup>2</sup> Unlike these chromatopsias, chloropsia is extremely uncommon and only rarely linked to a particular condition. Chloropsia may result from damage to photoreceptors and retinal ganglion cells but is rare.<sup>2</sup>

The mechanism for CBS is believed to be a cortical release phenomenon. The visual cortex attempts to independently “fill-in” sensory-deprived regions in a cerebral phenomenon similar to the “phantom limb” syndrome.<sup>1</sup> This hypothesis is supported by reports of stroke patients with homonymous hemianopia and CBS who experience visual hallucinations solely in their hemianopic fields.<sup>12</sup> Another potential mechanism for CBS development may occur via neurons in the lateral geniculate nucleus, which undergo “deafferentation” following vision loss, leading to spontaneous neural excitability and hallucinations.<sup>13</sup>

## 3. Conclusions

In summary, clinicians should monitor for Charles Bonnet syndrome (CBS) development in visually impaired patients with positive chromatopsias that are not explained by other ocular, systemic, or psychiatric mechanisms. To our knowledge, our case represents a unique presentation of CBS with diffuse, bilateral chloropsia.

## Funding

No funding or grant support

## Authorship

All authors attest that they meet the current ICMJE criteria for authorship

## Statement of Authorship

### Category 1

- Conception and design: AB, RI, MP, CC, and AGL
- Acquisition of data: AB, RI, MP, CC, and AGL
- Analysis and interpretation of data: AB, RI, MP, CC, and AGL

### Category 2

- Drafting the manuscript: AB, RI, MP, CC, and AGL
- Revising it for intellectual content: AB, RI, MP, CC, and AGL

### Category 3

- Final approval of the completed manuscript: AB, RI, MP, CC, and AGL.

## Patient consent

The patient consented to publication of the case in writing.

## Publication Originality Statement

We confirm this publication is original.

## Declaration of competing interest

The following authors have no financial disclosures (AB, RI, MP, CC, and AGL).

## Acknowledgements

None

## References

- Menon GJ, Rahman I, Menon SJ, Dutton GN. Complex visual hallucinations in the visually impaired: the Charles Bonnet syndrome. *Surv Ophthalmol.* 2003;48(1): 58–72. [https://doi.org/10.1016/S0039-6257\(02\)00414-9](https://doi.org/10.1016/S0039-6257(02)00414-9).
- Vaphiades MS, Grondines BD, Curcio CA. Erythropsia and chromatopsia: case, study and brief review. *Neuro Ophthalmol.* 2021;45(1):56–60. <https://doi.org/10.1080/01658107.2020.1797824>.
- Fox WC, Moon RE. Blue vision (cyanopsia) associated with TURP syndrome: a case report. *A&A Pract.* 2018;11(10):279–281. <https://doi.org/10.1213/XAA.0000000000000809>.
- Rassi SZ, Saint-Amour D, Wittich W. Drug-induced deficits in color perception: implications for vision rehabilitation professionals. *J Vis Impair Blind (JVIB).* 2016; 110(6):448–454.
- Roh YR, Woo SJ, Ahn J, Park KH, Hwang JM. Pulmonary tuberculosis associated retinal vasculitis presenting as xanthopsia. *Ocul Immunol Inflamm.* 2011;19(2): 121–123. <https://doi.org/10.3109/09273948.2010.530734>.
- Kitakawa T, Nakadomari S, Kuriki I, Kitahara K. Evaluation of early state of cyanopsia with subjective color settings immediately after cataract removal surgery. *J Opt Soc Am.* 2009;26(6):1375–1381. <https://doi.org/10.1364/JOSAA.26.001375>.
- Rietbrock N, Alken RG. Color vision deficiencies: a common sign of intoxication in chronically digoxin-treated patients. *J Cardiovasc Pharmacol.* 1980;2(1):93–99.
- Lee CH, Yoon JS, Ji E. A case report of cyanopsia after taking sildenafil. *Korean J Clin Pharm.* 2020;30(1):59–64. <https://doi.org/10.24304/kjcp.2020.30.1.59>.
- Pang L. Hallucinations experienced by visually impaired: Charles Bonnet syndrome. *Optom Vis Sci.* 2016;93(12):1466–1478. <https://doi.org/10.1097/OPX.0000000000000959>.
- Khan JC, Shahid H, Thurlby DA, Yates JRW, Moore AT. Charles Bonnet syndrome in age-related macular degeneration: the nature and frequency of images in subjects with end-stage disease. *Ophthalmic Epidemiol.* 2008;15(3):202–208. <https://doi.org/10.1080/09286580801939320>.
- Madill SA, Ffytche DH. Charles Bonnet syndrome in patients with glaucoma and good acuity. *Br J Ophthalmol.* 2005;89(6):785–786. <https://doi.org/10.1136/bjo.2005.066027/10.1136/bjo.2005.068510>.
- Contardi S, Rubboli G, Giulioni M, et al. Charles Bonnet syndrome in hemianopia, following antero-mesial temporal lobectomy for drug-resistant epilepsy. *Epileptic Disord.* 2007;9(3):271–275. <https://doi.org/10.1684/epd.2007.0110>.
- Burke W. The neural basis of Charles Bonnet hallucinations: a hypothesis. *J Neurol Neurosurg Psychiatry.* 2002;73(5):535–541. <https://doi.org/10.1136/jnnp.73.5.535>.