



## CASE REPORT

# Cerebellopontine angle lipoma in asymptomatic patients: case report<sup>☆</sup>



## Lipoma do ângulo pontocerebelar em pacientes assintomáticos: relato de caso

Ricardo Rodrigues Figueiredo<sup>a,b,\*</sup>, Andréia Aparecida de Azevedo<sup>c</sup>,  
João Alfredo de Mesquita Rodrigues Figueiredo<sup>d</sup>, Norma de Oliveira Penido<sup>a</sup>

<sup>a</sup> Universidade Federal de São Paulo (UNIFESP), São Paulo, SP, Brazil

<sup>b</sup> Faculdade de Medicina de Valença, Serviço de Otorrinolaringologia, Valença, RJ, Brazil

<sup>c</sup> Otorrinolaringologia Sul-Fluminense (OTOSUL), Volta Redonda, RJ, Brazil

<sup>d</sup> Universidade Unigranrio, Rio de Janeiro, RJ, Brazil

Received 13 December 2014; accepted 4 May 2015

Available online 5 November 2015

### Introduction

Lipomas represent approximately 0.15% of cerebellopontine angle tumors.<sup>1</sup> Audiometric findings include unilateral or asymmetrical sensorineural hearing loss with low speech recognition index (SRI).<sup>2</sup> Imaging procedures, particularly nuclear magnetic resonance (NMR), confirm the diagnosis.<sup>1–4</sup> There is no image enhancement with gadolinium; in this scenario, special fat suppression sequences are particularly useful.<sup>3</sup> In asymptomatic and mildly symptomatic patients, the treatment is expectant, and surgical approach should be reserved for cases of dizziness, as well as intense and clinically intractable trigeminal neuralgia and headache.<sup>3,4</sup>

### Case report

GPS, male, 30 years old, asymptomatic, referred after a change in periodic audiometry. The audiometry showed mild

sensorineural hearing loss, with a flat curve in the left ear, and SRI was 100% in both ears. Brainstem evoked auditory potential (BEAP) revealed increase in left I–III interpeak interval. NMR of the internal auditory canals and cerebellopontine angles (CPA) showed a small extra-axial elongated image of approximately 0.8 cm in greatest diameter in the upper portion of the left cerebellopontine angle cistern, that exhibited a fat-like signal intensity which disappeared with the use of fat-suppression technique. The Neurosurgery Service chose watchful waiting and audiometric follow-up. After one year, a repeat audiogram was performed with a second NMR; the size of the lesion (Fig. 1) was unchanged, and there was no worsening of hearing thresholds by pure tone audiometry.

### Discussion

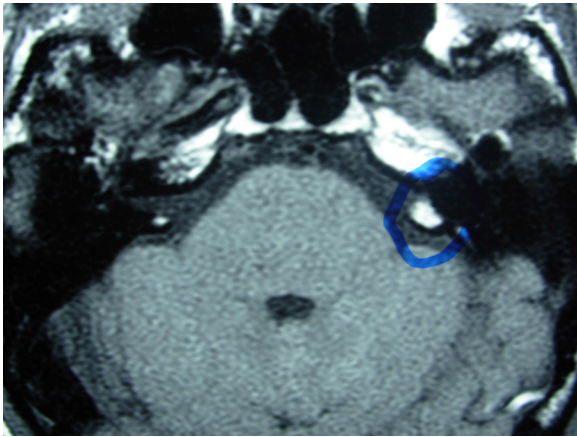
Unlike most cases described,<sup>1–4</sup> this patient was asymptomatic at the time of diagnosis. The audiometric findings (unilateral sensorineural hearing loss) are characteristic of retrocochlear lesions, except for the normal SRI.<sup>1</sup> No references were found with regard of BEAP findings (I–III interval increase), which was compatible with retrocochlear lesions.

As in other retrocochlear lesions, NMR is the diagnostic technique of choice to identify the critical features of a

<sup>☆</sup> Please cite this article as: Figueiredo RR, de Azevedo AA, Figueiredo JA, Penido NO. Cerebellopontine angle lipoma in asymptomatic patients: case report. Braz J Otorhinolaryngol. 2016;82:741–2.

\* Corresponding author.

E-mail: [rfigueiredo@otosul.com.br](mailto:rfigueiredo@otosul.com.br) (R.R. Figueiredo).



**Figure 1** Magnetic resonance imaging shows the lesion (circled in blue).

lipoma, the absence of image enhancement with gadolinium and the disappearance of the lesion with the use of fat-suppression techniques.<sup>3,4</sup> Given the slow growth of the lesion, there is consensus in the literature that surgical treatment only is indicated for cases with clinically intractable symptoms.<sup>2,3</sup>

## Final comments

CPA lipomas are rare lesions that behave like and should be treated similar to other tumors that occur in the same region. Our example of an asymptomatic case is unusual.

## Conflicts of interest

The authors declare no conflicts of interest.

## References

1. Borges RS, Brito CCB, Carvalho GA, Domingues RC, Gasparetto EL. Cerebellopontine angle lipomas magnetic resonance imaging in two cases. *Arq Neuropsiquiatr*. 2009;67:496–8.
2. Ferreira MP, Ferreira NP, Lenhardt R. Lipoma of the cerebellopontine angle. Case reports and literature review. *Arq Neuropsiquiatr*. 1994;52:58–63.
3. Truwitt CL, Barkovich AJ. Pathogenesis of intracranial lipoma: an MR study in 42 patients. *AJR*. 1990;155:855–64.
4. Kazner E, Stochdorph O, Wende S, Grumme T. Intracranial lipomas: diagnostic and therapeutic considerations. *J Neurosurg Sci*. 1988;32:161–7.