

Morin Ameliorates Myocardial Injury in Diabetic Rats via Modulation of Autophagy, Apoptosis, Inflammation, and Oxidative Stress

Liping Zhu¹, Jizhong He²

¹Department of Endocrinology, Huaihe Hospital of Henan University, Kaifeng, 475000, People's Republic of China; ²Department of Cardiology, Yan'an People's Hospital, Yan'an, 716000, People's Republic of China

Correspondence: Jizhong He, Department of Cardiology, Yan'an People's Hospital, Yan'an, 716000, People's Republic of China, Tel +8613619113453, Email Hejizhong1122@sina.com

Background: Morin is a flavonol with beneficial effects on diabetic-related injuries. However, the effect of morin on diabetic cardiomyopathy and its association with autophagy, apoptosis, inflammation, and oxidative stress remains unclear. The current study aimed to reveal the mechanisms underlying morin-mediated protection against cardiac failure in diabetic rats.

Methods: Diabetic cardiomyopathy in albino Wistar rats was induced by streptozotocin (STZ). After treatment with a dose of 25, 50, and 100 mg/kg/day orally for the next 60 days, autophagic (p62, LC3, and BECN1), apoptotic (BCL2, CASP-3, and CASP9), inflammatory (IL-1 β , IL-6, TNF- α), and oxidative stress (CAT, SOD, and MDA) markers in protein and gene levels as well as cardiac function tests were measured.

Results: The findings revealed that long-term morin treatment improved weight gain, lipid and glycemic profile, hypertension, and cardiac hypertrophy and fibrosis in diabetic rats compared to controls (p-value<0.001). Moreover, the upregulation of BCL-2, LC3, and BECN1 along with the downregulation of p62, CASP-3, and CASP-9 revealed that morin suppressed apoptosis and promoted autophagy in the cardiac tissue of rats with diabetes (p-value<0.05). Additionally, the reduction in IL-1 β , IL-6, TNF- α , and MDA levels and the increment of SOD and CAT activity suggested that morin decreased inflammation and apoptosis in the heart of the rat models of diabetes (p-value<0.01).

Conclusion: These results may highlight the potential properties of morin as a therapeutic strategy for diabetic cardiomyopathy.

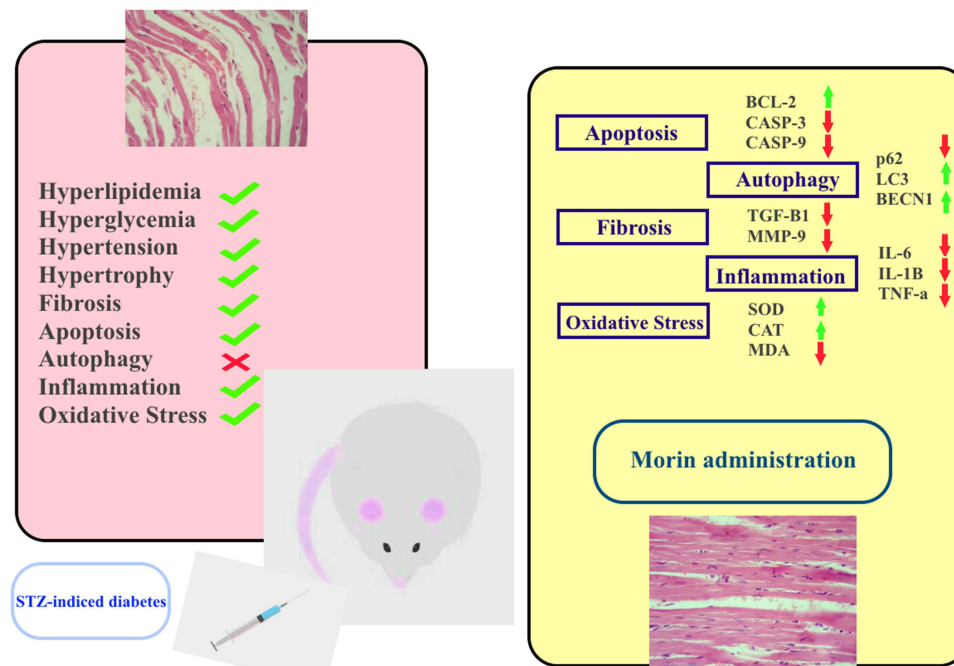
Keywords: morin, cardiomyopathy, heart failure, diabetes, complementary therapy

Introduction

Type 2 diabetes, also known as type 2 diabetes mellitus (T2DM), is a long-term condition marked by elevated glucose levels in the blood.¹ The underlying cause of type 2 diabetes is often a deficiency in insulin production by the pancreas or insulin resistance, where cells fail to respond effectively to insulin, leading to elevated blood glucose levels.² T2DM can be influenced by a combination of several factors, including obesity, a sedentary lifestyle, genetic predispositions, and insulin resistance.³ It is documented that T2DM can lead to cardiomyopathy and heart damage through several mechanisms such as myocardial lipotoxicity (where the excessive accumulation of lipids causes malfunction of cardiac cells), alterations in myocardial metabolism (eg impaired cellular and mitochondrial calcium handling, impaired cardiac insulin and glucose homeostasis, mitochondrial uncoupling, and oxidative stress), etc.^{4,5} Recent research indicates that elevated apoptosis,⁶ disrupted autophagic processes,⁷ oxidative stress,⁸ and sustained systemic inflammation⁹ are potential contributors to the onset and progression of diabetic cardiomyopathy (DCM). Since current therapeutic strategies have failed to manage DCM effectively, researchers are keen to find novel approaches capable of modulating the mentioned mechanisms.

Morin is a type of flavonol, a subset within the broader classification of flavonoids. These plant metabolites are distinguished by the presence of flavone and flavonol rings. The study of Morin has been extensive due to its potential

Graphical Abstract



health advantages and therapeutic impacts. Research indicates that morin plays a crucial role in numerous cellular functions, including inflammation regulation, apoptosis, autophagy, and oxidative stress mitigation. It achieves these effects by interacting with antioxidative enzymes and other signaling pathways like NF- κ B,¹⁰ PARP-1,^{11,12} p53,¹³ p21,¹⁴ and the metalloproteinase MMP-9.¹⁰

Despite the growing interest in morin therapy for diabetic diseases, the exact role of morin in managing DCM remains unclear. To address this gap, this study aimed to investigate the protective mechanisms of morin concerning cardiac dysfunction in diabetic rats.

Materials and Methods

Animals and Study Design

Healthy male Albino Wistar rats with weights ranging from 180 to 200 g were provided by the Animal Care and Handling Center of the university. Animals were kept in polypropylene cages on a 12/12 h day and night cycle, at 22 ± 2 °C. Animals were acclimatized with the environment and individuals for 7 days prior to the commencement of the experiment. The standard pellet diet was provided with fresh drinking water *ad libitum*. A single 60 mg/kg dose of streptozotocin (STZ), prepared by diluting with freshly prepared 0.1 M citrate buffer with maintained pH 4.5 was intraperitoneally (*i.p.*) injected to induce diabetes in the animals.

Before experiments began and after 48 h tail vein blood was collected to estimate blood glucose levels for each rat using a standard glucometer (SD Biosensor, Republic of Korea), as animals with a blood glucose concentration of 200 mg/dl or more were included in the study. 36 animals were alienated randomly into 6 groups, each containing 6 rats, as follows:

- Group I: Normal controls received 0.5 mL/100 g saline solution.
- Group II: Diabetic controls received 0.5 mL/100 g saline solution.
- Group III: Received morin orally at 25 mg/kg/day.
- Group IV: Received morin orally at 50 mg/kg/day.

Group V: Received morin orally at 100 mg/kg/day.

Group VI: Received metformin (350 mg/kg/day) as a positive control.

The procedure of treatment continued for 60 days and animals were treated as mentioned above. After 60 days animals were sacrificed under ketamine 10% (Bremer Pharma GMBH, 34414 Warburg, Germany) and xylazine 2% (Alfasan, Woerden, Holland) anesthesia, and then 5 mL blood samples were collected by cardiac puncture, maintained at room temperature for 15 minutes, and centrifuged at 2000 RPM. Serum samples were aliquoted and stored at -20°C for further biochemical analyses. Also, cardiac tissues from all animals were removed, washed with sterile PBS, and stored at -80°C for further analyses.

Blood Pressure and Cardiac Hypertrophy Assessment

The systolic blood pressure (SBP) was documented weekly benefiting from the CODA tail-cuff system (Kent Scientific in Torrington, USA). To avoid any interference from the circadian rhythm, SBP analyses were taken precisely at the same time between 10 AM and 12 AM, and an average of 6 to 8 blood pressure records were computed to obtain the SBP value.

The body weights of all animals were measured every two weeks. Upon completion of the sacrifice procedure, the heart tissues were methodically extracted, sanitized using PBS, and preserved at a stable temperature of 4°C . The atria's appendages were precisely dissociated from the surrounding ventricular structures and blood vessels, which were then subjected to comprehensive dehydration processes. Subsequent to these preparatory steps, the weight of the ventricular tissue was determined. By computing the ratio of ventricular mass to the entire body weight, the extent of cardiac hypertrophy was assessed.

Histopathological Analysis

The isolated cardiac tissues were fixed in buffered formalin (10%) for one day and then tissue dehydration was performed using a graded series of alcohol. Next, tissues were embedded in paraffin to obtain sections with 5 mm thickness using a standard microtome (Viabrembo, Milan, Italy). Dewaxation of the sections was performed using xylene followed by hydration by ethanol, and finally, sections were rinsed with sterile water and stained using H&E (hematoxylin and eosin). Stained sections were assessed under a standard microscope (Nikon, Tokyo, Japan).

The Measurement of Metabolic Indices

Utilizing available commercial kits, the key serum biochemical components including high-density lipoprotein (HDL, #catalog number: 80059, Crystal Chem, Zaandam, Netherlands), low-density lipoprotein (LDL, #catalog number: 80069, Crystal Chem, Zaandam, Netherlands), triglyceride (TG, #catalog number: 10010303, Cayman Chemical, Czech Republic), total cholesterol [TC, #catalog number: MBS8305378, MyBioSource, USA], and glucose (#catalog number: 81693, Crystal Chem, Zaandam, Netherlands) were determined, according to the manufacturer's guidelines. At the end of the long-term dietary challenge, the *ip* glucose tolerance test (GTT) and insulin tolerance test (ITT) were performed according to previously published research (16).

Enzyme-Linked Immunosorbent Assay

The heart and aorta tissue from rats, approximately 500 mg in weight, underwent homogenization using a protease-inhibited RIPA solution. Cardiac biomarkers such as troponin T (#catalog number: MBS039759, MyBioSource, USA) and creatine kinase MB (CK-MB, (#catalog number: MBS2515061, MyBioSource, USA), along with inflammation markers like Interleukin (IL)-6 (#catalog number: ab234570, Abcam, USA), IL- 1β (#catalog number: ab255730, Abcam, USA), and tumor necrosis factor (TNF)- α (#catalog number: ab100785, Abcam, USA) were quantified using ELISA kits, based on the manufacturer's guidance. Moreover, the presence of apoptosis indicators (caspase [CASP]-3 [#catalog number: MBS018987, MyBioSource, USA], CASP-9 [#catalog number: MBS765858, MyBioSource, USA], and BCL-2 [#catalog number: MBS2515143, MyBioSource, USA]) were determined. Additionally, extracellular matrix reshaping, specifically matrix metalloproteinase-9 (MMP-9, #catalog number: MBS722532, MyBioSource, USA), autophagy markers (SQSTM1/p62 [#catalog number: MBS3809397, MyBioSource, USA], LC3 [#catalog number: MBS9428940,

MyBioSource, USA], and Beclin [BECN]-1 [#catalog number: MBS2706719, MyBioSource, USA]), and fibrotic indicators (transforming growth factor [TGF]- β 1 [#catalog number: MBS824788, MyBioSource, USA]) were measured using ELISA kits from MyBioSource, following the protocols recommended by the supplier.

Real-Time Quantitative PCR

Total RNA was extracted from heart and aorta tissues using the PureLink RNA Mini Kit (#catalog number: 12183018A, Thermo Fisher, USA) adhering to the manufacturer's directions. The RNA's purity and concentration were assessed with the Biotek Nanodrop system. After synthesizing cDNA with the High-Capacity cDNA Reverse Transcription Kit (# catalog number: 4368814, Thermo Fisher, USA) real-time quantitative PCR (RT-qPCR) analysis was conducted using the StepOne™ Real-Time PCR System (Applied Biosystems, USA) and Maxima SYBR Green qPCR Master Mix (#catalog number: K0253, Thermo Fisher, USA). Expression levels were normalized relative to GAPDH. The results were presented as fold changes calculated via the $2^{-\Delta\Delta CT}$ method. The specific primer sequences used in this study are listed in Table 1. A two-stage reaction protocol was executed, commencing with a 95°C denaturation stage for 5 minutes, followed by 45 cycles of 95°C for 15 seconds and 60°C for 15 seconds.

Oxidative Stress Markers

To assess the extent of oxidative stress in heart and aortic tissues from rats treated with homogenization, a quantitative evaluation was conducted to measure the concentrations of malondialdehyde (MDA, #catalog number: MBS268427), catalase [CAT, #catalog number], and superoxide dismutase (SOD) enzymes. This study utilized the ELISA assay kit supplied by MyBioSource, strictly following the manufacturer's guidelines.

Table 1 Primer Sequences

Primers		Sequences
GAPDH	F	5'-GGTGGACCTCATGGCCTACAT-3'
	R	5'-GCCTCTCTTGGCTCTCAGTATCCT-3'
		5'-TTCCCTCAATAAGCTGTTCTG CC-3' 5'-TGCTCTCTTTGCACTCCCTGG-3'
CASP3	F	5'-CAACAACGAAACCTCCGTGG-3'
	R	5'-CTGCTCCTTTTGGCTGTGATC-3'
CASP9	F	5'-AGCCAGATGCTGTCCCATAC-3'
	R	5'-CAGGAACCGCTCTTCTTGTC-3'
BCL-2	F	5'-TGTGGATGACTGACTACCTGAACC-3'
	R	5'-CAGCCAGGAGAAATCAAACAGAGG-3'
SQSTM1/p62	F	5'-CTAGGCATCGAGGTTGACATT-3'
	R	5'-CTTGCTGAGTACCACTCTTATC-3'
LC3	F	5'-GGTCCAGTTGTGCCTTTATTGA-3'
	R	5'-GTGTGTGGGTTGTGTACGTCG-3'
BECN1	F	5'-CGGAATTCTATGGAAGGGTCTAAGACGTCC-3'
	R	5'-CGGGATCCTCATTTGTTATAAAAATTGTGAGGACA-3'

Statistical Analysis

In the present investigation, all studied groups have been compared with each other. All data are represented as the mean \pm SD and the difference between studied groups was determined using one-way/two-way ANOVA followed by Tukey's posthoc test. For this purpose, SPSS version 24.0 (IBM, Chicago, IL, USA) was used, and graphics were drawn using GraphPad Prism version 8 (San Diego, CA, USA). The difference level of significance was set at p -value < 0.05 .

Results

Morin Ameliorated Weight Gain, Hypertension, and Cardiac Hypertrophy

The present findings showed that the weight gain in Group II, Group III, and Group IV was significantly increased compared to the controls (p -value <0.001). Although Group IV, Group V, and Group VI revealed significant differences from Group II, the comparison of weight gain between the animals of Group IV and Group V with Group I demonstrated a significant increase (p -value <0.05). Moreover, animals in groups Group II, Group III, and Group IV represented significantly higher SBP than controls (p -value <0.05). However, Group IV, Group V, and Group VI showed a remarkable decrease in SBP compared to Group II animals. Cardiac hypertrophy was another component evaluated by measuring the H/B weight ratio (Figure 1). The findings revealed that the H/B weight ratio in Groups II and III had a significant

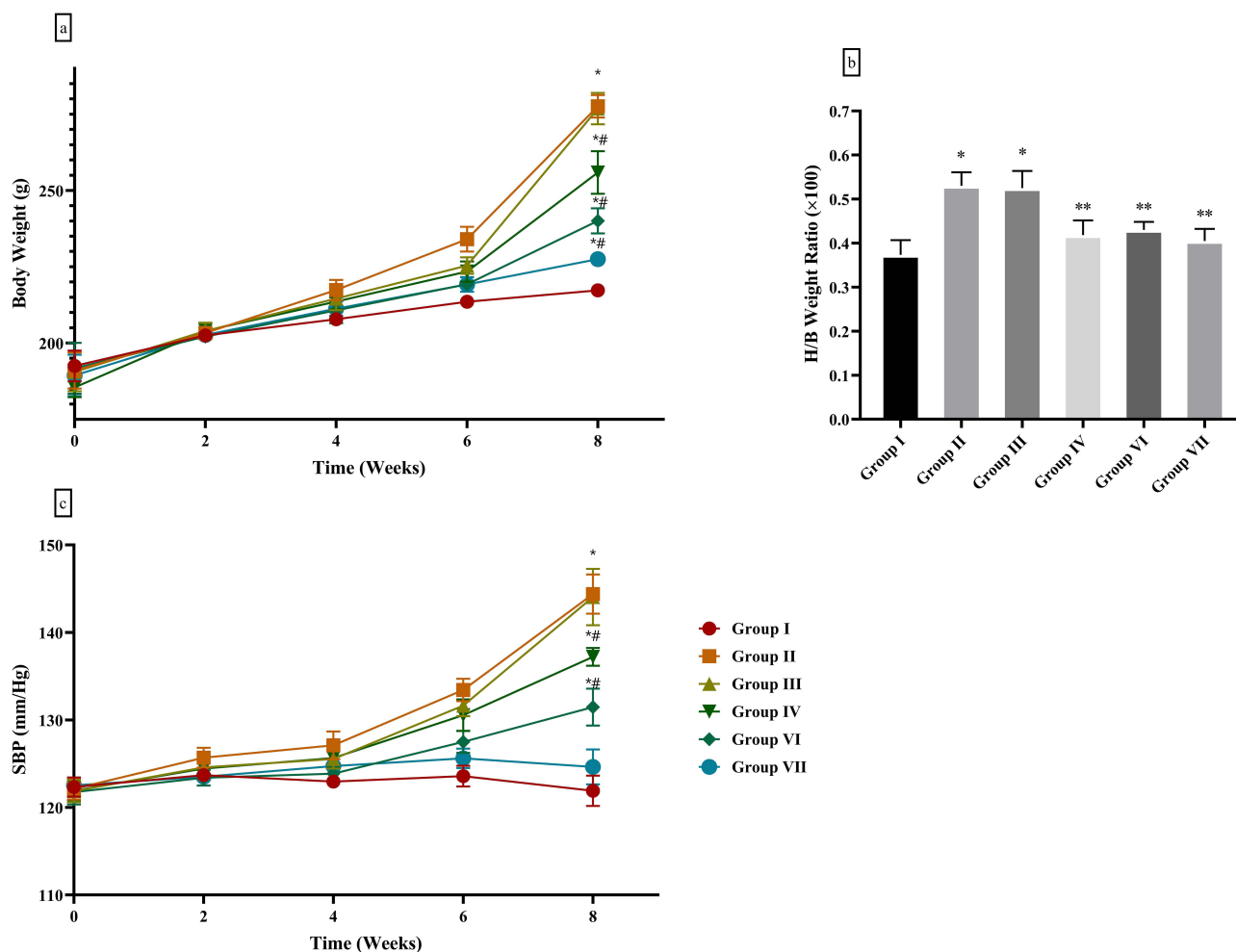


Figure 1 Morin prevented weight gain (a) and reduced H/B weight ratio (b) and SBP (c) in diabetic rats. The findings revealed that morin at a dose of 100 mg/kg/day prevented weight gain in diabetic animals. Moreover, the H/B weight ratio and SBP were significantly reduced when morin was administered. Group (I) normal controls; Group II: T2DM animals; Group III: T2DM animals received 25 mg/kg/day morin, Group IV: T2DM animals received 50 mg/kg/day morin, Group (V) T2DM animals received 100 mg/kg/day morin, Group VI: positive T2DM controls received 350 mg/kg/day metformin; *: significant difference only with Group I, **: significant difference only with Group II, #: significant difference with both Group I and Group II; the p -value <0.05 was considered significant.

increase compared to Group I (p -value <0.0001), although Group IV, group V, and Group VI were remarkably different from Group II animals (p -value <0.001).

Morin Improved Histopathology of Cardiac Tissue in Diabetic Rats

Histopathological examinations revealed that the cardiac tissue of Group I had striated cardiomyocytes with centrally located nuclei and anastomosed/branched cell fibers arranged in linear arrays were seen (Figure 2). However, lesser striation of cardiomyocytes with loss of anastomoses and intercalated discs was observed in both Group II and Group III. These pathological alterations in cardiac morphology were approximately improved in Group IV and Group VI. The histological examination of cardiac sections from Group V animals revealed an appearance similar to group I.

The Effects of Morin on Metabolic Factors

Lipid profile analysis was done by measuring HDL, LDL, TG, and TC levels (Figure 3). The findings showed that the levels of HDL in Group II and Group III had a significant decrease compared to Group I (p -value <0.0001). Although Group IV, Group V, and Group VI showed a significant increase in HDL levels compared to animals with T2DM (Group II), no significant difference was found between Group V and Group VI in comparison with Group I controls (p -value >0.05). Interestingly, LDL levels in all groups except Group VI had a significant increase compared to Group I controls (p -value <0.001), although Group IV and Group V revealed a remarkable decrease in comparison with Group II animals. Furthermore, the levels of TG and TC in all studied groups increased significantly compared to Group I controls (p -value <0.05), however, Group IV, Group V, and Group VI showed a remarkable decrease compared to Group II rats (p -value <0.05).

In addition, glycemic profile analysis was performed by evaluating levels of GTT, ITT, and glucose. Although GTT and ITT were significantly increased in Group II and Group III compared to Group I (p -value <0.0001), morin at doses of 50 mg/kg/day and 100 mg/kg/day caused a significant decrease when compared to Group II (p -value <0.001). Moreover, Group II, Group III, and Group IV caused a significant increase in glucose levels by 59.65%, 37.03%, and 25.23%, respectively, compared to Group I. However, the comparison of Group I with Group V and Group VI showed no

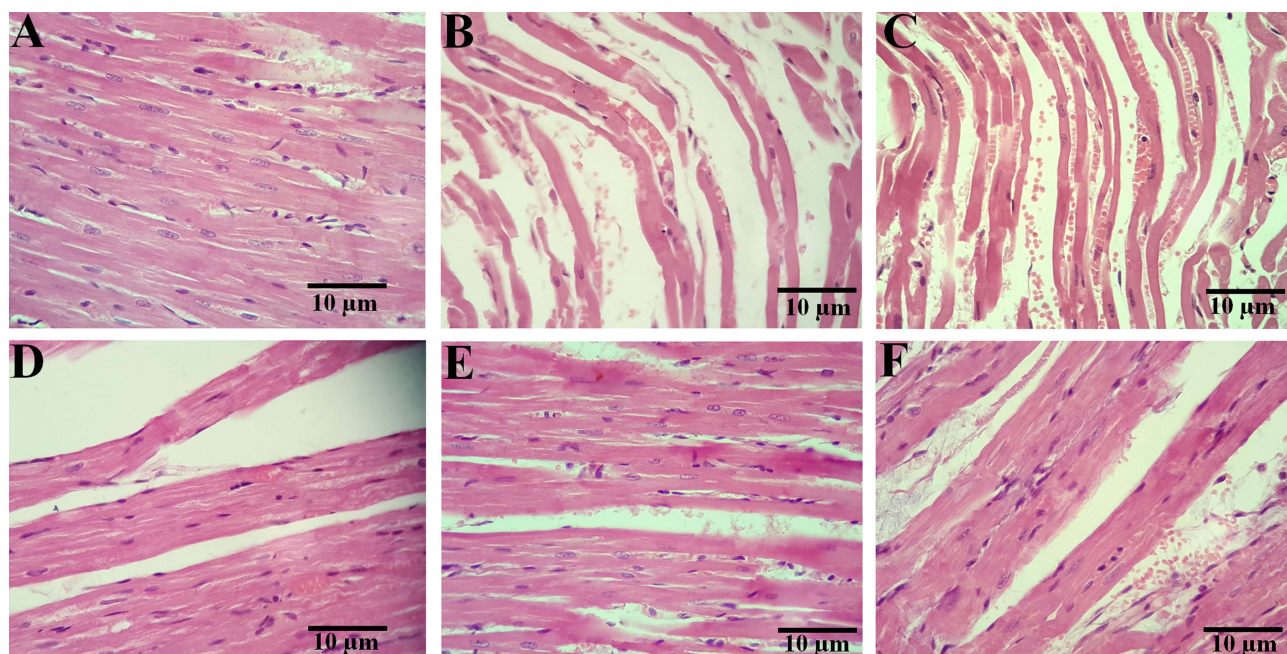


Figure 2 Histopathological examination. In both Group I (A) and Group V (E) branched and anastomosed fibers were arranged in linear arrays, the nuclei were located centrally, and cardiomyocytes appeared striated. However, the histopathology of cardiac tissue in Group II and Group III (C) showed loss of anastomoses and intercalated discs with reduced striation of cardiomyocytes. Group IV (D) and Group VI (F) revealed improved striation. H&E examination was performed. Group (I) normal controls; Group II: T2DM animals; Group III: T2DM animals received 25 mg/kg/day morin, Group IV: T2DM animals received 50 mg/kg/day morin, Group (V) T2DM animals received 100 mg/kg/day morin, Group VI: positive T2DM controls received 350 mg/kg/day metformin. H&E staining was performed.

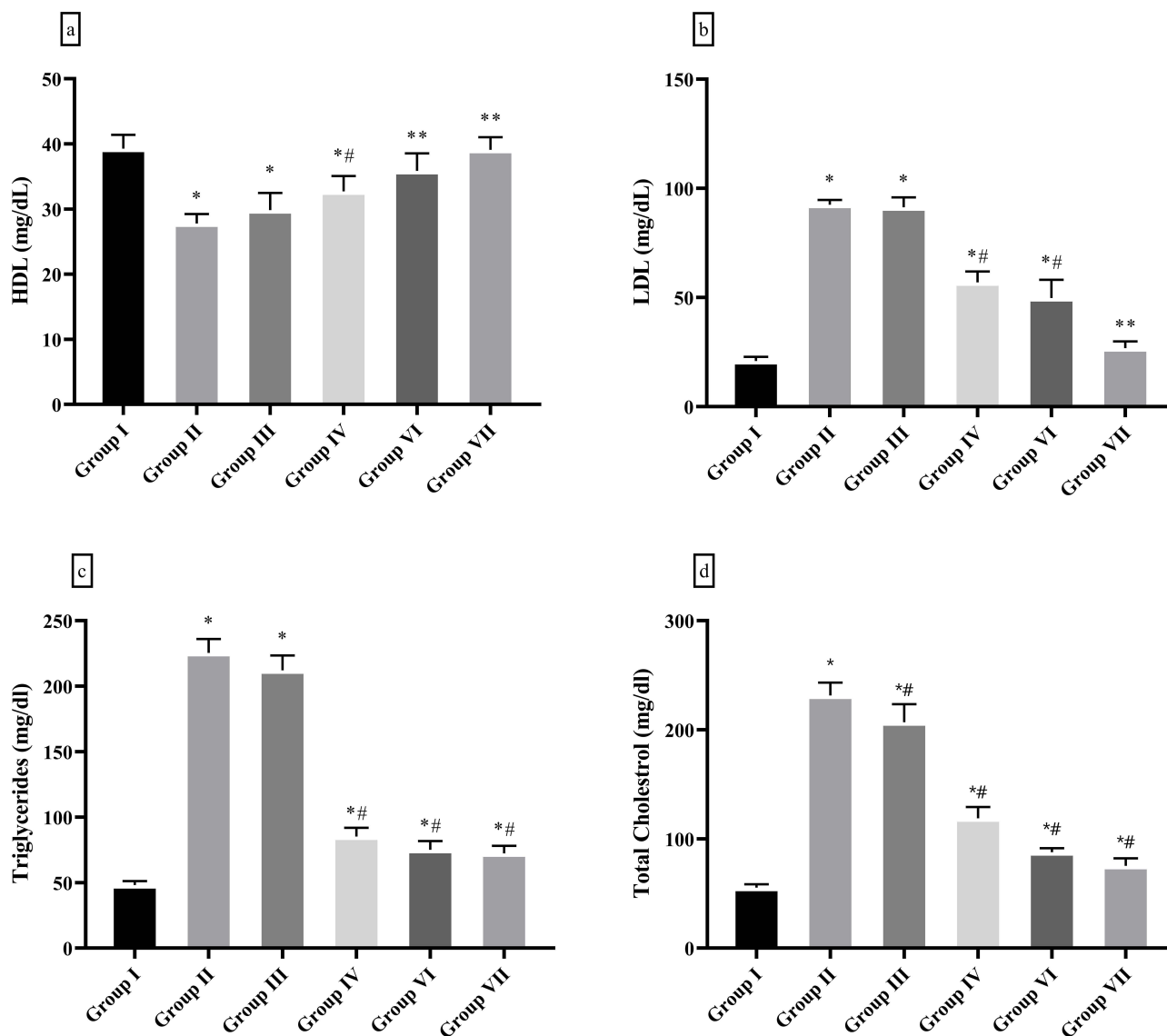


Figure 3 The analysis of lipid profile. Morin increased the levels of HDL (a) while reducing the levels of LDL (b), TG (c), and TC (d) in rats with T2DM. Group (I) normal controls; Group II: T2DM animals; Group III: T2DM animals received 25 mg/kg/day morin, Group IV: T2DM animals received 50 mg/kg/day morin, Group (V) T2DM animals received 100 mg/kg/day morin, Group VI: positive T2DM controls received 350 mg/kg/day metformin; *: significant difference only with Group I, **: significant difference only with Group II, *#: significant difference with both Group I and Group II; the p-value<0.05 was considered significant.

remarkable difference with Group I (p-value>0.05). Furthermore, animals treated with morin at doses of 25 mg/kg/day, 50 mg/kg/day, and 100 mg/kg/day, as well as 350 mg/kg/day of metformin, caused a significant decrease in glucose levels when compared to Group II animals (p-value<0.001, Figure 4).

Apoptosis Suppression in Cardiac Tissue of Rats with T2DM by Morin

Quantification of gene expression and protein levels of BCL-2, CASP-3, and CASP-9 was performed to analyze apoptosis in cardiac tissue using RT-qPCR and ELISA techniques (Figure 5). The findings showed that the expression of the *BCL-2* gene in the cardiac tissue of Group II rats was significantly reduced when compared with Group I (p-value<0.001), however, the treatment with morin at doses of 25 mg/kg/day, 50 mg/kg/day, and 100 mg/kg/day and 350 mg/kg/day of metformin did not determine a remarkable difference with Group I (p-value>0.05). In addition, the level of BCL-2 protein in Group II and Group III was reduced remarkably by 33.13% and 24.91%, respectively,

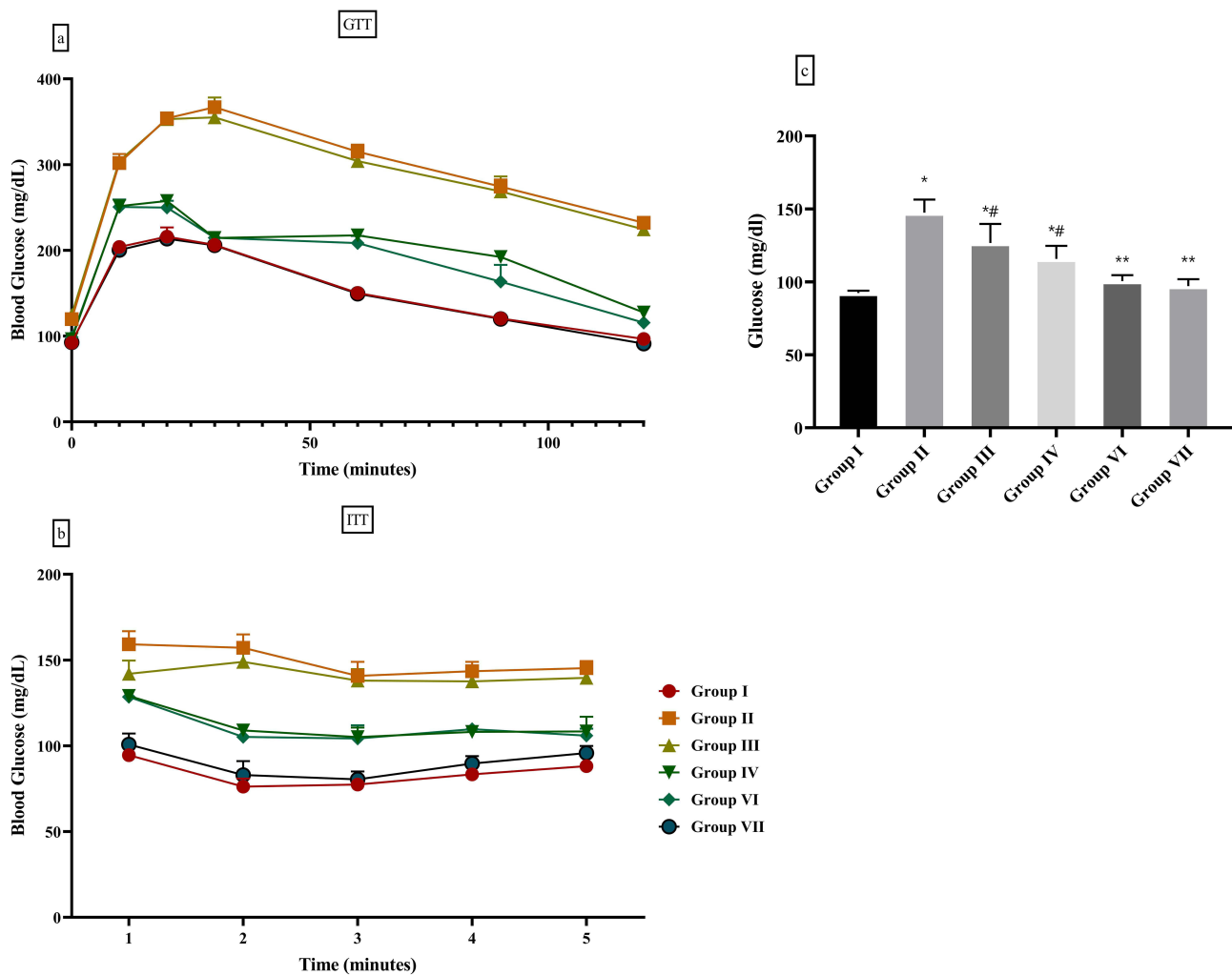


Figure 4 Morin improved glycemic profile in diabetic rats. The findings demonstrated that morin ameliorated GTT (a), ITT (b), and blood glucose levels (c) when administrated to diabetic animals. Group (I) normal controls; Group II: T2DM animals; Group III: T2DM animals received 25 mg/kg/day morin, Group IV: T2DM animals received 50 mg/kg/day morin, Group (V) T2DM animals received 100 mg/kg/day morin, Group VI: positive T2DM controls received 350 mg/kg/day metformin; *: significant difference only with Group I, **: significant difference only with Group II, *#: significant difference with both Group I and Group II; the p-value<0.05 was considered significant.

compared to Group I. Although the level of BCL-2 in Group V and Group VI rats was not significantly different from Group I (p-value>0.05), it showed a remarkable increase compared to Group II animals (p-value<0.001).

Interestingly, the expression of *CASP-3* and *CASP-9* genes demonstrated no significant difference between the studied groups (p-value>0.05). Meanwhile, the level of *CASP-3* and *CASP-9* proteins in the cardiac tissue of Group II rats was significantly increased by 79.14% and 57.34% when compared to controls (p-value<0.0001). However, the doses of 50 mg/kg/day and 100 mg/kg/day of morin as well as the treatment of rats with 350 mg/kg/day of metformin caused a remarkable decrease in the protein levels of *CASP-3* and *CASP-9* compared to Group II animals (p-value<0.001).

Morin Promoted Autophagy in the Cardiac Tissue of Diabetic Rats

The present study performed RT-qPCR and ELISA approaches to evaluate the expression levels of p62, LC3, and BECN1 at gene and protein levels in cardiac tissue (Figure 6). The findings showed that in Group II rats, gene expression and protein level of p62 were significantly increased by 1.9 times and 3.29 times, respectively (p-value<0.001). Although morin at a dose of 25 mg/kg/day could not induce a remarkable difference with Group II rats in terms of gene expression and p62 protein level, Group IV, Group V, and Group VI revealed a remarkable decrease compared to Group II. On the contrary, the expression of *LC3* and *BECN1* genes in the cardiac tissue of Group II rats was significantly decreased by

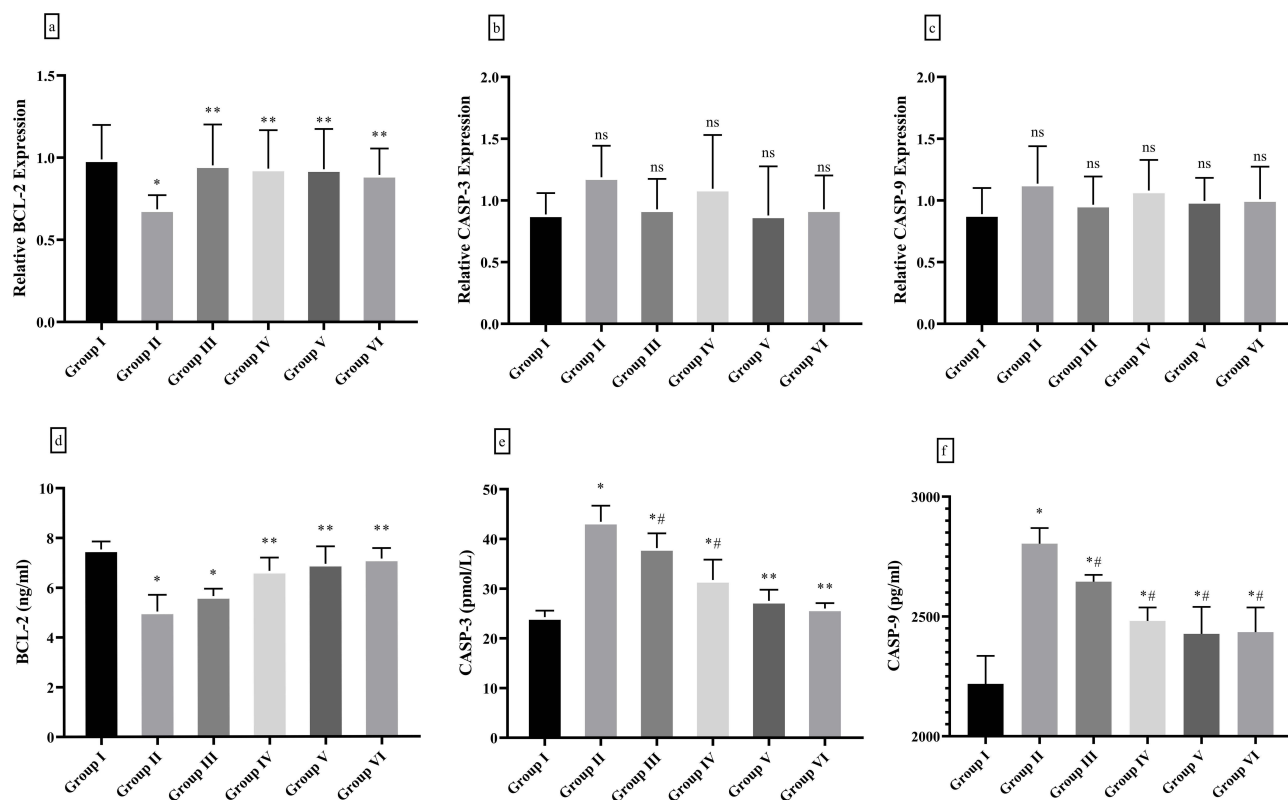


Figure 5 Apoptosis in cardiac tissue. The expression of BCL-2 at gene (a) and protein (d) levels were increased when morin was administrated to diabetic animals, whereas CASP-3 (b) and (e) and CASP-9 (c and f) gene and protein levels were reduced upon morin administration. Group (I) normal controls; Group II: T2DM animals; Group III: T2DM animals received 25 mg/kg/day morin, Group IV: T2DM animals received 50 mg/kg/day morin, Group (V) T2DM animals received 100 mg/kg/day morin, Group VI: positive T2DM controls received 350 mg/kg/day metformin; *: significant difference only with Group I, **: significant difference only with Group II, #: significant difference with both Group I and Group II, ns: significant difference neither with Group I nor with Group II; the p-value<0.05 was considered significant.

41.24% and 45.31% respectively (p-value<0.0001), as protein levels of LC3 and BECN1 in Group II and Group III significantly decreased by 24.22 and 46.1%, respectively, compared to Group I (p-value<0.0001). In terms of the expression of *LC3* and *BECN1* genes, only the dose of 100 mg/kg/day of morin did not cause a significant difference with Group I (p-value>0.05), whereas Group V and Group VI represented a significant increase in the level of LC3 and BECN1 proteins compared to Group II animals (p-value<0.001).

Morin-Induced Prevention of Cardiac Injury, Inflammation, and Oxidative Stress in Diabetic Animals

Cardiac damage was investigated by measuring troponin T, CK-MB, MMP-9, and TGF- β 1 markers using ELISA technique in the cardiac tissue of the studied groups (Figure 7). The present findings showed a significant increase of 15.10 times, 1.76 times, 1.43 times, and 3.57 times in the levels of troponin T, CK-MB, MMP-9, and TGF- β 1, respectively, in group II animals compared to Group I (p-value<0.0001). Although treatments of Group II animals with morin at doses of 25 mg/kg/day, 50 mg/kg/day, and 100 mg/kg/day, as well as 350 mg/kg/day of metformin, caused a remarkable decrease in the level of troponin T compared to Group II (p-value<0.05), a significant increase was also found when compared with Group I (p-value<0.01). In terms of CK-MB activity, all groups treated with morin at doses of 25 mg/kg/day, 50 mg/kg/day, and 100 mg/kg/day, and metformin at a dose of 350 mg/kg/day showed a considerable decrease compared to Group II (p-value<0.01), although only Group VI was not significantly different from Group I (p-value>0.05). Interestingly, the level of MMP-9 in animals treated with 50 mg/kg/day and 100 mg/kg/day of morin did not show a significant difference with Group I (p-value>0.05). Furthermore, treatment with doses of 50 mg/kg/day and 100 mg/kg/day of morin, as well as 350 mg/kg/day of metformin caused a significant decrease of 35.59%, 37.43%,

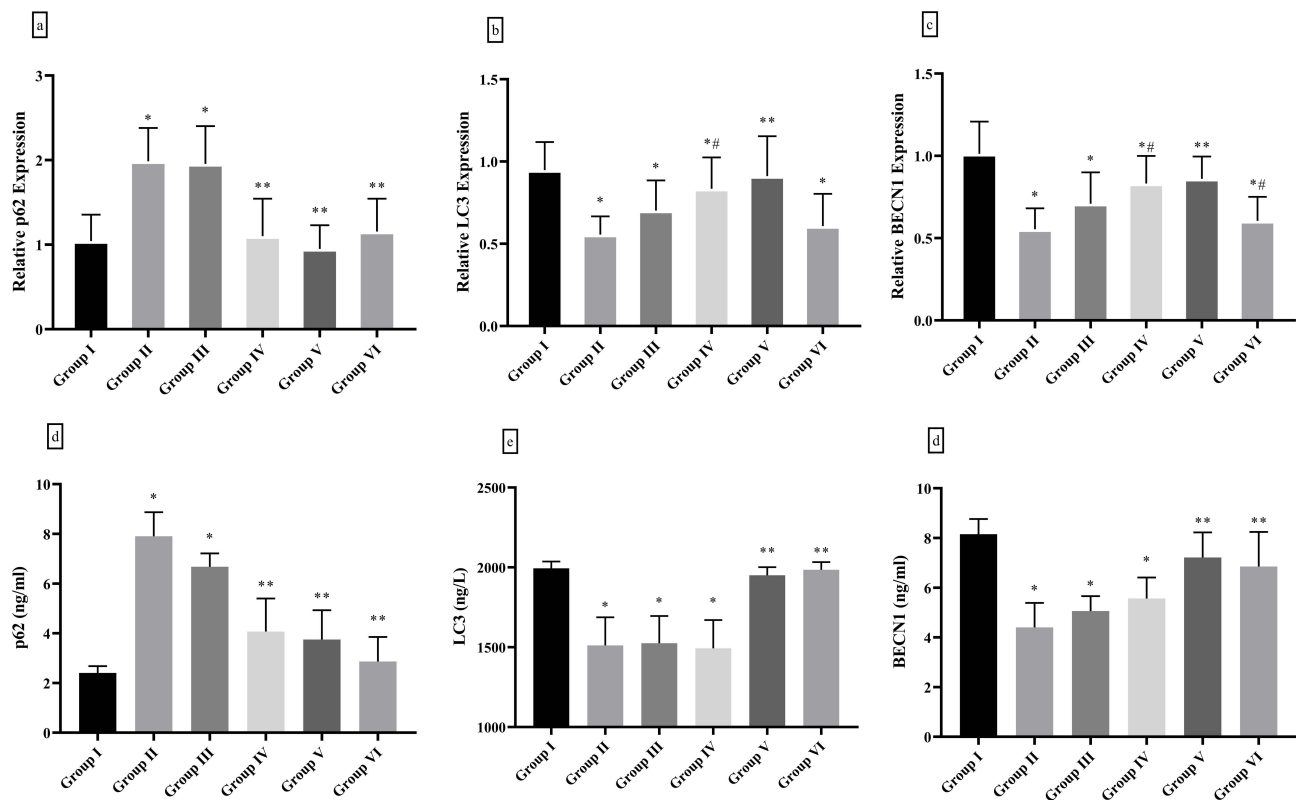


Figure 6 Morin promoted autophagy in cardiac tissue. Gene and protein levels of p62 (a and d), LC3 (b and e), and BECN1 (c and f) were analyzed. Group (I) normal controls; Group II: T2DM animals; Group III: T2DM animals received 25 mg/kg/day morin, Group IV: T2DM animals received 50 mg/kg/day morin, Group (V) T2DM animals received 100 mg/kg/day morin, Group VI: positive T2DM controls received 350 mg/kg/day metformin; *: significant difference only with Group I, **: significant difference only with Group II, *#: significant difference with both Group I and Group II; the p -value <0.05 was considered significant.

and 70.88%, respectively, when compared to Group II rats. Nevertheless, only Group VI did not cause a remarkable difference when compared to Group I (p -value >0.05).

Additionally, the current study measured levels of IL-1, IL-6, and TNF- α to evaluate inflammation and the activity of SOD and CAT enzymes along with MDA levels to evaluate oxidative stress (Table 2). The findings showed that Group II rats had remarkably increased levels of all three measured inflammatory markers compared to Group I (p -value <0.0001). Interestingly, doses of 50 mg/kg/day and 100 mg/kg/day of morin, as well as 350 mg/kg/day of metformin caused a significant difference with both Group I and Group II in terms of IL-1 and IL-6 levels. However, cardiac levels of TNF- α in Group VI were not remarkably different from Group I (p -value >0.05). Furthermore, Group II showed a considerable decrease in the activity of SOD and CAT and a significant increase in the level of MDA compared to Group I (p -value <0.0001). However, the dose of 100 mg/kg/day of morin along with 350 mg/kg/day of metformin demonstrated the most desired performance in improving the level of oxidative stress markers.

Discussion

A plethora of evidence has suggested a strong association between diabetes and heart failure as approximately one-third of patients with heart failure have diabetes and also similar risk factors such as hypertension, obesity, chronic kidney disease, and dyslipidemia are shared by these two common diseases.^{15–17} The current treatment strategies generally focus on lifestyle modification, although the outcome of these strategies is mostly unfavorable, which has worsened the management of DCM. Recently, a lot of attention has been paid to the characteristics of herbal compounds to restore the factors involved in the occurrence and progression of DCM by modulating the intracellular pathways resulting in the consideration of herbals as novel complementary treatment options.^{18–20} The present study aimed to administer different

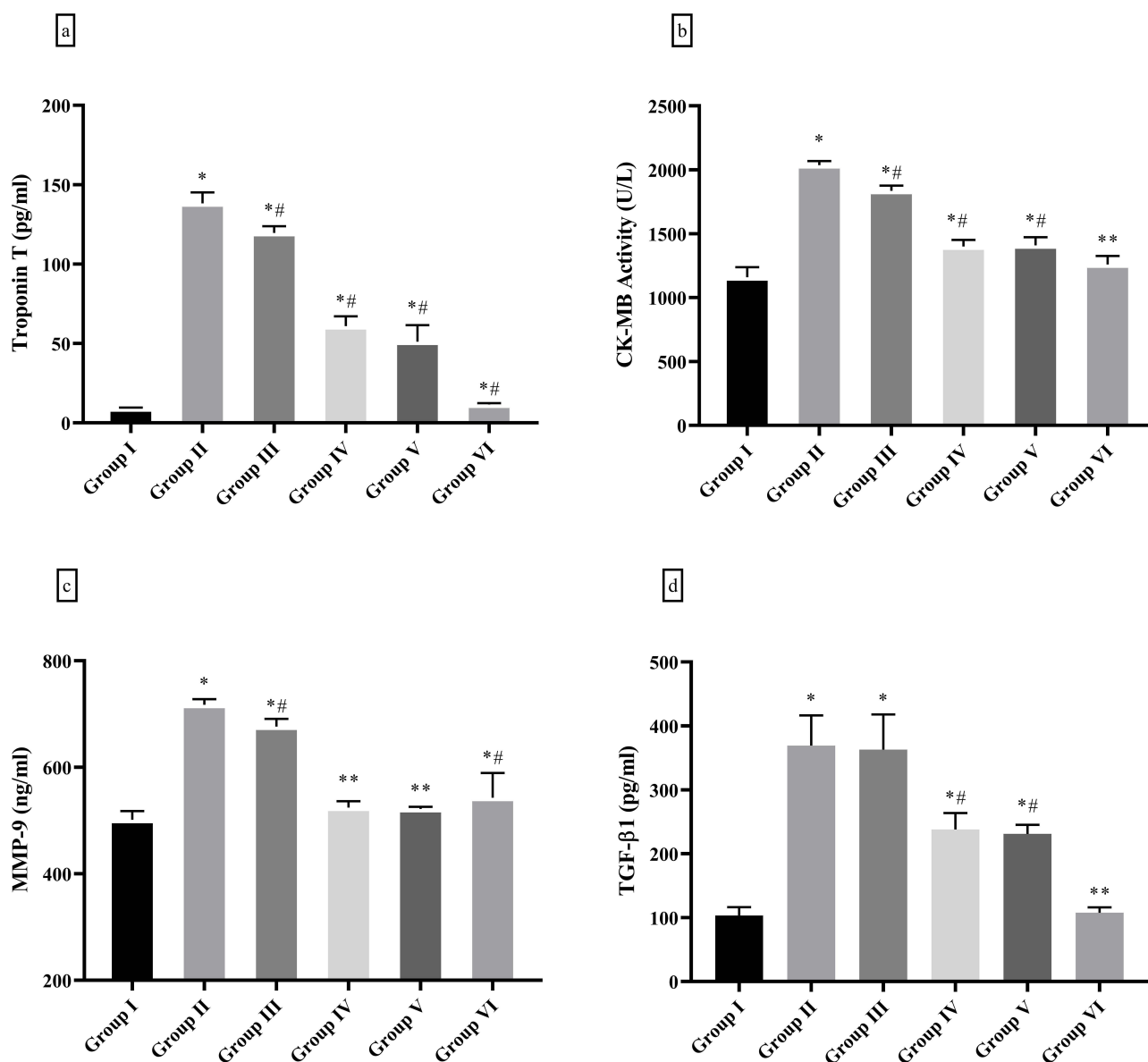


Figure 7 The levels of cardiac markers. Morin reduced the levels of troponin T (a), CK-MB (b), MMP-9 (c), and TGF-β1 (d) in rats with diabetes. Group (I) normal controls; Group II: T2DM animals; Group III: T2DM animals received 25 mg/kg/day morin, Group IV: T2DM animals received 50 mg/kg/day morin, Group (V) T2DM animals received 100 mg/kg/day morin, Group VI: positive T2DM controls received 350 mg/kg/day metformin; *: significant difference only with Group I, **: significant difference only with Group II, *#: significant difference with both Group I and Group II; the p-value<0.05 was considered significant.

doses of morin to diabetic rats and evaluate its effects in improving cardiac damage by measuring weight, blood pressure, lipid profile, glycemic profile, apoptosis, autophagy, inflammation, and oxidative stress.

The obtained data revealed that morin, particularly at a dose of 100 mg/kg/day, was able to prevent weight gain and hypertension in diabetic animals with a comparable approach to a dose of 350 mg/kg/day of metformin. Since the majority of diabetic patients are people with obesity, overweight has traditionally been assumed to be one of the risk factors associated with morbidity and mortality due to diabetes progression. Therefore, losing weight or preventing weight gain has been considered one of the most important strategies for glycemic management and dealing with the development of diabetes.^{21,22} Along with that, excessive weight is associated with hypertension and cardiovascular disorders, therefore, the obesity of patients with diabetes is listed as one of the key factors leading diabetes to heart failure.^{23,24} The findings of the present study showed that morin was able to improve SBP and cardiac hypertrophy comparable to metformin. It has already been established that hypertension is one of the major contributors to cardiac

Table 2 Morin Alleviated Inflammation and Stress in the Cardiac Tissue of Diabetic Animals

Markers	Group I	Group II	Group III	Group IV	Group V	Group VI
IL-1	130.28±5.88	344.62±13.13*	283.08±8.34*#	196.10±7.66*#	196.04±9.39*#	176.66±37.21*#
IL-6	254.11±8.64	441.34±17.42*	398.13±16.39*#	304.64±15.54*#	315.68±15.22*#	293.39±20.00*#
TNF- α	17.46±1.18	35.62±0.82*	33.89±2.04*	26.23±1.55*#	25.35±2.03*#	17.71±1.22**
SOD	7.24±0.19	5.40±0.93*	6.52±0.37*#	6.56±.37**	8.10±0.63**	7.35±.71**
CAT	95.99±2.86	69.99±11.38*	66.93±6.21*	83.09±11.91ns	100.73±4.86**	96.75±3.57**
MDA	1.64±0.28	3.45±0.27*	3.50±0.25*	2.41±0.29*#	2.67±0.30*#	1.96±0.07**

Notes: Group I: normal controls; Group II: T2DM animals; Group III: T2DM animals received 25 mg/kg/day morin, Group IV: T2DM animals received 50 mg/kg/day morin, Group V: T2DM animals received 100 mg/kg/day morin, Group VI: positive T2DM controls received 350 mg/kg/day metformin; *: significant difference only with Group I, **: significant difference only with Group II, *#: significant difference with both Group I and Group II, ns: significant difference neither with Group I nor with Group II; the p-value<0.05 was considered significant.

dysfunction and hypertension-induced hypertrophic remodeling occurs prevalently in patients with diabetes.^{25,26} Similarly, insulin resistance and disruption of lipid and glycemic profiles have been assumed to be the leading factors of cardiovascular disorders caused by diabetes.^{27,28} In addition, the current findings revealed that the administration of morin was followed by a significant improvement in DCM-induced histopathological alterations in cardiac tissue including lesser striation of cardiomyocytes with loss of anastomoses and intercalated discs, which are described as necrosis previously.²⁹ Concordant to the findings of the present study, the ability of morin to improve the metabolic profile and confront obesity has been clarified by a variety of previous research.^{30–32} Although the ameliorative properties of morin in diabetes-caused cardiac damage and underlying molecular mechanisms have been investigated for the first time by the present study.

The myocardium is known as the main source of CK-MB³³ and troponin T is a hallmark of myocardial injury.¹ In addition to myocardial damage, cardiac fibrosis is another event that consists of the processes of repair, reformation, and replacement of normal tissue with overgrowth of cardiac tissue, which leads to excessive deposition of extracellular matrix, initiation of inflammatory responses, and heart failure. Fibroblasts are key contributors to cardiac homeostasis and tissue repair after injury,³⁴ where TGF- β 1 plays a significant role in the remodeling/repair of cardiac tissue, and modification of the function and phenotype of fibroblasts, cardiomyocytes, and vascular cells.³⁵ Also, due to the ability of MMPs, especially MMP-9, to remove the extracellular matrix, they have been assumed to be strongly related to myocardial infarction and left ventricular dysfunction.^{36,37} The findings of the present study demonstrated a significant increase in the levels of troponin T, MMP-9, TGF- β 1, and CK-MB activity in diabetic animals, which indicates tissue fibrosis and heart damage caused by diabetes. Interestingly, morin at a dose of 100 mg/kg/day showed the potential to restore tissue damage, although its ability was significantly lower than that of metformin. As previously discussed, morin has been shown to improve lipid and glycemic profiles, hypertension, and weight gain in diabetic animals,^{38–40} all of which are considered risk factors for diabetic heart damage. In addition, heart damage may be caused by disruption of main cellular mechanisms such as apoptosis, autophagy, inflammation, and oxidative stress, which are discussed below.

It is widely suggested that cardiac injury caused by diabetes is accompanied by cardiomyocyte death and dysfunction,^{41,42} hence regulated death programs may play a role in these pathological events. Apoptosis is the most well-known form of programmed cell death,⁴³ while autophagy is a catabolic pathway with a dual role consisting of cell survival or providing a pathway for regulated cell death.⁴⁴ The present findings indicated the downregulation of BCL-2 and p62 in the heart tissue of diabetic rats compared to controls, while CASP-3, CASP-9, LC3, and BECN1 were upregulated. BCL-2, the main member of an apoptotic family known as the BCL-2 family, acts as the main inhibitor of the apoptotic pathway, whereas CASPs are considered functional proteases in the apoptotic cascade, whose activation is associated with the induction of apoptotic cell death.⁴⁵ In addition, p62 is a negative regulator of autophagic flux that potentially inhibits autophagy, whereas LC3 and BECN1 are of main proteins involved in the autophagic pathway and their function leads to the formation of autophagolysosomes and the breakdown of unnecessary cellular structures. Together, the obtained data indicate the promotion of apoptosis and the suppression of autophagy in the heart tissue of animals with T2DM. Interestingly, administration of doses of 50 mg/kg/day and 100 mg/kg/day of morin led to the

amelioration of pathological alterations induced by diabetes on the pathways of apoptosis and autophagy in heart tissue. Previously, apoptosis inhibitors and autophagy inducers were proposed as novel strategies for the management of diabetes-related cardiac injury.^{46,47} Therefore, morin as a natural promoter of autophagy⁴⁸ may be an ideal option, especially as a complementary treatment, to deal with cardiac damage. Contradictory, several studies have suggested that the prevention of autophagy protects against cardiac injury caused by diabetes.^{49,50} Importantly, autophagy is adaptive in most diet-induced T2DM models, hence autophagy enhancers represent protective characteristics against DCM.^{51,52} Moreover, genetic deletion or pharmacological inhibition of autophagy-negative regulators represent ameliorative properties against cardiac injury in diabetic models.^{51,52} Nevertheless, further studies are encouraged to reveal the exact role of autophagy in diabetic cardiomyopathy and the potential of this pathway as a therapeutic strategy.

Apoptosis and autophagy, as two intracellular signaling pathways, provide beneficial interactions with other cell processes such as inflammation and oxidative stress. In fact, the induction of oxidative stress and inflammation can be assumed to be the factors that initiate and promote apoptosis and autophagy.^{53,54} Accordingly, the obtained results showed that the heart tissue of diabetic rats had an increased level of inflammatory markers (IL-6, IL-1 β , and TNF- α), suppression of enzymes involved in antioxidant defense (including SOD and CAT), and increased lipid peroxidation (indicated by MDA levels). Concordantly, in the present study, morin was able to effectively suppress inflammation and oxidative stress, which was probably involved in preventing apoptosis and inducing autophagy in heart tissue. Improving the function of enzymes involved in the response to free radicals is pivotally important in cardioprotection in diabetic patients. It has been shown by different studies that the increase of SOD activity improves cardiac mitochondria while inhibition of CAT activity leads to damage to DNA and induction of apoptosis in cardiomyocytes.^{55,56} In addition, the overproduction of free radicals in the cardiac tissue of diabetic samples occurs with excessive levels of pro-inflammatory cytokines such as TNF- α and IL-6, which leads to myocardial inflammation and deteriorates cardiac damage.⁵⁷ Anti-inflammatory and antioxidant activity are among the main characteristics of plant compounds, which has led to their proposal as therapeutic complements for chronic diseases such as diabetes, cancer, infertility, etc.^{58–60} It has been previously suggested that morin exerts its anti-inflammatory and anti-oxidative stress properties through the modulation of upstream regulators such as mTOR, NF- κ B, NR4A2, and IP3R, which may also be involved in the regulation of programmed cell death.^{61,62} Although the present study did not aim to investigate the upstream signaling pathways, it is encouraged to direct further studies to clarify.

As noted by Jasińska-Stroschein, rodent models of DCM could be developed by induction of diabetes.⁶³ However, the differences with the disease in humans should be considered one of the major limitations of any animal investigation, including the present study. In addition, the lack of investigation of the upstream regulatory pathways and the application of further experiments such as Western blot, immunohistochemistry, etc. are other limitations of the present study. Therefore, it is necessary to carry out more studies in order to clarify the molecular mechanisms involved in the occurrence of therapeutic properties of morin and also to evaluate the feasibility of therapeutic effects of morin by clinical trials.

Conclusion

The findings of the present study revealed that morin alleviated weight gain, metabolic disruption, insulin resistance, hypertension, and cardiac hypertrophy caused by diabetes. Moreover, the administration of morin improved cardiac histological and biochemical markers, prevented fibrosis and myocardial infarction, suppressed apoptosis, induced autophagy, and reduced inflammation and oxidative stress in cardiac tissue in a rat model of T2DM. The obtained data may indicate the potential of morin as a complementary treatment for cardiac damage caused by diabetes. However, further studies including animal studies with more specific methods (eg electron microscopy, Western blotting, etc.) and clinical trials are required to validate these findings.

Key Messages

- Morin alleviated diabetic-induced cardiac hypertrophy, fibrosis, and hypertension and improved glycemic and lipid profiles.

- The suppression of apoptosis may contribute to the alleviation of diabetic-induced cardiomyopathy.
- Morin was able to promote autophagy and reduce inflammation and oxidative stress in the cardiac tissue.

Data Sharing Statement

The datasets used and/or analyzed during the current study are available from the corresponding author upon reasonable request.

Ethics Approval and Consent to Participate

The present study was designed and performed based on the international guidelines related to animal care and the National Institute of Health (NIH). The use of animals and procedures of this study were reviewed and approved by Xi'an Zhongkai Animal Experiments Medical Research Ethics (No. 12979).

Author Contributions

All authors made a significant contribution to the work reported, whether that is in the conception, study design, execution, acquisition of data, analysis and interpretation, or in all these areas; took part in drafting, revising or critically reviewing the article; gave final approval of the version to be published; have agreed on the journal to which the article has been submitted; and agree to be accountable for all aspects of the work.

Funding

There is no funding to report.

Disclosure

The authors declare that they have no competing interests.

References

1. Ahmad E, Lim S, Lamptey R, Webb DR, Davies MJ. Type 2 diabetes. *Lancet*. 2022;400(10365):1803–1820.
2. Shah AS, Nadeau KJ, Dabelea D, Redondo MJ. Spectrum of phenotypes and causes of type 2 diabetes in children. *Ann Rev Med*. 2022;73(1):501–515. doi:10.1146/annurev-med-042120-012033
3. Schnurr TM, Jakupović H, Carrasquilla GD, et al. Obesity, unfavourable lifestyle and genetic risk of type 2 diabetes: a case-cohort study. *Diabetologia*. 2020;63(7):1324–1332. doi:10.1007/s00125-020-05140-5
4. Wang J, Song Y, Wang Q, Kralik PM, Epstein PN. Causes and characteristics of diabetic cardiomyopathy. *Rev Diabetic Stud*. 2006;3(3):108. doi:10.1900/RDS.2006.3.108
5. Boudina S, Abel ED. Diabetic cardiomyopathy, causes and effects. *Rev Endocr Metab Disord*. 2010;11:31–39. doi:10.1007/s11154-010-9131-7
6. Sun S, Yang S, Dai M, et al. The effect of Astragalus polysaccharides on attenuation of diabetic cardiomyopathy through inhibiting the extrinsic and intrinsic apoptotic pathways in high glucose-stimulated H9C2 cells. *BMC Complement Altern Med*. 2017;17(1):1–12. doi:10.1186/s12906-017-1828-7
7. Feidantsis K, Mellidis K, Galatou E, Sinakos Z, Lazou A. Treatment with crocin improves cardiac dysfunction by normalizing autophagy and inhibiting apoptosis in STZ-induced diabetic cardiomyopathy. *Nutr Metab Cardiovasc Dis*. 2018;28(9):952–961. doi:10.1016/j.numecd.2018.06.005
8. Xu N, Liu S, Zhang Y, et al. Oxidative stress signaling in the pathogenesis of diabetic cardiomyopathy and the potential therapeutic role of antioxidant naringenin. *Redox Rep*. 2023;28(1):2246720. doi:10.1080/13510002.2023.2246720
9. Kaur N, Guan Y, Raja R, Ruiz-Velasco A, Liu W. Mechanisms and therapeutic prospects of diabetic cardiomyopathy through the inflammatory response. *Front Physiol*. 2021;12:694864. doi:10.3389/fphys.2021.694864
10. Sivaramakrishnan V, Devaraj SN. Morin regulates the expression of NF- κ B-p65, COX-2 and matrix metalloproteinases in diethylnitrosamine induced rat hepatocellular carcinoma. *Chem Biol Interact*. 2009;180(3):353–359. doi:10.1016/j.cbi.2009.02.004
11. Singh MP, Cho HJ, Kim J-T, Baek KE, Lee HG, Kang SC. Morin hydrate reverses cisplatin resistance by impairing PARP1/HMGB1-dependent autophagy in hepatocellular carcinoma. *Cancers*. 2019;11(7):986. doi:10.3390/cancers11070986
12. Singh MP, Chauhan AK, Kang SC. Morin hydrate ameliorates cisplatin-induced ER stress, inflammation and autophagy in HEK-293 cells and mice kidney via PARP-1 regulation. *Int Immunopharmacol*. 2018;56:156–167. doi:10.1016/j.intimp.2018.01.031
13. Wei Z, He X, Kou J, et al. Renoprotective mechanisms of morin in cisplatin-induced kidney injury. *Int Immunopharmacol*. 2015;28(1):500–506. doi:10.1016/j.intimp.2015.07.009
14. Kuo H-M, Chang L-S, Lin Y-L, et al. Morin inhibits the growth of human leukemia HL-60 cells via cell cycle arrest and induction of apoptosis through mitochondria dependent pathway. *Anticancer Res*. 2007;27(1A):395–405.
15. C Thomas M. Type 2 diabetes and heart failure: challenges and solutions. *Curr Cardiol Rev*. 2016;12(3):249–255. doi:10.2174/1573403X12666160606120254
16. Ghosh N, Chacko L, Bhattacharya H, et al. Exploring the complex relationship between diabetes and cardiovascular complications: understanding diabetic cardiomyopathy and promising therapies. *Biomedicines*. 2023;11(4):1126. doi:10.3390/biomedicines11041126

17. Vijay K, Neuen BL, Lerma EV. Heart failure in patients with diabetes and chronic kidney disease: challenges and opportunities. *Cardiorenal Med.* 2022;12(1):1–10. doi:10.1159/000520909
18. Hu M, Li H, Ni S, Wang S. The protective effects of Zhi-Gan-Cao-Tang against diabetic myocardial infarction injury and identification of its effective constituents. *J Ethnopharmacol.* 2023;309:116320. doi:10.1016/j.jep.2023.116320
19. Huo S, Wang Q, Shi W, et al. ATF3/SPI1/SLC31A1 signaling promotes cuproptosis induced by advanced glycosylation end products in diabetic myocardial injury. *Int J Mol Sci.* 2023;24(2):1667. doi:10.3390/ijms24021667
20. Shabab S, Gholamnezhad Z, Mahmoodabady M. Protective effects of medicinal plant against diabetes induced cardiac disorder: a review. *J Ethnopharmacol.* 2021;265:113328.
21. Colditz GA, Willett WC, Rotnitzky A, Manson JE. Weight gain as a risk factor for clinical diabetes mellitus in women. *Ann Internal Med.* 1995;122(7):481–486.
22. Ross SA, Dzida G, Vora J, Khunti K, Kaiser M, Ligthelm RJ. Impact of weight gain on outcomes in type 2 diabetes. *Curr Med Res Opin.* 2011;27(7):1431–1438. doi:10.1185/03007995.2011.585396
23. De Boer IH, Bangalore S, Benetos A, et al. Diabetes and hypertension: a position statement by the American Diabetes Association. *Diabetes Care.* 2017;40(9):1273–1284. doi:10.2337/dci17-0026
24. Kaneko H, Itoh H, Yotsumoto H, et al. Association of body weight gain with subsequent cardiovascular event in non-obese general population without overt cardiovascular disease. *Atherosclerosis.* 2020;308:39–44. doi:10.1016/j.atherosclerosis.2020.05.015
25. Srivastava PM, Calafiore P, Macisaac RJ, et al. Prevalence and predictors of cardiac hypertrophy and dysfunction in patients with Type 2 diabetes. *Clin Sci.* 2008;114(4):313–320. doi:10.1042/CS20070261
26. van Bilsen M, Daniels A, Brouwers O, et al. Hypertension is a conditional factor for the development of cardiac hypertrophy in type 2 diabetic mice. *PLoS One.* 2014;9(1):e85078. doi:10.1371/journal.pone.0085078
27. Ning Z, Ai G, Chen B, et al. Impact of chiglitazar on glycemic control in type 2 diabetic patients with metabolic syndrome and insulin resistance: a pooled data analysis from two Phase III trials. *J Diabetes.* 2024;16(2):e13484. doi:10.1111/1753-0407.13484
28. Ormazabal V, Nair S, Elfeky O, Aguayo C, Salomon C, Zuñiga FA. Association between insulin resistance and the development of cardiovascular disease. *Cardiovasc Diabetol.* 2018;17:1–14.
29. Roslan J, Giribabu N, Karim K, Salleh N. Quercetin ameliorates oxidative stress, inflammation and apoptosis in the heart of streptozotocin-nicotinamide-induced adult male diabetic rats. *Biomed Pharmacother.* 2017;86:570–582. doi:10.1016/j.biopha.2016.12.044
30. Madkhali HA. Morin attenuates high-fat diet induced-obesity related vascular endothelial dysfunction in Wistar albino rats. *Saudi Pharm J.* 2020;28(3):300–307. doi:10.1016/j.jps.2020.01.009
31. Najm MA, Khalaf RM, Oudah KH. A study of the impact of morin extract on obesity diseases compared with some chemical drugs used in male rats with induced obesity. *Ann Roman Soc Cell Biol.* 2021;2198–2207.
32. Prahalthan P, Saravanakumar M, Raja B. The flavonoid morin restores blood pressure and lipid metabolism in DOCA-salt hypertensive rats. *Redox Rep.* 2012;17(4):167–175. doi:10.1179/1351000212Y.0000000015
33. Parsanathan R, Jain SK. Novel invasive and noninvasive cardiac-specific biomarkers in obesity and cardiovascular diseases. *Metab Syndr Relat Disord.* 2020;18(1):10–30. doi:10.1089/met.2019.0073
34. Han M, Zhou B. Role of cardiac fibroblasts in cardiac injury and repair. *Curr Cardiol Rep.* 2022;24(3):295–304. doi:10.1007/s11886-022-01647-y
35. Frangogiannis NG. Transforming growth factor- β in myocardial disease. *Nat Rev Cardiol.* 2022;19(7):435–455. doi:10.1038/s41569-021-00646-w
36. Becirovic-Agic M, Chalise U, Daseke MJ, et al. Infarct in the heart: what's MMP-9 got to do with it? *Biomolecules.* 2021;11(4):491. doi:10.3390/biom11040491
37. Luchian I, Goriuc A, Sandu D, Covasa M. The role of matrix metalloproteinases (MMP-8, MMP-9, MMP-13) in periodontal and peri-implant pathological processes. *Int J Mol Sci.* 2022;23(3):1806. doi:10.3390/ijms23031806
38. Choudhury A, Chakraborty I, Banerjee TS, Vana DR, Adapa D. Efficacy of morin as a potential therapeutic phytochemical: insights into the mechanism of action. *Int J Med Res Health Sci.* 2017;6(11):175–194.
39. Naowaboot J, Wannasiri S, Pannangpetch P. Morin attenuates hepatic insulin resistance in high-fat-diet-induced obese mice. *J Physiol Biochem.* 2016;72:269–280. doi:10.1007/s13105-016-0477-5
40. Thakur K, Zhu -Y-Y, Feng J-Y, et al. Morin as an imminent functional food ingredient: an update on its enhanced efficacy in the treatment and prevention of metabolic syndromes. *Food Funct.* 2020;11(10):8424–8443. doi:10.1039/D0FO01444C
41. Lodrini AM, Goumans M-J. Cardiomyocytes cellular phenotypes after myocardial infarction. *Front Cardiovasc Med.* 2021;8:750510. doi:10.3389/fcvm.2021.750510
42. Sun Z, Chai Q, Zhang Z, Lu D, Meng Z, Wu W. Inhibition of SGLT1 protects against glycemic variability-induced cardiac damage and pyroptosis of cardiomyocytes in diabetic mice. *Life Sci.* 2021;271:119116. doi:10.1016/j.lfs.2021.119116
43. Samare-Najaf M, Samareh A, Savardashtaki A, et al. Non-apoptotic cell death programs in cervical cancer with an emphasis on ferroptosis. *Crit Rev Oncol/Hematol.* 2023;194:104249. doi:10.1016/j.critrevonc.2023.104249
44. Samare-Najaf M, Neisy A, Samareh A, et al. The constructive and destructive impact of autophagy on both genders' reproducibility, a comprehensive review. *Autophagy.* 2023;19(12):3033–3061. doi:10.1080/15548627.2023.2238577
45. Hussar P. Apoptosis regulators bcl-2 and caspase-3. *Encyclopedia.* 2022;2(4):1624–1636. doi:10.3390/encyclopedia2040111
46. He C, Zhu H, Li H, Zou M-H, Xie Z. Dissociation of Bcl-2–Beclin1 complex by activated AMPK enhances cardiac autophagy and protects against cardiomyocyte apoptosis in diabetes. *Diabetes.* 2013;62(4):1270–1281. doi:10.2337/db12-0533
47. Sciarretta S, Zhai P, Shao D, et al. Rheb is a critical regulator of autophagy during myocardial ischemia: pathophysiological implications in obesity and metabolic syndrome. *Circulation.* 2012;125(9):1134–1146. doi:10.1161/CIRCULATIONAHA.111.078212
48. Zhang X, Han X, Zhang P, et al. Morin attenuates oxidized low-density lipoprotein-mediated injury by inducing autophagy via activating AMPK signalling in HUVEC s. *Clin Ex Pharmacol Physiol.* 2019;46(11):1053–1060. doi:10.1111/1440-1681.13160
49. Guo X, Lin H, Liu J, et al. 1, 25-Dihydroxyvitamin D attenuates diabetic cardiac autophagy and damage by vitamin D receptor-mediated suppression of FoxO1 translocation. *J Nutr Biochem.* 2020;80:108380. doi:10.1016/j.jnutbio.2020.108380
50. Madonna R, Moscato S, Cufaro MC, et al. Empagliflozin inhibits excessive autophagy through the AMPK/GSK3 β signalling pathway in diabetic cardiomyopathy. *Cardiovasc Res.* 2023;119(5):1175–1189. doi:10.1093/cvr/cvad009

51. Wu X, Liu Z, Yu XY, Xu S, Luo J. Autophagy and cardiac diseases: therapeutic potential of natural products. *Med Res Rev.* 2021;41(1):314–341. doi:10.1002/med.21733
52. Zech AT, Singh SR, Schlossarek S, Carrier L. Autophagy in cardiomyopathies. *Biochim Biophys Acta Mol Cell Res.* 2020;1867(3):118432. doi:10.1016/j.bbamer.2019.01.013
53. Chipurupalli S, Samavedam U, Robinson N. Crosstalk between ER stress, autophagy and inflammation. *Front Med.* 2021;8:758311. doi:10.3389/fmed.2021.758311
54. Wan Y, Yang L, Jiang S, Qian D, Duan J. Excessive apoptosis in ulcerative colitis: crosstalk between apoptosis, ROS, ER stress, and intestinal homeostasis. *Inflamm Bowel Dis.* 2022;28(4):639–648. doi:10.1093/ibd/izab277
55. Ivanović-Matić S, Bogojević D, Martinović V, et al. Catalase inhibition in diabetic rats potentiates DNA damage and apoptotic cell death setting the stage for cardiomyopathy. *J Physiol Biochem.* 2014;70(4):947–959. doi:10.1007/s13105-014-0363-y
56. Shen X, Zheng S, Metreveli NS, Epstein PN. Protection of cardiac mitochondria by overexpression of MnSOD reduces diabetic cardiomyopathy. *Diabetes.* 2006;55(3):798–805. doi:10.2337/diabetes.55.03.06.db05-1039
57. Drimal J, Knezl V, Navarova J, et al. Role of inflammatory cytokines and chemoattractants in the rat model of streptozotocin-induced diabetic heart failure. *Endocr Regul.* 2008;42(4):129.
58. Rodríguez-Yoldi MJ. Anti-inflammatory and antioxidant properties of plant extracts. *Antioxidants.* 2021;10:921. doi:10.3390/antiox10060921
59. Wang RX, Zhou M, Ma HL, Qiao YB, Li QS. The role of chronic inflammation in various diseases and anti-inflammatory therapies containing natural products. *ChemMedChem.* 2021;16(10):1576–1592. doi:10.1002/cmdc.202000996
60. Jafari khorchani M, Samare-Najaf M, Abbasi A, Vakili S, Zal F. Effects of quercetin, vitamin E, and estrogen on metabolic-related factors in uterus and serum of ovariectomized rat models. *Gynecol Endocrinol.* 2021;37(8):764–768. doi:10.1080/09513590.2021.1879784
61. El-Emam MA, Sheta E, El-Abhar HS, et al. Morin suppresses mTORc1/IRE-1 α /JNK and IP3R-VDAC-1 pathways: crucial mechanisms in apoptosis and mitophagy inhibition in experimental Huntington's disease, supported by in silico molecular docking simulations. *Life Sci.* 2024;338:122362. doi:10.1016/j.lfs.2023.122362
62. Ola MS, Aleisa AM, Al-Rejaie SS, et al. Flavonoid, morin inhibits oxidative stress, inflammation and enhances neurotrophic support in the brain of streptozotocin-induced diabetic rats. *Neurol Sci.* 2014;35(7):1003–1008. doi:10.1007/s10072-014-1628-5
63. Jasińska-Stroschein M. The current state of preclinical modeling of human diabetic cardiomyopathy using rodents. *Biomed Pharmacother.* 2023;168:115843.

Diabetes, Metabolic Syndrome and Obesity

Dovepress
Taylor & Francis Group

Publish your work in this journal

Diabetes, Metabolic Syndrome and Obesity is an international, peer-reviewed open-access journal committed to the rapid publication of the latest laboratory and clinical findings in the fields of diabetes, metabolic syndrome and obesity research. Original research, review, case reports, hypothesis formation, expert opinion and commentaries are all considered for publication. The manuscript management system is completely online and includes a very quick and fair peer-review system, which is all easy to use. Visit <http://www.dovepress.com/testimonials.php> to read real quotes from published authors.

Submit your manuscript here: <https://www.dovepress.com/diabetes-metabolic-syndrome-and-obesity-journal>