



CKJ REVIEW

Environmental toxin-induced acute kidney injury

Benjamin A. Vervaet, Patrick C. D'Haese and Anja Verhulst

Department of Biomedical Sciences, Laboratory of Pathophysiology, University Antwerp, Antwerp, Belgium

Correspondence and offprint requests to: Patrick C. D'Haese; E-mail: benjamin.vervaet@uantwerpen.be

Abstract

Human beings are exposed to various potentially toxic agents and conditions in their natural and occupational environments. The kidney, due to its concentrating ability and excretory function, is highly vulnerable to the effects of environmental toxins. Identifying the precise cause and mechanisms of environmentally induced renal injury remains a challenge for which various scientific disciplines need to be involved. Investigations in this field are confronted with the apparent infinite types of toxins, their mutual interaction, handling/metabolization by the body, ways of exposure, etc. Although interdisciplinary efforts and persistence are required to identify, mechanistically unravel and tackle environmental toxin-induced pathologies, research eventually pays off in ameliorated working/living conditions and development of preventive/therapeutic strategies. This review was compiled to particularly emphasize the need for a maintained awareness of environmental threats in general and those targeting the kidney. Different mechanisms of renal toxicity are illustrated and discussed, thereby focusing on three types of environmental toxins, namely aristolochic acid, melamine and heavy metals.

Key words: aristolochic acid, heavy metals, melamine, nephropathy

Introduction

Human beings are continuously exposed to various potentially harmful conditions and agents, both in their natural and occupational environments. Environmental causes of health issues can be physical (e.g. high temperature, dehydration), biological (e.g. bacteria/viruses) or chemical (organic/inorganic). Being responsible for maintaining body homeostasis and waste management, the kidneys are an important primary target of these hazards and thus are highly vulnerable to their toxic effects [1]. In particular, environmental toxins, to which we are unintentionally exposed via oral, inhalational or transdermal routes, are a common yet underappreciated cause of kidney injury. The high vulnerability of the kidney can be explained by its main physiological features, such as the highest blood flow per 100 g tissue, the largest endothelial surface by weight, highly active multiple metabolizing enzyme systems, the high concentration of filtered chemicals in tubular fluid adjacent to tubular cells, protein unbinding of chemical compounds in the tubules and further intrarenal

biotransformation of chemicals. Two major mechanisms inducing renal toxicity are (i) proximal tubular cell damage occurring due to extensive cellular uptake of toxins by both apical and basolateral transport systems and (ii) extensive tubular crystal formation due to the kidney's concentrating capacity. In this review we deal with these two different mechanisms of toxicity by focusing on three different types of environmental toxins, namely aristolochic acid, melamine and heavy metals.

Aristolochic acid nephropathy

In 1993, a group of Belgian women who had ingested slimming pills containing powdered root extracts of Chinese herbs presented urothelial malignancy concomitant with a rapidly progressive tubulointerstitial nephritis and fibrosis leading to end-stage renal disease (ESRD) [2–5]. This so-called Chinese-herb nephropathy (CHN) showed great clinical and histopathological similarities with a chronic tubulointerstitial kidney disease that

Received: February 22, 2016. Editorial decision: May 24, 2017

© The Author 2017. Published by Oxford University Press on behalf of ERA-EDTA.

This is an Open Access article distributed under the terms of the Creative Commons Attribution Non-Commercial License (<http://creativecommons.org/licenses/by-nc/4.0/>), which permits non-commercial re-use, distribution, and reproduction in any medium, provided the original work is properly cited. For commercial re-use, please contact journals.permissions@oup.com

was reported for the first time in the 1950s and was only seen in the Balkan area of Southeastern Europe and for this reason was termed Balkan Endemic Nephropathy (BEN) [6–8]. Rigorous investigations identified aristolochic acid (AA), a chemical compound (i.e. nitrophenanthrene carboxylic acid) commonly found in the Aristolochiaceae plant family, as the causative nephrotoxic agent in both these pathologies [9–14]. CHN appeared to be the dramatic consequence of substituting roots of the harmless *Stephanietrandra* with the AA-rich *Aristolochiafangchi* in herbal preparations, which was due to the fact that both plants share the same name, Pin Yin [4, 15, 16]. BEN most likely is the result of environmental exposure to seeds of *Aristolochiaclematitis*, a weed commonly found in Balkan meadows and crop fields, which can commingle with grain during harvesting and contaminate wheat flour for home-baked bread [8, 10–14, 17]. After the identification of AA as the common causal factor in CHN and BEN, any renal disease following AA exposure is now commonly recognized as aristolochic acid nephropathy (AAN).

Epidemiology

The true global, let alone country-specific, incidence and prevalence of AAN is unknown. This lack of up-to-date epidemiological data is largely due to the absence of a consensus definition, unavailability of diagnostic criteria and tools and the limited awareness of this disease. Since the publication of the Belgian cases index, several cases and case series from around the world (Europe [4, 18–22], USA [23], Australia [24], Japan [25], Korea [26], China [27, 28], Taiwan [28] and Hong Kong [29]) have been and are still reported, indicating that AAN is a global problem (Figure 1). Although the use of *Aristolochia* spp. and herbs that can be mistaken for them in herbal treatments have now been prohibited in many countries, there is evidence that large-scale exposure to AA continues and that the incidence is much higher than previously thought [28, 30–32]. Particularly in Asia, numerous ingredients known or suspected to contain AA are still used in traditional medicine. Warned by the severe and prolonged nephrotoxicity of AA, Chinese nephrologists started collecting histories of medication use from patients with chronic kidney disease (CKD) as routine clinical practice, especially from those presenting idiopathic chronic tubulointerstitial nephropathy. In this way, over the years, thousands of AAN patients have been diagnosed and are still followed in the long term [27, 33]. Additionally, in Taiwan a longitudinal analysis conducted on a random cohort of 200 000 patients from the data of the National Health Insurance (NHI) between 1997 and 2003 revealed that up to 40% of the population are likely to have been prescribed AA-containing herbal products [34], thus indicating AAN is a potentially devastating public health problem. Furthermore, AA containing species are known to be used in many regions where AAN has not yet been officially reported and diagnosis is not yet part of routine clinical practice, including Africa, South America and the Indian subcontinent [4, 35].

With respect to BEN, which is geographically confined to families living near tributaries of the Danube River in Bosnia, Bulgaria, Croatia, Romania and Serbia [7, 36], the estimated prevalence of the use of AA ranges between 2% and 10% [37]. Based on a more profound screening, the idea has been put forward that even the suspected cases need to be included, by which the prevalence increases up to 20% in endemic areas [37]. The rather wide range of variation greatly depends on the precise region and country [37–41] in which the data were gathered. Overall, at least 25 000 people have been identified as suffering from BEN [42].

Pathophysiology

Based on multiple regression analysis, it is clear that the cumulative dose of AA determines the onset and rate of decline in renal function and the degree of renal insufficiency [27, 43]. Even after cessation of the exposure, progression of renal failure is generally relentless. Acute AAN may progress to ESRD within 1 month and is often observed in patients having continuously ingested a high dose during a short period of time [44]. Generally, development of ESRD takes longer (months to years) and is associated with either a consistent or intermittent intake of a low dose of AA for a long period of time [45]. The slowest rate of renal functional decline is typically observed in patients with BEN, where progression to complete renal failure can take up to 15–20 years [46] due to relatively low exposure [17].

On a pathological level, AAN causes two main distinct health problems that are either carcinogenic or degenerative/fibrotic in nature. In the upper urinary tract, AAN induces typical multifocal urothelial atypia and transitional cell carcinoma, whereas in the kidney it induces cortical tubular atrophy and extensive interstitial fibrosis [15, 47]. The exact pathophysiological mechanisms by which AA initiates its pathological features are not fully understood. However, with respect to malignancy it has been established that AA is metabolically activated (i.e. nitroreduction by microsomal and cytosolic enzymes [48–50] to a cyclic N-acylnitrenium ion that is able to covalently bind the purine bases (adenine, guanine)) leading to the formation of DNA adducts [51]. These DNA adducts, termed aristolactams, are mutagenic and typically lead to AT→TA transversions. Whereas in rodent AAN models these mutations typically affect the H-ras proto-oncogene [52], in urothelial carcinomas isolated from AAN patients the tumour suppressor gene p53 appeared to be particularly affected by a specific AAG→TAG mutation [14, 53, 54]. Nonetheless, given the gene targets, it is highly likely that aristolactams drive urothelial tumourigenesis [55].

How AA exerts its proximal epithelial cytotoxic effects and thereby induces tubular atrophy is not yet fully understood. However, the mechanisms involved in AA toxicity appear to converge to apoptosis [56–58]. From *in vivo* and *in vitro* experiments it is clear that AA can enter the cell via organic anion transporters (OATs) [59–62], resulting in defective activation of anti-oxidative enzymes, mitochondrial damage, impaired regeneration of proximal tubular epithelial cells (i.e. cell cycle S-phase arrest) [63, 64], endoplasmic reticulum and mitochondrial stress, activation of the caspase pathway and apoptosis [65, 66] (Figure 4). Furthermore, AA is able to impair receptor mediated endocytosis of low molecular weight proteins (e.g. albumin, beta2-microglobulin) via decreased megalin expression [67]. Given the typical formation of aristolactam DNA adducts it is highly likely that injury to and/or breakage of the DNA strand is causing these cytotoxic effects in addition to the carcinogenic effects [63, 67]. Why injury to the upper urinary tract urothelium turns malignant whereas injury to proximal epithelial cells leads to apoptosis and cortical atrophy remains to be clarified.

Another major renal histopathological feature of AA toxicity is tubulointerstitial fibrosis (Figure 1). Whereas fibrosis might ensue as an inherent consequence of proximal epithelial cell injury/death [68], there are indications that AA, as a toxin, might directly induce extracellular matrix deposition via multiple signalling pathways that often converge to increased transforming growth factor beta (TGF-β) expression, a major pro-fibrotic cytokine. Rui et al. [69] demonstrated in a human proximal epithelial cell line that AA is able to induce overexpression of TGF-β1 and that this overexpression is mainly mediated by the Jun N-

terminal kinase signalling pathway. Also, a recent study made clear that AA-injured kidneys lose phosphate tensin homologue (PTEN) expression both in the epithelium and the interstitium [70]. This PTEN downregulation induces expression of pro-fibrotic genes via SMAD3-, p53- and Akt-dependent pathways and appears to facilitate TGF- β -induced gene expression and apoptosis. In addition, AAN has been shown to present G2/M cell cycle arrest, a pathological feature closely linked to the development of fibrosis [71]. Overall, it is clear that the numerous pathways associated with the development of AA-induced fibrosis are also involved in cell injury, dedifferentiation, proliferation and apoptosis. Therefore it remains an ongoing and daunting task to pinpoint the exact (obviously multipathway) mechanism by which AA affects gene expression and specifically initiates its fibrosis-stimulating action. It is likely that new studies focusing on miRNAs and epigenetic modifications might open new avenues in unravelling mechanisms underlying the development of AAN [64, 72, 73].

Treatment

Until recently there has been no well-established therapeutic regimen for the treatment of AAN. In the mid-1990s, glucocorticosteroid treatment of AAN patients with mild renal injury revealed that patients who had received steroids had a slower progression to ESRD as compared with untreated patients [74]. More recently it was reported that low-dose steroid therapy reversed or delayed the progression of severe chronic AAN [75]. As most patients progress to ESRD, however, there is usually a need for renal replacement therapy, i.e. dialysis or kidney transplant. However, given the high malignant potential, care must be taken to minimize future development of upper urinary tract cancers by performing prophylactic bilateral nephro-ureterectomies and aggressive cancer surveillance [76].

Melamine-induced nephropathy

What is melamine and where is it used?

Melamine is an organic base that is commercially synthesized from urea with cyanic acid as an intermediate step. Melamine contains 67% nitrogen by mass (Figure 2). Depending on the process by which it is purified, melamine may contain a number of structurally related by-products, including cyanuric acid, ammeline and ammelide (Figure 2). In the gastrointestinal tract these compounds are produced by microbial degradation of melamine through sequential hydrolysis, thereby replacing either one, two or three amino groups.

Melamine is produced for the synthesis of melamine formaldehyde resin, a very durable thermosetting plastic. Melamine also has fire-retardant properties and is used as insulation, soundproofing material and as a major component in Pigment Yellow 150.

It is also worth mentioning that melamine is a metabolite of the pesticide cyromazine. Melamine, because of its high nitrogen content, was used in fertilizers in the 1950s and 1960s, however, it is much more expensive and less effective compared with other common nitrogen fertilizers, such as urea. In the past, melamine has been used as a non-protein nitrogen source in cattle food, but because of its slow hydrolysis in ruminants, it is now categorized as ineffective.

Why is melamine added to food?

Melamine is illegally added to food to falsely boost apparent protein levels. Standard methods, such as the Kjeldahl and Dumas tests, estimate protein levels by measuring the nitrogen content. Hence these tests can overestimate the protein content if nitrogen-rich compounds such as melamine are added. Thus the addition of 1 g of melamine to 1 L of milk falsely increases the protein content (normal content in milk \pm 3.0%). When

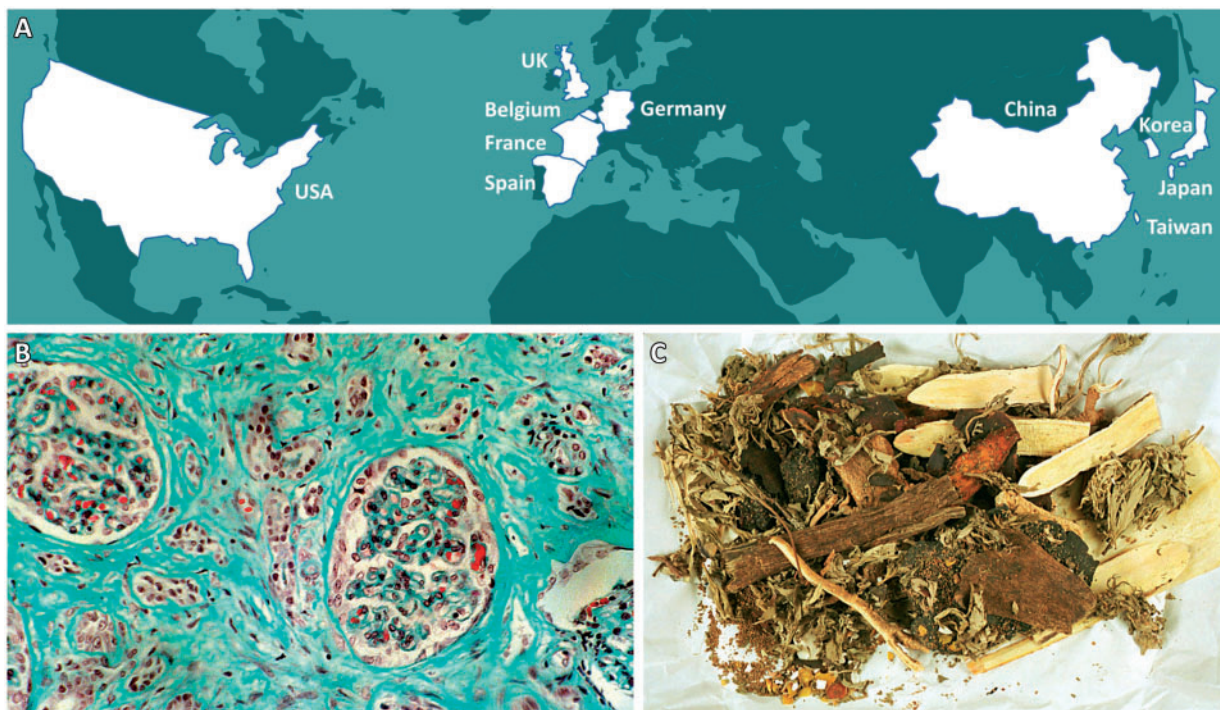

Fig. 1. CHN/AAN is a rapidly progressive interstitial nephritis leading to ESRD and urothelial malignancy that was originally reported in Belgium in the context of the intake of slimming pills containing powdered Chinese herbs (*Aristolochia fangchi*). (A) Countries with reported cases of CHN/AAN around the world. (B) Masson's trichrome staining shows the deposition of extracellular matrix in blue/green. (C) Example of a traditional mixture of Chinese herbs.

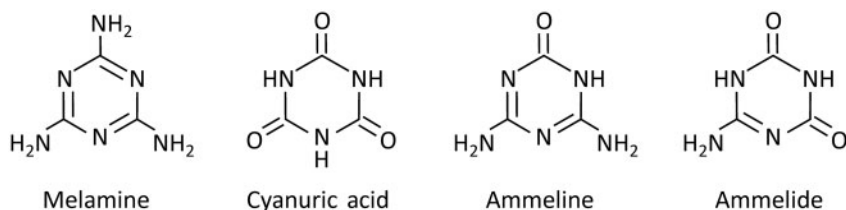


Fig. 2. Structure formula of melamine and its analogues.

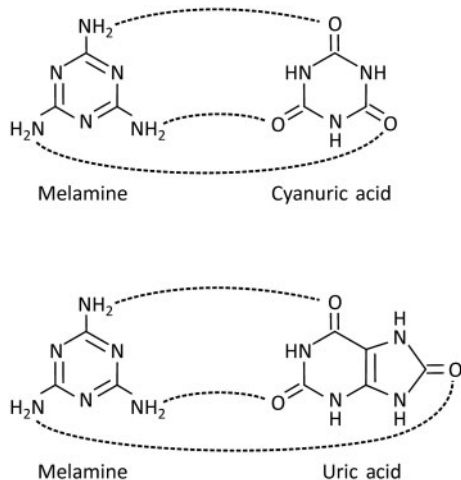


Fig. 3. Hydrogen-bonded interaction between melamine and cyanuric acid/uric acid.

melamine is dissolved at room temperature, 3.1 g of melamine can be dissolved in 1L water without forming precipitate, thereby falsely increasing the protein content by 1.2%, which ultimately may lead to an overestimation of the milk's protein content of 30%.

Toxicity of melamine: results from animal studies leading to safe guidelines for melamine content of foods

The LD50 (i.e. the dose of a compound that results in the death of 50% of the tested animals) of melamine in rats was found to be 3.2 g/kg body weight (bw) [77]. Acute toxicity of melamine is mainly localized in the kidney, as was seen during a study performed in sheep: animals receiving lethal oral doses of melamine (single 100 g dose or daily doses of 25–50 g over 7–9 days) suffered from acute kidney injury (AKI) with elevations in blood urea and creatinine preceding death [78]. Post-mortem analysis identified renal tubular crystals as the potential cause of the renal failure. Animals chronically exposed to melamine suffer from urinary crystal formation as well: dogs receiving a 3% melamine diet for 1 year showed crystalluria and proteinuria/haematuria [79]. Actually, consequences of renal tubular crystals and renal stone formation are the commonly reported problems of animals that are affected by melamine overload [80, 81].

In order to provide safety guidelines for melamine content in food [82], the US Food and Drug Administration (FDA) provided a tolerable daily intake (TDI) of 0.63 mg/kg bw, based on the no observed adverse effect level (NOAEL) of 63 mg/kg bw in rats and an uncertainty factor of 100 for interspecies differences. By introducing an additional uncertainty factor of 10 (among other things because of immature kidney function in young children), the TDI was later decreased to 0.063 mg/kg bw.

Using other calculations based on animal data, both the World Health Organization and European Food Safety Authority (EFSA) came to a TDI of 0.2 mg/kg bw, which is between the two values of the US FDA.

Outbreak of melamine toxicity in cats and dogs

In 2007 it was reported in North America that numerous dogs and cats were suffering from AKI [83]. This outbreak was associated with ingestion of melamine-contaminated pet foods and was associated with a very high mortality rate, which, along with melamine, could be attributed to the presence of another toxic compound, the melamine analogue cyanuric acid [84].

A study in cats investigated the toxic effects of cyanuric acid and melamine and revealed that the toxic dietary dose of melamine was reduced to one-fifth (from 1% to 0.2% in the diet) if co-administrated with cyanuric acid (0.2%) [85]. Analysis of the urine and renal tissue of affected cats revealed the presence of crystals containing both melamine and cyanuric acid. Melamine can interact with the isomeric form of cyanuric acid during the formation of melamine cyanurate (Figure 3), which in turn explains the increased stone formation and toxicity [84].

Outbreak of melamine toxicity in humans

In spite of many reports describing melamine toxicity in animals, an outbreak of melamine-induced renal stones was reported in Chinese children <3 years of age in September 2008 [86, 87]. The outbreak was associated with the consumption of milk powder containing melamine at concentrations as high as 2.6 g/kg [88]. In total, 52 857 children received treatment for consumption of melamine-contaminated milk. AKI occurred in 2.5% of the cases and mortality was recorded in four cases [89, 90]. It is also important to mention that currently it is not clear to what extent cases of nephrolithiasis without clinically overt AKI in these children may lead to CKD in the future. Analysis of the stone composition in humans exposed to melamine-contaminated milk mainly demonstrated the presence of melamine and uric acid [88, 89]. Currently we hope for no further outbreaks of melamine toxicity in the future, however, ambient exposure to lower concentrations because of widespread melamine use is possible. A recent manuscript in the *Journal of the American Society of Nephrology* reported on increases in serum and urinary melamine concentrations in workers in melamine tableware manufacturing factories in Taiwan. More importantly, those urinary increases in melamine concentration were positively associated with urinary markers of renal tubular damage [91].

Mechanism of melamine nephrotoxicity

While investigating melamine excretion in rats it became clear that 90% of an administered dose of melamine is excreted in the urine within 24 h [92]. During renal excretion, melamine

precipitates in the distal tubules as green radial crystals that could be visualized on haematoxylin and eosin-stained kidney sections originating from cats and dogs having eaten melamine-contaminated pet food [84, 85]. Distal tubular crystals in some animals induced distal tubular obstruction and necrosis, resulting in AKI in those animals. Other animals suffered from CKD characterized by the presence of tubular crystals that were partially overgrown by tubular epithelial cells, interstitial inflammation and fibrosis.

Interestingly, as melamine in rats has a relative low toxicity profile (toxicity defined as the development of urolithiasis) and a relatively high LD50 of 3161 mg/kg bw [77], one should not expect that melamine alone could induce renal crystal deposition when extrapolating these results to cats, dogs and humans. This discrepancy can be explained by the co-precipitation of melamine with another compound. During the outbreak in cats and dogs [84], melamine co-precipitated with cyanuric acid (the food was co-contaminated with cyanuric acid for unknown reasons), while in human infants the co-precipitant was uric acid [88, 89] present at relatively high concentrations in the urine of young infants [82]. Figure 3 shows the interactions between melamine and cyanuric acid/uric acid.

At present, it is not clear whether the tubular and interstitial damage seen in melamine-affected kidneys is induced solely because of physical obstruction by precipitated or adhered crystals (Figure 4) or by a direct toxic effect of melamine. *In vitro* studies using renal epithelial cell lines of different species showed that a direct toxic effect of melamine is unlikely [93]. It is possible that other pathological findings induced by melamine, such as urinary bladder and ureteral transitional cell

carcinomas as reported in male rats, are the result of stone formation as well [77, 94]. Research dealing with the mechanisms of melamine toxicity in recent years has also focused on lower and longer-term melamine-cyanuric acid exposure rather than high-dose acute toxicity. These studies revealed that young male rats are more prone to develop renal toxicity induced by melamine-cyanuric acid compared with older and female rats and that melamine-cyanuric acid toxicity is reversible [95]. Furthermore, it was reported that urinary markers of renal tubular damage can be used as early markers of renal damage induced by melamine-cyanuric acid [96, 97].

Treatment of melamine nephropathy

Data on the treatment of melamine nephropathy are scarce. A study in 47 children with melamine-induced urolithiasis and AKI revealed successful treatment in 9 patients who underwent conservative treatment (including intravenous fluid infusion, use of diuretics, urine alkalization and urethral catheterization), in 31 children after retrograde ureteral catheterization, in 4 patients treated with ureterolithotomy and in 1 patient after percutaneous nephrostomy [98].

Metal-induced nephropathy

General considerations

Exposure to toxic metals is one of the oldest occupational and environmental chemical risks causing adverse health effects.

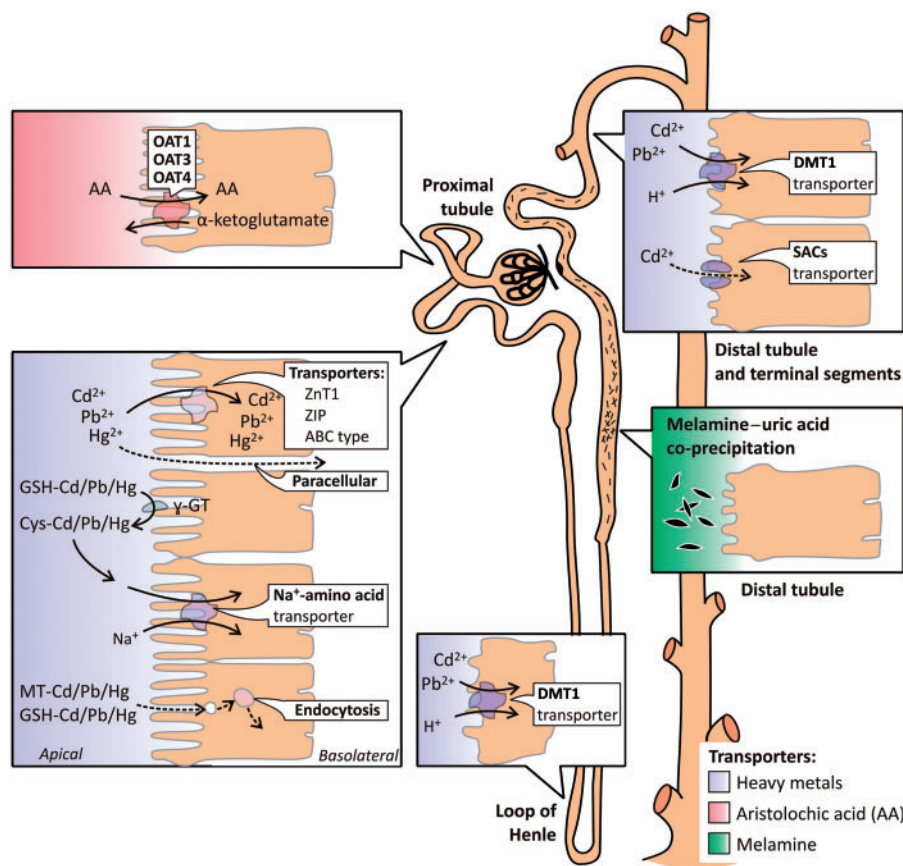


Fig. 4. Mechanisms involved in the uptake and action of aristolochic acid, melamine and the heavy metals Cd, Pb and Hg along the nephron. Adapted from Barbier et al. [111] with permission.

Cadmium (Cd), lead (Pb) and to a lesser extent mercury (Hg) are widespread occupational and environmental toxins. Human exposure can occur due to activities such as mining, melting, soldering, welding, plating, recycling of metals, fossil fuel combustion and industrial applications [99–105]. Exposure to metals may occur through inhalation, ingestion or skin penetration. In an occupational setting, inhalation is the most important exposure route [99–101]. An important route of exposure that should not be neglected is the inhalation of tobacco smoke [106–108]. Metals do not biologically break down. As a consequence, the metal resides in the body until it is excreted. During this period, metal compounds can be transformed into other more or less toxic substances, e.g. through protein binding or binding to other ligands [109].

The chemical form (i.e. species) may influence the toxicokinetics and toxicodynamics of metals. Factors that influence metal speciation include (i) carrier-mediated processes for specific metal species (Pb), (ii) valence state (Hg), (iii) particle size (Pb and Cd), (iv) the nature of metal-binding ligands (Pb), (v) the presence of the metal as an organic versus inorganic species (Pb and Hg) and (vi) biotransformation of metal species (Pb and Hg) [110]. With respect to renal handling, the proximal tubule is a central player in metal toxicity for the vast majority of metals. This is particularly due to its bulk reabsorbing activity.

The mechanisms involved in the uptake of Cd, Pb and Hg along the nephron have been elegantly described by Barbier et al. (Figure 4) [111, 112]. In the proximal tubule, several transporters of essential metals are involved in the uptake of free forms of Cd, Pb and Hg [e.g. zinc transporter 1 (ZnT1), ZRT/IRT-like protein (ZIP) and ATP-binding cassette (ABC) protein] [113]. Furthermore, after conjugation with metallothionein and glutathione (GSH), these metals can also be reabsorbed by endocytosis or by transport of Cys conjugates through the Na⁺ amino acid co-transporter after degradation of GSH by the brush border enzyme γ -glutamyltransferase. In the distal tubule or connecting ducts, divalent metal transporter 1 (DMT1) and stretch-activated channels (SACs) could play an important role in the uptake of ionized forms of Cd, Pb and Hg. DMT1 is probably a major transporter of metals in the loop of Henle. Paracellular pathways may also participate in metal transport along the proximal tubule and the loop of Henle.

The exact cellular processes underlying the metal-induced nephrotoxicity are not yet fully understood. Growing attention is directed towards the effect of metals on the oxidative status of cells and the production of reactive oxygen species (ROS) as well as their effect on cellular antioxidant defences such as superoxide dismutase (SOD) and glutathione peroxidase (GPX) [99, 101, 103, 114–121]. Oxidative stress can cause disruption of cellular macromolecules such as DNA, proteins and lipids [122–124].

The extent to which and how metals interact with each other remains a relatively unexplored field [125]. Several epidemiological studies have underlined that isolated environmental and occupational exposure to a single metal rarely occurs and is often combined with exposure to other metals [101, 126–129]. As reviewed by Choudhury and Mudipalli [129], research on the effect of combined exposure to metals on the kidney in humans is scarce. Similarities in kidney target areas and mechanisms of injury raise concerns regarding the possible nephrotoxicity of combined exposure to metals [99, 130]. In this respect, the recent finding that co-exposure to Pb increases the renal response to low levels of Cd in metallurgy workers is worth mentioning [100].

Cadmium

Occurrence and exposure

Cadmium, discovered by the German chemist Friedrich Strohmeyer in 1817 [131], is a highly toxic and carcinogenic metal that is widely distributed in the environment. Mounting evidence from populations exposed to low or moderate levels points to Cd as a risk factor for a broad spectrum of health conditions, including cardiovascular, kidney and bone disease [132, 133]. Being a by-product of mining, melting and refining of Zn, Pb and Cu ores, the industrial production of Cd started in the 1930s. The use of Cd in consumer products (e.g. pigments, batteries, coatings and plastic stabilizers) increased dramatically until the 1970s and 1980s, resulting in widespread soil contamination from industrial releases, fuel combustion and Cd-containing phosphate fertilizers. Soil contamination by Cd is a major environmental health problem because leafy and root vegetables and grains concentrate the metal from soil, providing a major pathway for exposure through diet and tobacco [134–136]. Ambient air and dust can also contribute to Cd exposure, particularly in urban areas and in the vicinity of industrial sources and waste sites [137]. Public health policies such as tobacco control, air pollution reduction and hazardous waste remediation, have resulted in significantly decreased Cd exposure in developed countries. Nevertheless, additional public health efforts and efforts to reduce the levels of Cd in air, soils and food are critical to further prevent Cd exposure in the general population, especially since studies of National Health and Nutrition Examination Survey (1999–2008) data revealed that exposure to Cd at the current reduced levels is associated with cardiovascular, bone and kidney disease.

Absorption and distribution

As described by Johri et al. [101] Cd is absorbed from the gastrointestinal tract by DMT1. Following absorption, Cd primarily binds to serum albumin, the form in which it is transported to the various parts of the body, mainly the liver. Within the liver, intracellular Cd dissociates from albumin and released Cd ions induce the synthesis of metallothionein, which results in an increasing proportion of liver Cd being bound to metallothionein. The Cd–metallothionein complex is then slowly released back into the circulation.

Renal handling/toxicity

During the phase when plasma Cd is bound to albumin, there is only limited uptake of Cd by the kidney. The Cd–metallothionein complex, because of its low molecular weight, is freely filtered through the glomerulus and reabsorbed by the proximal tubule [101, 131, 116, 138]. Cd upregulates metallothionein production in the liver and kidney to limit the toxicity of free Cd²⁺. However, when the capacity of the proximal tubule to produce metallothionein is exhausted, progressive tubular cell damage may occur due to an increased uptake/intracellular concentration of Cd²⁺ [101, 112].

Renal Cd toxicity is primarily characterized by dysfunction of the proximal tubule, evidenced by polyuria and increases in the urinary excretion of glucose, amino acids, electrolytes (particularly Na⁺, K⁺ and Ca²⁺) and low molecular weight proteins. Prozialeck and Edwards [139], in an excellent review, put forward an elegant model of Cd-induced proximal tubule injury. Following accumulation of Cd in the proximal tubule, epithelial cell function may be affected, involving mild oxidative stress, disruption of cellular signalling cascades and alterations in cell adhesion. With mild injury, damage may be repaired through

an autophagic response. However, if the injury is more severe, apoptosis and/or autophagic cell death can occur and repair processes will be inadequate, which ultimately results in necrosis of the proximal tubule cells [140].

Renal pathology

Data on pathologic findings in chronic Cd nephrotoxicity are scarce. One example can be found in itai-itai disease, named after the excruciating pains (*Jap. itai = Eng. it hurts*) in the spine and joints that were associated with severe Cd poisoning in Japan in the early 20th century. Kidneys in cases of itai-itai disease were red-brown, had a granular surface and were decreased in size. Microscopically there was extensive tubular atrophy and interstitial fibrosis. Inflammatory cells were present in small numbers. Some degree of glomerular sclerosis was present. Others investigating the renal pathology in patients exposed to either Cd fumes or pigments failed to show significant histological changes that might be due to differences in exposure and hence differences in the quantity of Cd in renal tissue [141–143].

Treatment

None of the chelation therapies have thus far been approved for clinical use in Cd toxicity. Balanced iron intake has proven effective in reducing the bioavailability of Cd present in the intestine by reducing its absorption [144].

Lead

Occurrence and exposure

Lead exposure/toxicity was a common problem among Romans >2000 years ago. Exposure to Pb is still an important environmental risk factors and in the year 2010 was estimated to account for 0.6% of the global disease burden [145]. Due to the elimination of Pb in gasoline, Pb-based paints and Pb pipes in homes, a significant reduction in blood Pb levels has been observed in recent decades [145, 146]. While cases of acute Pb poisoning have become rare, continuous exposure to low levels of Pb is still a public health issue in industrialized countries. Lead exposure leading to acute Pb poisoning or chronic health effects remains a significant public health problem in low- and middle-income countries, particularly because regulatory policies are lacking [147].

Once Pb is contained in dust and soil, it does not dissipate, biodegrade or decay, which means that it becomes a long-term source of Pb exposure, particularly in children. The mode for Pb transmission from contaminated soil to children is by hand to mouth (pica) and it was reported in a very recent review that elevated blood Pb levels of children living near landfills were closely associated with increased soil Pb levels and toxic effects, including adverse outcomes such as encephalopathy or even death [148].

Absorption and distribution

Corporeal handling of Pb is much less understood [99, 116, 149, 150]. Following absorption, Pb is transported to the blood plasma and within minutes is transferred to the erythrocytes where it is primarily bound to haemoglobin. Only $\pm 6\%$ circulates in the plasma from where it is distributed to the soft tissues (e.g. kidney), teeth and the skeleton, which contains up to 95% of the total Pb burden.

Renal handling/toxicity

Circulating Pb bound to low molecular weight proteins (<1% of the total) is filtered freely through the glomerulus and partially

reabsorbed by the proximal tubule [116]. Following Chaumont *et al.* [151] it is likely that Pb is reabsorbed by the proximal tubule as a low molecular weight complex protein similar to the Cd-metallothionein complex. Cellular toxicity of Pb is complex and may develop via different pathways. First, exposure to Pb may induce oxidative stress, thereby initiating a cascade of events that may lead to vascular resistance and high blood pressure. Second, free radicals may be generated that activate nuclear factor κB and inflammation. Third, Pb may interfere with Ca-dependent enzymatic reactions and the induction of apoptosis. These various pathways can ultimately lead to the development of renal injury [116].

Renal pathology

Renal pathology in 'chronic' Pb nephropathy is characterized by granular contracted kidneys with a reduced number of functioning nephrons with multifocal tubular atrophy and dilatation and arteriolar and interstitial fibrosis. Glomeruli are normal and arteries and arterioles show medial thickening and luminal narrowing, probably related to hypertension. This renal pathology differs from that seen in 'acute' Pb nephropathy, which is consistently associated with acid-fast intranuclear inclusions in proximal epithelial cells. These intranuclear inclusion bodies consist of a Pb-protein complex and may be seen in tubular epithelial cells in the urinary sediment during acute poisoning [152].

Treatment

The most commonly used therapeutic strategy for Pb poisoning is chelation therapy to promote metal excretion. Chelators such as CaNa_2EDTA and meso-2,3-dimercaptosuccinic acid (DMSA) have been reported to have protective effects against Pb toxicity. However, CaNa_2EDTA can cause renal toxicity (particularly at the proximal tubule), especially with repeated high doses and in subjects with a previous history of kidney damage. Moreover, because of its relative lack of specificity, co-excretion of other essential metals such as zinc, iron and manganese may occur and continuous monitoring of these metals is warranted [153].

Mercury

Occurrence and exposure

Mercury is used in gold mining to extract gold from ore by forming 'amalgam'—a mixture composed of approximately equal parts of Hg and gold. Approximately 15 million people, including ~3 million women and children, participate in artisanal small-scale gold mining in developing countries and 37% of global air emissions of Hg are produced by this activity [154]. Exposure to Hg can cause various adverse health effects in humans. The nervous system and the kidneys are especially sensitive to Hg toxicity [114, 155, 156]. The three key determinants of Hg toxicity are the chemical form one is exposed to (i.e. mercury vapour versus inorganic versus organic compounds), the route of exposure and the dose [157].

Absorption and distribution

Once absorbed, Hg may undergo several metabolic transformations through oxidation, reduction, methylation and demethylation processes. The distribution of Hg in the body after exposure essentially depends on the binding form of the absorbed Hg: inorganic Hg salts are predominantly deposited in the kidney, while exposure to metallic Hg vapour or methylmercury increases the Hg concentration in the brain. Normally the

highest Hg concentrations are found in the kidney followed by the liver, spleen and brain [158, 159].

Renal handling/toxicity

Renal accumulation of inorganic Hg was found to occur mainly in the convoluted and straight segments of the proximal tubule [160]. Mercury–thiol conjugates of GSH are considered the principal entity involved in the uptake of Hg at the proximal tubule [161]. Regarding its uptake, studies suggest the involvement of different transporters operating at the luminal and basolateral membrane (162). At the luminal surface, transport of Hg appears to occur through the luminal membrane as a conjugate of L-cysteine, such as dicysteinylmercury, via one of the amino acid transport systems, while at the basolateral membrane, transport of mercuric conjugates of GSH and/or cysteine takes place through OAT1 and OAT3 [163–165]. It has been hypothesized that Hg binding to sulphhydryl groups on proteins, which are extensively present in the S3 part of the proximal tubule, is responsible for the characteristic S3 segment Hg-induced cellular dysfunction and death, resulting in the well-known Hg-induced nephrotoxicity [163].

Renal pathology

Chronic Hg poisoning results in kidneys of normal or slightly decreased size. Initially, interstitial oedema, inflammatory infiltration with lymphocytes and tubular cell changes such as necrosis, flattening of epithelium and desquamation of epithelial cells are present [166–168]. Later, there is progressive loss of tubules and interstitial fibrosis [166]. Glomerular pathology is limited to membranous nephropathy [168].

Treatment

Mercury intoxications were previously treated with dimercaprol, also called British antilewisite (BAL) and d-penicillamine. However, dimercaprol is itself toxic, with a narrow therapeutic range and serious side effects, including nephrotoxicity, hypertension and brain deposition of inorganic as well as organic Hg. In view of this, BAL is now considered to be contraindicated [169]. The efficacy of d-penicillamine in the removal of Hg is rather poor and use of the compound is contraindicated in renal failure. Data from several case and cohort reports present increasing evidence for the safe use of DMSA and d,l-2,3-dimercapto-1-propanesulfonic acid (Dimaval or DMPS) in the treatment human poisoning by various Hg compounds [170].

Conclusion

It is clear that our bodies are continuously challenged by environmental toxins and that the kidney, due to its concentrating ability and excretory function, very often is affected. Since our kidneys play a crucial role in maintaining body homeostasis, i.e. providing a balanced ionic composition, volume, pH and osmolality of our body fluid, renal injury often has far-reaching clinical consequences. In contrast to the majority of disease aetiologies, identifying the precise cause and mechanism of environmentally induced renal injury remains a daunting task involving many scientific disciplines, as evidenced above. Investigations in this field are particularly challenged by the apparent infinite types of toxins, their mutual interaction and handling/metabolization by the body. With the recent development of ‘-omics’, in particular metabolomics, and chemical profiling research tools, this process is likely to speed up in the future. Although a group effort and persistence are required to identify and tackle environmental toxin-induced renal

pathologies, research eventually pays off in ameliorated working/living conditions, the development of treatments or, at least, an increased general awareness of particular environmental threats to the kidney. An important driving factor herein is the fact that environmental toxins are a preventable cause of kidney disease.

Conflict of interest statement

None declared.

References

- Soderland P, Lovekar S, Weiner DE et al. Chronic kidney disease associated with environmental toxins and exposures. *Adv Chronic Kidney Dis* 2010; 17: 254–264
- Depierreux M, Van DB, Vanden Houte K et al. Pathologic aspects of a newly described nephropathy related to the prolonged use of Chinese herbs. *Am J Kidney Dis* 1994; 24: 172–180
- Vanhaelen M, Vanhaelen-Fastre R, But P et al. Identification of aristolochic acid in Chinese herbs. *Lancet* 1994; 343: 174
- Vanherweghem JL, Depierreux M, Tielemans C et al. Rapidly progressive interstitial renal fibrosis in young women: association with slimming regimen including Chinese herbs. *Lancet* 1993; 341: 387–391
- Cosyns JP, Jadoul M, Squifflet JP et al. Urothelial malignancy in nephropathy due to Chinese herbs. *Lancet* 1994; 344: 188
- Stefanovic V, Polenakovic M. Fifty years of research in Balkan endemic nephropathy: where are we now? *Nephron Clin Pract* 2009; 112: c51–c56
- Polenakovic M, Stefanovic V. Balkan nephropathy. In: Davison AM (ed.) *Oxford Textbook of Clinical Nephrology*. New York: Oxford University Press, 1998, p. 1203
- Ivic M. [Etiology of endemic nephropathy]. *Lijec Vjesn* 1969; 91: 1273–1281
- Lord GM, Tagore R, Cook T et al. Nephropathy caused by Chinese herbs in the UK. *Lancet* 1999; 354: 481–482
- Schmeiser HH, Kucab JE, Arlt VM et al. Evidence of exposure to aristolochic acid in patients with urothelial cancer from a Balkan endemic nephropathy region of Romania. *Environ Mol Mutagen* 2012; 53: 636–641
- Arlt VM, Stiborova M, vom BJ et al. Aristolochic acid mutagenesis: molecular clues to the aetiology of Balkan endemic nephropathy-associated urothelial cancer. *Carcinogenesis* 2007; 28: 2253–2261
- Arlt VM, Ferluga D, Stiborova M et al. Is aristolochic acid a risk factor for Balkan endemic nephropathy-associated urothelial cancer? *Int J Cancer* 2002; 101: 500–502
- Grollman AP, Shibutani S, Moriya M et al. Aristolochic acid and the etiology of endemic (Balkan) nephropathy. *Proc Natl Acad Sci USA* 2007; 104: 12129–12134
- Jelakovic B, Karanovic S, Vukovic-Lela I et al. Aristolactam-DNA adducts are a biomarker of environmental exposure to aristolochic acid. *Kidney Int* 2012; 81: 559–567
- Nortier JL, Martinez MC, Schmeiser HH et al. Urothelial carcinoma associated with the use of a Chinese herb (*Aristolochia fangchi*). *N Engl J Med* 2000; 342: 1686–1692
- Gokmen MR, Lord GM. Aristolochic acid nephropathy. *BMJ* 2012; 344: e4000.
- Hranjec T, Kovac A, Kos J et al. Endemic nephropathy: the case for chronic poisoning by aristolochia. *Croat Med J* 2005; 46: 116–125

18. Krumme B, Endmeir R, Vanhaelen M et al. Reversible Fanconi syndrome after ingestion of a Chinese herbal 'remedy' containing aristolochic acid. *Nephrol Dial Transplant* 2001; 16: 400–402
19. Laing C, Hamour S, Sheaff M et al. Chinese herbal uropathy and nephropathy. *Lancet*. 2006; 368: 338
20. Pena JM, Borrás M, Ramos J et al. Rapidly progressive interstitial renal fibrosis due to a chronic intake of a herb (*Aristolochia pistolochia*) infusion. *Nephrol Dial Transplant* 1996; 11: 1359–1360
21. Pourrat J, Montastruc JL, Lacombe JL et al. [Nephropathy associated with Chinese herbal drugs. 2 cases]. *Presse Med* 1994; 23: 1669
22. Stengel B, Jones E. [End-stage renal insufficiency associated with Chinese herbal consumption in France]. *Nephrologie* 1998; 19: 15–20
23. Meyer MM, Chen TP, Bennett WM. Chinese herb nephropathy. *Proc(Bayl Univ Med Cent)* 2000; 13: 334–337
24. Chau W, Ross R, Li JY et al. Nephropathy associated with use of a Chinese herbal product containing aristolochic acid. *Med J Aust* 2011; 194: 367–368
25. Tanaka A, Nishida R, Maeda K et al. Chinese herb nephropathy in Japan presents adult-onset Fanconi syndrome: could different components of aristolochic acids cause a different type of Chinese herb nephropathy? *Clin Nephrol* 2000; 53: 301–306
26. Lee S, Lee T, Lee B et al. Fanconi's syndrome and subsequent progressive renal failure caused by a Chinese herb containing aristolochic acid. *Nephrology* 2004; 9: 126–129
27. Yang L, Su T, Li XM et al. Aristolochic acid nephropathy: variation in presentation and prognosis. *Nephrol Dial Transplant* 2012; 27: 292–298
28. Yang CS, Lin CH, Chang SH et al. Rapidly progressive fibrosing interstitial nephritis associated with Chinese herbal drugs. *Am J Kidney Dis* 2000; 35: 313–318
29. Poon WT, Lai CK, Chan AYW. Aristolochic acid nephropathy: the Hong Kong perspective. *Hong Kong J Nephrol* 2007; 9: 7–14
30. Wu Y, Liu Z, Hu W et al. Mast cell infiltration associated with tubulointerstitial fibrosis in chronic aristolochic acid nephropathy. *Hum Exp Toxicol* 2005; 24: 41–47
31. Guh JY, Chen HC, Tsai JF et al. Herbal therapy is associated with the risk of CKD in adults not using analgesics in Taiwan. *Am J Kidney Dis* 2007; 49: 626–633
32. Debelle FD, Vanherweghem JL, Nortier JL. Aristolochic acid nephropathy: a worldwide problem. *Kidney Int* 2008; 74: 158–169
33. Zhang J, Zhang L, Wang W et al. Association between aristolochic acid and CKD: a cross-sectional survey in China. *Am J Kidney Dis* 2013; 61: 918–922
34. Hsieh SC, Lin IH, Tseng WL et al. Prescription profile of potentially aristolochic acid containing Chinese herbal products: an analysis of National Health Insurance data in Taiwan between 1997 and 2003. *Chin Med* 2008; 3: 13.
35. Heinrich M, Chan J, Wanke S et al. Local uses of *Aristolochia* species and content of nephrotoxic aristolochic acid 1 and 2—a global assessment based on bibliographic sources. *J Ethnopharmacol* 2009; 125: 108–144
36. Djukanovic L, Radovanovic Z. Balkan endemic nephropathy. In: De Broe ME, Porter GAs (eds). *Clinical Nephrotoxins: Renal Injury from Drugs and Chemicals*. New York: Springer, 2008, pp. 843–858
37. Ceovic S, Hrabar A, Saric M. Epidemiology of Balkan endemic nephropathy. *Food Chem Toxicol* 1992; 30: 183–188
38. Bukvic D, Maric I, Arsenovic A et al. Prevalence of Balkan endemic nephropathy has not changed since 1971 in the Kolubara region in Serbia. *Kidney Blood Press Res* 2007; 30: 117–123
39. Bukvic D, Jankovic S, Arsenovic A et al. Balkan endemic nephropathy is still present in the Kolubara region, Serbia. *Ren Fail* 2005; 27: 565–569
40. Arsenovic A, Bukvic D, Trbojevic S et al. Detection of renal dysfunctions in family members of patients with Balkan endemic nephropathy. *Am J Nephrol* 2005; 25: 50–54
41. Long DT, Voice TC. Role of exposure analysis in solving the mystery of Balkan endemic nephropathy. *Croat Med J* 2007; 48: 300–311
42. Tatu CA, Orem WH, Finkelman RB et al. The etiology of Balkan endemic nephropathy: still more questions than answers. *Environ Health Perspect* 1998; 106: 689–700
43. Unger P, Nortier J, Muniz Martinez MC et al. High prevalence of fenfluramine-related aortic regurgitation in women with end-stage renal disease secondary to Chinese herb nephropathy. *Nephrol Dial Transplant* 2003; 18: 906–910
44. Shaohua Z, Ananda S, Ruxia Y et al. Fatal renal failure due to the Chinese herb "GuanMu Tong" (*Aristolochia manshuriensis*): autopsy findings and review of literature. *Forensic Sci Int* 2010; 199: e5–e7
45. Gokmen MR, Cosyns JP, Arlt VM et al. The epidemiology, diagnosis, and management of aristolochic acid nephropathy: a narrative review. *Ann Intern Med* 2013; 158: 469–477
46. Cukuranovic R, Savic V, Stefanovic N et al. Progression of kidney damage in Balkan endemic nephropathy: a 15-year follow-up of patients with kidney biopsy examination. *Ren Fail* 2005; 27: 701–706
47. Cosyns JP, Jadoul M, Squifflet JP et al. Urothelial lesions in Chinese-herb nephropathy. *Am J Kidney Dis* 1999; 33: 1011–1017
48. Stiborova M, Frei E, Hodek P et al. Human hepatic and renal microsomes, cytochromes P450 1A1/2, NADPH:cytochrome P450 reductase and prostaglandin H synthase mediate the formation of aristolochic acid-DNA adducts found in patients with urothelial cancer. *Int J Cancer* 2005; 113: 189–197
49. Stiborova M, Frei E, Sopko B, et al. Human cytosolic enzymes involved in the metabolic activation of carcinogenic aristolochic acid: evidence for reductive activation by human NAD(P)H:quinone oxidoreductase. *Carcinogenesis* 2003; 24: 1695–1703
50. Stiborova M, Frei E, Wiessler M et al. Human enzymes involved in the metabolic activation of carcinogenic aristolochic acids: evidence for reductive activation by cytochromes P450 1A1 and 1A2. *Chem Res Toxicol* 2001; 14: 1128–1137
51. Arlt VM, Stiborova M, Schmeiser HH. Aristolochic acid as a probable human cancer hazard in herbal remedies: a review. *Mutagenesis* 2002; 17: 265–277
52. Arlt VM, Wiessler M, Schmeiser HH; Using polymerase arrest to detect DNA binding specificity of aristolochic acid in the mouse H-ras gene. *Carcinogenesis* 2000; 21: 235–242
53. Lord GM, Hollstein M, Arlt VM et al. DNA adducts and p53 mutations in a patient with aristolochic acid-associated nephropathy. *Am J Kidney Dis* 2004; 43:e11–e17
54. Chen CH, Dickman KG, Moriya M et al. Aristolochic acid-associated urothelial cancer in Taiwan. *Proc Natl Acad Sci USA* 2012; 109: 8241–8246
55. Kathuria P, Sharma P, Abendong MN et al. Conformational preferences of DNA following damage by aristolochic acids: structural and energetic insights into the different

- mutagenic potential of the ALI and ALII-N(6)-dA adducts. *Biochemistry* 2015; 54: 2414–2428
56. Okada H, Watanabe Y, Inoue T et al. Transgene-derived hepatocyte growth factor attenuates reactive renal fibrosis in aristolochic acid nephrotoxicity. *Nephrol Dial Transplant* 2003; 18: 2515–2523
 57. Balachandran P, Wei F, Lin RC et al. Structure activity relationships of aristolochic acid analogues: toxicity in cultured renal epithelial cells. *Kidney Int* 2005; 67: 1797–1805
 58. Liu MC, Maruyama S, Mizuno M et al. The nephrotoxicity of *Aristolochia manshuriensis* in rats is attributable to its aristolochic acids. *Clin Exp Nephrol* 2003; 7: 186–194
 59. Babu E, Takeda M, Nishida R et al. Interactions of human organic anion transporters with aristolochic acids. *J Pharmacol Sci* 2010; 113: 192–196
 60. Bakhiya N, Arlt VM, Bahn A et al. Molecular evidence for an involvement of organic anion transporters (OATs) in aristolochic acid nephropathy. *Toxicology* 2009; 264: 74–79
 61. Xue X, Gong LK, Maeda K et al. Critical role of organic anion transporters 1 and 3 in kidney accumulation and toxicity of aristolochic acid I. *Mol Pharm* 2011; 8: 2183–2192
 62. Baudoux TE, Pozdzik AA, Arlt VM et al. Probenecid prevents acute tubular necrosis in a mouse model of aristolochic acid nephropathy. *Kidney Int* 2012; 82: 1105–1113
 63. Nitzsche D, Melzig MF, Arlt VM. Evaluation of the cytotoxicity and genotoxicity of aristolochic acid I—a component of Aristolochiaceae plant extracts used in homeopathy. *Environ Toxicol Pharmacol* 2013; 35: 325–334
 64. Jenkins RH, Davies LC, Taylor PR et al. miR-192 induces G2/M growth arrest in aristolochic acid nephropathy. *Am J Pathol* 2014; 184: 996–1009
 65. Pozdzik AA, Salmon IJ, Debelle FD et al. Aristolochic acid induces proximal tubule apoptosis and epithelial to mesenchymal transformation. *Kidney Int* 2008; 73: 595–607
 66. Hsin YH, Cheng CH, Tzen JT et al. Effect of aristolochic acid on intracellular calcium concentration and its links with apoptosis in renal tubular cells. *Apoptosis* 2006; 11: 2167–2177
 67. Lebeau C, Arlt VM, Schmeiser HH et al. Aristolochic acid impedes endocytosis and induces DNA adducts in proximal tubule cells. *Kidney Int* 2001; 60: 1332–1342
 68. Grgic I, Campanholle G, Bijol V et al. Targeted proximal tubule injury triggers interstitial fibrosis and glomerulosclerosis. *Kidney Int* 2012; 82: 172–183
 69. Rui HL, Wang YY, Cheng H et al. JNK-dependent AP-1 activation is required for aristolochic acid-induced TGF- β 1 synthesis in human renal proximal epithelial cells. *Am J Physiol Renal Physiol* 2012; 302: F1569–F1575
 70. Samarakoon R, Helo S, Dobberfuhr AD et al. Loss of tumour suppressor PTEN expression in renal injury initiates SMAD3- and p53-dependent fibrotic responses. *J Pathol* 2015; 236: 421–432
 71. Yang L, Besschetnova TY, Brooks CR et al. Epithelial cell cycle arrest in G2/M mediates kidney fibrosis after injury. *Nat Med* 2010; 16: 535–543, 1p following 143.
 72. Li Z, Qin T, Wang K et al. Integrated microRNA, mRNA, and protein expression profiling reveals microRNA regulatory networks in rat kidney treated with a carcinogenic dose of aristolochic acid. *BMC Genomics* 2015; 16: 365
 73. Liu N, Zhuang S. Treatment of chronic kidney diseases with histone deacetylase inhibitors. *Front Physiol* 2015; 6: 121
 74. Vanherweghem JL, Abramowicz D, Tielemans C et al. Effects of steroids on the progression of renal failure in chronic interstitial renal fibrosis: a pilot study in Chinese herbs nephropathy. *Am J Kidney Dis* 1996; 27: 209–215
 75. Ma DH, Zheng FL, Su Y et al. Influence and analysis of low-dosage steroid therapy in severe aristolochic acid nephropathy patients. *Nephrology* 2016; 21: 835–840
 76. Luciano RL, Perazella MA. Aristolochic acid nephropathy: epidemiology, clinical presentation, and treatment. *Drug Saf* 2015; 38: 55–64
 77. Melnick RL, Boorman GA, Haseman JK et al. Urolithiasis and bladder carcinogenicity of melamine in rodents. *Tox Appl Pharmacol* 1984; 72: 292–303
 78. Clark R. Melamine crystalluria in sheep. *J S Afr Vet Med Assoc* 1966; 37: 349–351
 79. Tusing TW. *Chronic Feeding: Dogs*. <http://www.cdpr.ca.gov/docs/risk/toxsums/pdfs/1023.pdf> (June 2015, date last accessed)
 80. Bhalla V, Grimm PC, Chertow GM et al. Melamine nephrotoxicity: emerging epidemic in an era of globalization. *Kidney Int* 2009; 75: 774–779
 81. Hau AK, Kwan TH, Li PK. Melamine toxicity and the kidney. *J Am Soc Nephrol* 2009; 20: 245–250
 82. Dorne JL, Doerge DR, Vandebroek M et al. Recent advances in the risk assessment of melamine and cyanuric acid in animal feed. *Tox Appl Pharmacol* 2013; 270: 218–219
 83. Burns K. Researchers examine contaminants in food, deaths of pets: survey, case definition, studies implicate combination of melamine and cyanuric acid. *J Am Vet Med Assoc* 2007; 231: 1632–1644
 84. Brown CA, Jeong KS, Poppenga RH et al. Outbreaks of renal failure associated with melamine and cyanuric acid in dogs and cats. *J Vet Diagn Invest* 2007; 19: 525–531
 85. Puschner B, Poppenga RH, Lowenstine LJ. Assessment of melamine and cyanuric acid toxicity in cats. *J Vet Diagn Invest* 2007; 19: 616–624
 86. Du GD. *Milk Powder Sent for Testing after Dozens of Babies Get Sick, Windows of China, Xinhua News*. http://nexs.xinhuanet.com/english/2008-09/11/content_9921877.htm (18 December 2008, date last accessed).
 87. Report on the Treatment of Children Suffering from Melamine-Tainted Milk Formula, Ministry of Health of the People's Republic of China. <http://www.moh.gov.cn/publicfiles/business/htmlfiles/mohbgt/s3582/20089/37957.htm> (18 December 2008, date last accessed).
 88. Recommendation on Diagnosis and Treatment of Children Consuming Melamine-Tainted Product, Ministry of Health of The People's Republic of China, 11 September 2008. <http://www.moh.gov.cn/publicfiles///business/cmsresources/mohyzs/cmsrsdocument/doc2317.doc> (18 December 2008, date last accessed).
 89. Preliminary Fact Sheet Concerning Urinary Stone Relating to Melamine-Tainted Milk Formula in Children, Ministry of Health of the People's Republic of China, 12 September 2008. <http://www.moh.gov.cn/publicfiles///business/htmlfiles/mohbgt/s3582/200809/37783.htm> (18 December 2008, date last accessed).
 90. Parry J. China's tainted infant formula sickens nearly 13000 babies. *BMJ* 2008; 337: 711
 91. Wu CF, Peng CY, Liu CC et al. Ambient melamine exposure and urinary biomarkers of early renal injury. *J Am Soc Nephrol* 2015; 26: 2821–2829
 92. Mast RW, Jeffcoat AR, Sadler BM et al. Metabolism, disposition and excretion of 14C melamine in male Fischer 344 rats. *Food Chem Toxicol* 1983; 21: 807–810
 93. Dobson RL, Motlagh S, Quijano M et al. Identification and characterization of toxicity of contaminants in pet food

- leading to an outbreak of renal toxicity in cats and dogs. *Toxicol Sci* 2008; 106: 2512–2562
94. Ogasawara H, Imaida K, Ishiwata H et al. Urinary bladder carcinogenesis induced by melamine in F344 male rats: correlation between carcinogenicity and urolith formation. *Carcinogenesis* 1995; 16: 2773–2777
 95. Yasui T, Kobayashi T, Okada A et al. Long-term follow-up of nephrotoxicity in rats administered both melamine and cyanuric acid. *BMC Res Notes* 2014; 7: 87
 96. Bandele OJ, Stine CB, Ferguson M et al. Use of urinary renal biomarkers to evaluate the nephrotoxic effects of melamine or cyanuric acid in non-pregnant and pregnant rats. *Food Chem Toxicol* 2014; 74: 301–308
 97. Son JY, Kang YJ, Kim KS et al. Evaluation of renal toxicity by combination exposure to melamine and cyanuric acid in male Sprague Dawley rats. *Toxicol Res* 2014; 30: 99–107
 98. Shang P, Chang H, Yue ZJ et al. Acute kidney injury caused by consumption of melamine-contaminated infant formula in 47 children: a multi-institutional experience in diagnosis, treatment and follow-up. *Urol Res* 2012; 40: 293–298
 99. Hambach R, Lison D, D'Haese P et al. Adverse effects of low occupational cadmium exposure on renal and oxidative stress biomarkers in solderers. *Occup Environ Med* 2013; 70: 108–113
 100. Hambach R, Lison D, D'Haese PC, et al. Co-exposure to lead increases the renal response to low levels of cadmium in metallurgy workers. *Toxicol Lett* 2013; 222: 233–8.
 101. Johri N, Jacquillet G, Unwin R. Heavy metal poisoning: the effects of cadmium on the kidney. *Biometals* 2010; 23: 783–292
 102. Smith NJ, Topping MD, Stewart JD et al. Occupational cadmium exposure in jig solderers. *Br J Ind Med* 1986; 43: 663–666
 103. Wieloch M, Kaminski P, Ossowska A et al. Do toxic heavy metals affect antioxidant defense mechanisms in humans? *Ecotoxicol Environ Saf* 2012; 78: 195–205
 104. Mason HJ, Williams N, Armitage S et al. Follow up of workers previously exposed to silver solder containing cadmium. *Occup Environ Med* 1999; 56: 553–558
 105. Joseph P. Mechanisms of cadmium carcinogenesis. *Toxicol Appl Pharmacol* 2009; 238: 272–279
 106. Orth SR, Viedt C, Ritz E. Adverse effects of smoking in the renal patient. *Tohoku J Exp Med* 2001; 194: 1–15
 107. Bernhard D, Rossmann A, Wick G. Metals in cigarette smoke. *IUBMB Life* 2005; 57: 805–809
 108. Mercado C, Jaimes EA. Cigarette smoking as a risk factor for atherosclerosis and renal disease: novel pathogenic insights. *Curr Hypertens Rep* 2007; 9: 66–72
 109. van Landeghem GF, de Broe ME, D'Haese PC. Al and Si: their speciation, distribution, and toxicity. *Clin Biochem* 1998; 31: 385–397
 110. Yokel RA, Lasley SM, Dorman DC. The speciation of metals in mammals influences their toxicokinetics and toxicodynamics and therefore human health risk assessment. *J Toxicol Environ Health B Crit Rev* 2006; 9: 63–85
 111. Barbier O, Jacquillet G, Tauc M et al. Acute study of interaction among cadmium, calcium, and zinc transport along the rat nephron in vivo. *Am J Physiol Renal Physiol* 2004; 287: F1067–F1075
 112. Barbier O, Jacquillet G, Tauc M et al. Effect of heavy metals on, and handling by, the kidney. *Nephron Physiol* 2005; 99: p105–p110
 113. Thevenod F. Catch me if you can! Novel aspects of cadmium transport in mammalian cells. *Biometals* 2010; 23: 857–75
 114. Al-Saleh I, Al-Sedairi A, Elkhatib R. Effect of mercury (Hg) dental amalgam fillings on renal and oxidative stress biomarkers in children. *Sci Total Environ* 2012; 431: 188–196
 115. Vahter ME. Interactions between arsenic-induced toxicity and nutrition in early life. *J Nutr* 2007; 137: 2798–2804
 116. Sabath E, Robles-Osorio ML. Renal health and the environment: heavy metal nephrotoxicity. *Nefrologia* 2012; 32: 279–286
 117. Devi SS, Biswas AR, Biswas RA et al. Heavy metal status and oxidative stress in diesel engine tuning workers of central Indian population. *J Occup Environ Med* 2007; 49: 1228–1234
 118. Garcon G, Leleu B, Marez T et al. Biomonitoring of the adverse effects induced by the chronic exposure to lead and cadmium on kidney function: usefulness of alpha-glutathione S-transferase. *Sci Total Environ* 2007; 377: 165–172
 119. Garcon G, Leleu B, Zerimech F et al. Biologic markers of oxidative stress and nephrotoxicity as studied in biomonitoring of adverse effects of occupational exposure to lead and cadmium. *J Occup Environ Med* 2004; 46: 1180–1186
 120. Thijssen S, Cuypers A, Maringwa J et al. Low cadmium exposure triggers a biphasic oxidative stress response in mice kidneys. *Toxicology* 2007; 236: 29–41
 121. Akesson A, Lundh T, Vahter M et al. Tubular and glomerular kidney effects in Swedish women with low environmental cadmium exposure. *Environ Health Perspect* 2005; 113: 1627–1631
 122. Ercal N, Gurer-Orhan H, Aykin-Burns N et al. Toxic metals and oxidative stress part I: mechanisms involved in metal-induced oxidative damage. *Curr Top Med Chem* 2001; 1: 529–539
 123. Valko M, Rhodes CJ, Moncol J et al. Free radicals, metals and antioxidants in oxidative stress-induced cancer. *Chem Biol Interact* 2006; 160: 1–40
 124. Han SG, Kim Y, Kashon ML et al. Correlates of oxidative stress and free-radical activity in serum from asymptomatic shipyard welders. *Am J Respir Crit Care Med* 2005; 172: 1541–1548
 125. Carpenter DO, Arcaro K, Spink DC. Understanding the human health effects of chemical mixtures. *Environ Health Perspect* 2002; 110: 25–42
 126. Ekong EB, Jaar BG, Weaver VM. Lead-related nephrotoxicity: a review of the epidemiologic evidence. *Kidney Int* 2006; 70: 2074–2084
 127. Wang G, Fowler BA. Roles of biomarkers in evaluating interactions among mixtures of lead, cadmium and arsenic. *Toxicol Appl Pharmacol* 2008; 233: 92–99
 128. Bernard A, Thielemans N, Roels H et al. Association between NAG-B and cadmium in urine with no evidence of a threshold. *Occup Environ Med* 1995; 52: 177–80
 129. Choudhury H, Mudipalli A. Potential considerations & concerns in the risk characterization for the interaction profiles of metals. *Indian J Med Res* 2008; 128: 462–483
 130. Navas-Acien A, Tellez-Plaza M, Guallar E et al. Blood cadmium and lead and chronic kidney disease in US adults: a joint analysis. *Am J Epidemiol* 2009; 170: 1156–1164
 131. Nordberg GF. Historical perspectives on cadmium toxicology. *Toxicol Appl Pharmacol* 2009; 238: 192–200
 132. Tellez-Plaza M, Navas-Acien A, Caldwell KL, Menke A, Muntner P, Guallar E. Reduction in cadmium exposure in the United States population, 1988–2008: the contribution of declining smoking rates. *Environ Health Perspect* 2012; 120: 204–9.
 133. Jarup L, Akesson A. Current status of cadmium as an environmental health problem. *Toxicol Appl Pharmacol* 2009; 238: 201–208

134. Golia E, Dimirkou A, Mitsios IK. Heavy-metal concentration in tobacco leaves in relation to their available soil fractions. *Commun Soil Sci Plant Anal* 2009; 40: 106–120
135. Nordberg G, Nogawa K, Nordberg M, Friberg L. Cadmium. In: (Nordberg GF, Fowler BF, Nordberg M, Friberg L, eds) p445–486. *Handbook on the Toxicology of Metals* Amsterdam: Elsevier, 2007; pp. 445–486.
136. Staessen JA, Vyncke G, Lauwerys RR et al. Transfer of cadmium from a sandy acidic soil to man: a population study. *Environ Res* 1992; 58: 25–34
137. Hogervorst J, Plusquin M, Vangronsveld J et al. House dust as possible route of environmental exposure to cadmium and lead in the adult general population. *Environ Res* 2007; 103: 30–37
138. Cucu D, D'Haese PC, De Beuf A et al. Low doses of cadmium chloride and methallothionein-1-bound cadmium display different accumulation kinetics and induce different genes in cells of the human nephron. *Nephron Extra* 2011; 1: 24–37
139. Prozialeck WC, Edwards JR. Mechanisms of cadmium-induced proximal tubule injury: new insights with implications for biomonitoring and therapeutic interventions. *J Pharmacol Exp Ther* 2012; 343: 2–12
140. Kim SC, Cho MK, Kim SG. Cadmium-induced non-apoptotic cell death mediated by oxidative stress under the condition of sulfhydryl deficiency. *Toxicol Lett* 2003; 144: 325–336
141. Brodsky SV, Nadasdy T. Acute and chronic tubulointerstitial nephritis. In: Jennette JC, D'Agati VD, Olson JL, Silva FG (eds). *Heptinstall's Pathology of the Kidney*, 7th ed. Philadelphia: Wolters Kluwer, 2015, pp. 1111–1154
142. Yasuda M1, Miwa A, Kitagawa M. Morphometric studies of renal lesions in itai-itai disease: chronic cadmium nephropathy. *Nephron* 1995; 69: 14–19
143. Smith J, Smith J, McCall A. Chronic poisoning from cadmium fume. *J Pathol Bacteriol* 1960; 80: 287
144. Nawrot TS, Staessen JA, Roels HA et al. Cadmium exposure in the population: from health risks to strategies of prevention. *Biometals* 2010; 23: 769–782
145. Pfadenhauer LM, Burns J, Rohwer A et al. Effectiveness of interventions to reduce exposure to lead through consumer products and drinking water: a systematic review. *Environ Res* 2016; 147: 525–536
146. Stromberg U, Lundh T, Skerfving S. Yearly measurements of blood lead in Swedish children since 1978: the declining trend continues in the petrol-lead-free period 1995–2007. *Environ Res* 2008; 107: 332–335
147. Venkatesh T. Editorial role of a clinical biochemist in evaluating the impact of lead poisoning. *Indian J Clin Biochem* 2013; 28: 1–2
148. Kim MA, Williams KA. Lead levels in landfill areas and childhood exposure: an integrative review. *Public Health Nurs* 2017; 34: 87–97
149. Chaumont A, De Winter F, Dumont X. The threshold level of urinary cadmium associated with increased urinary excretion of retinol-binding protein and beta 2-microglobulin: a re-assessment in a large cohort of nickel-cadmium battery workers. *Occup Environ Med* 2011; 68: 257–264
150. Gonick HC. Lead-binding proteins: a review. *J Toxicol* 2011; 2011: 686050
151. Chaumont A, Nickmilder M, Dumont X et al. Associations between proteins and heavy metals in urine at low environmental exposures: evidence of reverse causality. *Toxicol Lett* 2012; 210: 345–352
152. Wedeen RP, Emmerson BT. Lead nephropathy. In: De Broe ME, Porter GA, Bennett WM, Verpooten GA (eds). *Clinical Nephrotoxins: Renal Injury from Drugs and Chemicals*, 2nd edn. London: Kluwer Academic, 2003, pp. 495–506
153. Zhai Q, Narbad A, Chen W. Dietary strategies for the treatment of cadmium and lead toxicity. *Nutrients* 2015; 7: 552–571
154. Gibb H, O'Leary KG. Mercury exposure and health impacts among individuals in the artisanal and small-scale gold mining community: a comprehensive review. *Environ Health Perspect* 2014; 122: 667–672
155. Thygesen LC, Flachs EM, Hanehoj K et al. Hospital admissions for neurological and renal diseases among dentists and dental assistants occupationally exposed to mercury. *Occup Environ Med* 2011; 68: 895–901
156. Jarosinska D, Horvat M, Sallsten G et al. Urinary mercury and biomarkers of early renal dysfunction in environmentally and occupationally exposed adults: a three-country study. *Environ Res* 2008; 108: 224–232
157. Kulig K. A tragic reminder about organic mercury. *N Engl J Med* 1998; 338: 1692–1694
158. Berlin M ZR, Fowler BA. Mercury. *Handbook on the Toxicology of Metals*, 3rd edn. New York: Elsevier, 2007, p. 684.
159. Drasch G. Mercury. In: Seiler G, Sigel A and Sigels H. (eds). *Handbook on Metals in Clinical and Analytical Chemistry*, Eds. Marcel Dekker, New York: Marcel Dekker, 1994, pp. 479–493.
160. Zalups RK. Method for studying the in vivo accumulation of inorganic mercury in segments of the nephron in the kidneys of rats treated with mercuric chloride. *J Pharmacol Methods* 1991; 26: 89–104
161. Jan AT, Azam M, Siddiqui K et al. Heavy metals and human health: mechanistic insight into toxicity and counter defence system of antioxidants. *Int J Mol Sci* 2015; 16: 29592–29630
162. Jan AT, Ali A, Haq Q. Glutathione as an antioxidant in inorganic mercury induced nephrotoxicity. *J Postgrad Med* 2011; 57: 72–77
163. Zalups RK. Molecular interactions with mercury in the kidney. *Pharmacol Rev* 2000; 52: 113–143
164. Zalups RK, Barfuss DW. Participation of mercuric conjugates of cysteine, homocysteine, and N-acetylcysteine in mechanisms involved in the renal tubular uptake of inorganic mercury. *J Am Soc Nephrol* 1998; 9: 551–561
165. Bridges CC, Zalups RK. Molecular and ionic mimicry and the transport of toxic metals. *Toxicol Appl Pharmacol* 2005; 204: 274–308
166. Burston J, Darmady EM, Stranack F. Nephrosis due to mercurial diuretics. *Br Med J* 1958; 14: 1277–1279
167. Joekes AM, Heptinstall RH, Porter KA. The nephrotic syndrome; a study of renal biopsies in 20 adult patients. *QJ Med* 1958; 27: 495–516
168. Preedy JR, Russell DS. Acute salt depletion associated with the nephrotic syndrome developing during treatment with a mercurial diuretic. *Lancet* 1953; 265: 1181–1184
169. Cao Y, Skaug MA, Andersen O et al. Chelation therapy in intoxications with mercury, lead and copper. *J Trace Elem Med Biol* 2015; 31: 188–192
170. Mandema E, Arends A, Van Zeijst J et al. Mercury and the kidney. *Lancet* 1963; 1: 1266