



# Inside-Out Bucket-Handle Meniscus Repair With a Single-Handed Self-Advancing Zone-Specific Meniscus Repair Device

Gun Min Youn, B.A., Angelica M. R. Van Gogh, B.S., Asher B. Mirvish, B.A.,  
Moyukh O. Chakrabarti, M.B.B.S., Patrick J. McGahan, M.D., and  
James L. Chen, M.D., M.P.H.

**Abstract:** Meniscus tears are among the most common knee injuries in the general population and often are treated arthroscopically with a meniscus repair. Of the various meniscus repair techniques available, the inside-out meniscus tear is considered the gold standard due to its versatility and good clinical outcomes. The purpose of this Technical Note and accompanying video is to describe an inside-out bucket-handle meniscus repair using a single handed, self-advancing meniscus repair device with an interchangeable zone-specific multicannula system to decrease the technical difficulty and operative time of the repair.

The meniscus serves a major role in knee biomechanical function by acting as a shock absorber, maintaining joint stability, and ensuring proper articulation between the femoral condyles and tibial plateau.<sup>1,2</sup> Unfortunately, meniscus tears are the most common knee injury throughout the general population.<sup>3,4</sup> Of the various types of meniscal tears, bucket-handle tears are especially problematic due to the displacement of a significant portion of meniscal tissue.<sup>5</sup>

Today, the most widely used treatment options for a torn meniscus are either a meniscectomy or meniscus repair to remove or restore the damaged tissue, respectively.<sup>6,7</sup> Although meniscectomies provide symptomatic relief, the loss of meniscus tissue increases

knee joint load and significantly increases the long-term risk for osteoarthritis.<sup>7,8</sup> Thus, if possible, a meniscus repair should be performed to retain biomechanical function.

Of the many surgical meniscal repair options orthopaedic surgeons have at their disposal, the inside-out meniscus repair is considered the gold standard due to its versatility and good clinical outcomes.<sup>9</sup> The purpose of this Technical Note is to describe our version of the inside-out bucket-handle meniscus repair using a single-handed, self-advancing meniscus repair device with a zone-specific cannula attachment to reduce technical difficulty and operative time.

## Surgical Technique

### Preoperative Assessment

Preoperative assessment includes a physical examination and computed tomography or magnetic resonance imaging of the knee. Physical examination may find tenderness to palpation at the medial joint line as well as painful active and passive range of motion with a positive medial and/or lateral McMurray's test. Magnetic resonance imaging or computed tomography imaging may be used to identify the location and extent of the meniscus tear.

### Patient Positioning and Preparation

Before the procedure, the patient is seen in the preoperative area and the correct knee is marked. The

From *Advanced Orthopaedics and Sports Medicine, San Francisco, California, U.S.A.*

The authors report the following potential conflict of interest or source of funding: J.L.C. is an educational consultant for Arthrex and receives compensation for medical educational lectures and instruction only. Full ICMJE author disclosure forms are available for this article online, as [supplementary material](#).

This investigation was performed at *Advanced Orthopaedics and Sports Medicine*.

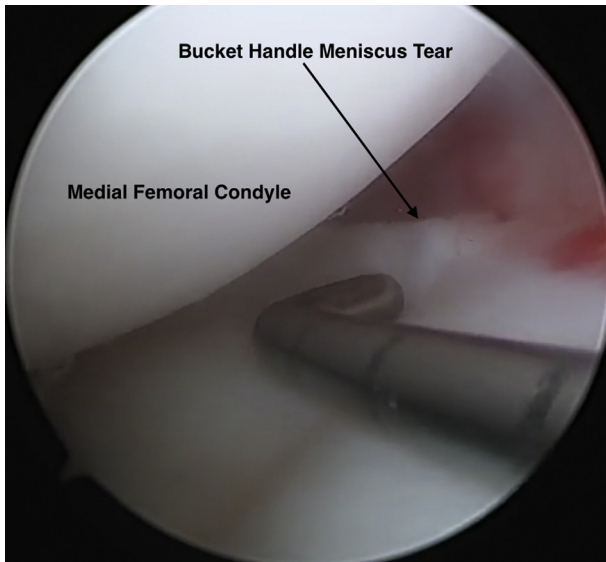
Received July 3, 2019; accepted September 11, 2019.

Address correspondence to Gun Min Youn, B.A., *Advanced Orthopaedics and Sports Medicine, 450 Sutter St., Suite 400, San Francisco, CA 94108.*  
E-mail: [gunmin.chris.youn@gmail.com](mailto:gunmin.chris.youn@gmail.com)

© 2019 by the Arthroscopy Association of North America. Published by Elsevier. This is an open access article under the CC BY-NC-ND license (<http://creativecommons.org/licenses/by-nc-nd/4.0/>).

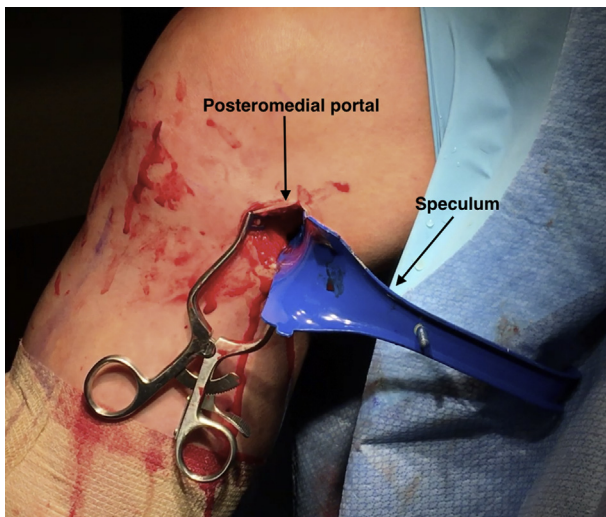
2212-6287/19841

<https://doi.org/10.1016/j.eats.2019.09.007>

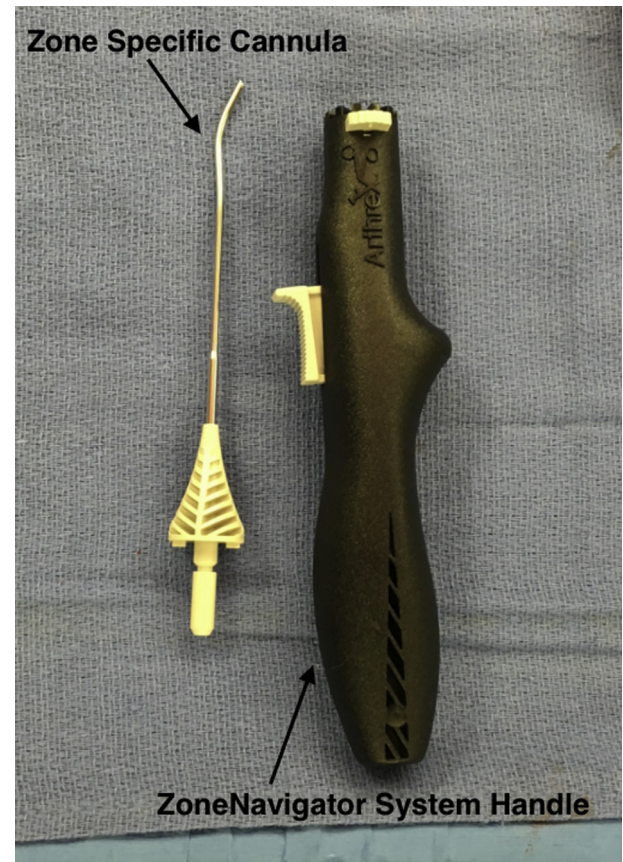

**Fig 1.** Intraoperative image of the medial meniscus bucket-handle tear as seen through the anterolateral portal of the right knee using a 30° 4.0-mm arthroscope (Arthrex). A probe is used to assess the severity of the tear and determine if it is a suitable candidate for an inside-out meniscus repair. A posteromedial incision of the right knee is created with a no. 15 blade if the meniscus tear is deemed repairable.

patient is transferred to the operating room, placed supine on a standard operating table, and anesthetized with general anesthesia. A tourniquet is applied to the proximal thigh of the operative leg to minimize blood loss and maximize visualization. The leg is then placed in an OSI leg-holder (Mizuho OSI, Union City, CA). All bony prominences are well padded and



**Fig 2.** Operative image of the posteromedial incision on the right knee. The speculum is used to prevent iatrogenic damage by retracting and protecting neurovascular structures such as the saphenous nerve and popliteal artery. The posteromedial incision is used as the point of exit for the long needles used in the inside-out technique.




**Fig 3.** The ZoneNavigator System (Arthrex) is opened on the back table. The handle for this system allows for a single hand to both advance and withdraw the needle in 1-cm increments without the need for an assistant. This system is also disposable and eliminates the need for equipment sterilization. The zone-specific cannula is used to access the tear on the medial meniscus.

preoperative skin prep solution is applied to the operative leg from the mid-thigh to foot before draping it in the usual sterile fashion.

### Diagnostic Arthroscopy

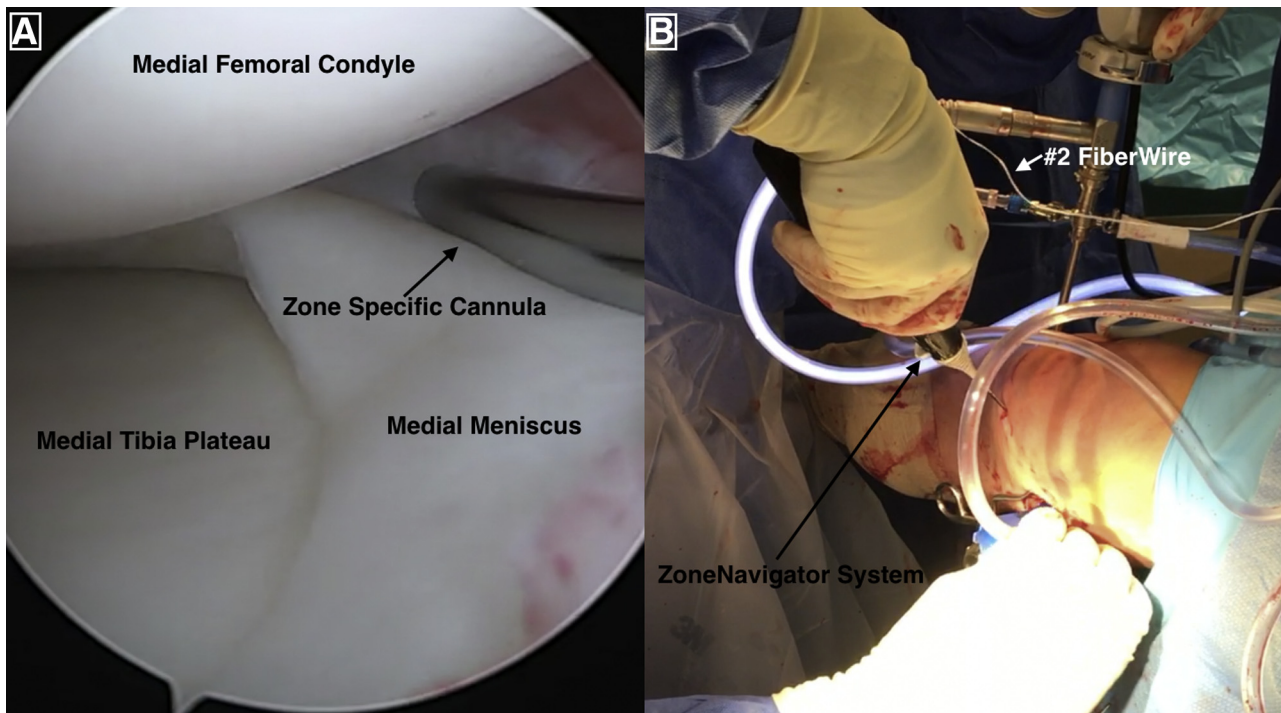
A no. 11 blade is used to create the anterolateral portal by making a vertical incision adjacent to the lateral border of the patellar tendon at the level of the joint line. The portal is then dilated with a blunt trocar and an arthroscopic sheath. The trocar is removed and a 30° 4.0-mm arthroscope (Arthrex, Naples, FL) is inserted in the anterolateral portal to perform a complete diagnostic knee arthroscopy and visualize the bucket-handle medial meniscus tear. A no. 11 blade is used to create the anteromedial portal. A probe is introduced to determine the extent of the tear and to determine whether it is a suitable candidate for repair (Fig 1). If the tear is deemed repairable, a posteromedial incision is created between the gastrocnemius and joint capsule with a no. 15 blade in preparation for the inside-out repair.



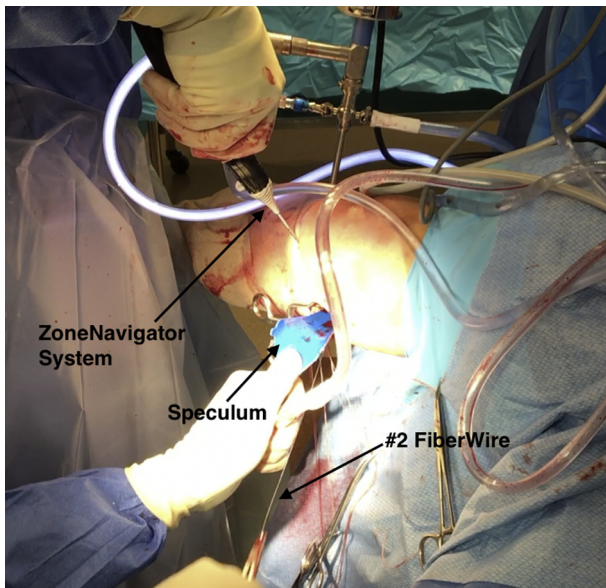
**Fig 4.** Operative image of the #2 FiberWire suture connected to the repair needle before needle advancement. This needle is fed through the rear of the handle by the assistant to prepare for advancement through the anteromedial portal of the right knee. The advancement is conducted by surgeon in 1-cm increments with the use of only one hand. The needles used in the inside-out meniscus repair procedure are smaller in diameter compared with the needles used in the all-inside technique and thus reduce the risk of iatrogenic damage.

### Inside-Out Repair (With Video Illustration)

A speculum is placed through the posteromedial incision to protect neurovascular structures such as the saphenous nerve and popliteal artery and minimize the risk of iatrogenic damage (Fig 2). An appropriate cannula is selected (Fig 3) based on the location of the tear from the multicannula system from the ZoneNavigator set (Arthrex). The zone-specific cannula is inserted through the anteromedial portal. The first repair needle with an attached #2 FiberWire suture (Arthrex) is fed through the rear of the handle by an assistant (Fig 4). The needle is then advanced by the surgeon in 1-cm increments through the meniscus. After advancement by the surgeon, the needle is retrieved by the assistant through the posteromedial incision between the joint capsule and gastrocnemius, removed, and cut (Fig 5). The cannula is adjusted and the second needle is also advanced through the meniscus, retrieved through the posteromedial incision, and cut (Fig 6). This process is repeated as needed throughout the extent of the tear to fully address the meniscus tear. The corresponding pair of FiberWire suture ends exiting from the posteromedial incision are then tensioned and knotted over the joint capsule. This step is repeated for each pair of suture ends. The excess suture is then cut and the final repair is probed (Fig 7). These key steps are illustrated



**Fig 5.** (A) Intraoperative arthroscopic image as seen through the anterolateral portal of the right knee of the zone-specific cannula being used to guide the long repair needle and the #2 FiberWire. (B) Operative image of the surgeon advancing the needle in 1-cm increments with the use of one hand through the medial meniscus of the right knee. The use of the ZoneNavigator System (Arthrex) allows for needle advancement without the need for an assistant, reducing the technical difficulty of the procedure.



**Fig 6.** Operative image of a needle driver being used by the assistant to withdraw the long needle and #2 FiberWire from the posteromedial incision of the right knee. A speculum should be used to protect neurovascular structures such as the popliteal artery and saphenous nerve and prevent iatrogenic damage. After withdrawal, the long needle is removed, and the corresponding FiberWire suture ends are tensioned and knotted over the joint capsule of the right knee.

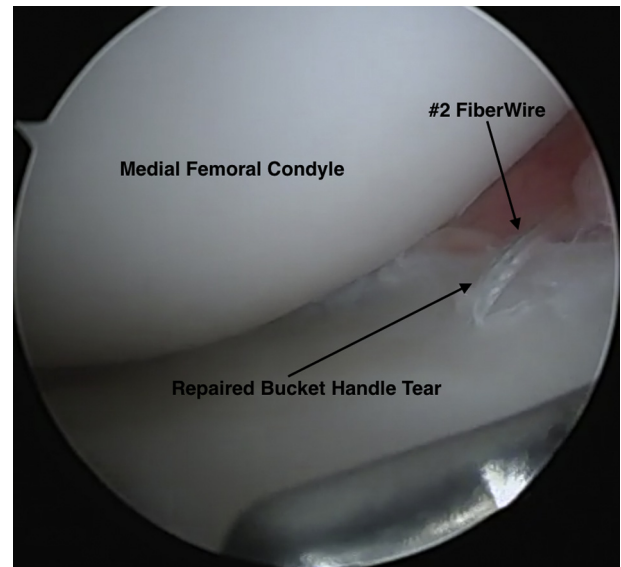
in [Video 1](#). The pearls and pitfalls of this procedure are outlined in [Table 1](#).

### Final Examination and Postoperative Care

For the first 2 weeks, the patient should remain in a brace at all times and remain nonweight-bearing until wound healing occurs and sutures are removed. The patient should remain nonweight-bearing for an additional 2 weeks. Formal physical therapy and home exercises may also begin, with the focus on passive and active range of motion to maximize quadriceps control as well as patellar mobility. Six to twelve weeks after the operation, physical therapy and home exercises should aim to return the knee to full range of motion and restore normal gait. The patient may begin running at the 4-month mark and return to full activity as tolerated between 6 and 8 months.

## Discussion

With modern medical advances, arthroscopic procedures such as partial meniscectomies or meniscus repairs are common treatment options for a torn meniscus. However, Roemer et al.<sup>6</sup> noted that undergoing a partial meniscectomy significantly increased the risk of furthering cartilage damage. At 1-year follow-up of patients previously diagnosed with concurrent osteoarthritis and meniscus damage, 80.8% of knees that underwent partial meniscectomy demonstrated



**Fig 7.** Intraoperative arthroscopic image of the completed inside-out medial meniscus bucket-handle repair as seen through the anterolateral portal of the right knee. The #2 FiberWire mattress suture can be seen. The use of the ZoneNavigator System (Arthrex) eliminates the need for an assistant to advance the needle and thus reduces the technical difficulty and operative time of the procedure.

cartilage loss in the interval period compared with 37.4% of knees that had no meniscus surgery.<sup>6</sup> This disparity may be attributed to the increased knee joint load following a partial meniscectomy, as noted by Thorlund et al.<sup>8</sup>

Compared with partial meniscectomies, meniscus repairs focus on preserving as much meniscal tissue as possible to retain its biomechanical properties. Today, the inside-out repair technique is considered the gold standard for treatment due to its good clinical outcomes in addition to its versatility and use of smaller diameter needles.<sup>9,10</sup> In a study conducted on elite athletes with either standalone meniscus tears or meniscus tears with concomitant anterior cruciate ligament tears using this technique, Logan et al.<sup>11</sup> found that 81% of patients were able to return to full activity within an average of 10.4 months. In a

**Table 1.** Pearls and Pitfalls of an Inside-Out Meniscus Repair Using the ZoneNavigator System

Pearls	Pitfalls
<ul style="list-style-type: none"> <li>When placing sutures, keep the tip of the needle exposed to assist with proper suture placement</li> <li>Use a speculum to retract and protect the saphenous nerve</li> </ul>	<ul style="list-style-type: none"> <li>Avoid needle contact with neurovascular structures, including the tibial nerve and popliteal artery, to avoid iatrogenic damage</li> </ul>

**Table 2.** Advantages and Disadvantages of an Inside-Out Meniscus Repair Using the ZoneNavigator System

Advantages	Disadvantages
<ul style="list-style-type: none"> <li>• Allows for the surgeon to advance the needle without the need for an assistant</li> <li>• Smaller-diameter needles minimize the risk of iatrogenic meniscus damage relative to larger diameter needles of the all-inside technique</li> <li>• Reduced operative time</li> <li>• Reduced technical difficulty</li> <li>• Interchangeable cannula system maximizes versatility of the system</li> <li>• Disposable system eliminates the need for equipment sterilization</li> </ul>	<ul style="list-style-type: none"> <li>• Risk of iatrogenic damage to the saphenous and tibial nerves and popliteal artery</li> <li>• Risk of iatrogenic chondral damage</li> <li>• Need for additional incision on the posterior aspect of the knee</li> </ul>

systematic review by Grant et al.,<sup>12</sup> the clinical failure rate using this technique was found to be 17%. In a more recent systematic review, Fillingham et al.<sup>9</sup> note an even lower rate of clinical failure at 11%. However, it is important to note that this same study also analyzed the failure rates of the inside-out technique to the all-inside technique and noted similar functional outcomes and clinical failure rates.

The proposed technique maintains the advantages provided by the standard inside-out meniscus repair while reducing operative time as well as technical difficulty. In a standard inside-out meniscus repair, the assistant inserts and advances the needle while the surgeon maintains control of the cannula. Our proposed technique eliminates the need for an assistant to advance the needle by using the ZoneNavigator system's handle, which allows for needle advancement and withdrawal in 1-cm increments with the use of only one hand. Another advantage of our technique is the use of the interchangeable multiple-cannula system, which allows for suture placement throughout the posterior, middle, and anterior meniscal zones, maximizing the versatility of this procedure. In addition, as this system is disposable, the waiting time for equipment sterilization is eliminated. Finally, the wider SutureTape meniscal needles also can be used instead of FiberWire to provide greater security of the repair by distributing force over a larger area and consequently reducing the risk for tissue pull-through.

One potential disadvantage of our technique is that similar to every inside-out meniscus repair, there is the need for an additional posterior incision and the risk of iatrogenic neurovascular damage is not nonexistent (Table 2). Further studies are necessary to analyze if this technique leads to better patient outcomes and lower failure rates.

## References

1. Renstrom P, Johnson RJ. Anatomy and biomechanics of the menisci. *Clin Sports Med* 1990;9:523-538.
2. Fox AJS, Wanivenhaus F, Burge AJ, Warren RF, Rodeo SA. The human meniscus: A review of anatomy, function, injury, and advances in treatment. *Clin Anat* 2014;28:269-287.
3. Xu C, Zhao J. A meta-analysis comparing meniscal repair with meniscectomy in the treatment of meniscal tears: The more meniscus, the better outcome? *Knee Surg Sports Traumatol Arthrosc* 2013;23:164-170.
4. Espejo-Reina A, Serrano-Fernández JM, Martín-Castilla B, Estades-Rubio FJ, Briggs KK, Espejo-Baena A. Outcomes after repair of chronic bucket-handle tears of medial meniscus. *Arthroscopy* 2014;30:492-496.
5. Moatshe G, Cinque ME, Godin JA, Vap AR, Chahla J, LaPrade RF. Comparable outcomes after bucket-handle meniscal repair and vertical meniscal repair can be achieved at a minimum 2 years' follow-up. *Am J Sports Med* 2017;45:3104-3110.
6. Roemer FW, Kwok CK, Hannon MJ, et al. Partial meniscectomy is associated with increased risk of incident radiographic osteoarthritis and worsening cartilage damage in the following year. *Eur Radiol* 2016;27:404-413.
7. Stein T, Mehling AP, Welsch F, von Eisenhart-Rothe R, Jäger A. Long-term outcome after arthroscopic meniscal repair versus arthroscopic partial meniscectomy for traumatic meniscal tears. *Am J Sports Med* 2010;38:1542-1548.
8. Thorlund JB, Holsgaard-Larsen A, Creaby MW, et al. Changes in knee joint load indices from before to 12 months after arthroscopic partial meniscectomy: A prospective cohort study. *Osteoarthritis Cartilage* 2016;24:1153-1159.
9. Fillingham YA, Riboh JC, Erickson BJ, Bach BR, Yanke AB. Inside-out versus all-inside repair of isolated meniscal tears: An updated systematic review. *Am J Sports Med* 2016;45:234-242.
10. Nelson CG, Bonner KF. Inside-out meniscus repair. *Arthrosc Tech* 2013;2:e453-e460.
11. Logan M, Watts M, Owen J, Myers P. Meniscal repair in the elite athlete. *Am J Sports Med* 2009;37:1131-1134.
12. Grant JA, Wilde J, Miller BS, Bedi A. Comparison of inside-out and all-inside techniques for the repair of isolated meniscal tears. *Am J Sports Med* 2011;40:459-468.