

## Clinical Characteristics of Cerebellar Infarction Due to Arterial Dissection

### Abstract

**Objectives and Background:** Arterial dissection (AD) of the vertebral artery (VA) or its branches may cause ischemic stroke of the posterior circulation. However, clinical and radiological characteristics of patients with AD-related cerebellar infarction (CI) have rarely been reported.

**Methods:** Forty-nine patients with CI admitted to our department from April 2008 to March 2015 were identified from our database. After dichotomization into the AD and non-AD group, their demographics and presenting symptoms were compared. Subsequently, a multivariate regression analysis was performed to identify variables that correlated with AD. **Results:** During the 7-year period, 14 and 35 patients were identified in the AD and non-AD group, respectively. The AD group was significantly younger than the non-AD group ( $55.0 \pm 16.3$  vs.  $69.7 \pm 10.7$  years,  $P = 0.001$ ) and was also more likely to experience acute pain at onset (86% vs. 17%,  $P < 0.001$ ). Using a multivariate regression analysis, these two variables and the male sex were found to correlate with AD. AD was located in extracranial VA ( $n = 3$ ); intracranial VA ( $n = 8$ ); posterior inferior cerebellar artery (PICA) ( $n = 3$ ); and superior cerebellar artery ( $n = 1$ ). Identification of AD was delayed in one patient with an extracranial VA and one patient with a PICA dissection. **Conclusions:** AD was responsible for approximately 30% of CI in our cohort. Pain at onset may be a useful symptom to identify patients with AD-related CI. While intracranial VA was the most common location of AD, physicians should be aware of the possibility of extracranial VA or PICA dissection in patients with seemingly unremarkable radiological findings.

**Keywords:** Arterial dissection, cerebellar infarction, extracranial, posterior inferior cerebellar artery, vertebral artery

### Introduction

The frequency of cerebellar infarction (CI) is substantially lower compared with that of supratentorial infarction as the former has accounted for only 3% of strokes in recent epidemiological studies.<sup>[1,2]</sup> Arterial dissection (AD) has long been known to be a cause of ischemic stroke,<sup>[2]</sup> and the vertebral artery (VA) and/or its branches are more likely to be involved in a dissection than the carotid artery in East Asian populations.<sup>[3]</sup> However, the clinical and radiological characteristics of patients with AD-related CI have rarely been reported in literature.<sup>[4]</sup> Since diagnostic delay is not uncommon in patients with CI,<sup>[5,6]</sup> early identification of AD-related CI by clinical characteristics may be beneficial not only for strokeologists but also for primary care and emergency physicians. A single-center retrospective study was conducted with the aim of clarifying the clinical and radiological characteristics of patients with AD-related CI.

This is an open access journal, and articles are distributed under the terms of the Creative Commons Attribution-NonCommercial-ShareAlike 4.0 License, which allows others to remix, tweak, and build upon the work non-commercially, as long as appropriate credit is given and the new creations are licensed under the identical terms.

For reprints contact: reprints@medknow.com

### Methods

#### Patient background

Clinical data related to patients with CI admitted to our department from April 2008 to March 2015 were retrieved from an institutional database. Patients who sustained a concomitant brainstem infarction were excluded from analysis. Patients with CI were classified into three groups according to the stroke etiology: (1) cardioembolic; (2) atherothrombotic; and (3) AD. The first two groups were subsequently combined to form a non-AD group. All patients with CI underwent brain computed tomography (CT), magnetic resonance imaging (MRI), and MR angiography (MRA) within 24 h of admission. Three-dimensional CT angiography (CTA) was also routinely performed, while digital subtraction angiography was performed only in selected patients. Board-certified radiologists reviewed all MRA and CTA images, and diagnosis of AD was established based

**How to cite this article:** Inamasu J, Nakae S, Kato Y, Hirose Y. Clinical characteristics of cerebellar infarction due to arterial dissection. *Asian J Neurosurg* 2018;13:995-1000.

Joji Inamasu,  
Shunsuke Nakae,  
Yoko Kato,  
Yuichi Hirose

Department of Neurosurgery,  
Fujita Health University  
Hospital, Toyoake, Japan

**Address for correspondence:**  
Dr. Joji Inamasu,  
Department of Neurosurgery,  
Fujita Health University  
Hospital, 1-98 Dengakugakubo,  
Toyoake 470-1192, Japan.  
E-mail: inamasu@fujita-hu.ac.jp

#### Access this article online

Website: [www.asianjns.org](http://www.asianjns.org)

DOI: 10.4103/ajns.AJNS\_373\_16

#### Quick Response Code:



on the criteria of the Strategies Against Stroke Study for Young Adults in Japan (SASSY Japan).<sup>[7]</sup> Demographic variables were compared between the AD group and non-AD group, including patients' age, sex, and underlying medical conditions. Furthermore, patients' presenting symptoms (e.g., headache, vertigo/dizziness, and ataxia/dysarthria) were also compared. This study was approved by our Institutional Internal Review Board, and informed consent was obtained either from patients themselves or from their surrogates.

### Clinical course

Variables related to the clinical outcomes were compared between the AD and non-AD groups. These variables included (1) the diagnostic delay in establishing diagnosis by primary care/emergency physicians; (2) neurologic deterioration due to progression of the dissection or worsening of brain edema; and (3) the modified Rankin Scale (mRS) score evaluated at discharge. Patients with discharge mRS scores  $\leq 2$  were considered to have favorable outcomes.

### Multivariate logistic regression analysis

An effort was made to identify clinical variables that correlated with AD by conducting a multivariate logistic regression analysis. The variables included age, sex, underlying medical conditions, and presenting symptoms (e.g., pain at onset, vertigo, and ataxia/dysarthria).

### Statistical analysis

The Fisher's exact test was used to compare differences in categorical variables, and the Student's *t*-test was used to compare differences in numerical variables. A multivariate logistic regression analysis was performed using JMP software (SAS Institute, Cary, NC, USA) to identify variables that correlated with AD. Numerical data are expressed as the mean  $\pm$  SD, and  $P < 0.05$  was considered to be statistically significant.

### Summary of patients with arterial dissection

The clinical and radiological characteristics of patients with AD-related CI were summarized with an emphasis on the anatomical distribution of AD and temporal profile. Furthermore, representative cases are presented to highlight the potential pitfalls in the diagnosis of AD-related CI.

## Results

### Demographics

During the 7-year study period, a total of 49 patients with CI were admitted to our institution (35 men and 14 women; mean age:  $62.5 \pm 12.5$  years). The 49 patients were divided into three groups based on their stroke etiologies: (1) AD ( $n = 14$ ); (2) cardioembolic ( $n = 18$ ); and (3) atherothrombotic ( $n = 17$ ). The latter two groups were then combined to form the non-AD group. During the same period, 7 AD patients harboring both

a brainstem and cerebellar ischemia were treated at our institution, and they were excluded from analysis. Comparison of the demographic variables revealed that the AD group was significantly younger than the non-AD group ( $55.0 \pm 16.3$  vs.  $69.7 \pm 10.7$  years,  $P = 0.001$ ) [Table 1]. The frequency of chronic hypertension and atrial fibrillation was significantly higher in the non-AD group. Otherwise, there were no significant intergroup differences [Table 1]. Regarding the presenting symptoms, the AD group was significantly more likely to experience pain with a sudden onset (i.e., headache or posterior neck pain) compared with the non-AD group (86% vs. 17%,  $P < 0.001$ ). There were no significant differences in the frequency of other symptoms between the two groups.

### In-hospital course

In the AD group, 14% of primary care/emergency physicians who first treated patients failed to establish the diagnosis of CI. The rate was 26% in the non-AD group, and there was no significant difference between the two rates ( $P = 0.47$ ). In the AD group, 6 patients (43%) experienced neurologic worsening: Four patients were affected by a worsening of brain edema, for which a decompressive craniectomy (DC) was performed, and the other two sustained progression of AD and ischemia. In the non-AD group, 7 patients exhibited a worsening of brain edema for which DC was performed, and the other 3 patients experienced progression of AD and ischemia. The frequency of DC was not significantly different between the two groups. Eleven patients (79%) from the AD group and 15 patients from the non-AD group (43%) were discharged with mRS scores  $\leq 2$ , respectively. The difference was statistically significant ( $P = 0.03$ ). There was no significant difference in the mean hospital stay between the two groups ( $41.0 \pm 19.2$  days vs.  $40.4 \pm 31.2$  days,  $P = 0.95$ ).

### Multivariate logistic regression analysis

The results of the multivariate logistic regression analysis were summarized in Table 2. The variables included patient's age, male sex, chronic hypertension, diabetes mellitus, atrial fibrillation, pain at onset, vertigo/dizziness, and ataxia/dysarthria. Among these variables, age (odds ratio [OR]: 0.839; 95% confidence interval [CI]: 0.722–0.974;  $P = 0.02$ ), male sex (OR: 53.281; 95% CI: 1.825–1555.69;  $P = 0.02$ ), and presence of pain at onset (OR: 72.600; 95% CI: 1.705–3090.866;  $P = 0.03$ ) were correlated with AD [Table 2].

### Summary of patients with arterial dissection

The 14 AD patients were classified based on anatomical distribution of the dissection [Table 3]. Three patients exhibited a dissection in the extracranial VA; seven patients had a dissection in the intracranial VA; three patients displayed a dissection in the posterior-anterior cerebellar artery (PICA); and one patient had a

**Table 1: Comparison of demographic variables between arterial dissection and nonarterial dissection**

	AD (n=14), n (%)	Non-AD (n=35), n (%)	P
Age (years)	55.0±16.3	69.7±10.7	0.001*
Male versus female	12:2	23:12	0.29
Admission GCS score ≤12	1 (7)	4 (11)	1.00
Cardioembolism versus atherosclerosis	N/A	18:17	N/A
Vascular territory affected (PICA vs. SCA)	12:2	31:4	1.00
Chronic hypertension	6 (43)	28 (80)	0.02*
Diabetes mellitus	4 (29)	13 (37)	0.74
History of IHD/stroke	2 (14)	15 (43)	0.10
Atrial fibrillation	1 (7)	16 (46)	0.02*
Presenting symptoms			
Pain of sudden onset	12 (86)	6 (17)	<0.0001*
Vertigo/dizziness	12 (86)	24 (69)	0.30
Nausea/vomiting	8 (57)	22 (63)	1.00
Ataxia/dysarthria	7 (50)	18 (51)	1.00

\*Statistically significant. AD – Arterial dissection; GCS – Glasgow Coma Scale; IHD – Ischemic heart disease; PICA – Posterior inferior cerebellar artery; SCA – Superior cerebellar artery; N/A – Not available

**Table 2: Multivariate regression analysis to identify variables that correlated with arterial dissection**

Variables	OR	95% CI	P
Age	0.839	0.722-0.974	0.02*
Male sex	53.281	1.825-1555.649	0.02*
Chronic hypertension	1.095	0.053-22.822	0.95
Diabetes mellitus	1.897	0.067-53.775	0.71
Atrial fibrillation	22.889	0.524-1000.404	0.11
Pain with sudden onset	72.600	1.705-3090.866	0.03*
Vertigo/dizziness	3.874	0.115-130.344	0.45
Ataxia/dysarthria	3.801	0.179-80.769	0.39

\*Statistically significant. CI – Confidence interval; OR – Odds ratio

dissection in the superior cerebellar artery. Only one patient could recall a recent episode of trauma to the neck. While the diagnosis of CI was established without delay in 12 of the 14 patients [86%, Table 4], identification of AD as a cause of CI was delayed in 3 of the 14 patients (Case 2, 3, 11).

Regarding the management of ischemia, all three patients with extracranial VA dissection (Case 1–3) received anticoagulants, and 10 of the 11 patients with intracranial VA dissection (Case 4–14) received antiplatelet therapy. Among the 12 patients who received follow-up imaging studies, none exhibited a configuration change of dissection into an aneurysmal shape [Table 3]. Similarly, none of the 12 patients sustained recurrence of CI.

## Case illustrations

### Case 2

A 54-year-old man with chronic hypertension visited ED of a local hospital following the sudden onset of posterior neck pain and left-sided homonymous hemianopsia. A brain CT revealed a subcortical hemorrhage in the right occipital lobe [Figure 1a]. He was diagnosed with a hypertensive intracerebral hemorrhage and admitted

for several days to receive conservative management before he was discharged home. However, 2 weeks later, he experienced dizziness and visited our ED. A brain MRI (diffusion-weighted images) revealed a high-intensity signal in the left cerebellar hemisphere which corresponded to the area perfused by the left PICA [Figure 1b]. The left PICA was poorly depicted on the brain MRA [Figure 1c] and a presumptive diagnosis of atherosclerotic PICA occlusion was made. However, CTA of the extracranial vessels obtained the next day revealed a tapered occlusion of the left VA inside the transverse foramen [Figure 1d]. In addition, a thin-slice contrast-enhanced axial image at the C5 level showed a double-lumen sign [Figure 1e], establishing the diagnosis of an extracranial VA dissection. In retrospect, the initial hemorrhage in the right occipital lobe was not an arterial bleeding but was a hemorrhagic infarction secondary to a temporary embolic occlusion of the left posterior cerebral artery. Anticoagulation with warfarin was initiated, and the patient has not experienced a recurrent infarction for over a year.

### Case 11

A 55-year-old woman visited our ED with a complaint of vertigo and sudden-onset headache. A diffusion-weighted MRI revealed a high-signal intensity lesion in the right cerebellar hemisphere [Figure 2a], leading to the diagnosis of CI. Although depiction of the right PICA was poor, a pathologic process involving the PICA remained unclear [Figure 2b]. CTA performed the next day revealed a pearl-string lesion at the orifice of the right PICA [Figure 2c], establishing the diagnosis of a right PICA dissection. The patient recovered uneventfully with conservative management, including administration of aspirin. A repeated CTA obtained a month after admission showed improvement in the stenosis of the PICA distal to the dissection [Figure 2d].

Table 3: Summary of 14 patients with cerebellar infarction due to arterial dissection

Case	Age, sex	Location of dissection	History of trauma	HA symptoms	Other symptoms	Delay in identifying dissection	MRA/CTA findings	Progression of dissection	DC Tx with AC/AP	Discharge mRS	Follow-up (m)	Follow-up images
1	39, male	VA (V1), right	No	Yes	V/D, A/D	No	Pearl/string	Yes	No Warfarin	4	68	Recanalized
2	54, male	VA (V2), right	No	Yes	V/D	Yes	Tapered occlusion	No	No Warfarin	2	13	Occluded
3	37, male	VA (V3), left	No	Yes	V/D, N/V, A/D	Yes	Double lumen	No	Yes Edoxaban	2	9	No change
4	75, male	VA (V4), right	No	Yes	V/D	No	Pearl/string	No	Yes Clopidogrel	3	75	Occluded
5	55, male	VA (V4), right	No	No	V/D, N/V	No	Tapered occlusion	Yes	No Clopidogrel	2	30	Occluded
6	58, male	VA (V4), right	No	Yes	A/D	No	Tapered occlusion	No	No Aspirin	2	72	Occluded
7	45, male	VA (V4), left	Yes	Yes	V/D	No	Pearl/string	No	No Ozagrel	2	16	Recanalized
8	75, male	VA (V4), left	No	Yes	V/D, N/V	No	Tapered occlusion	No	No Aspirin	1	12	Recanalized
9	79, male	VA (V4), left	No	Yes	N/V	No	Pearl/string	No	No Clopidogrel	2	78	N/A
10	63, male	VA (V4), left	No	Yes	V/D, N/V	No	Pearl/string	No	No Cilostazol	1	68	Recanalized
11	55, female	PICA, right	No	Yes	V/D, N/V	Yes	Pearl/string	No	No Aspirin	1	9	Recanalized
12	49, male	PICA, left	No	No	V/D, N/V, A/D	No	Tapered occlusion	No	Yes Cilostazol	4	3	N/A
13	49, male	PICA, left	No	Yes	V/D	No	Pearl/string	No	Yes No	2	70	Recanalized
14	20, female	SCA, left	No	Yes	V/D, A/D	No	Tapered occlusion	No	No Aspirin	1	68	Recanalized

AC/AP – Anticoagulant/antiplatelet; A/D – Ataxial/dysarthria; CTA – Computed tomography angiography; DC – Decompressive craniectomy; HA – Headache; MRA – Magnetic resonance angiography; mRS – Modified Rankin Scale; N/A – Not available; N/V – Nausea/vomiting; PICA – Posterior inferior cerebellar artery; SCA – Superior cerebellar artery; VA – Vertebral artery; V/D – Vertigo/dizziness

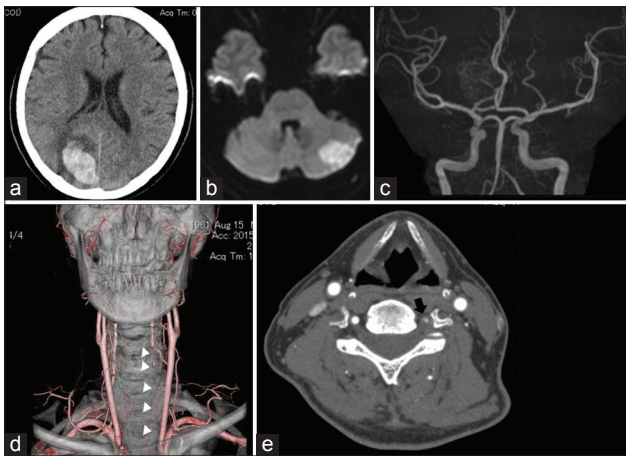
## Discussion

AD involving the intracranial VA or its branches is relatively common in East Asian countries.<sup>[3]</sup> The degree of destruction of the adventitia may be one of the most crucial factors in determining the manifestation of patients with AD as they may either sustain a hemorrhage, ischemia, or only pain.<sup>[2,8,9]</sup> It has been known that VA dissection is a cause of posterior circulation stroke, including CI.<sup>[1,2]</sup> However, the clinical and radiological characteristics of patients with AD-related CI have rarely been reported in literature.

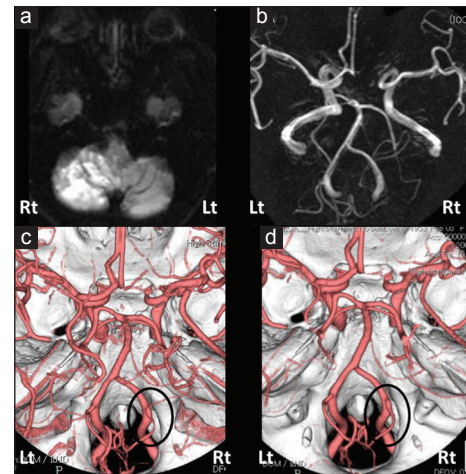
AD was found to be the cause of CI in as many as 30% of our cohort. Therefore, it is imperative that AD be considered during the initial evaluation of patients suspected of CI. Pain at onset, particularly a headache or posterior neck pain, is suggestive of AD and was present in 86% [Table 1]. The pain is thought to be referred pain associated with the nerves connected to the vessels. Only one patient could recall an episode of traumatic injury before the onset of symptoms, suggesting that trauma may not necessarily be a triggering event for dissection. The frequency of delay in establishing the diagnosis of CI by primary care/emergency physicians did not differ significantly between the AD and non-AD group [Table 4] although the sudden-onset pain may serve as a warning sign in the former. In total, diagnosis of CI was delayed in 22% of our cohort, which highlights the difficulty in establishing a diagnosis of CI.<sup>[5,6]</sup> Other demographic variables that correlated with AD, including younger age at onset and male preponderance, are in agreement with the published literature.<sup>[10,11]</sup> Significantly, better outcomes in the AD group [Table 4] may have partly been due to the younger age in that population.

Based on the anatomical distribution of AD, the 13 patients were classified into three categories: (1) extracranial VA dissection ( $n = 3$ ); (2) intracranial VA dissection ( $n = 7$ ); and (3) PICA dissection ( $n = 3$ ), except for one patient with an SCA dissection which occurs very rarely.<sup>[12]</sup> Patients with extracranial VA dissection may pose a diagnostic challenge. As illustrated in Case 2, seemingly unremarkable MRA findings led to the false assumption that the patient had sustained an atherothrombotic infarction, resulting in diagnostic delay. An extracranial VA dissection may not be as rare in the East Asian population as has been previously thought.<sup>[3]</sup> Ideally, a cervical MRA may be obtained simultaneously with the brain MRA for the initial radiological evaluation of patients with CI.

Isolated PICA dissections have been associated with hemorrhage more often than ischemia.<sup>[10]</sup> However, recent studies have indicated that PICA dissection as a cause of ischemia may not be as rare as previously thought.<sup>[11]</sup> In this study, PICA dissection was the cause of CI in 3 of the 14 patients (21%). In all 3 patients, the dissection involved the orifice of the PICA. There appears to be little



**Figure 1:** A brain computed tomography of a 54-year-old man presenting with left-sided hemianopsia revealed a subcortical hemorrhage (a). A diffusion-weighted magnetic resonance imaging showed an area of a high-intensity signal in the left cerebellar hemisphere (b). The left posterior inferior cerebellar artery was not depicted on the brain magnetic resonance angiography (c). Computed tomography angiography of the neck showed a tapered occlusion of the left vertebral artery inside the transverse foramen (d, white arrowheads). A contrast-enhanced axial image at the C5 level showed a double-lumen sign (e, black arrow)



**Figure 2:** A diffusion-weighted magnetic resonance image revealed an area containing a high-intensity signal in the left cerebellar hemisphere (a) The depiction of the right posterior inferior cerebellar artery was poor on the brain magnetic resonance angiography (b). Computed tomography angiography revealed a pearl-string lesion at the orifice of the right posterior inferior cerebellar artery (c, black circle). A repeat computed tomography angiography showed improvement in the stenosis of the posterior inferior cerebellar artery distal to the dissection (d, black circle)

demographic or prognostic differences between the patients with intracranial VA dissection and those with PICA dissection [Table 3]; however, statistical comparison was not performed due to the small sample size. While delay in identifying AD occurred in one of the three patients with PICA dissection, no such delay occurred in the 7 patients with intracranial VA dissection. This may be attributable to the shorter dissection length in the former. Recent advances in MRI may improve the diagnostic accuracy to detect the presence and extent of PICA dissection.<sup>[13]</sup>

This study may also be valuable given that follow-up imaging studies were performed in as many as 86% of patients with AD-related CI [Table 3]. Progression of AD in the acute phase (i.e., the progression within 14 days of onset) was observed in 2 of the 14 patients (14%), which was compatible with current literature.<sup>[14,15]</sup> While anticoagulants were required in patients with an extracranial VA dissection to prevent a recurrent embolic stroke, patients exhibiting an intracranial VA or PICA dissection tended to be treated with antiplatelets. The degree and/or extent of AD remained stable in the subacute to chronic phase in all patients with follow-up.

There are several limitations to this retrospective study. First, it is important to note that a substantial proportion of patients with VA dissection sustained both a brainstem and CI: Those with a concomitant brainstem infarction were excluded because only CI was the focus of this study. This may partly explain why the AD group fared significantly better. Second, our institution is a tertiary stroke center which primarily accommodates patients with moderate to severe neurologic deficits. Therefore, patients with mild deficits may have visited local clinics and have been

**Table 4: Comparison of in-hospital course between arterial dissection and nonarterial dissection**

	AD (n=14), n (%)	Non-AD (n=35), n (%)	P
Diagnostic delay by physicians in establishing the diagnosis of cerebellar infarction	2 (14)	9 (26)	0.47
Neurologic worsening after admission	6 (43)	10 (29)	0.50
Brain edema requiring decompressive surgery	4 (27)	7 (20)	0.71
Acute progression of ischemia	2 (13)	3 (9)	0.62
Favorable outcomes at discharge (mRS ≤2)	11 (79)	15 (43)	0.03*
Mean hospital stay (days)	41.0±19.2	40.4±31.2	0.95

\*Statistically significant. AD – Arterial dissection; mRS – Modified Rankin Scale

underrepresented in this study. Because of this possibility, the frequency of AD may have been disproportionately high. Finally, improvement in MRI technology occurred even during the 7-year study period. The patient with a PICA dissection that was not detected by the initial MRA (Case 11) was treated in 2008. With the current 3.0 T MRA, it is probable that the case may not have been missed if the patient had presented today.

### Conclusions

AD was responsible for as many as 30% of CI in this study. Patients with AD were significantly younger with a male preponderance than those without AD. Moreover, the AD patients were more likely to experience acute pain at onset. The presence of pain at onset may be a useful clinical

symptom to identify patients with AD-related CI. While intracranial VA dissection was the most common location of AD, physicians should be aware of the possibility of either extracranial VA or PICA dissection in patients with CI, particularly when the initial brain MRA findings are inconclusive.

#### Financial support and sponsorship

Nil.

#### Conflicts of interest

There are no conflicts of interest.

#### References

- Edlow JA, Newman-Toker DE, Savitz SI. Diagnosis and initial management of cerebellar infarction. *Lancet Neurol* 2008;7:951-64.
- Debette S, Compter A, Labeyrie MA, Uyttenboogaart M, Metso TM, Majersik JJ, *et al.* Epidemiology, pathophysiology, diagnosis, and management of intracranial artery dissection. *Lancet Neurol* 2015;14:640-54.
- Kobayashi H, Morishita T, Ogata T, Matsumoto J, Okawa M, Higashi T, *et al.* Extracranial and intracranial vertebral artery dissections: A comparison of clinical findings. *J Neurol Sci* 2016;362:244-50.
- Ramphul N, Geary U. Caveats in the management and diagnosis of cerebellar infarct and vertebral artery dissection. *Emerg Med J* 2009;26:303-4.
- Masuda Y, Tei H, Shimizu S, Uchiyama S. Factors associated with the misdiagnosis of cerebellar infarction. *J Stroke Cerebrovasc Dis* 2013;22:1125-30.
- Sangha N, Albright KC, Peng H, Vahidy F, Boehme A, Chen Z, *et al.* Misdiagnosis of cerebellar infarctions. *Can J Neurol Sci* 2014;41:568-71.
- Maruyama H, Nagoya H, Kato Y, Deguchi I, Fukuoka T, Ohe Y, *et al.* Spontaneous cervicocephalic arterial dissection with headache and neck pain as the only symptom. *J Headache Pain* 2012;13:247-53.
- Inamasu J, Nakamura Y, Saito R, Kuroshima Y, Mayanagi K, Ichikizaki K, *et al.* Endovascular treatment of ruptured vertebral artery dissection in the acute stage. *Cerebrovasc Dis* 2003;16:306-8.
- Mizutani T. Natural course of intracranial arterial dissections. *J Neurosurg* 2011;114:1037-44.
- Matsumoto J, Ogata T, Abe H, Higashi T, Takano K, Inoue T. Do characteristics of dissection differ between the posterior inferior cerebellar artery and the vertebral artery? *J Stroke Cerebrovasc Dis* 2014;23:2857-61.
- Kobayashi J, Ohara T, Shiozawa M, Minematsu K, Nagatsuka K, Toyoda K. Isolated posterior inferior cerebellar artery dissection as a cause of ischemic stroke: Clinical features and prognosis. *Cerebrovasc Dis* 2015;40:215-21.
- Nussbaum ES, Defillo A, Zelensky A, Stoller R, Nussbaum L. Dissecting peripheral superior cerebellar artery aneurysms: Report of two cases and review of the literature. *Surg Neurol Int* 2011;2:69.
- Ishitsuka K, Sakaki Y, Sakai S, Uwatoko T, Aibe H, Ago T, *et al.* Diagnosis and follow-up of posterior inferior cerebellar artery dissection complicated with ischemic stroke assisted by T1-VISTA: A report of two cases. *BMC Neurol* 2016;16:121.
- Mori M, Wakugawa Y, Yasaka M, Yasumori K, Nagata S, Okada Y. Neurological deterioration within 30 days of ischemic stroke with spontaneous cervicocranial artery dissection. *Rinsho Shinkeigaku* 2014;54:1-9.
- Hassan AE, Jadhav V, Zacharatos H, Chaudhry SA, Rodriguez GJ, Mohammad YM, *et al.* Determinants of neurologic deterioration and stroke-free survival after spontaneous cervicocranial dissections: A multicenter study. *J Stroke Cerebrovasc Dis* 2013;22:389-96.