

# An institutional experience of 26 patients with Moyamoya disease: A study from Northwest India

Trilochan Srivastava, Raghavendra Bakki Sannegowda, R. S Mittal<sup>1</sup>, R. S Jain, Shankar Tejwani<sup>2</sup>, Rahul Jain

Departments of Neurology, <sup>1</sup>Neurosurgery and <sup>2</sup>Radiology, Sawai Man Singh Medical College Hospital, Jaipur, Rajasthan, India

## Abstract

**Aim:** Moyamoya disease (MMD) is a slowly progressive bilateral stenocclusive process of the distal internal carotid and proximal portions of the anterior and middle cerebral arteries and the formation of an abnormal vascular network at the base of the brain. The purpose of this retrospective study was to identify clinical features, salient features, radiological features and yield of diagnostic cerebral angiography in MMD. **Materials and Methods:** We analyzed the records of 26 patients with MMD evaluated and treated at our institute from August 2010 until March 2013. Diagnosis of MMD was made on the basis of features of angiographic findings. Cerebral angiography showed typically fine network of vessels at the base of the brain with puff of smoke appearance suggestive of MMD. CT angiography (CTA) was done in 25 (96.15%) patients where as Digital subtraction angiography (DSA) was done in 18 (69.23%) patients. **Results:** Out of the 26 patients 13 were in the pediatric age group and 13 were adults. At presentation 14 patients had infarcts and 10 patients had hemorrhages. Among the hemorrhagic group 20% had isolated intracerebral hemorrhage (ICH), 50% patients had ICH with intraventricular extension (IVE) and 30% patients had primary intraventricular hemorrhage (PIVH). 50% of the patients had involvement of the posterior circulation. **Conclusion:** Posterior circulation involvement is frequent in MMD. Though parenchymal bleed with/without intraventricular extension is the usual presentation of hemorrhagic MMD, isolated intraventricular hemorrhage could also be the mode of presentation.

## Key Words

Aneurysm, cerebral angiography, Moyamoya disease, primary intraventricular hemorrhage

## For correspondence:

Dr. Raghavendra Bakki Sannegowda, Plot no.256/C, Sector-3, Chitrakoot, Vaishali Nagar, Jaipur - 302 021, Rajasthan, India. E-mail: padayappa4u@gmail.com

*Ann Indian Acad Neurol* 2014;17:182-6

## Introduction

Moyamoya disease (MMD) is a vasoocclusive disease characterized by abnormal vasculature at the base of the brain.<sup>[1]</sup> MMD is characterized by stenosis or occlusion observed at the terminal portions (supraclinoid) of the internal carotid artery (ICA) and the proximal middle cerebral and anterior cerebral arteries.<sup>[1,2]</sup> These findings are present bilaterally and called 'definite moyamoya'. Unilateral cases are termed as 'probable moyamoya'.<sup>[3]</sup> Highest incidence of MMD occurs during the 1<sup>st</sup> decade of life, most commonly presenting as transient ischemic attacks (TIA) or ischemic strokes; whereas, intracranial hemorrhage is more common in adults.<sup>[1,4]</sup>

Etiology is unknown, but number of mediators of the neovascular response like fibroblast growth factor (FGF), transforming growth factor (TGF beta 1), and prostaglandins have been proposed.<sup>[5,6]</sup> Possible role of viral infection with Epstein-Barr virus has also been suggested.<sup>[7]</sup> Suzuki and Takaku described six stages of MMD by cerebral angiography.<sup>[8]</sup> Moyamoya network may be seen at different sites and named accordingly. Ethmoidal moyamoya refers to the network formed at the frontal base of the brain with branches from ophthalmic artery. Posterior basal moyamoya refers to the formation of moyamoya network by the branches of posterior cerebral artery and vault moyamoya is due to extra- and intracranial transdural leptomeningeal collaterals between pial vessels and external carotid artery branches.<sup>[1,2]</sup>

A number of procedures have been devised to create collateralization on the brain surface like superficial temporal-middle cerebral artery (ST-MCA) bypass and encephaloduro-arterio-synangiosis (EDAS).<sup>[1]</sup> Ambekar *et al.*,<sup>[9]</sup> did intraoperative assessment of STA-MCA bypass patency using near-infrared indocyanine green video angiography (ICGA) and found it as an effective technique to assess bypass patency during cerebrovascular surgery. They also concluded that

### Access this article online

#### Quick Response Code:



#### Website:

www.annalsofian.org

#### DOI:

10.4103/0972-2327.132623

routine use of ICGA in cerebral bypass surgery improves graft patency and minimizes complications due to graft occlusion.

**Materials and Methods**

This is a retrospective study of 26 patients diagnosed with MMD, admitted at our institute from August 2010–March 2013. All the patients underwent brain imaging in the form of computed tomography (CT), magnetic resonance imaging (MRI), followed by cerebral angiography (CT angiography (CTA)/digital subtraction angiography (DSA)) to confirm the diagnosis. Diagnosis was made on the basis of features of angiographic findings studied by the visualization of both the carotid and vertebrobasilar circulation. All patients had a negative vasculitis workup. Work-up for hepatitis B and C were negative. None of the patients died during hospital stay and most of the patients were discharged in stable condition with conservative treatment. One patient who presented to us with coma remained in vegetative state 2 months after the discharge. Out of the 26 patients, 20 (76.92%) were females and six (23.08%) were males (ratio F:M = 3.3:1). Patients were aged from 5 to 50 years (mean age, 19.96%). Thirteen (50%) were pediatric (0-18 years) and 13 (50%) were adults.

**Results**

Eighteen patients (69.23%) presented with hemiparesis, two patients presented with TIAs, four patients with headache, one patient with seizure only, and one presented with coma. Fifteen (57.69%) patients had infarcts on brain imaging. One patient with TIA had normal imaging of the brain and one patient with seizure had developmental venous anomaly (DVA). Ten (38.46%) patients had intracranial hemorrhage. Out of 26 patients, four (15.38%) patients presented with recurrent stroke. Out of 13 children, all of them (100%) had ischemic episodes. Out of 13 adults, 10 (76.92%) had hemorrhage and three (23.07%) had infarcts. One pediatric patient with recurrent stroke had startle myoclonus. Salient features of this study have been depicted in Table 1. Clinical features, CT, and MRI findings are given in Table 2.

MMD was diagnosed by CT/MRI followed by cerebral angiography. CTA was done in 25 (96.15%) patients; whereas DSA was done in 18 (69.23%) patients. Disease was bilateral in 22 (84.62%) patients hence definite moyamoya; whereas, disease was unilateral in four (15.38%) patients (probable moyamoya). Thirteen (50%) patients had posterior circulation involvement. One of the patient had proximal MCA aneurysm and one had DVA. Out of 10 patients with intracranial hemorrhage, two (20%) had isolated intracerebral hemorrhage (ICH), five (50%) patients had ICH with intraventricular extension (IVE), and three (30%) patients had primary intraventricular hemorrhage (PIVH). DSA findings have been detailed including staging in Table 3.

**Illustrative cases**

**Case 2:** A 45-year-old female presented with sudden onset left hemiparesis and headache. Imaging revealed ICH with IVE and DSA showed bilateral MMD [Figure 1].

**Table 1: Depicting salient features of our study**

Salient features	No. of patients = %
Males	06 (23.8)
Females	20 (76.92)
Age<14 yrs	10 (38.46)
Age>14 yrs	16 (61.54)
Hemiparesis	18 (69.23)
Transient ischemic attacks only	02 (7.69)
Coma	01 (3.85)
Others= headache	04 (15.38)
Infarcts	14 (53.84)
Haemorrhage	10 (38.46)
Intraventricular extension (Secondary intraventricular haemorrhage)	05 (19.23)
Primary intraventricular haemorrhage (PIVH)	03 (11.54)
Associated with aneurysm	01 (3.85)
CT angio done	25 (96.15)
Digital subtraction angiography (DSA) done	18 (69.23)
Unilateral	04 (15.38)
Bilateral	22 (84.62)
Posterior circulation	13 (50)

**Table 2: Depicting clinical features, CT and MRI findings of patients with moyamoya disease**

Age (yrs)/sex	Clinical deficits	Ct/mri (hgge/infarct)	Special features
17/M	H/P	I	
45/M	H/P	H	ICH/IVE
12/F	H/P	I	
25/F	Headache	H	PIVH
35/F	Headache	H	Rt Proximal MCA aneurysm
35/F	Headache	H	PIVH
30/F	H/P	H	ICH/IVE
09/F	H/P	I	
07/M	TIAs only	-	
27/F	Headache	I	
50/F	H/P	H	PIVH
23/F	Headache	H	ICH
07/M	Rec stroke-startle myoclonus	I	
12/M	H/P	I	
05/F	H/P	I	
30/F	H/P	H	ICH/IVE
40/F	COMA	H	ICH/IVE
05/F	H/P	I	
35/F	TIAs only	I	
16/F	Rec Stroke	I	
12/F	Rec Stroke	I	
33/F	H/P	H	ICH/IVE
08/M	Rec Stroke	I	
11/M	H/P	I	
35/M	H/P	I	
12/F	SEIZURES	-	DVA

H/P = Hemiparesis, CT = Computed Tomography, MRI = Magnetic Resonance Imaging, H= Haemorrhage, I = Infarct, ICH = Intracerebral hemorrhage, IVE = Intraventricular extension, PIVH = Primary intraventricular hemorrhage, DVA = Developmental Venous Anomaly

**Table 3: Depicting angiographic features with staging in patient with moyamoya disease**

ICA Stenosis	MCA Stenosis	PCA Stenosis	Collaterals	Side	Aneurysm	Suzuki Stage
+	+	+	B+E	B/L	-	III
+	-	+	B+E	B/L	-	IV
+	+	+	B+E	B/L	-	IV
+	+	+	B+E	B/L	-	III
+	-	-	B+E	U/L	+	III
+	-	+	B+E	B/L	-	IV
+	-	+	B+E	B/L	-	IV
+	+	-	B	U/L	-	II
+	+	-	B+E/V	B/L	-	III
+	+	-	E	B/L	-	V
+	+	-	B+E/V	B/L	-	IV
+	+	+	B+E	B/L	-	III
+	+	+	B+E	B/L	-	III
+	+	+	B	U/L	-	IV
+	+	-	B/E	B/L	-	III
+	-	-	V	U/L	-	IV
+	+	-	E/V	B/L	-	III
+	+	-	E/V	B/L	-	IV
+	+	-	B/E	B/L	-	III
+	+	+	B/V	B/L	-	IV
+	+	+	B/E	B/L	-	III
+	+	-	B/E/V	B/L	-	III
+	+	+	E	B/L	-	II
+	+	-	B/E	B/L	-	II
+	+	-	B	B/L	-	IV
+	+	+	B	B/L	-	II

ICA = Internal carotid artery, MCA = Middle cerebral artery, PCA = Posterior cerebral artery, + = Present, - = Absent, B = Basal, E = Ethmoidal, V = Vault, U/L = Unilateral, B/L = Bilateral

**Case 4:** A 25-year-old female presented with headache with no focal deficits on examination. Imaging showed PIVH and DSA revealed bilateral MMD with posterior circulation affection [Figure 2].

**Case 5:** A 35-year-old female presented with sudden onset right hemiparesis. Imaging showed ICH and DSA revealed unilateral left sided MMD with associated right proximal MCA aneurysm [Figure 3].

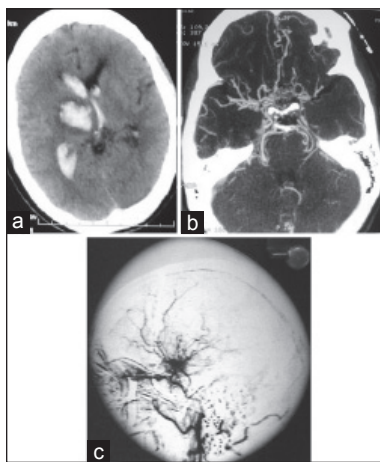
**Case 12:** A 23-year-old female presented with headache with no neurological deficits on examination. Imaging showed ICH, whereas DSA revealed bilateral MMD with extensive collaterals [Figure 4].

**Case 18:** A 5-year-old female child with recurrent stroke had infarcts on MRI. DSA revealed bilateral MMD with basal collaterals [Figure 5].

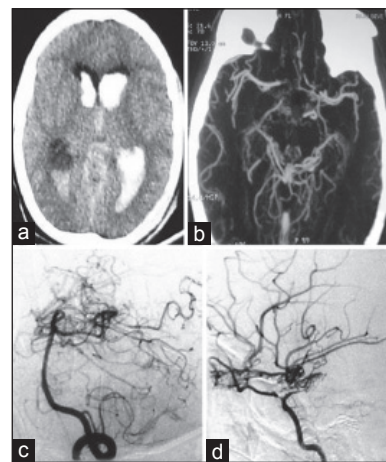
**Discussion**

MMD was first described by Suzuki and Takaku and the term means a ‘waving puff of smoke’ and was used to describe the abnormal vasculature at the base of the brain.<sup>[8]</sup> MMD is also called as “spontaneous occlusion of the circle of Willis”.<sup>[4]</sup> MMD is characterized by narrowing, starting at the distal internal carotid and proximal anterior, and middle cerebral arteries.<sup>[1,2,8]</sup> Though the etiology is unknown, genetic mode of inheritance is considered. The frequency of familial occurrence has been estimated to be 616%.<sup>[10]</sup> There was no familial occurrence in our group of patients.

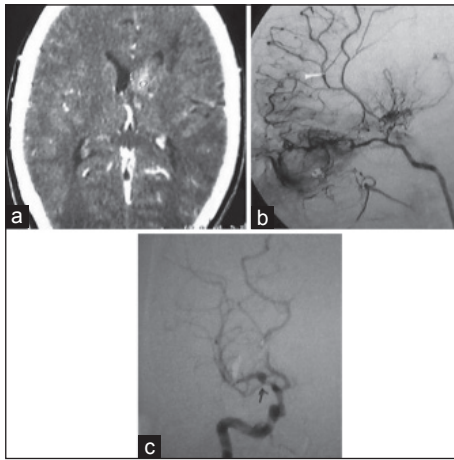
DSA is considered as the procedure of choice for confirming the diagnosis of MMD,<sup>[8]</sup> and conventional angiography is considered as the official criteria for diagnosis of MMD by the Japanese Ministry of Health and Welfare.<sup>[11]</sup> Brain perfusion scintigraphy is an important adjunct in evaluation of patients



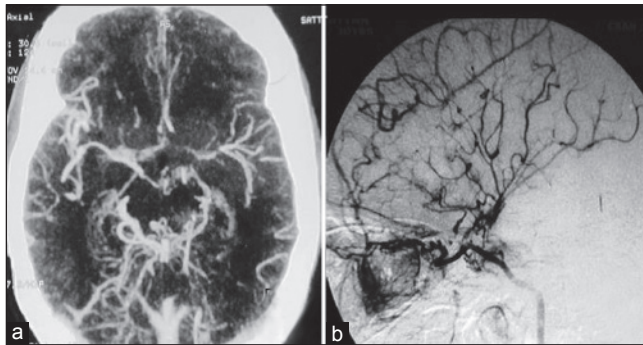
**Figure 1:** (a) Computed tomography (CT) head showing ICH with IVE. (b) CT angiography showing bilateral prominent basal collaterals. (c) DSA (right ICA injection) showing puff of smoke appearance at distal ICA and proximal MCA. ICH = Intracerebral hemorrhage, IVE = intraventricular extension, DSA = digital subtraction angiography, ICA = internal carotid artery, MCA = middle cerebral artery



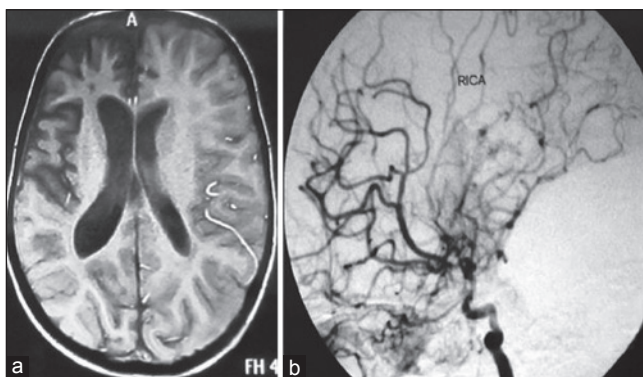
**Figure 2:** (a) CT head showing pivh. (b) CT angiography showing bilateral posterior basal moyamoya. (c) DSA (left vertebral artery injection) lateral view showing moyamoya network at posterior cerebral artery. (d) DSA (right ica injection) revealing supraclinoid ICA stenosis with classical “puff”. DSA = digital subtraction angiography, ICA = internal carotid artery, pivh = primary intraventricular hemorrhage



**Figure 3:** (a) CT head showing left basal ganglia bleed. (b) DSA lateral view (left ica injection) showing network of vessels at frontal base suggestive of ethmoidal moyamoya. (c) dsa (right ICA injection) showing associated right asymptomatic proximal mca aneurysm (arrow). DSA = digital subtraction angiography, ICA = internal carotid artery, MCA = middle cerebral artery



**Figure 4:** (a) CT angio showing bilateral proximal mca and aca narrowing with extensive posterior basal (collaterals) moyamoya. (b) DSA lateral view (left ICA injection) showing leptomeningeal collaterals suggestive of vault moyamoya along with basal as well as ethmoidal moyamoya. DSA = digital subtraction angiography, ICA = internal carotid artery, MCA = middle cerebral artery, ACA = anterior cerebral artery)



**Figure 5:** (a) Magnetic Resonance Imaging (MRI) brain axial section showing right mca territory infarcts. (b) DSA lateral view (right ica injection) showing supraclinoid ica, proximal MCA severe narrowing with classical “puff” suggestive of basal collaterals (moyamoya). DSA = digital subtraction angiography, ICA = internal carotid artery, MCA = middle cerebral artery)

with MMD.<sup>[12]</sup> Kashyap *et al.*,<sup>[12]</sup> in their study on 17 patients of MMD found that Tc99m-ethylcysteinate dimer (ECD) brain single-photon emission computed tomography (SPECT) showed perfusion defects that were more extensive compared to those detected on MR. Initially it was believed that MMD was restricted to Japan, but later cases were reported from all over the world especially from China and Korea.<sup>[5]</sup> There are only few studies from India, though there are case reports describing individual cases. Largest Indian study was done by Garg *et al.*,<sup>[13]</sup> with 44 patients in 10 years, including both childhood and adult onset MMD where 26 patients were adults. Singhi *et al.*,<sup>[14]</sup> retrospectively analyzed data of 23 patients, diagnosed with pediatric MMD in 16 years. Chinchure *et al.*,<sup>[15]</sup> analyzed case records of 11 patients which includes only adult onset MMD. Our study is the second largest study in India with 26 patients in the span of just 3 years including both adult and childhood onset MMD. There was equal distribution of adult and children in our study (13 patients each). Four of our patients had unilateral involvement suggestive of “probable” MMD.

The welfare ministry for MMD in 1979 described four major types of MMD; hemorrhagic type, infarction type, TIA type, and epileptic type.<sup>[16]</sup> In a study done by Singhi *et al.*,<sup>[14]</sup> all patients had cerebral ischemic events. In our study; 10 patients had hemorrhagic type, 14 had infarction type, one had TIA type, and one of them was epileptic type. Though two of them had clinically only TIAs, imaging was suggestive of infarction type in one.

While most of the studies concentrate on the anterior circulation, studies pertaining to posterior circulation are very few.<sup>[17]</sup> Mugikura *et al.*,<sup>[18]</sup> reported high prevalence of clinical strokes and infarctions in patients diagnosed before 4 years of age, associated with advanced steno-occlusive lesions of the posterior cerebral artery (PCA). Indian study by Chinchure *et al.*,<sup>[15]</sup> showed three out of 11 patients with posterior circulation involvement. Jayakumar *et al.*,<sup>[17]</sup> in their series reported that 90% of the patients had involvement of posterior circulation. Garg *et al.*,<sup>[13]</sup> did not mention about the involvement of posterior circulation in their series of 44 patients. Posterior circulation was involved in 26.1% patients in a study done by Singhi *et al.*,<sup>[14]</sup> In our series, 50% of the patients had involvement of the posterior circulation. Though posterior circulation is frequently involved in MMD as evident by angiography, ischemic events of the posterior circulation are not frequent, as the posterior circulation acts as collateral pathway for the diseased anterior circulation till the later stage.<sup>[14]</sup>

Series from Garg *et al.*,<sup>[13]</sup> showed male predominance (68.2%); while study from Chinchure *et al.*,<sup>[15]</sup> also showed slight male predominance (six out of 11 patients). But in our study, there was a female predominance with a ratio of 3.3:1. Garg *et al.*,<sup>[13]</sup> reported intracranial hemorrhage in 96% of adults and 27.8% of children with MMD. Six out of 11 adults presented with intracranial hemorrhage in a study done by Chinchure *et al.*<sup>[15]</sup> In our series, 38.46% of the patients had intracranial hemorrhage.

MMD can present with PIVH. In our series, three (30%) out of 10 MMD with hemorrhagic presentation had PIVH, while incidence of PIVH was high in the study done by Garg *et al.*,<sup>[13]</sup> (46.7%).

Association of aneurysm has been mentioned with MMD. Garg *et al.*,<sup>[13]</sup> reported 11 out of 44 patients with aneurysms (nine in the circle of Willis and two in the periphery), while only one case of aneurysm was found in our study as well as the study done by Chinchure *et al.*<sup>[15]</sup> However, one of our pediatric MMD patient with seizure alone had DVA.

Lack of follow-up and revascularization procedures was the major limitation of our study. However, most of our patients were treated conservatively and few underwent revascularization procedures at other centers. But now, as more studies demonstrate the efficacy of revascularization procedures most patients are given the option of surgery in our institute too, and in future revascularization procedures may be of promising value.

To conclude, MMD is no more an uncommon disease entity and one should consider and rule out MMD in all patients with stroke, particularly in children and young adults. Though earlier studies in India had shown male preponderance, our data from northwest region showed female preponderance. Apart from ischemic or hemorrhagic strokes, MMD can present clinically as TIA and seizure alone and should be evaluated extensively. Posterior circulation involvement is frequent in MMD. Though parenchymal bleed with/without IVE is the usual presentation of hemorrhagic MMD, isolated intraventricular hemorrhage could also be the mode of presentation.

## References

- Gosalakkal JA. Moyamoya disease: A review. *Neurol India* 2002;50:6-10.
- Houkin K, Yoshimoto T, Kurodo S, Ishikawa T, Takahashi A, Abe H. Angiographic analysis of moyamoya disease-how does moyamoya disease progress? *Neurol Med Chir*1996;36:783-7.
- Natori Y, Ikezaki K, Matsushima T, Fukui M. 'Angiographic moyamoya' its definition, classification and therapy. *Clin Neurol Neurosurg* 1997;99 Suppl 2: S168-72.
- Fukui M. Current state of study on moyamoya disease in Japan. *Surg Neurol* 1997;47:138-43.
- Yonekawa Y, Ogata N, Kaku Y, Taub E, Imhof HG. Moyamoya disease in Europe, past and present status. *Clin Neurol Neurosurg* 1997;99 Suppl 2:S58-60.
- Malek AM, Connors S, Robertson RL, Folkman J, Scott RM. Elevation of cerebrospinal fluid levels of basic fibroblast growth factor in moyamoya and central system disorders. *Pediatr Neurosurg* 1997;27:182-9.
- Tanigawara T, Yamada H, Sakai N, Andoh T, Deguchi K, Iwamura M. Studies on cytomegalovirus and Epstein-Barr virus infection in moyamoya disease. *Clin Neurol Neurosurg* 1997;99 Suppl 2:S225-8.
- Suzuki J, Takaku A. Cerebrovascular moyamoya disease. Disease showing abnormal net-like vessels in base of the brain. *Arch Neurol* 1969;20:288-99.
- Ambekar S, Babu A, Pandey P, Devi IB. Intraoperative assessment of STA-MCA bypass patency using near-infrared indocyanine green video-angiography: A preliminary study. *Neurol India* 2012;60:604-7.
- Houkin K, Aoki T, Takahashi A, Abe H. Diagnosis of moyamoya disease with magnetic resonance angiography. *Stroke* 1994;5:2159-64.
- Nishimoto A, Ueda K, Homma Y. Follow-up study on outcome of the occlusion of the circle of Willis. In: Goth S, . Proceedings of the Research Committee on Spontaneous Occlusion of the Circle of Willis. Tokyo: Ministry of Health and Welfare; 1983:p 66-74
- Kashyap R, Mittal BR, Sunil HV, Bhattacharya A, Singh B, Mukherjee KK, *et al.* Tc99m-ECD brain SPECT in patients with Moyamoya disease: A reflection of cerebral perfusion status at tissue level in the disease process. *Indian J Nucl Med* 2011;26:82-5.
- Garg AK, Suri A, Sharma BS. Ten-year experience of 44 patients with moyamoya disease from a single institution. *J Clin Neurosci* 2010;17:460-3.
- Singhi P, Choudhary A, Khandewal N. Pediatric Moyamoya Disease: Clinical Profile, Literature Review and Sixteen Year Experience from a Tertiary Care Teaching Institute. *Indian J Pediatr* 2013 Mar 24. [Epub ahead of print].
- Chinchure SD, Pendharkar HS, Gupta AK, Bodhey N, Harsha KJ. Adult onset moyamoya disease: Institutional experience. *Neurol India* 2011;59:733-8.
- Maki Y, Enomoto T. Moyamoya disease. *Childs Nerv Syst*1988;4:204-12.
- Jayakumar PN, Vasudev MK, Srikanth SG. Posterior circulation abnormalities in moyamoya disease: A radiological study. *Neurol India* 1999;47:112-7.
- Mugikura S, Higano S, Shirane R, Fujimura M, Shimanuki Y, Takahashi S. Posterior circulation and high prevalence of ischemic stroke among young pediatric patients with moyamoya disease: Evidence of angiography-based differences by age at diagnosis. *AJNR Am J Neuroradiol* 2011;32:192-8.

**How to cite this article:** Srivastava T, Sannegowda RB, Mittal RS, Jain RS, Tejwani S, Jain R. An institutional experience of 26 patients with Moyamoya disease: A study from Northwest India. *Ann Indian Acad Neurol* 2014;17:182-6.

**Received:** 18-07-13, **Revised:** 29-08-13, **Accepted:** 06-10-13

**Source of Support:** Nil, **Conflict of Interest:** Nil