

Papilledema or pseudopapilledema?

Case

A 6-year-old systemically healthy Caucasian boy presented with decreased vision in the left eye (OS) for 10 months. Visual acuity was 20/30 in the right eye (OD) and 20/400 OS with relative afferent pupillary defect OS. Intraocular pressures were normal in both eyes (OU). Funduscopy revealed swollen, elevated optic disc OU, with indistinct disc margin and cup/disc ratio of 0 [Fig. 1a]. Superotemporal to the disc in OS, there was subretinal hemorrhage with central subretinal fibrosis. Blood pressure and body temperature were normal.

What Is Your Next Step?

- Consult pediatric neurosurgery for assessment
- Perform lumbar puncture with opening pressure
- Order toxoplasma and toxocara serology
- Perform additional ocular diagnostic imaging with B-scan ultrasonography, optical coherence tomography (OCT), and fluorescein angiography (FA).

Findings

B-scan ultrasonography showed a small scleral canal and optic disc hyperreflectivity, suggestive of calcified optic disc drusen (ODD) OU [Fig. 1b]. FA showed early hyperfluorescence with late staining at the site of blood, suggestive of choroidal neovascular membrane (CNVM) [Fig. 1c]. OCT over the hemorrhage [Fig. 1d] revealed subretinal hyperreflective CNVM with buried drusen at the optic disc [Fig. 1e]. Brain and orbit magnetic resonance imaging (MRI)

showed no mass. These findings were consistent with CNVM arising from ODD. Intravitreal bevacizumab resulted in CNVM regression after 1 month.

Diagnosis

ODD with CNVM.

Correct Answer: D.

Discussion

Bilateral optic disc swelling can result from papilledema or pseudopapilledema. The latter is a group of optic disc abnormalities including hypoplastic, dysplastic, or tilted optic disc, persistent hyaloid remnants, ODD, and others.^[1] True disc swelling warrants immediate MRI evaluation for intracranial mass or venous sinus thrombosis. ODD are acellular deposits believed to result from a tight scleral canal that leads to axoplasmic stasis.^[2] ODD are present in 0.4%–2.4% of eyes on autopsy and 14.6% by OCT.^[1] ODD are bilateral in 75%, increase in size and calcification with age, and can cause visual field defects.^[2] CNVM is a fairly common complication, found on OCT in 24 of 98 pediatric eyes (24.5%) with ODD. The CNVM typically responds to intravitreal anti-vascular endothelial growth factor medication.^[3]

Declaration of patient consent

The authors certify that they have obtained all appropriate patient consent forms. In the form the patient(s) has/have given his/her/their consent for his/her/their images and other clinical information to be reported in the journal. The patients understand that their names and initials will not be published and due efforts will be made to conceal their identity, but anonymity cannot be guaranteed.

Financial support and sponsorship

Nil.

Conflicts of interest

There are no conflicts of interest.

References

- Gema R, Aki K, Victoria de J, Noelia O, Francisco Jose MN. Optical coherence tomography to differentiate papilledema from pseudopapilledema. *Curr Neurol Neurosci Rep* 2017;17:74-87.
- Claudia AH, Flemming S, Heinrich W. Optic disk drusen. *Surv Ophthalmol* 2002;47:515-32.
- Jared ED, Sharon FF, Mays A El-D. The incidence of neovascular membranes and visual field defects from optic nerve head drusen in children. *J AAPOS* 2016;20:44-8.

Lin Liu, Michael D Yu, Carol L Shields

Oncology Service, Wills Eye Hospital, Thomas Jefferson University, 840 Walnut Street, 14th Floor, Philadelphia, PA 19107, USA

Correspondence to: Dr. Carol L Shields,

Ocular Oncology Service, 840 Walnut Street, Suite 1440, Philadelphia, PA 19107, USA.

E-mail: carolshields@gmail.com

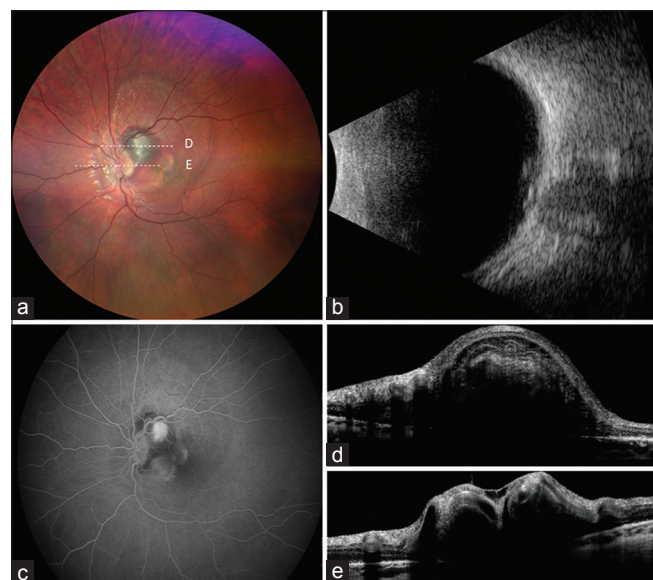


Figure 1: (a) Fundus photograph demonstrating subretinal hemorrhage with subretinal fibrosis superotemporal to the disc OS. The lesion is further visualized using (b) B-scan ultrasonography, (c) FA, and (d and e) OCT (horizontal orientation)

Access this article online

Quick Response Code:



Website:

www.ijjo.in

DOI:

10.4103/ijjo.IJO_2013_18

This is an open access journal, and articles are distributed under the terms of the Creative Commons Attribution-NonCommercial-ShareAlike 4.0 License, which allows others to remix, tweak, and build upon the work non-commercially, as long as appropriate credit is given and the new creations are licensed under the identical terms.

For reprints contact: reprints@medknow.com

Cite this article as: Liu L, Yu MD, Shields CL. Papilledema or pseudopapilledema? *Indian J Ophthalmol* 2019;67:449.