

Received: 2017.02.26
Accepted: 2017.03.28
Published: 2017.06.30

ISSN 1941-5923
© Am J Case Rep, 2017; 18: 733-738
DOI: 10.12659/AJCR.904045

Algorithm for Bosniak 2F Cyst in Kidney Donation

Authors' Contribution:
Study Design A
Data Collection B
Statistical Analysis C
Data Interpretation D
Manuscript Preparation E
Literature Search F
Funds Collection G

AEF 1 **Robert C. Minnee**
AE 1 **Hendrikus J.A.N. Kimenai**
E 2 **Paul Verhagen**
E 3 **Jan Von den Thüsen**
E 4 **Roy S. Dwarkasing**
AE 5 **Jacqueline van der Wetering**
AE 1 **Jan N. IJzermans**

1 Department of Surgery, Division of Hepato-Pancreato-Biliary and Transplant Surgery, Erasmus Medical Center, University Medical Center Rotterdam, Rotterdam, The Netherlands
2 Department of Urology, Erasmus Medical Center, University Medical Center Rotterdam, Rotterdam, The Netherlands
3 Department of Pathology, Erasmus Medical Center, University Medical Center Rotterdam, Rotterdam, The Netherlands
4 Department of Radiology, Erasmus Medical Center, University Medical Center Rotterdam, Rotterdam, The Netherlands
5 Department of Nephrology, Erasmus Medical Center, University Medical Center Rotterdam, Rotterdam, The Netherlands

Corresponding Author: Robert C. Minnee, e-mail: r.minnee@erasmusmc.nl
Conflict of interest: None declared

Patient: Female, 54
Final Diagnosis: Multilocular cystic renal cell carcinoma with clear cells
Symptoms: None
Medication: —
Clinical Procedure: Hand-assisted retroperitoneal donor nephrectomy
Specialty: Transplantology

Objective: Unusual setting of medical care
Background: The Bosniak system for radiological classification of renal cysts offers a tool for surgical decision-making in clinical practice. Although 95% of Bosniak 2F cysts remain benign, a consensus on the management of Bosniak 2F cysts in kidney donation has not been developed.
Case Report: We present a donor with a Bosniak 2F cyst, who successfully donated her kidney after partial resection of the Bosniak 2F cyst. Postoperative pathology examination of the partially resected cystic wall revealed a multilocular cystic renal cell carcinoma. Postoperative pathology examination revealed a multilocular cystic renal cell carcinoma. Resection of the Bosniak 2F cyst provides 2 advantages: the recipient receives a new donor kidney and will be free of dialysis, and the donor will be free of surveillance.
Conclusions: We present a practical guideline for kidney donors with Bosniak 2F cysts, balancing the risk of tumor transmission or recurrence with the benefit associated with organ transplantation, without compromising the risk of the donor and recipient. Further evaluation of this algorithm by longer follow-up and more studies is needed to prove its safety.

MeSH Keywords: Kidney Neoplasms • Kidney Transplantation • Living Donors

Full-text PDF: <http://www.amjcaserep.com/abstract/index/idArt/904045>



2099



1



4



32



Background

A renal cyst is a common finding by CT scan. The incidence in patients 50 years of age and over is between 17% and 39% [1–3]. Mean diameter of cysts is 2 cm and many cysts increase in size over time, with growth being higher in patients below as compared to above 50 years of age, with a mean of 3.9 versus 1.8 mm per year, respectively [3,4]. The Bosniak system for radiological classification of renal cysts offers a tool for surgical decision-making in clinical practice [5]. The Bosniak 2F category is composed of lesions that are thought most likely to be benign, but still must be proven to be stable over serial interval imaging. The radiology definition of Bosniak 2F cysts implies the presence of multiple hairline-thin or minimally, smoothly thick septa and/or walls that may contain perceived enhancement and/or coarse calcification but no measurable enhancement. Also included are uniformly high attenuation lesions greater than 3 cm that may be totally intrarenal [6]. Up to 5% of these cysts progress to malignancy; therefore, follow-up imaging is recommended, although there is no consensus recommendation on the appropriate interval of follow-up [7]. The American College of Radiology recommends imaging surveillance with CT or MRI without and with IV contrast material at 6 and 12 months after diagnosis and yearly thereafter for a total of 5 years [8].

Most malignant lesions in Bosniak 2F lesions are cystic clear-cell renal cell carcinomas. Histology of the remaining lesions is reported to include papillary renal cell carcinoma and a heterogeneous group of other malignancies [9]. Approximately a one-quarter of clear-cell renal cell carcinomas are classified as multilocular cystic renal cell carcinoma, a subtype of clear-cell renal cell carcinoma [9]. This entity is regarded as a ‘malignancy of low malignant potential’. Development of metastases has never been reported for this histology, irrespective of size [10,11]. No examples of metastatic progression of a Bosniak 2F lesion on surveillance has been reported in the literature.

The Dutch and UK guidelines for living kidney donation provide no information on the management of kidney donors with a Bosniak 2F cyst [12,13]. The recent Kidney Disease Improving Global Outcomes (KDIGO) clinical guideline 2015 for living kidney donation stated that use of live donor kidneys with Bosniak 2 or higher renal cysts should proceed only after careful assessment for the presence of solid components, septations, and calcifications on the preoperative CT scan (or MRI) to avoid accidental transplantation of a kidney with cystic renal cell carcinoma. Bosniak 2 or higher cysts should not be left in the donor [14]. However, a step-by-step practical guideline is missing. Here, we describe a donor with a Bosniak 2F cyst and propose a practical guideline.

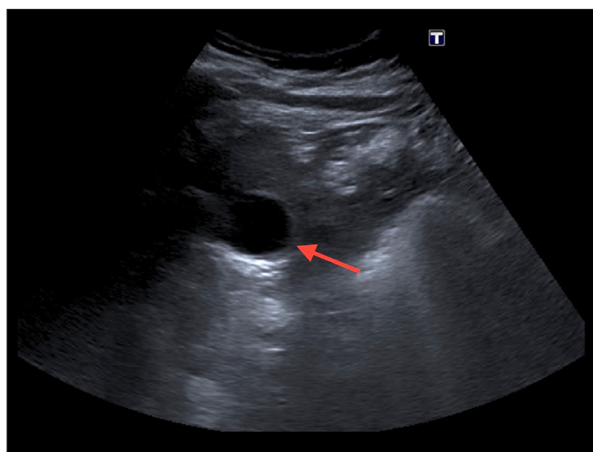


Figure 1. Ultrasound image of Bosniak 2F cyst in left kidney (red arrow).

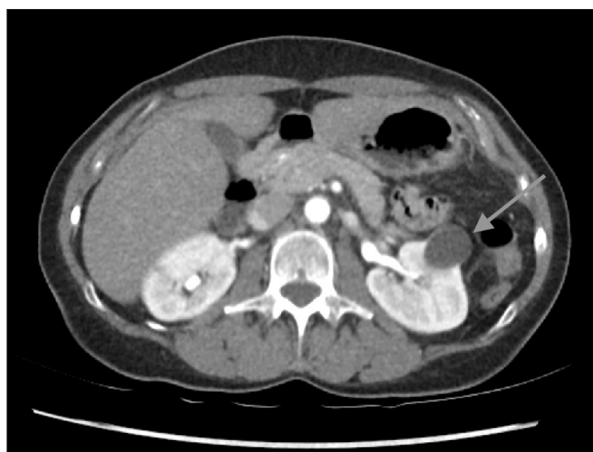

Figure 2. Bosniak 2F cyst in left kidney (red arrow).

Case Report

A 54-year-old woman was evaluated for possible kidney donation to her husband. She had a medical history of Caesarean section and 2 episodes of acute pyelonephritis successfully treated with antibiotics. Analyzing the cause of recurrent pyelonephritis ultrasound imaging was performed and a renal cyst was diagnosed on the left kidney, classified as a Bosniak 2F. She had follow-up examination using ultrasonography for 20 months, showing no change in the lesion characteristics (Figure 1). As she was willing to donate a kidney to her husband, she was included in the screening program for living kidney donation. She had previously been in good health and her medication consisted of hydrochlorothiazide for mild hypertension. She reported no allergies. Physical examination was normal with a BMI of 26. Blood and urine examination revealed no abnormalities. CT scan (Figure 2) showed normal-sized kidneys of 11 cm with 1 renal artery, 1 renal vein, and 1 ureter on the right side and 2 renal arteries, 1 renal vein and 1 ureter on the left side. On the left kidney, a cyst was visualized

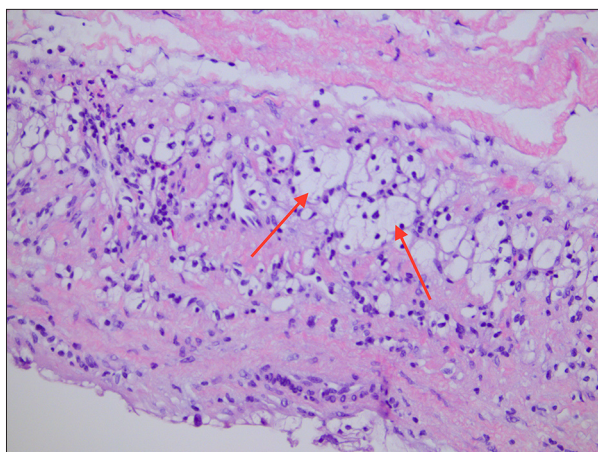


Figure 3. Hematoxylin and eosin stain: Cystic wall revealing multilocular cystic renal cell carcinoma with clear cells and low-grade nuclear features (red arrows).

measuring 3.1×2.6 cm. It was classified as a Bosniak 2F cyst due to size and smoothly thick septa. During the renal transplant multidisciplinary meeting, it was recommended to select the left kidney for donation and remove the Bosniak 2F cyst before transplantation.

The patient proceeded to donate the left kidney to her husband. Left hand-assisted retroperitoneal donor nephrectomy was performed without perioperative complications. On the bench, an end-to-side anastomosis was made between the accessory upper polar renal artery and main renal artery with Prolene 7.0. Cyst fluids were aspirated and cytological examination showed no abnormalities. Because of the necessity to apply anticoagulation postoperatively due to the arterial reconstruction, it was decided peri-operatively to refrain from radical resection of the cyst, balancing the risk of leaving a small part of the cystic wall, 1 cm in diameter, against the risk of bleeding, as the recipient would be treated with anticoagulant therapy due to arterial reconstruction. The cyst roof containing a smoothly thickened part was removed for pathology,

while electric coagulation was applied on the base of the cyst, showing no abnormalities on inspection.

The recipient was diagnosed with renal insufficiency of unknown origin and a biopsy showed glomerulosclerosis. Except for depression and secondary hyperthyroidism treated with alfacalcidol, the patient had no comorbidities. He underwent a preemptive kidney transplant through a standard right Gibson's incision. The renal vein was anastomosed to the external iliac vein, and the renal artery to the external iliac artery. The method used to establish urinary continuity was extravesical ureterocystostomy and closure of the abdominal wall in layers. The ureteroneocystostomy was stented with an externally draining 8 French catheter for 9 days. Our standard protocol after arterial reconstruction consisted of a standard dose of 12 000 U unfractionated heparin intravenously daily during the first 5 days, without PTT monitoring. The postoperative course of the patient was unremarkable.

Postoperative pathology examination of the partially resected cystic wall revealed a multilocular cystic renal cell carcinoma with clear cells and low-grade nuclear features (Figure 3). Both the donor and recipient postoperative periods were uneventful. Six months after the kidney transplantation, an MRI showed no anomalies. Urological surveillance for the recipient is planned once a year.

After the definitive pathology report, we analyzed our case comprehensively. The next time, we would perform a partial nephrectomy without the possibility of leaving positive margins behind. To facilitate other hospitals struggling with similar cases, we developed a practical step-by-step guideline for living kidney donors with a Bosniak 2F cyst (Figure 4, Table 1).

Practical guideline

All donors suitable for donation, including donors with unilateral Bosniak 2F cyst present at CT scan, are evaluated by a

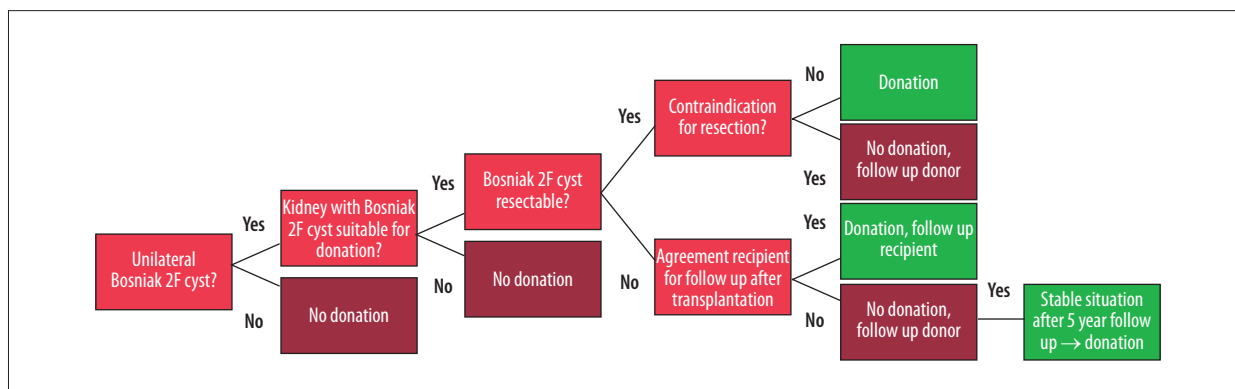


Figure 4. Bosniak 2F cyst flowchart.

Table 1. Outpatient clinic Bosniak 2F checklist.

Situation	Discuss with donor and/or recipient
Resectable Bosniak 2F Cyst	Due to partial nephrectomy may be slightly lesser kidney function
	Possibility of increased bleeding risks
Non-resectable Bosniak 2F Cyst	Option of donation without resection cyst and follow up recipient
	Option of partial resection of the lesion and coagulation remaining wall and follow up recipient
	Unknown biological behavior Bosniak 2F cyst under immune suppression after donation
	Patient survival benefit of kidney transplantation with Bosniak 2F versus dialysis
Recipient's refusal of kidney transplant with non-resectable Bosniak 2F cyst	Risk of malignant tendency
	Follow up donor for 5 years
	Unchanged Bosniak classification after 5 years → donation
	Insecure 5-year period for donor with several scans

multidisciplinary transplantation team, consisting of a transplant nephrologist, transplant surgeon, urologist, and anesthesiologist. Absolute contraindications for donation, such as diabetes mellitus, polycystic kidneys, and bilateral nephrolithiasis, are the same for donors without a unilateral Bosniak 2F cyst [13]. Relative contraindication for donation is the presence of a Bosniak 2F cyst in the kidney with significantly higher function as determined by nuclear renal scan.

In case of a Bosniak 2F cyst, the transplant team should address the resectability of the lesion and the collateral damage to a well-functioning kidney. Large cysts near the renal pelvis or blood vessels make it difficult to remove, and after partial nephrectomy, function should be sufficient for transplantation. Non-resectable Bosniak 2F cysts, however, can be donated to the recipient without any other donors, after agreement and written informed consent of the recipient to follow-up after kidney transplantation. These recipients should have regular imaging surveillance with CT or MRI. If the Bosniak 2F cyst is resectable, contraindications for resection should be balanced. Clinical indications for anticoagulation, such as mitral valve insufficiency, are relative contraindications to resection and transplantation. Hemorrhage risk should be discussed with the recipient. When we remove the Bosniak 2F cyst on the back-table, we precisely describe the location and aspect and ensure complete removal of all macroscopic cyst tissues, which are then sent to the pathology lab. In contrast to the case presented, we would not recommend deroofting and fulguration of the base of a Bosniak 2F cyst with the possibility of leaving positive margins behind. Closure of the parenchymal defect will be performed with running sutures and hemostatic agents if necessary.

If the recipient does not agree to transplant a kidney with non-resectable Bosniak 2F cyst, the donor will be followed for 5 years. When the situation is unchanged without progression to a higher-category lesion, kidney donation can be done safely.

Bosniak cyst 3/4 or renal cell carcinoma are contraindications for donation and partial nephrectomy is recommended. Total nephrectomy and donation may be offered in exceptional cases where rescue therapy is indicated or donor and recipient are well informed and decide to accept the risk of recurrence. Some case series describe donors with incidental renal masses in living and deceased kidney donors, which were resected with clear margins on the back table and where no local recurrence or metastasis were observed in long-term follow-up [15–17].

Discussion

At present, a consensus on the management of Bosniak 2F cysts in kidney donation has not been developed. Therefore, an algorithm for kidney donors with Bosniak 2F cysts was made. This practical approach to the assessment of Bosniak 2F cyst in kidney donation is of importance in minimizing the risk of the donor and recipient and optimizing the donor pool.

The Bosniak classification system is the most widely accepted method for identifying cystic renal lesions that are potentially malignant [5]. Because Bosniak 2F renal cysts are infrequently malignant, the American College of Radiology recommends imaging surveillance with CT or MRI without and with intravenous contrast material at 6 and 12 months after diagnosis and yearly thereafter for a total of 5 years [8]. The purpose of imaging surveillance is to identify Bosniak 2F renal cysts that

progress to higher-category lesions, because upward reclassification is associated with an increased malignancy rate. The malignancy rate of upward reclassification ranges from 5% to 16% and typically occurs in the first 2 years after diagnosis [18]. However, the malignancies in Bosniak 2F cysts are in general of low grade and stage and prognosis is excellent. In addition, malignancies in complex renal cysts have no tendency to metastasize [9,10], although biological behavior of Bosniak 2F cysts on immune suppression is unknown.

To remove the Bosniak 2F cyst, partial nephrectomy surgery is the preferred method, as it is the standard treatment for renal masses smaller than 4 cm in diameter [19,20]. The most frequent complications after partial nephrectomy are postoperative hemorrhage and urinary fistula. The incidence of hemorrhage varies between 4% and 8% [21,22], and the risk of postoperative hemorrhage is higher in patients with larger tumor size and central tumor location with deeper infiltration [23,24]. Other risk factors for hemorrhagic complications are high American Society of Anesthesiologists (ASA) scores and smoking [25]. The incidence of urinary fistula after partial nephrectomy has ranged from 1% to 17.4% [26]. However, more recent studies report urinary leakage rates between 0.6% and 3% [27,28]. Risk factors include hilar tumor location, tumor size, blood loss, and need for pelvic/lyceal repair [26,29–31].

Additionally, some centers have even transplanted donor kidneys after a partial nephrectomy due to a small renal cell carcinoma. Penn et al. reported that when a donor renal carcinoma <2 cm was completely removed, no recurrences in 14 recipients were observed after 55–57 months follow-up [32]. It was stated that donor kidneys with renal tumors <2 cm, that have been completely removed, could be used for transplantation,

with a low risk of local recurrence or metastasis. However, strict follow-up is advocated. Lugo-Baruqui et al. identified 4 donors with renal cell carcinomas [16]. All donor kidneys underwent partial nephrectomy of the tumor during the back-table preparation. After a median follow-up of 36 months, all patients remained tumor-free [32].

In consideration of the shortage of donor organs, it is important to balance the risk of tumor transmission or recurrence with the benefit associated with organ transplantation. Resection of Bosniak 2F cysts provides 2 advantages: the recipient receives a new donor kidney and will be free of dialysis, and the donor will be free of surveillance. In high-volume centers with surgical expertise, Bosniak 2F cysts should be a feasible option in expanding donor criteria. The recommendations presented here are largely based on expert experience and pragmatism and are supported where possible by published evidence. Nonetheless, a practical guideline in managing Bosniak 2F cyst in kidney donation will help healthcare professionals in daily practice.

Conclusions

We present a practical guideline for kidney donors with Bosniak 2F cysts, providing a tool to increase the donor pool without compromising the risk of the donor and recipient. Further evaluation of this algorithm by longer follow-up and more studies is needed to prove its safety.

Conflicts of interest

None.

References:

1. Tada S, Yamagishi J, Kobayashi H et al: The incidence of simple renal cyst by computed tomography. *Clin Radiol*, 1983; 34(4): 437–39
2. Ravine D, Gibson RN, Donlan J, Sheffield LJ: An ultrasound renal cyst prevalence survey: Specificity data for inherited renal cystic diseases. *Am J Kidney Dis*, 1993; 22(6): 803–7
3. Terada N, Ichioka K, Matsuta Y et al: The natural history of simple renal cysts. *J Urol*, 2002; 167(1): 21–23
4. Chang CC, Kuo JY, Chan WL et al: Prevalence and clinical characteristics of simple renal cyst. *J Chin Med Assoc*, 2007; 70(11): 486–91
5. Bosniak MA: The current radiological approach to renal cysts. *Radiology*, 1986; 158(1): 1–10
6. Israel GM, Bosniak MA: An update of the Bosniak renal cyst classification system. *Urology*, 2005; 66(3): 484–88
7. Whelan TF: Guidelines on the management of renal cyst disease. *Can Urol Assoc J*, 2010; 4(2): 98–99
8. Berland LL, Silverman SG, Gore RM et al: Managing incidental findings on abdominal CT: White paper of the ACR incidental findings committee. *J Am Coll Radiol*, 2010; 7(10): 754–73
9. Reese AC, Johnson PT, Gorin MA et al: Pathological characteristics and radiographic correlates of complex renal cysts. *Urol Oncol*, 2014; 32(7): 1010–16
10. Suzigan S, Lopez-Beltran A, Montironi R et al: Multilocular cystic renal cell carcinoma: A report of 45 cases of a kidney tumor of low malignant potential. *Am J Clin Pathol*, 2006; 125(2): 217–22
11. Eccher A, Boschiero L, Delahunt B et al: *De novo* renal neoplasia after kidney transplantation according to new 2016 WHO Classification of renal tumors. *Ann Transplant*, 2016; 21: 745–54
12. Dutch guideline evaluation of potential living kidney donors. 2008
13. UK Guidelines for Living Donor Kidney 3e edition. 2011
14. KDIGO Clinical Practice Guideline On The Evaluation And Follow-Up Care Of Living Kidney Donors. 2015
15. Buell JF, Hanaway MJ, Thomas M et al: Donor kidneys with small renal cell cancers: Can they be transplanted? *Transplant Proc*, 2005; 37(2): 581–82
16. Lugo-Baruqui JA, Guerra G, Chen L et al: Living donor renal transplantation with incidental renal cell carcinoma from donor allograft. *Transpl Int*, 2015; 28(9): 1126–30
17. Musquera M, Perez M, Peri L et al: Kidneys from donors with incidental renal tumors: Should they be considered acceptable option for transplantation? *Transplantation*, 2013; 95(9): 1129–33
18. Smith AD, Allen BC, Sanyal R et al: Outcomes and complications related to the management of Bosniak cystic renal lesions. *Am J Roentgenol*, 2015; 204(5): W550–56

19. Delakas D, Karyotis I, Daskalopoulos G et al: Nephron-sparing surgery for localized renal cell carcinoma with a normal contralateral kidney: A European three-center experience. *Urology*, 2002; 60(6): 998–1002
20. Uzzo RG, Novick AC: Nephron sparing surgery for renal tumors: Indications, techniques and outcomes. *J Urol*, 2001; 166(1): 6–18
21. Campbell SC, Novick AC, Beldegrun A et al: Guideline for management of the clinical T1 renal mass. *J Urol*, 2009; 182(4): 1271–79
22. Jung S, Min GE, Chung BI, Jeon SH: Risk factors for postoperative hemorrhage after partial nephrectomy. *Korean J Urol*, 2014; 55(1): 17–22
23. Ramani AP, Desai MM, Steinberg AP et al: Complications of laparoscopic partial nephrectomy in 200 cases. *J Urol*, 2005; 173(1): 42–47
24. Van Poppel H, Bamelis B, Oyen R, Baert L: Partial nephrectomy for renal cell carcinoma can achieve long-term tumor control. *J Urol*, 1998; 160(3 Pt 1): 674–78
25. Richstone L, Montag S, Ost MC et al: Predictors of hemorrhage after laparoscopic partial nephrectomy. *Urology*, 2011; 77(1): 88–91
26. Potretzke AM, Knight BA, Zargar H et al: Urinary fistula after robot-assisted partial nephrectomy: A multicentre analysis of 1 791 patients. *BJU Int*, 2016; 117(1): 131–37
27. Thompson RH, Leibovich BC, Lohse CM et al: Complications of contemporary open nephron sparing surgery: A single institution experience. *J Urol*, 2005; 174(3): 855–58
28. Zargar H, Khalifeh A, Autorino R et al: Urine leak in minimally invasive partial nephrectomy: Analysis of risk factors and role of intraoperative ureteral catheterization. *Int Braz J Urol*, 2014; 40(6): 763–71
29. Kundu SD, Thompson RH, Kallingal GJ et al: Urinary fistulae after partial nephrectomy. *BJU Int*, 2010; 106(7): 1042–44
30. Wheat JC, Roberts WW, Hollenbeck BK et al: Complications of laparoscopic partial nephrectomy. *Urol Oncol*, 2013; 31(1): 57–62
31. Tomaszewski JJ, Smaldone MC, Cung B et al: Internal validation of the renal pelvic score: A novel marker of renal pelvic anatomy that predicts urine leak after partial nephrectomy. *Urology*, 2014; 84(2): 351–57
32. Penn I: Primary kidney tumors before and after renal transplantation. *Transplantation*, 1995; 59(4): 480–85