



# Surgical Management of Meningiomas Involving the Torcula, Transverse Sinus, and Jugular Bulb: A Technical Note and Review of the Literature

Robert G. Power<sup>1</sup> Fred C. Lam<sup>1</sup> Anthony C. Whitton<sup>2,3</sup> Sunjay Sharma<sup>1</sup> Ekkehard M. Kasper<sup>1,3</sup> 

<sup>1</sup>Division of Neurosurgery, DeGroot School of Medicine, McMaster University, Hamilton, Ontario, Canada

<sup>2</sup>Department of Radiation Oncology, Juravinski Cancer Centre, Hamilton, Ontario, Canada

<sup>3</sup>Juravinski Cancer Centre, Hamilton Health Sciences Corporation, Hamilton, Ontario, Canada

**Address for correspondence** Ekkehard M. Kasper, MD, DPhil, FAANS, FACS, FRCS(C), Division of Neurosurgery, Faculty of Health Sciences, McMaster University, 237 Barton Street East, Hamilton, ON L8S 4K1, Canada (e-mail: kaspere@mcmaster.ca).

J Neurol Surg Rep 2023;84:e92–e102.

## Abstract

Meningiomas that invade the confluens sinuum are rare and require extensive preoperative planning. Here, we describe the surgical and radio-oncological management of an aggressive large occipital meningioma invading the superior sagittal sinus, torcula, right and left transverse sinus down to the level of the jugular bulb in a 21-year-old female patient. Details of the surgical approach are presented to highlight the planned staged resection of this tumor at the level of the torcula to initially debulk the lesion while preserving venous outflow through the patent's sinus. Once the tumor fully occluded the confluens, a second-stage en bloc resection ensued. Postsurgical adjuvant radiation therapy was delivered via fractionated external beam therapy which has provided local control of the tumor since. This case is being discussed in the context of the pertinent literature to demonstrate the highly complex interdisciplinary and staged management of partially intravascular meningiomas involving the major venous sinuses.

## Keywords

- ▶ meningioma
- ▶ torcula
- ▶ intravascular meningioma
- ▶ venous sinus
- ▶ tumor

## Introduction

Meningiomas invading the torcular herophili are surgically very challenging lesions which require multidisciplinary adjuvant management to ensure the best long-term result. Given the high risk from tumors or their treatment in this locale, we agree with Brotchi, who commented that “the one good thing about torcular meningiomas is their rarity.”<sup>1</sup> However, when treatment of these formidable lesions is indicated, a diligent approach is mandatory.

Not many surgeons have extensive experience with torcular lesions, which may be somewhat surprising, given that

meningiomas, which are thought to arise from arachnoid cap cells, are the most common nonmalignant tumors of the central nervous system (CNS).<sup>2</sup> According to the Central Brain Tumor Registry of the United States (CBTRUS), they account for 37.6% of all tumors and 53.3% of nonmalignant tumors of the CNS.<sup>3</sup> Meningiomas invading or occluding the torcula herophili however are rare entities, accounting for only approximately 1% of all intracranial meningiomas.<sup>4</sup>

A genetic predisposition to developing meningiomas has been demonstrated with several conditions, mainly neurofibromatosis type 2 (NF2) and schwannomatosis.<sup>5</sup> Those with multiple endocrine neoplasia type 1 may also carry

received  
February 21, 2021  
accepted after revision  
January 26, 2023

DOI <https://doi.org/10.1055/s-0043-1772201>.  
ISSN 2193-6358.

© 2023. The Author(s).

This is an open access article published by Thieme under the terms of the Creative Commons Attribution-NonDerivative-NonCommercial-License, permitting copying and reproduction so long as the original work is given appropriate credit. Contents may not be used for commercial purposes, or adapted, remixed, transformed or built upon. (<https://creativecommons.org/licenses/by-nc-nd/4.0/>)

Georg Thieme Verlag KG, Rüdigerstraße 14, 70469 Stuttgart, Germany

an increased incidence of harboring a meningioma, though it is believed to be less than that of NF2.<sup>2,6,7</sup> As of now, no particular predisposition has been described for the development of torcular meningiomas.

With a peak incidence in the seventh decade of life, meningiomas have an adjusted annual incidence of 4.5 per 100,000 individuals. There also appears to be a higher prevalence in African Americans and in females with a gender ratio of 2.27:1. This predilection for females is thought to be in part due to receptor expression for endogenous sex hormones which correlates with an even higher F:M incidence of 3:1 during childbearing years.<sup>3,8</sup> Meningiomas are furthermore subcategorized into Grades I to III according to a system devised by the World Health Organization (WHO) which is based on specific histopathological characteristics.<sup>9</sup> Approximately 80% of all meningiomas WHO I behave as benign, slow-growing entities.<sup>2</sup> The extent of resection and recurrence rates are most frequently reported based on the Simpson grading system.<sup>10</sup> While gross total resection can be curative for certain WHO I meningiomas, some tumors recur despite seemingly complete Simpson Grade 1 resection. Of those that are categorized as WHO II or WHO III lesions, many follow a more aggressive course with postsurgical recurrence rates approaching 50 and 90%, respectively, at 5 years.<sup>11</sup> In general, however, complete resection including the area of infiltrated dura and bone is associated with significantly improved progression-free survival (PFS) and local control, regardless of WHO grade.<sup>12,13</sup>

The majority of cranial meningiomas occur at the convexity of the periorbital and frontoparietal regions, along the skull base, and along cranial sutures.<sup>14,15</sup> In some instances, parasagittal meningiomas can invade one major dural venous sinus, but simultaneous invasion of multiple venous sinuses at the level of the torcula is exceedingly rare, and such tumors present a unique challenge for treating clinicians.<sup>16</sup> Review of the pertinent literature demonstrates heterogeneity in the application of surgical techniques and adjuvant therapies aimed at the management of such torcular meningiomas specifically.

Here, we describe our experience with a particularly challenging case requiring an interdisciplinary and staged approach for the treatment of a young female with an aggressive meningioma involving the parasagittal occipital area from where it invaded the torcula and transverse sinus (TS) reaching as far as the jugular bulb. The surgical and adjuvant management of this case is being discussed in the context of the pertinent literature to demonstrate the complex management of such highly complicated intravascular meningiomas requiring ligation and en bloc resection of involved major venous sinuses.

## Case Illustration

### History and Presentation

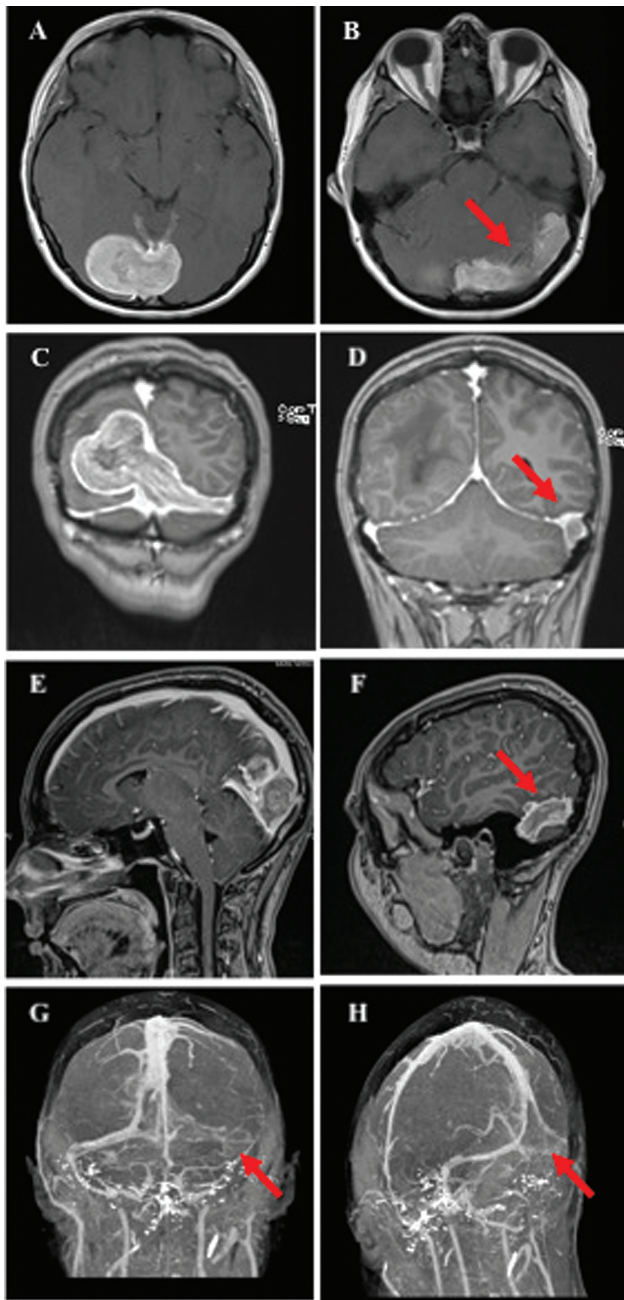
A 21-year-old female college student presented to her ophthalmologist after experiencing 5 months of intermittent blurry vision, left-sided visual field disturbances, and progressive headaches. Her medical history was unremarkable,

and she had no other active medical issues. Home medications included over the counter nonsteroidal anti-inflammatory drugs and oral contraception only. Physical examination revealed bilateral papilledema and notable left homonymous hemianopsia, but the patient had no other focal neurological deficits. The patient was referred to neurosurgery for further assessment and imaging was arranged. Initial standard magnetic resonance imaging (MRI) with gadolinium demonstrated a multilobulated approximately 3 cm × 5 cm × 4 cm measuring and avidly enhancing mass of the right parafalcine occipital area with transdural extension into the torcula, left TS and sigmoid sinus reaching as far laterally as the proximal internal jugular vein (►Fig. 1). Presurgical conventional cerebral digital subtraction angiography (DSA) demonstrated an extra-axially supplied mass abutting the torcula with predominant feeders arising from the posterior meningeal artery as well as some parasitized pial vessels from the posterior cerebral artery. The left TS was already completely occluded at this time, but there remained residual flow to the torcula and the right TS, although there was a high degree of stenosis at the most posterior portion of the superior sagittal sinus (SSS). Despite the presence of some early parasagittal collaterals, most of the supratentorial veins drained through the SSS that remained patent into the right TS and jugular system. There was further evidence of venous congestion/hypertension with flow diversion through the external jugular system via transosseous and scalp veins, the superficial temporal cavernous system, deep venous system, as well as the spinal muscular veins (►Fig. 2).

Given the fact that the patient was symptomatic from significant mass effect as appreciated on imaging, the team saw a clear indication for surgical intervention. Surgery was carried out in two stages. The goal of the first operation was to achieve decompression of the occipital lobe by resecting the large extra-axial portion of the mass causing the hemianopsia. This would also provide a histopathological diagnosis. A second-stage surgery was envisioned at a later time when the torcula would be completely occluded.

Image-guided microsurgery was carried out in the third-fourth prone position through a right occipital paramedian linear incision followed by a standard craniotomy that was brought to the midline. An excellent peritumoral plane could be developed, and the bulk of the lesion was removed with the exception of a 5-mm parasagittal “tumor plug” which was intentionally left attached to the SSS. Resection of the intravascular portion of this lesion was not attempted at the initial session since the confluens remained patent. Allograft duraplasty was performed, and the wound was closed in layers. Pathological analysis of the specimen revealed an atypical meningioma (WHO II) with mixed fibrous and transitional architecture and high mitotic index. Postoperatively, the patient did not show any new neurological deficits, and she had an unremarkable course in hospital prior to discharge on postoperative day 2.

MRI on day 2 after resection showed postsurgical changes only, with residual disease as expected and described earlier (►Fig. 3). The patient was subsequently presented at multidisciplinary rounds, and the decision was made to follow the



**Fig. 1** Preoperative MRI/MRV of the brain showing (A, B) T1-weighted noncontrast axial images demonstrating large, homogeneous right-sided occipital, parafalcine mass with extension into the torcula and left transverse sinus (red arrow); (C, D) coronal T1-weighted gadolinium-enhanced sequence demonstrating the mass with extension to the left sigmoid sinus (red arrow); (E, F) T1-weighted sagittal gadolinium-enhanced sequences demonstrating the midline tumor at the level of the superior sagittal sinus as well as left sigmoid sinus involvement to the level of the jugular bulb (red arrow); (G, H) MRV 3D reconstruction; coronal and oblique view demonstrating partial occlusion of the torcula, occlusion of the left transverse sinus with flow through the right transverse sinus. MRI, magnetic resonance imaging; MRV, magnetic resonance venography; 3D, three-dimensional.

patient closely with sequential imaging including repeat computed tomography venography (CTV) every 2 to 3 months. Approximately 6 months later, the patient returned urgently to our outpatient clinic after acute onset of significantly worsened headaches with recurrence of

visual disturbances. Repeat CT and MRI of the brain revealed substantial swelling of the occipital parenchyma, thought to be vasogenic in nature as well as from venous congestion. Cerebral DSA was performed the next morning which demonstrated further intravascular tumor expansion resulting in cessation of the flow which had previously been seen at the level of the distal SSS. There now was complete occlusion of the confluents at the level of the torcula. Furthermore, there was new evidence of progression of extensive venous rerouting through the anterior cortical veins into the superficial sylvian vein, via the sphenopalatine and cavernous sinus, and via the pterygoid plexus. There was significant transosseous flow at the level of the vertex along the mid-portion of the SSS with venous outflow through the scalp veins as well as venous drainage into the deep venous system via the basal veins of Rosenthal, and drainage through the occipital sinus into the foramen magnum and down the muscular venous outflow (→Fig. 4).

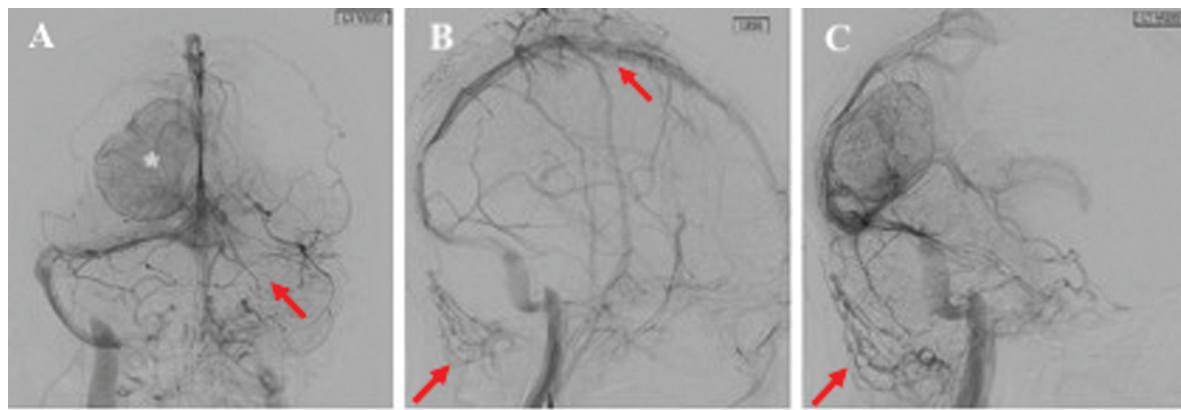
At this time, the neurosurgical team decided to urgently pursue the second stage of surgery, and the patient was taken back to the operating room the next morning. Goal of this second intervention was to undertake an aggressive en bloc surgical resection of the tumor including the torcula to remove the entire intravascular portion of the tumor as well as the extension into the TS and adjacent involved structures.

### Surgery

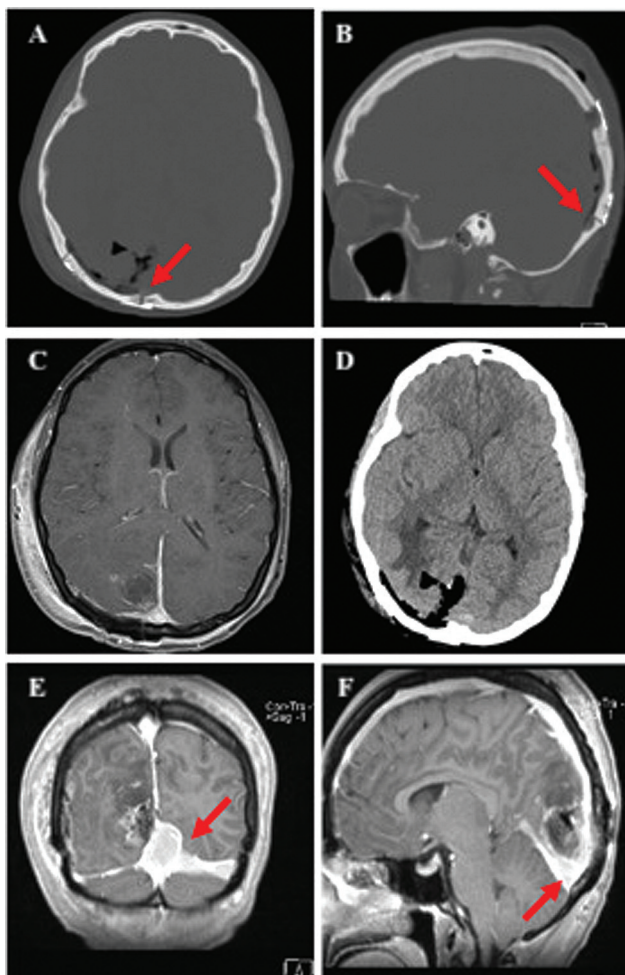
The patient was again placed in the lateral decubitus position with the head turned third-fourth prone in a Mayfield headrest, rotated 20 degrees to the left so that the occluded TS would be positioned at the apex of the surgical field. For intraoperative image guidance, presurgical CTV and post-contrast MP-RAGE (magnetization prepared rapid gradient echo) sequences had been fused which allowed us to identify the entire extent of tumor outside and inside the sinus. Using stereotactic neuronavigation, an extended “barn-door” incision was planned to incorporate the previous linear access for the right occipital craniotomy with an extension to a new left-sided supratentorial occipital and suboccipital craniotomy with the inferior margin of the bone flap running 2 cm below the nuchal line. A standard myocutaneous flap was dissected out and deflected caudally with holding sutures. The previous right osteoplastic trepanation was reopened, and new left-sided burr holes were placed both supratentorially and infratentorially to give access to the occipital lobe and also the posterior fossa to facilitate dissection of the TS.

Once the durotomy was done bilaterally and inferiorly, careful parasagittal dissection was carried out superiorly toward the point where the upper dural margin of the falx was identified as tumor free, and the SSS appeared patent by image guidance. The posterior segment of the SSS was then tied off just distal to the last remaining patent draining vein, which was achieved with a double loop of 0-silk ties and closure of the free end was further enforced with a Weck-clip.

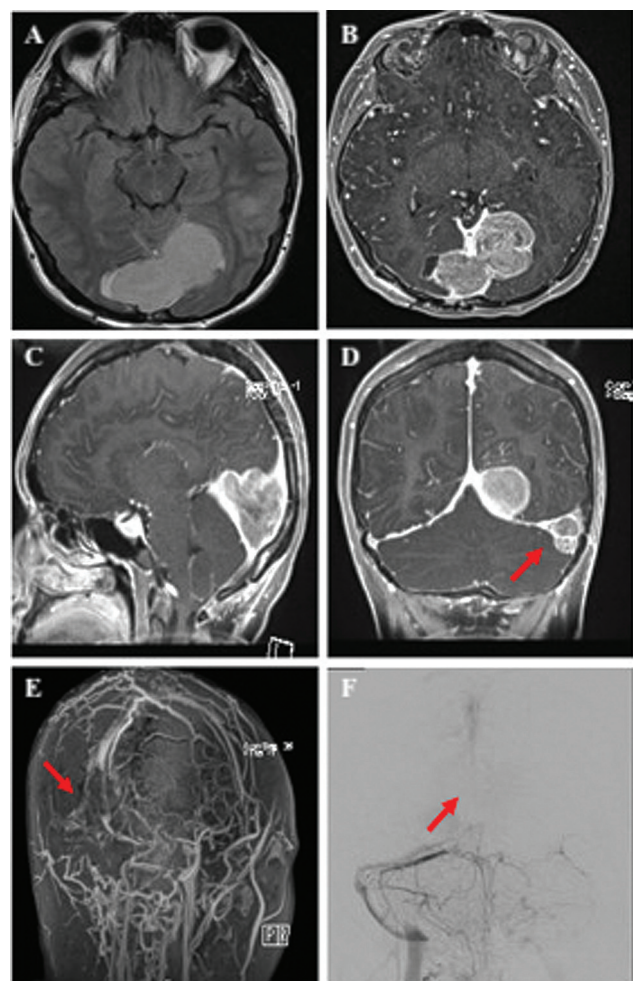
The right TS was identified and the junction where its lumen appeared patent was separated medially from the torcula by a second set of double silk ties and clips. We now



**Fig. 2** Preoperative digital subtraction cerebral angiography; (A) coronal view of a left vertebral artery injection demonstrating the right-sided parafalcine tumor (asterisk) and occlusion of the left transverse sinus (red arrow); (B) sagittal view of a left internal carotid artery injection demonstrating engorged veins of the scalp and neck musculature (red arrows); (C) sagittal view of a left vertebral artery injection showing engorged veins of the neck musculature (red arrow).



**Fig. 3** Postoperative head imaging following the initial operation showing (A, B) axial and sagittal CT bone windows illustrating placement of burr holes at the midline and partially over the superior sagittal sinus, and inferiorly partially over the transverse sinus; (C, D) axial gadolinium-enhanced MRI and noncontrast CT demonstrating excellent parenchymal decompression of the occipital lobe; (E, F) coronal and sagittal gadolinium-enhanced MRI showing the residual tumor of the torcula (red arrows). CT, computed tomography; MRI, magnetic resonance imaging.



**Fig. 4** Preoperative imaging prior to the second operation showing (A, B) axial T1-weighted MRI pre- and postcontrast demonstrating progression of the mass from the torcula causing mass effect on the surrounding occipital lobe; (C, D) gadolinium-enhanced T1-weighted images again showing the torcular mass as well as the progression of the left transverse sinus component (red arrow); (E) oblique view of an MRV 3D reconstruction showing occlusion of the torcula; (F) digital subtraction angiography of the left vertebral artery; coronal view showing complete occlusion of the torcula with evidence of venous rerouting to the right transverse sinus (red arrows). MRI, magnetic resonance imaging; MRV, magnetic resonance venography; 3D, three-dimensional.

had isolated the occluded posterior SSS and torcula as well as the left TS segment, which was internally completely plugged with tumor tissue. The torcula with the tumor left inside was now excised from the falx and resected en bloc. The posterior-lateral dissection was then continued along the left sigmoid sinus which was extended along the petrous segment just proximal to the jugular bulb. The medial TS was resected, and the lateral part of the sinus was split open horizontally (along its long axis). The intravascular tumor could then be shelled out easily resulting in clearly visible smooth endothelial lining. The walls of the empty TS were resected to the tentorial margin. The most lateral portion of the intravascular tumor of the TS was removed using microdissection techniques until we encountered venous backflow from the JB. At this point, we decided to plug the inner lumen of the JB with Gelfoam (Pfizer Inc, New York, New York, United States) and Surgicel (Johnson & Johnson, NV, Belgium), which was secured in place and augmented with fibrin sealant. Once complete hemostasis was achieved, bilateral allograft duraplasties were performed, and the epidural space of the craniectomy site was covered with gel foam before the bone flap was secured with a miniplating system. The wound was closed in a conventional, multilayered fashion.

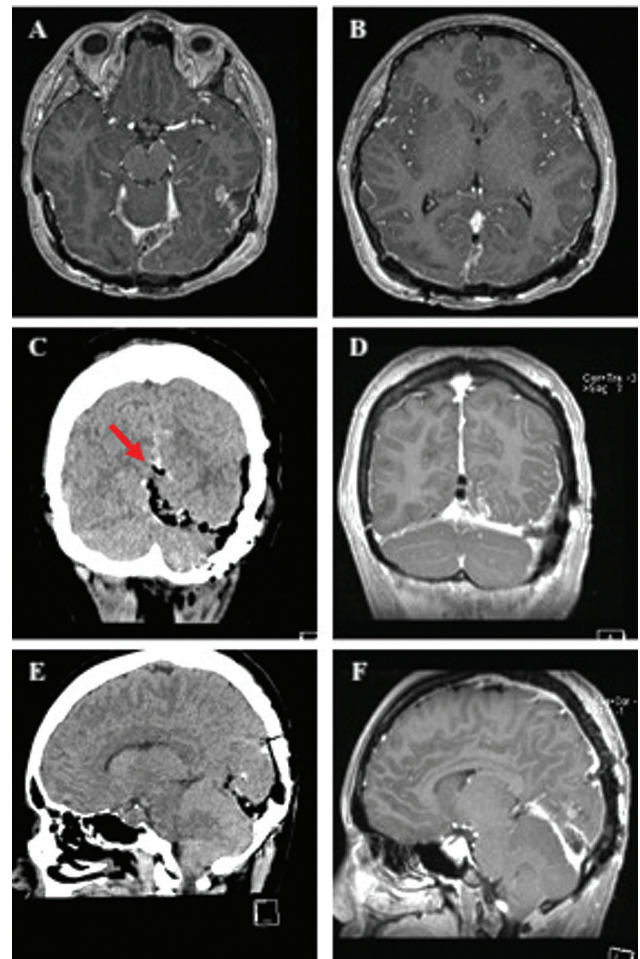
### Postoperative Course

The patient had an uncomplicated course in the hospital with no new neurological deficits and minimal headaches and could be discharged home on the third postoperative day. Her vision improved to the point that she no longer displayed any left-sided homonymous hemianopsia on confrontational testing, and she continued to only have mild intermittent blurry vision. On discharge, the patient was prescribed acetylsalicylic acid 81 mg daily to prevent extension of her JB-venous sinus thrombosis.

### Histopathology

Microscopic examination of the tissue specimen was consistent with an atypical meningioma (WHO II). In contrast to the first tumor resection, this specimen demonstrated more aggressive features with marked hypercellularity and multifocal necrosis, though no direct brain invasion was noted. There were 4 to 10 mitotic figures observed per  $\times 10$  high power field. Immunohistochemistry demonstrated cells that were largely positive epithelial membrane antigen, with negative progesterone receptor and estrogen receptor status, and with an increased Ki67 proliferation index of up to 20% in many areas. Germline testing was also conducted, though no genetic variants associated with cancer predisposition or therapeutic actionability were identified.

The patient was then seen again on postoperative day 14 in our multidisciplinary brain tumor clinic. Given the recurrent nature of this meningioma and the pathological diagnosis of an atypical WHO II tumor, our neurosurgical oncology team recommended a course of adjuvant radiation therapy to the surgical bed to cover any possible residual disease including the left transverse and sigmoid sinus, and jugular bulb (**Fig. 5**). Four weeks postoperatively, the patient received conventional three-dimensional-intensity modu-

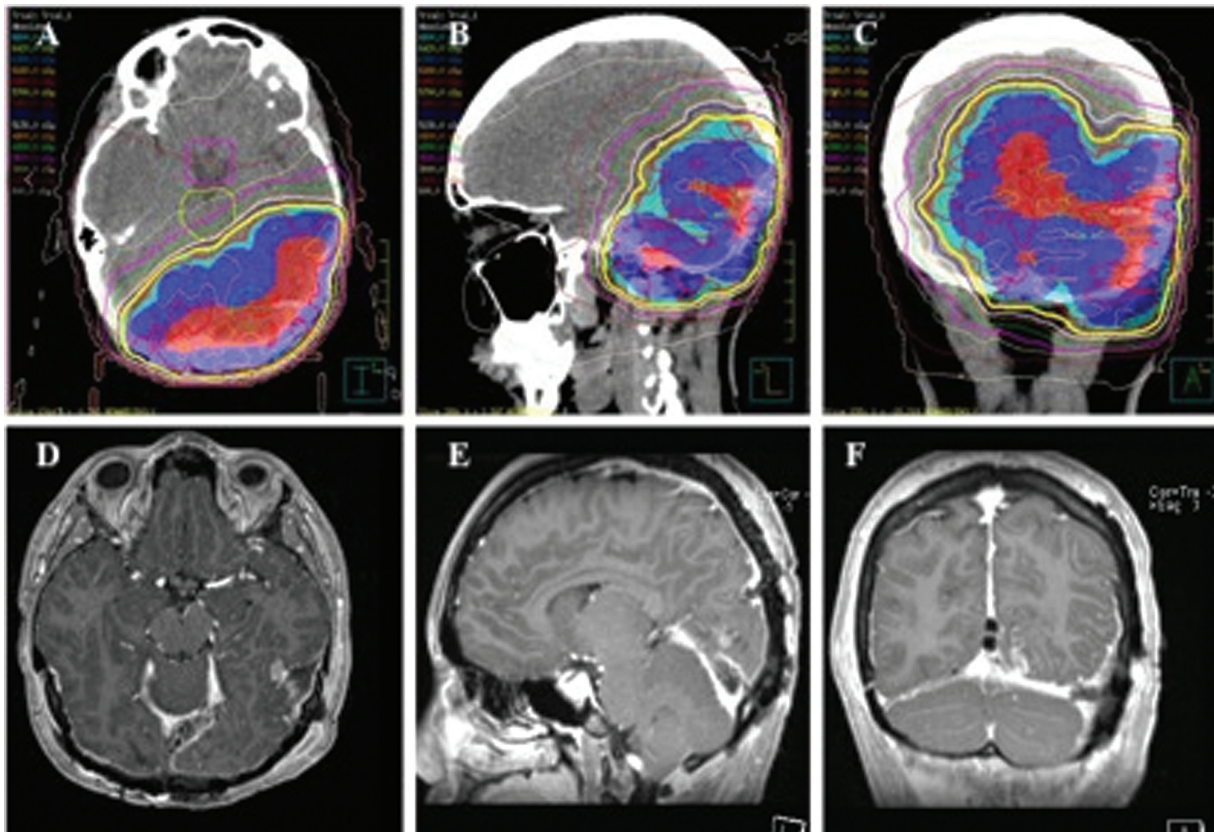


**Fig. 5** Postoperative brain images following the second operation showing (A, B) axial T1-weighted gadolinium-enhanced images demonstrating the resection of the torcula, left transverse sinus, and incorporated tumor; (C) coronal noncontrast CT demonstrating the level of superior sagittal sinus ligation which was performed using silk sutures and reinforced with a Weck clip (red arrow); (D) coronal T1-weighted gadolinium-enhanced MRI sequence showing the en bloc resection of the torcular mass; (E) sagittal noncontrast CT showing the postoperative resection cavity; (F) sagittal T1-weighted, gadolinium-enhanced image again showing the resection cavity without damage to the integrity of the straight sinus. CT, computed tomography; MRI, magnetic resonance imaging.

lated external beam radiation therapy with a cumulative dose of 60 Gray in 30 fractions, delivered in equal doses over a period of 6 weeks. Subsequent repeat MRI with gadolinium shows no recurrence in the surgical bed and a small area of stable residual disease at the left jugular bulb at 6 and 12 months (**Fig. 6**).

### Discussion

Meningiomas invading or occluding the torcula herophili are rare entities, accounting for only approximately 1% of all intracranial meningiomas.<sup>4</sup> The first attempt at surgical removal was undertaken in 1871; however, the patient succumbed in the immediate postoperative period. One of the early detailed accounts of such tumors was described by Cushing and Eisenhardt in their 1938 seminal textbook on



**Fig. 6** (A–C) Conventional 3D intensity modulated external beam radiation maps; radiation commenced 4 weeks postoperatively with a cumulative dose of 60 Gy in 30 fractions delivered in equal doses over a period of 6 weeks; (D–F) T1-weighted, gadolinium-enhanced MRI at 1-year following showing stable disease on axial, sagittal, and coronal images. MRI, magnetic resonance imaging; 3D, three-dimensional.

meningiomas.<sup>17</sup> Since then, there have been relatively few reports of the surgical techniques needed for removal of torcular meningiomas, and significant controversy still exists regarding the optimal management strategy.<sup>18,19</sup> Key surgical considerations include the timing of surgery, the optimal approach, the degree of resection that should be pursued, and whether or not ligation of associated major dural venous sinus can be safely performed. Only a handful of centers have investigated whether or not reconstruction efforts should be attempted.<sup>1,20</sup> An overview of the literature on the management of torcular meningiomas is shown in ► **Table 1**.

Consensus exists, that the extent of surgical resection should be weighed against the risk in light of the patient's life expectancy, symptomatology, and the risk of recurrence necessitating retreatment. In general, a well-accepted strategy for surgical management of meningiomas which are invading, but not occluding, major venous sinuses was originally described for parasagittal meningiomas based on a classification proposed by Sindou and Hallacq.<sup>21</sup>

Based on these observations and further studies (e.g., by Mathiesen et al<sup>22</sup>), those patients who harbor low-grade meningiomas that cause incomplete occlusion of the SSS (Sindou Types II–IV) should undergo resection of the extravascular portion of the tumor while leaving a cuff of coagulated tissue along the wall of the venous sinus.<sup>23,24</sup> Patients are then followed up postoperatively with sequential imag-

ing to monitor residual disease until progression is documented, at which point radiotherapy can be added. For more aggressive WHO II or WHO III meningiomas, surgeons should consider the eventual necessity of a more radical excision.<sup>4</sup> In the case of a completely occluded dural venous sinus (Sindou Types V and VI), ligation and resection of the occluded portion of the sinus without any attempt at sinus reconstruction may be considered.<sup>25,26</sup> However, this maneuver places the venous collateral system at risk of injury and has the potential to cause malignant swelling, edema, and hemorrhagic transformation.<sup>18,27</sup>

Debernardi et al observed that the degree of preoperative venous engorgement may be inversely correlated with postoperative edema and hemorrhage risk, serving as an indirect measure to be considered when setting surgical goals for extent of resection during the preoperative planning phase. These authors also described the presence of four distinct peritumoral venous patterns which need to be taken into account during surgical planning: (1) compensatory, dilated venous channels of the brain, (2) normal veins of the brain, (3) veins exclusively draining the tumor, and (4) veins with shared drainage of the tumor and of normal brain parenchyma.<sup>28</sup> Importantly, collateral venous flow may traverse the calvarium and surrounding muscle and soft tissue. Careful evaluation of preoperative angiography and the use of intraoperative vascular imaging and neuronavigation are imperative in designing a suitable skin incision as well as an osseus

**Table 1** Overview of the literature on the management of torcular meningiomas

Author	Article	No. of patients treated for torcular meningioma	Surgical strategy	Radiation therapy	Outcomes/complications
Barua et al <sup>41</sup>	Spontaneous peritumoral hemorrhage associated with sinus confluence meningioma: Case report ( <i>Surg Neurol</i> ; 2000)	1	Two-staged surgical resection for secretory meningothehal meningioma: (1) suboccipital + supratentorial occipital craniotomy, resection of occluded left TS, tumor shelled out of right TS and SSS with primary closure (2) Reopening of craniotomy and resection of posterior SSS, right TS prior to vein of Labbé, and straight sinus which was completely occluded	N/A	Two y following the initial operation, the patient presented with spontaneous occipital intracerebral hemorrhage. No new neurological deficit was noted following the second operation.
Debernardi et al <sup>27</sup>	Torcula meningioma with multivenous sinus invasion: compensatory drainage veins and surgical strategy ( <i>World Neurosurg</i> ; 2018)	1	Subtotal resection of WHO I meningioma which included surgical removal of included torcula, right TS, partial left TS, and straight sinus; Simpson IV	Gamma Knife radiosurgery focusing on the SSS residual tumor at 8 mo postoperatively. Target volume = 6.45 mL. Marginal radiation dose of 15 Gy (median dose 20 Gy)	Moderate occipital and cerebellar edema postoperatively treated with corticosteroids for 4 d. No new neurological deficits. One-y follow-up post-Gamma Knife showed minimal volumetric reduction of residual tumor
Feng et al <sup>42</sup>	Surgical treatment of recurrent torcular meningiomas: case report and review of the literature ( <i>J Neurol Surg A</i> ; 2013)	1	Gross total resection of torcular meningioma including the removal of occluded posterior SSS, confluens, right and left TS	N/A	Generalized seizures postoperatively with CNS imaging showing massive brain edema. Poor functional status at discharge
Li et al <sup>43</sup>	Microsurgical management of meningiomas in the torcular herophili region ( <i>J Craniofacial Surg</i> ; 2016)	35	Simpson I in 27 patients, Simpson II in 5 patients, Simpson IV in 3 patients	The three patients with Simpson IV resection of WHO II meningiomas underwent postoperative Gamma Knife therapy. The remaining 32 patients held a diagnosis of WHO I meningioma and did not receive radiation	Average follow-up of 17.0 ± 8.4 mo Average preoperative Karnofsky score of 63.4 ± 14.7 vs. 86.9 ± 11.6 postoperatively
Mantovani et al <sup>18</sup>	Management of meningiomas invading the major dural venous sinuses: operative technique, results and potential benefit for higher grade tumors ( <i>World Neurosurg</i> ; 2014)	5	Gross total resection of torcular meningiomas in which the dural sinuses were opened and the tumor shelled out of partially occluded transverse sinuses. Sinus repair carried out using either dural patch or galea patch	N/A	No deaths. One patient suffered from intraventricular hemorrhage and hydrocephalus necessitating reopening of occipital craniotomy, suboccipital decompressive craniectomy, and ventriculostomy

Table 1 (Continued)

Author	Article	No. of patients treated for torcular meningioma	Surgical strategy	Radiation therapy	Outcomes/complications
Mazur et al <sup>15</sup>	Surgical management of a transosseous meningioma with invasion of torcula, superior sagittal sinus, transverse sinus, calvaria, and scalp ( <i>Surg Neurol Int</i> ; 2015)	1	Gross total resection was carried out for large WHO I meningioma occluding the torcula and left TS, with hyperostosis of occipital bone and scalp involvement. The SSS was ligated proximal to the occlusion and the left TS was resected as well. The right TS and straight sinus walls were repaired primarily. Cranial reconstruction was performed using a sutured AlloDerm duraplasty and titanium mesh followed by a latissimus dorsi free flap	N/A	The patient had a transient loss of visual acuity which improved throughout rehabilitation
Raza et al <sup>44</sup>	Perioperative and long-term outcomes from the management of parasagittal meningiomas invading the superior sagittal sinus ( <i>Neurosurgery</i> ; 2010)	10	One patient with a torcular meningioma which also occluded the right TS underwent preoperative embolization via a feeding right occipital artery followed by Simpson I resection. Ten patients in total underwent surgery for posterior SSS meningiomas (eight with partial sinus invasion and two with complete sinus invasion)	One patient underwent postoperative radiotherapy	Overall perioperative complication rate of 7% with a 2.5% recurrence rate (in a series of 110 parasagittal meningiomas)
Sindou and Alvernia <sup>28</sup>	Results of attempted radical tumor removal and venous repair in 100 consecutive meningiomas involving the major dural sinuses ( <i>Neurosurg</i> ; 2006)	3	Three patients underwent surgery for torcular meningiomas. One patient received a bypass graft from the SSS to the external jugular vein using autologous saphenous vein	N/A	Good functional recovery was noted following the use of a venous bypass graft for torcular meningioma with Grade IV invasion
Talacchi et al <sup>45</sup>	Surgical management of medial tentorial meningioma: falcontentorial and torcular ( <i>World Neurosurg</i> ; 2018)	12	Four patients underwent Simpson Grade I resection, two patients underwent Simpson II resection, two patients underwent Simpson III resection, and five patients underwent Simpson IV resection	Stereotactic radiosurgery was offered to patients presenting with recurrent tumors	Two patients suffered from postoperative hematoma, two patients developed CSF fistula, and one patient developed hydrocephalus requiring VP shunt. One patient became quadriplegic and one patient suffered from a new cranial nerve deficit

(Continued)



**Table 1** (Continued)

Author	Article	No. of patients treated for torcular meningioma	Surgical strategy	Radiation therapy	Outcomes/complications
Zeesan et al <sup>46</sup>	Resection of meningiomas involving major dural venous sinuses: classification, technique, and long-term results ( <i>World Neurosurg</i> ; 2019)	3	Extravascular tumor resection was carried out before entering into the major dural venous sinuses to resect the remaining tumor. The sinuses were repaired with either primary closure or dural patch graft	Radiotherapy was administered for all WHO II and III tumors	One patient developed intraventricular hemorrhage which did not require intervention and made a full recovery

Abbreviations: CNS, central nervous system; CSF, cerebrospinal fluid; SSS, superior sagittal sinus; N/A, not available; TS, transverse sinus; VS, ventriculoperitoneal; WHO, World Health Organization.

access corridor in order to preserve these essential venous channels intraoperatively.

Our case demonstrates a stepwise approach to the surgical management of torcular meningiomas guided by the degree of torcular invasion. Given our patient's young age and tumor histopathology (atypical WHO II with high mitotic index), the risk of symptomatic recurrence in the future was high. Therefore, our overarching goal was to safely resect the accessible portion of the tumor including the surrounding structures (sinus wall) which was achieved. On presentation, the patients torcula was only partially occluded, and we believed that the safest option was to stage the procedure into a first phase with the sole intent to resect the extravascular portion of the tumor. This was to address the symptomatic portion causing mass effect on the adjacent occipital lobe resulting in visual field compromise. This step of surgery could be achieved with routine microsurgical techniques while leaving a sliver of tumor along the wall of the torcula. In the expectant interval between the first and second operations, the tumor progressed resulting in complete occlusion of the torcula with further development of venous collateral circulation, which was demonstrated on repeat cerebral angiography. At this juncture, we felt that the risk versus benefit ratio favored an aggressive resection of the intravascular portion of the tumor at the torcula as well as the portion that extended into the patent right TS and the completely occluded left TS.

As we have demonstrated here, the resection of completely occluded portions of major dural venous sinuses can generally be considered safe in the presence of adequate collateral venous flow. However, in an effort to prevent delayed complications, several authors advocate for the use of a sinus patch technique to reconstitute flow through the sinus, or for a venous bypass in selected patients, though this algorithm remains under debate.<sup>1,20,29</sup> Importantly, one must consider the relation of the tumor to the patient's specific venous sinus anatomy, of which four key variants have been described by Alvernia and Sindou.<sup>29</sup> Approximately 55% of patients demonstrate asymmetric SSS to TS drainage, 20% demonstrate symmetric SSS to bilateral TS drainage, 25% drain from the SSS to a TS unilaterally, while 17% of patients possess one normal TS and one atretic TS.

In one study, Mantovani et al described their center's experience with using primary suture repair and autologous dural patch repair of the affected venous sinus. In this retrospective cohort of mixed topographies, 38 patients underwent operations for resection of meningiomas involving major venous sinus. Of those 38 patients, only 5 invaded the torcula itself. Reconstruction was carried out in 21 patients overall (13 by direct suture and 8 by using a dural patch). Postoperative patency rates were about 50% with the implementation of a perioperative antiplatelet regimen.<sup>4</sup>

While some studies have observed high thrombosis rates associated with the use of autologous vein bypasses (~50%),<sup>30,31</sup> others have demonstrated promising results. In a study by Sindou and Alvernia, radical tumor removal and venous repair were attempted in 100 consecutive meningiomas involving major dural sinuses.<sup>29</sup> In the first 2 weeks

after surgery, angiographic data revealed sinus patency in all eight patients treated with primary repair and 13 of 15 patched cases. Furthermore, 7 of 10 saphenous bypass grafts remained patent as well—including one bypass from the SSS to the external jugular vein following the resection of a torcular meningioma. Of note, those patients who underwent saphenous vein bypass grafts that later thrombosed remained asymptomatic. It is postulated that the temporary bypass allowed more time for venous collaterals to emerge.

When a gross total resection is not feasible, or where histopathological diagnosis reveals an aggressive atypical or anaplastic meningioma (WHO II/WHO III), external beam radiation is considered the adjuvant therapy of choice to prolong PFS.<sup>32–34</sup> Current National Comprehensive Cancer Network guidelines recommend radiotherapy for incompletely resected or recurrent WHO II meningiomas and for all WHO III meningiomas (Level 2A).<sup>35</sup> Although there is a relative paucity of long-term data or randomized controlled trials in the literature, retrospective data have shown a trend toward improved outcomes with immediate postoperative radiation following gross total resection with certain WHO Grades II and III meningiomas.<sup>36</sup> Initial results of two prospective trials, EORTC 22042 and RTOG 0539, have also shown promising results with 3-year PFS rates of 88.7 and 93.8%, respectively, following adjuvant radiotherapy.<sup>37,38</sup> Caution must be exercised when irradiating meningiomas with venous sinus involvement as venous occlusive complications may affect collateral flow and has been shown to lead to a higher morbidity rate.<sup>39,40</sup> Given our patient's age, histopathological diagnosis, and near total yet incomplete tumor resection status, our center also offered adjuvant radiotherapy in an attempt to improve our patient's chances for better local control and improved PFS. As of now, only 18 months after her complex second-stage surgery and subsequent radiation therapy, the patient remains in good health and with no evidence of recurrence. Given the rarity of this entity, we recommend the establishment of multicenter registries, collecting the outcome data in these infrequent cases of torcular meningioma, which will tell us whether this combined treatment strategy confers the highest benefit to this vulnerable patient population.

## Conclusion

We advocate for a tailored approach to each patient when determining the optimal timing of surgery and designing a surgical strategy in torcular meningiomas. The use of preoperative cerebral angiography has proved to be an invaluable adjunct to MRI and CT/CTV for evaluating the adequacy of collateral venous flow and should be utilized to determine the timing and safety of venous sinus ligation and resection. Staged resection may be the most suitable and safest approach to this scenario, allowing the formation of collaterals prior to complete resection. When encountering atypical meningiomas, adjuvant radiation therapy may be needed to achieve local control and prolonged PFS.

## Conflict of Interest

None declared.

## References

- 1 Brotchi J. Brussels. *World Neurosurg* 2013;82:325
- 2 Riemenschneider MJ, Perry A, Reifenberger G. Histological classification and molecular genetics of meningiomas. *Lancet Neurol* 2006;5(12):1045–1054
- 3 Ostrom QT, Cioffi G, Gittleman H, et al. CBTRUS statistical report: primary brain and other central nervous system tumors diagnosed in the United States in 2012–2016. *Neuro-oncol* 2019;21 (Suppl 5):v1–v100
- 4 Harsh GR IV, Wilson CB. Meningiomas of the peritorcular region. In: Al-Mefty O, ed. *Meningiomas*. New York: Raven Press; 1991: 363–369
- 5 Pathmanaban ON, Sadler KV, Kamaly-Asl ID, et al. Association of genetic predisposition with solitary schwannoma or meningioma in children and young adults. *JAMA Neurol* 2017;74(09): 1123–1129
- 6 Evans DG. Neurofibromatosis 2 [bilateral acoustic neurofibromatosis, central neurofibromatosis, NF2, neurofibromatosis type II]. *Genet Med* 2009;11(09):599–610
- 7 Kerr K, Qualmann K, Esquenazi Y, Hagan J, Kim DH. Familial syndromes involving meningiomas provide mechanistic insight into sporadic disease. *Neurosurgery* 2018;83(06):1107–1118
- 8 Hatch EE, Linet MS, Zhang J, et al. Reproductive and hormonal factors and risk of brain tumors in adult females. *Int J Cancer* 2005;114(05):797–805
- 9 Louis DN, Perry A, Reifenberger G, et al. The 2016 World Health Organization classification of tumors of the central nervous system: a summary. *Acta Neuropathol* 2016;131(06):803–820
- 10 Simpson D. The recurrence of intracranial meningiomas after surgical treatment. *J Neurol Neurosurg Psychiatry* 1957;20(01): 22–39
- 11 Buerki RA, Horbinski CM, Kruser T, Horowitz PM, James CD, Lukas RV. An overview of meningiomas. *Future Oncol* 2018;14(21): 2161–2177
- 12 Gousias K, Schramm J, Simon M. The Simpson grading revisited: aggressive surgery and its place in modern meningioma management. *J Neurosurg* 2016;125(03):551–560
- 13 Ehresman JS, Garzon-Muvdi T, Rogers D, et al. The relevance of Simpson grade resections in modern neurosurgical treatment of World Health Organization grade I, II, and III meningiomas. *World Neurosurg* 2018;109:e588–e593
- 14 Fogh SE, Johnson DR, Barker FG II, et al. *Case-Based Review: meningioma*. *Neurooncol Pract* 2016;3(02):120–134
- 15 Mazur MD, Neil JA, Agarwal C, Jensen RL, Couldwell WT. Surgical management of a transosseous meningioma with invasion of torcula, superior sagittal sinus, transverse sinus, calvaria, and scalp. *Surg Neurol Int* 2015;6(01):40
- 16 Alvernia JE, Sindou MP. Torcular, transverse, and sigmoid sinus meningiomas. In: Lee JH, ed. *Meningiomas*. London: Springer; 2009
- 17 Cushing H, Eisenhardt L. *Meningiomas: Their Classification, Regional Behaviour, Life History and Surgical Results*. Springfield, IL: Charles C Thomas; 1938
- 18 Mantovani A, Di Maio S, Ferreira MJ, Sekhar LN. Management of meningiomas invading the major dural venous sinuses: operative technique, results, and potential benefit for higher grade tumors. *World Neurosurg* 2014;82(3–4):455–467
- 19 Sindou M. Meningiomas involving major dural sinuses: should we attempt at radical removal and venous repair? *World Neurosurg* 2014;81(01):46–47
- 20 Di Maio S, Ramanathan D, Garcia-Lopez R, et al. Evolution and future of skull base surgery: the paradigm of skull base meningiomas. *World Neurosurg* 2012;78(3–4):260–275

- 21 Sindou M, Hallacq P. Venous reconstruction in surgery of meningiomas invading the sagittal and transverse sinuses. *Skull Base Surg* 1998;8(02):57–64
- 22 Mathiesen T, Lindquist C, Kihlström L, Karlsson B. Recurrence of cranial base meningiomas. *Neurosurgery* 1996;39(01):2–9
- 23 Sindou MP, Alvernia JE. Results of attempted radical tumor removal and venous repair in 100 consecutive meningiomas involving the major dural sinuses. *J Neurosurg* 2006;105(04):514–525
- 24 Sindou M, Hallacq P, Ojemann RG, Laws ER. Aggressive vs. conservative treatment of parasagittal meningiomas involving the superior sagittal sinus. In: Al Mefty Origitano TC, Harkey HL, eds. *Controversies in Neurosurgery*. New York: Thieme; 1996:80–89
- 25 Hwang SK, Gwak HS, Paek SH, Kim DG, Jung HW. Guidelines for the ligation of the sigmoid or transverse sinus during large petroclival meningioma surgery. *Skull Base* 2004;14(01):21–28, discussion 29
- 26 Oka K, Go Y, Kimura H, Tomonaga M. Obstruction of the superior sagittal sinus caused by parasagittal meningiomas: the role of collateral venous pathways. *J Neurosurg* 1994;81(04):520–524
- 27 Caroli E, Orlando ER, Mastronardi L, Ferrante L. Meningiomas infiltrating the superior sagittal sinus: surgical considerations of 328 cases. *Neurosurg Rev* 2006;29(03):236–241
- 28 Debernardi A, Quilici L, La Camera A, Boccardi E, Cenzato M. Torcular meningioma with multi-venous sinus invasion: compensatory drainage veins and surgical strategy. *World Neurosurg* 2018;109:451–454
- 29 Sindou MP, Alvernia JE. Results of attempted radical tumor removal and venous repair in 100 consecutive meningiomas involving the major dural sinuses. *J Neurosurg* 2006;105(04):514–525
- 30 Al-Mefty O, Yamamoto Y. Neurovascular reconstruction during and after skull base surgery. *Contemp Neurosurg* 1993;15:1–6
- 31 Hakuba A. Reconstruction of dural sinus involved in meningiomas. In: Al Mefty O, ed. *Meningiomas*. New York: Raven Press; 1991:371–382
- 32 Bauman GS, Wong E. Re: new radiotherapy technologies for meningiomas: 3D conformal radiotherapy? Radiosurgery? Stereotactic radiotherapy? Intensity modulated radiotherapy? Proton beam radiotherapy? Spot scanning proton radiation therapy? Or nothing at all? [*Radiother Oncol* 2004;71(3):247–249]. *Radiother Oncol* 2004;73(02):251–252
- 33 Chin LS, Szerlip NJ, Regine WF. Stereotactic radiosurgery for meningiomas. *Neurosurg Focus* 2003;14(05):e6
- 34 Kondziolka D, Nathoo N, Flickinger JC, Niranjan A, Maitz AH, Lunsford LD. Long-term results after radiosurgery for benign intracranial tumors. *Neurosurgery* 2003;53(04):815–821
- 35 NCCN Guidelines. Central Nervous System Cancers Version 1.2017, Accessed 9 June 2020 at: <http://nccn.org/>
- 36 Walcott BP, Nahed BV, Brastianos PK, Loeffler JS. Radiation treatment for WHO Grade II and III meningiomas. *Front Oncol* 2013;3:227
- 37 Weber DC, Ares C, Villa S, et al. Adjuvant postoperative high-dose radiotherapy for atypical and malignant meningioma: a phase-II parallel non-randomized and observation study (EORTC 22042-26042). *Radiother Oncol* 2018;128(02):260–265
- 38 Rogers CL, Won M, Vogelbaum MA, et al. High-risk meningioma: initial outcomes from NRG oncology/RTOG 0539. *Int J Radiat Oncol Biol Phys* 2020;106(04):790–799
- 39 Kondziolka D, Mathieu D, Lunsford LD, et al. Radiosurgery as definitive management of intracranial meningiomas. *Neurosurgery* 2008;62(01):53–58, discussion 58–60
- 40 Singh VP, Kansai S, Vaishya S, Julka PK, Mehta VS. Early complications following gamma knife radiosurgery for intracranial meningiomas. *J Neurosurg* 2000;93(Suppl 3):57–61
- 41 Barua KK, Tamaki N, Ehara K, Nagashima T, Suzuki H. Spontaneous peritumoral haemorrhage associated with sinus confluence meningioma: case report. *Surg Neurol* 2000;54(03):254–259
- 42 Feng R, Che X, Hu J, Pan L, Cui D, Yang L. Surgical treatment of recurrent torcular meningiomas: case report and review of the literature. *J Neurosurg A Cent Eur Neurosurg* 2013;74(Suppl 1):e266–e270
- 43 Li X, He X, Niu J, Du C, Wang J. Microsurgical Treatment of Meningiomas in the Torcular Herophili Region. *J Craniofac Surg* 2016;27(02):e211–e215
- 44 Raza SM, Gallia GL, Brem H, Weingart JD, Long DM, Olivi A. Perioperative and long-term outcomes from the management of parasagittal meningiomas invading the superior sagittal sinus. *Neurosurgery* 2010;67(04):885–893
- 45 Talacchi A, Biroli A, Hasanbelliu A, Locatelli F. Surgical Management of Medial Tentorial Meningioma: Falcotentorial and Torcular. *World Neurosurg* 2018;115:e437–e447
- 46 Zeeshan Q, Patel A, Cheng CY, Zhao NH, Barber J, Ghodke BV, Sekhar LN. Resection of Meningiomas Involving Major Dural Venous Sinuses: Classification, Technique, and Long-Term Results. *World Neurosurg* 2019;125:e521–e536