

## Case Report

# Regrowth of Cervical Intradural Lipoma without Spinal Dysraphism

Doo Kyung Son, M.D.,<sup>1</sup> Dong Wuk Son, M.D., Ph.D.,<sup>1</sup> Chang Hwa Choi, M.D., Ph.D.,<sup>2</sup> Geun Sung Song, M.D., Ph.D.<sup>1</sup>

Department of Neurosurgery,<sup>1</sup> Pusan National University Yangsan Hospital, Yangsan, Korea

Department of Neurosurgery,<sup>2</sup> Pusan National University Hospital, Busan, Korea

A 49 years old male patient who suffered from deterioration of posterior neck pain, left hand numbness, left lower limb pain and gait disturbance for 3 years visited our outpatient department. He had been diagnosed as non-dysraphic cervical intradural lipoma and operated in August 1990. On the radiologic images, we found the regrowth of non-dysraphic cervical intradural lipoma from C2 to C7 level, which surrounds and compresses the cervical spinal cord. Previous subtotal laminectomy from C2 to C7 and severe cervical lordosis were also found. Appropriate debulking of lipoma mass without duroplasty was successfully done with intraoperative neurophysiological monitoring (IONM). We are following up the patient for 24 months via outpatient department, his neurologic symptoms such as hand numbness, gait disturbance, left lower limb pain and posterior neck pain have improved. We describe a rare case of regrowth of non-dysraphic cervical intradural lipoma.

**Key Words** : Spinal lipoma · Spinal cord lipoma · Extent of resection · Regrown lipoma.

## INTRODUCTION

Spinal cord lipomas are rare and account for about 1% of all spinal cord tumors<sup>2,4,6-8,10-12,16-18</sup>. They are usually associated with lumbo-sacral spinal dysraphism, and these lesions extend to the subcutaneous tissue through a defect in the posterior elements of the spine. Non-dysraphic spinal cord lipomas are rare tumors of the spinal cord<sup>2,4,6-8,10,11,16</sup>.

On reviewing the literature, we found that articles which demonstrate regrowth of spinal cord lipomas are uncommon, and we managed to find some articles on this subject<sup>6,14,16</sup>. In this article, we present our recent experience about regrowth of cervical intradural lipoma without spinal dysraphism.

## CASE REPORT

A 49-year-old male patient who was suffering from aggravation of posterior neck pain, numbness in the left hand, pain in the left lower limb, and gait disturbance since 3 years visited our out-patient department. He had been diagnosed as having non-dysraphic cervical intradural lipoma and was operated in August 1990. This case was previously reported<sup>15</sup>.

We had reviewed the patient's previous chart since he re-visit-

ed our out-patient department. According to the previous chart, he had been suffering from posterior neck pain for one year, and at that time, there were no neurologic symptoms except for neck pain. Physical examination did not reveal any stigmata such as dimples, hair, fistula, or any masses on his vertebral column. Previous preoperative cervical plain film images showed severe cervical lordosis and increased anteroposterior diameter of the spinal canal (Fig. 1). Previous computed tomography (CT) and magnetic resonance imaging (MRI) images showed a huge lipomatous mass, which was located intradurally and it encircled and compressed the spinal cord from the C2 to C7 level (Fig. 2, 3). Although he was neurologically intact, we performed adequate debulking of the lipomatous mass with subtotal laminectomy from the C2 to C7 level in order to prevent neurological deterioration. Histopathological examination showed mature and uniform adipose cells without any cellular pleomorphism, suggesting the diagnosis of a benign lipoma.

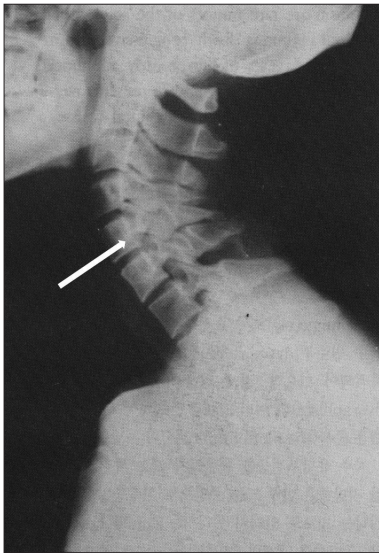
When the patient re-visited our outpatient department, neurological examination showed slightly decreased motor power in the left lower limb (MRC grade 4/5), numbness in the left hand along the C6 and C7 dermatomes, and posterior neck pain radiating to the left shoulder. On radiologic examination, we found regrowth of the lipomatous mass from the C2 to C7 level, which

• Received : January 2, 2014 • Revised : April 22, 2014 • Accepted : August 14, 2014

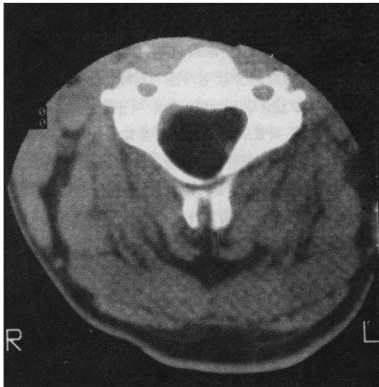
• Address for reprints : Dong Wuk Son, M.D., Ph.D.

Department of Neurosurgery, Pusan National University Yangsan Hospital, 20 Geumo-ro, Mulgeum-eup, Yangsan 626-770, Korea  
Tel : +82-55-360-2126, Fax : +82-55-360-2156, E-mail : md6576@naver.com

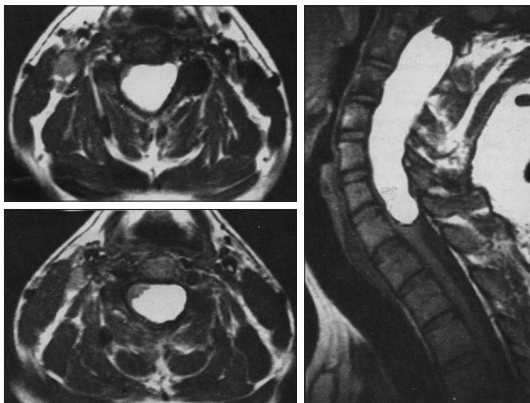
• This is an Open Access article distributed under the terms of the Creative Commons Attribution Non-Commercial License (<http://creativecommons.org/licenses/by-nc/3.0>) which permits unrestricted non-commercial use, distribution, and reproduction in any medium, provided the original work is properly cited.



**Fig. 1.** Preoperative cervical plain film at the time of the first operation shows severe cervical lordosis and increased anteroposterior diameter of the spinal canal (arrow), which may suggest the presence of a mass lesion in the vertebral canal.



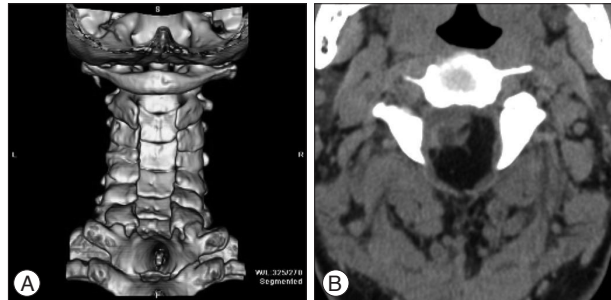
**Fig. 2.** Preoperative CT image at the time of the first operation shows a hypodense tumor mass occupying the spinal canal almost entirely. Cervical spinal cord was severely compressed and located peripherally in the spinal canal.



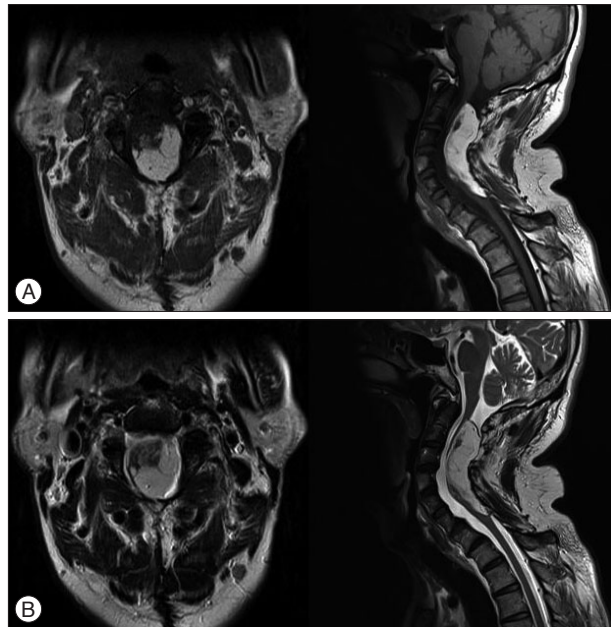
**Fig. 3.** Preoperative T1-weighted sagittal image at the time of the first operation shows a huge intradural mass with high signal intensity located from the C2 to C7 level. Axial image shows that this mass occupies the entire spinal canal and distorts the cervical spinal cord.

encircled and compressed the cervical spinal cord. Previous subtotal laminectomy from C2 to C7 and severe cervical lordosis were also observed (Fig. 4, 5).

We performed subtotal laminectomy of C1 in order to identify the normal elements of cervical dura because there were severe adhesions between paraspinal muscles, soft tissues and cervical dura. After that, we could perform dissection of the previous adhesions and could identify the cervical dura (Fig. 6A). When the dura was opened, we found a huge, yellowish mass in the intradural space, which encircled and compressed the cervical spinal cord (Fig. 6B). We performed subtotal debulking of the lipomatous mass using ultrasonic tissue ablation system paying careful attention to signals of intraoperative neurophysiological monitoring (IONM). There were no complications during IONM in the intraoperative course. We performed an adequate decompression of the spinal canal, and therefore we could suture the dura watertightly without duraplasty (Fig.

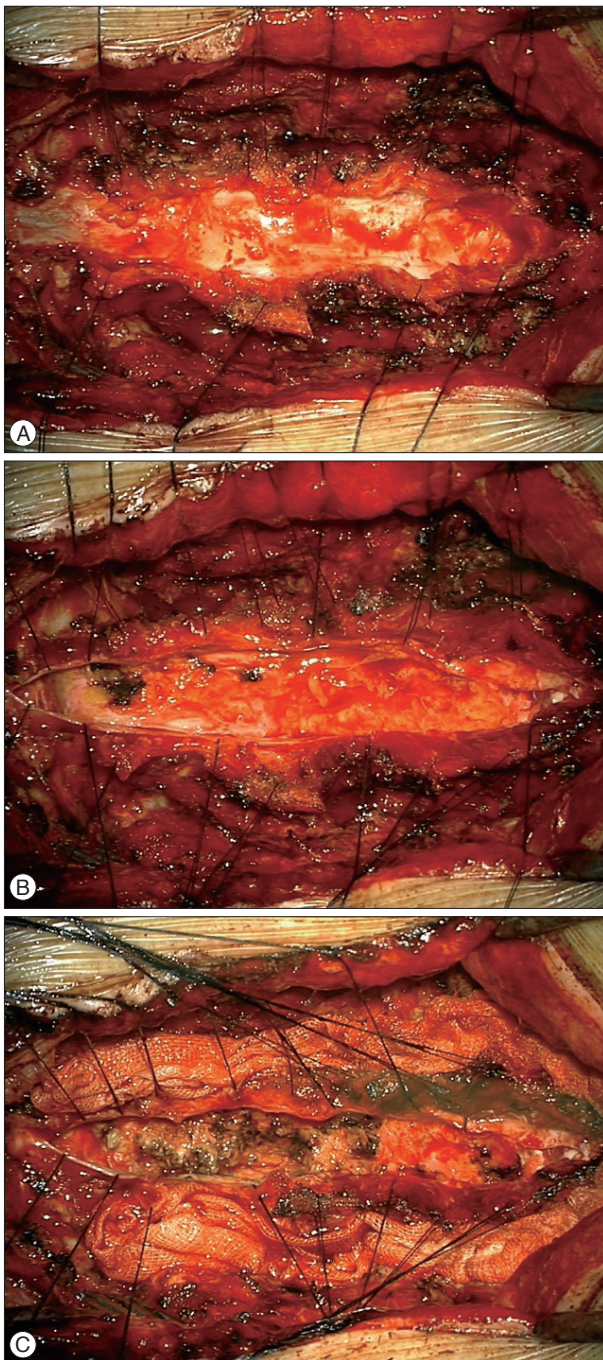


**Fig. 4.** Preoperative 3-dimensional CT images at the time of the second operation show previous subtotal laminectomy from C2 to C7 (A). The hypodense intradural mass is the recurred intradural lipoma, and it also compresses and distorts the cervical spinal cord (B).



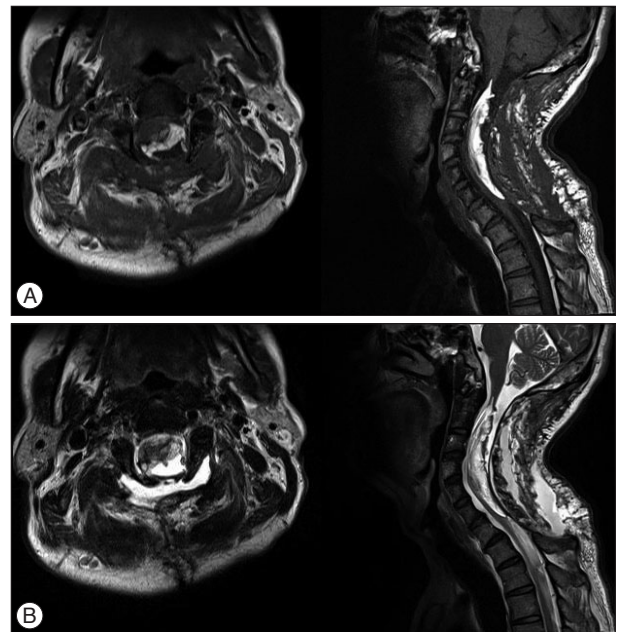
**Fig. 5.** Preoperative T1- (A) and T2- (B) weighted MRI images at the time of the second operation show an intradural lipoma from the C2 to C7 level exhibiting high signal intensity, suggesting a regrown lipomatous mass.



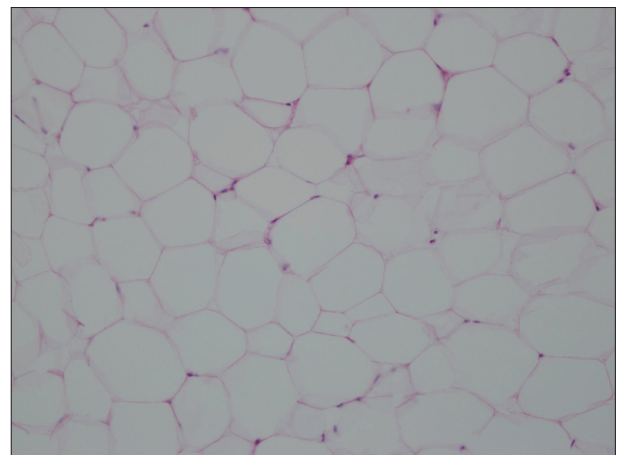


**Fig. 6.** During the operation, there were severe adhesions between the cervical dura, paraspinal muscles and soft tissues. A : When we incised the cervical dura after performing dissection of adhesions, we found a huge, yellowish mass in the intradural space, and it looked like a lipomatous mass. B : After performing subtotal debulking of the lipomatous mass, we achieved adequate decompression of the spinal canal. C : Thus, we could close the cervical dura without duraplasty.

6C). On the postoperative day 2, we found a cystic mass at the surgical site and it had gradually increased in size. On MRI, the cystic mass showed low signal intensity on T1-weighted images and high signal intensity on T2-weighted images; it suggested the presence of cerebrospinal fluid (CSF) (Fig. 7). We gently as-



**Fig. 7.** Postoperative T1- (A) and T2- (B) weighted MRI images show that the debulked intradural lipoma at the C2–7 vertebral level exhibits high signal intensity. The low signal intensity mass on T1-weighted image and the high signal intensity mass on T2-weighted image suggest fluid collection at the surgical site, it was found to be cerebrospinal fluid.



**Fig. 8.** Peripherally located nucleus and vacant cytoplasm without fat necrosis confirm the presence of mature adipose cells, suggesting the diagnosis of lipoma (Hematoxylin and Eosin stain,  $\times 200$ ).

pirated the cystic mass with a 24 gauge needle attached to the syringe, and then the surgical site was continuously compressed. After that, the cystic mass spontaneously disappeared. Histopathologic examination showed mature adipose tissue and fibrous tissue without cellular pleomorphism, suggesting the diagnosis of a benign lipoma (Fig. 8).

We are following up the patient for 24 months at the out-patient department, and his neurological symptoms have improved.

## DISCUSSION

Spinal cord lipomas are usually associated with spinal dysra-

phism, and they account for 1% of all spinal cord tumors. The number of non-dysraphic spinal cord lipomas is less than that of dysraphic spinal cord lipomas, and they are usually located intradurally. Thus, they usually do not present as subcutaneous lesions<sup>3,10,18</sup>. In this case, according to the previous chart, there were no subcutaneous lesions on the patient's vertebral column.

Non-dysraphic intradural lipomas are commonly located in the thoracic spine; like our case, non-dysraphic cervical intradural lipomas account for only one-seventh or one-eighth of the spinal cord lipomas<sup>8,9</sup>. Most of these lipomas are found in the posterior part of the spinal cord, and they usually distort and expand the spinal cord. In our case, we could observe increased anteroposterior diameter of the cervical spinal canal (Fig. 1). Most of these lipomas are subpial or juxtamedullary in location, and hence true intramedullary lipomas are very rare with only a few cases having been reported in the literature<sup>2,10,11</sup>. In this case, the radiologist deciphered that the lipomatous mass was juxtamedullary in location, and we were also able to identify the mass in that location.

About half of the patients who had spinal cord lipomas developed neurologic symptoms during their young adult age, and approximately one-fourth of the patients were in their childhood years and above 40 years of age<sup>2,8,10</sup>. Neurologic symptoms usually present in the form of myelopathies such as radiating pain, weakness or numbness in limbs of patients in the young adult age group. The symptoms are often delayed and they worsen gradually. Unfortunately, most of the patients suffer from spinal cord lipomas for 2 years before visiting the hospital<sup>2,8,10,13</sup>. Kabir et al.<sup>10</sup> stated that most of the patients who have cervical cord lipomas take more than 10 years for seeking medical advice. It took approximately 20 years for the development of neurologic symptoms in our patient after the initial operation.

Since Elsberg et al.<sup>5</sup> reported about the danger associated with total removal of spinal cord lipomas, which caused postoperative quadriplegia in 1925, many authors have changed their management strategy from conservative care to operation. Recently, several authors agree that proper treatment of these lesions includes surgical removal using microsurgical techniques with IONM in order to preserve the normal neurological tissues<sup>2,6,10,12,14,16,17</sup>. Adequate bony decompression is also recommended. Although many authors have mentioned and performed duraplasty, it is still controversial whether surgeons should perform duraplasty in all of the patients<sup>10,12</sup>. In our case, as described above, we mentioned that we could perform watertight closure of the cervical dura without duraplasty after subtotal debulking. Although CSF leakage occurred as an acute postoperative complication, we cautiously concluded that lack of duraplasty is not the reason for development of this complication. On reviewing the literature, we could not find the same complication in patients with similar disease; thus further studies are required to determine whether surgeons should perform duraplasty in all of the patients.

Meanwhile, the relationship between growth of these lesions

and lipid metabolism was reported and debated by many authors<sup>1,2,6,10,14,16</sup>. Fleming et al.<sup>6</sup> described 5 cases of non-dysraphic pediatric intramedullary spinal cord lipomas in 2010; they reported 2 cases of recurrence, and re-operation was needed in these 2 cases. They suspect that the number of adipocytes within non-dysraphic spinal cord lipomas can increase over time. Pruthi et al.<sup>16</sup> reported their experience with eight cases of non-dysraphic intradural lipomas in 2010, and they suggested that the spinal cord lipomas are not associated with obesity and metabolism of body fat. Our patient was thin and his weight had not changed since the time he underwent surgery in 1990. Furthermore, there was no increase in the lipid level on serum analysis. All of the authors had a similar opinion that further clinical and experimental studies are necessary for confirming the conclusions. To the best of our knowledge, only a few articles have reported regarding regrowth of cervical intradural lipomas<sup>6,14,16</sup>. Therefore, more studies are needed to understand the relationship between regrowth of cervical intradural lipomas and lipid metabolism.

## CONCLUSION

The patient's symptoms had recurred very slowly and insidiously at approximately 20 years after the initial operation. We describe a rare case of regrowth of cervical intradural lipoma without dysraphism who be successfully managed by appropriate debulking of regrown lipomatous mass.

## References

1. Akyuz M, Goksu E, Tuncer R : Spontaneous decrease in the size of a residual thoracic intradural lipoma. *Br J Neurosurg* 19 : 53-55, 2005
2. Bhatoe HS, Singh P, Chaturvedi A, Sahai K, Dutta V, Sahoo PK : Non-dysraphic intramedullary spinal cord lipomas : a review. *Neurosurg Focus* 18 : ECP1, 2005
3. Blount JP, Elton S : Spinal lipomas. *Neurosurg Focus* 10 : e3, 2001
4. Caram PC, Carton CA, Scarcella G : Intradural lipomas of the spinal cord; with particular emphasis on the intramedullary lipomas. *J Neurosurg* 14 : 28-42, 1957
5. Elsberg CA : Some aspects of the diagnosis and surgical treatment of tumors of the spinal cord : with a study of the end results in a series of 119 operations. *Ann Surg* 81 : 1057-1073, 1925
6. Fleming KL, Davidson L, Gonzalez-Gomez I, McComb JG : Nondysraphic pediatric intramedullary spinal cord lipomas : report of 5 cases. *J Neurosurg Pediatr* 5 : 172-178, 2010
7. Fujiwara F, Tamaki N, Nagashima T, Nakamura M : Intradural spinal lipomas not associated with spinal dysraphism : a report of four cases. *Neurosurgery* 37 : 1212-1215, 1995
8. Giuffrè R : Intradural spinal lipomas. Review of the literature (99 cases) and report of an additional case. *Acta Neurochir (Wien)* 14 : 69-95, 1966
9. Iwatsuki K : Intradural cervical lipoma with parenchymal marginal fibrous tissue : case report. *Neurosurgery* 59 : E208; discussion E208, 2006
10. Kabir SM, Thompson D, Rezajooi K, Casey AT : Non-dysraphic intradural spinal cord lipoma : case series, literature review and guidelines for management. *Acta Neurochir (Wien)* 152 : 1139-1144, 2010
11. Kim CH, Wang KC, Kim SK, Chung YN, Choi YL, Chi JG, et al. : Spinal intramedullary lipoma : report of three cases. *Spinal Cord* 41 : 310-315, 2003

12. Klekamp J, Fusco M, Samii M : Thoracic intradural extramedullary lipomas. Report of three cases and review of the literature. *Acta Neurochir (Wien)* **143** : 767-773; discussion 773-774, 2001
13. McGillicuddy GT, Shucart W, Kwan ES : Intradural spinal lipomas. *Neurosurgery* **21** : 343-346, 1987
14. O'Grady J, Kaliaperumal C, O'Sullivan M : Recurrent 'universal tumour' of the spinal cord. *BMJ Case Rep* **2012**. doi : 10.1136/bcr.12.2011.5284
15. Park IS, Choi CH, Lee YW, Song GS, Park DJ, Cha SH : Huge cervical intradural lipoma in a neurologically intact patient : case report. *J Korean Neurosurg Soc* **24** : 1583-1589, 1995
16. Pruthi N, Devi BI : Nondysraphic cervical and thoracic intraspinal lipomas : a review. *Br J Neurosurg* **24** : 228-232, 2010
17. Roka YB, Shrestha M, Puri PR, Adhikari HB : High cervical nondysraphic intradural extramedullary lipoma. *Neurol India* **60** : 350-351, 2012
18. Wood BP, Harwood-Nash DC, Berger P, Goske M : Intradural spinal lipoma of the cervical cord. *AJR Am J Roentgenol* **145** : 174-176, 1985