

# Involvement of Vitamin D in Chronic Infections of the Waldeyer's Ring in the School Aged Child

BIANCA ȘTEFĂNIȚA VINTILESCU<sup>1</sup>, CARMEN ELENA NICULESCU<sup>2</sup>,  
MIOARA DESDEMONA STEPAN<sup>2</sup>, ELENA IONIȚĂ<sup>3</sup>

<sup>1</sup>PhD Student, ENT Department, University of Medicine and Pharmacy of Craiova, Romania

<sup>2</sup>Department of Infant Care-Pediatrics-Neonatology, University of Medicine and Pharmacy of Craiova, Romania

<sup>3</sup>ENT Department, University of Medicine and Pharmacy of Craiova, Romania

**ABSTRACT:** Chronic infections of the Waldeyer's lymphatic ring constitute a frequent pathology in school age, one of the pathogenic mechanisms involving low levels of vitamin D. In this study, we analyzed integrated the clinico-epidemiological aspects, the risk factors and the serum level of vitamin D for 51 school aged children who presented chronic inflammation in various levels of the Waldeyer's ring. Most inflammations were present in females patients (80.4%), from the urban areas (66.6%), being localized in palatine tonsils (64.7%), in patients with deficient prophylaxis of hypovitaminosis D (68.6%) and low serum levels of vitamin D (72.5%). The results highlight the importance of maintaining a normal status of vitamin D, especially in recurrent infectious context.

**KEYWORDS:** Vitamin D, chronic infections, Waldeyer's ring, school aged child

## Introduction

Vitamin D is an essential element for the body, is involved in the regulation of calcium and phosphorus metabolism and interfere with the immune or inflammatory processes [1-4].

Decreasing the level of vitamin D below the optimal level is considered worldwide a problem in the school age, which persists both through environmental factors and nutrition and care deficits [5,6].

At the same time, in medical practice, one of the most frequent presentation to the pediatrician for the school age is represented by upper respiratory infections.

The pharynx is an organ with a complex immunological structure and function, both because of the location as an entry gate for numerous pathogenic agents and the presence of Waldeyer's ring composed of lymphoid structures such as the Luschka's tonsils, Gerlach's tonsils, palatine tonsils and lingual tonsil [7,8].

Chronic infections from the Waldeyer's ring involve pathogenic mechanisms maintained by different factors.

Recent studies indicate the immunomodulatory properties of vitamin D in inflammations of Waldeyer's ring [5,9].

At this level, the chronic inflammation develop through complex pathogenic mechanisms which involve monocytes, macrophages, T lymphocytes, B lymphocytes, their participation being influenced by the

presence of membrane surface receptors for vitamin D [5,9].

There are relatively few studies addressed to the vitamin D deficiency in Waldeyer's ring chronic infections, which indicated that optimal levels of vitamin can promote the differentiation and proliferation of inflammatory cells as well as inhibition of the Major Histocompatibility Complex II, the effect being to reduce the inflammatory process [10-13].

In this context, the school aged children have frequently chronic infections of the Waldeyer's ring and vitamin D deposits obtained in the early life years due to a much more careful therapeutic treatment are depleted, leaving only those in the diet or resulting from exposure to sunlight [14,15].

In this study we analyzed the clinico-epidemiological aspects and the risk factors involved in vitamin D deficiency in the context of chronic Waldeyer's lymphatic ring infections in school aged children.

## Material and methods

In this retrospective study we included 51 school aged children (7-15 years) with chronic infection of Waldeyer's ring.

The patients were presented for the current infectious episode in the Ambulatory of Pediatrics of the Craiova County Emergency Clinical Hospital during 2017-2018.

The diagnosis of Waldeyer's ring chronic infection was based on anamnesis, clinical and paraclinical data obtained in collaboration with

ENT Ambulatory (ear, nose, and throat) from the same hospital.

In the examinations carried were excluded other infectious or chronic inflammatory conditions.

This study also excluded patients who received drug treatments during the last three months, who took nutritional supplements outside of the hypovitaminosis D prophylaxis or who had an immunocompromised status.

The integrated statistical analysis of the clinico-epidemiological data (location of inflammation, gender, environment origin), risk factors (incorrect or absence of vitamin D administration in the last year) and paraclinical data (vitamin D level) was done using chi square comparative test ( $\chi^2$ ) within SPSS10 (Statistical Package for Social Sciences) software, the  $p < 0.05$  values being considered significant.

In this study, the optimal limit value of vitamin D was 30ng/ml, the vitamin D deficiency had a threshold of 20ng/ml, and vitamin insufficiency was established for values ranging between 21-29ng/ml [16].

In this study were respected the ethical standards in research, informed consent being obtained from all legal representatives of patients.

## Results

Clinico-epidemiological analysis indicated that of the 51 patients identified with chronic inflammatory pathology of the Waldeyer's lymphatic ring, the majority presented the location of the inflammatory process in palatine tonsils (tonsillitis), respectively in 33 cases, which accounted 64.7% of the cases.

In another 11 cases (21.6%) the inflammation was present in the Luschka's pharyngeal tonsil (adenoiditis) and in 7 cases the inflammation was present in both palatine and Luschka's tonsils (mixed or adeno-tonsillitis).

There were no cases of chronic inflammation of lingual tonsil and Gerlach's tonsils (Table 1, Fig.1A).

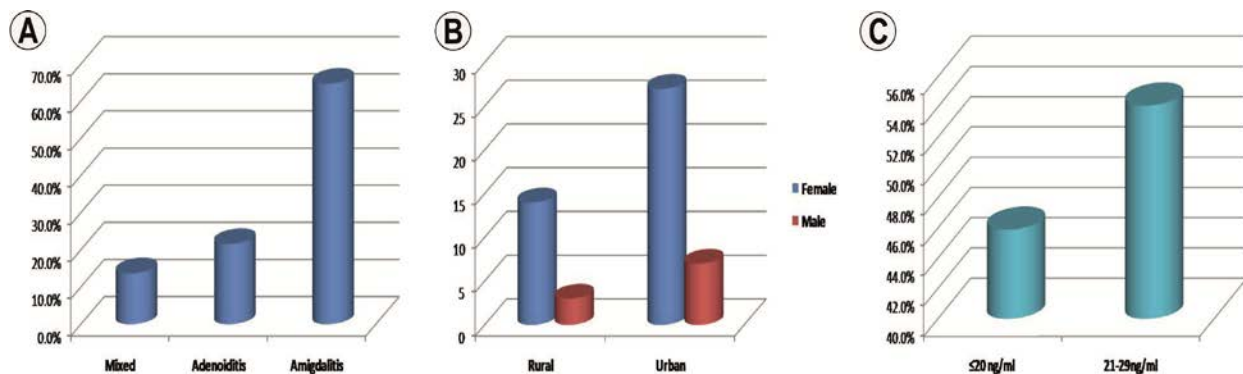
The study indicated the predominance of chronic inflammation in females, respectively in 41 cases, which accounted for 80.4% of the casuistry.

At the same time, most of the patients came from the urban area, respectively 34 cases which accounted for 66.6% of the patients.

The analysis of the cases distribution in relation to gender and environment origin indicated the predominance of females regardless of the patients living area or the inflammation location (Table 1, Fig.1B).

**Table 1. Cases distribution depending on inflammation type and analyzed parameters**

Parameter/ Inflammation	Gender		Environment origin		Vitamin D administration		Vitamin D deficiency or insufficiency (<30 ng)	
	Male	Female	Rural	Urban	Correct	Incorrect	Absent	Present
Mixed	1	6	6	1	6	1	6	1
Adenoiditis	2	9	5	6	4	7	4	7
Amigdalitis	7	26	6	27	6	27	4	29
<b>Total</b>	10	41	17	34	16	35	14	37
<b>p value (<math>\chi^2</math> test)</b>	0.908		0.002		0.002		<0.001	



**Fig.1. A. Cases distribution depending on inflammation type; B. Cases distribution related to gender and environment origin; C. Cases distribution with vitamin D deficiency/ insufficiency**

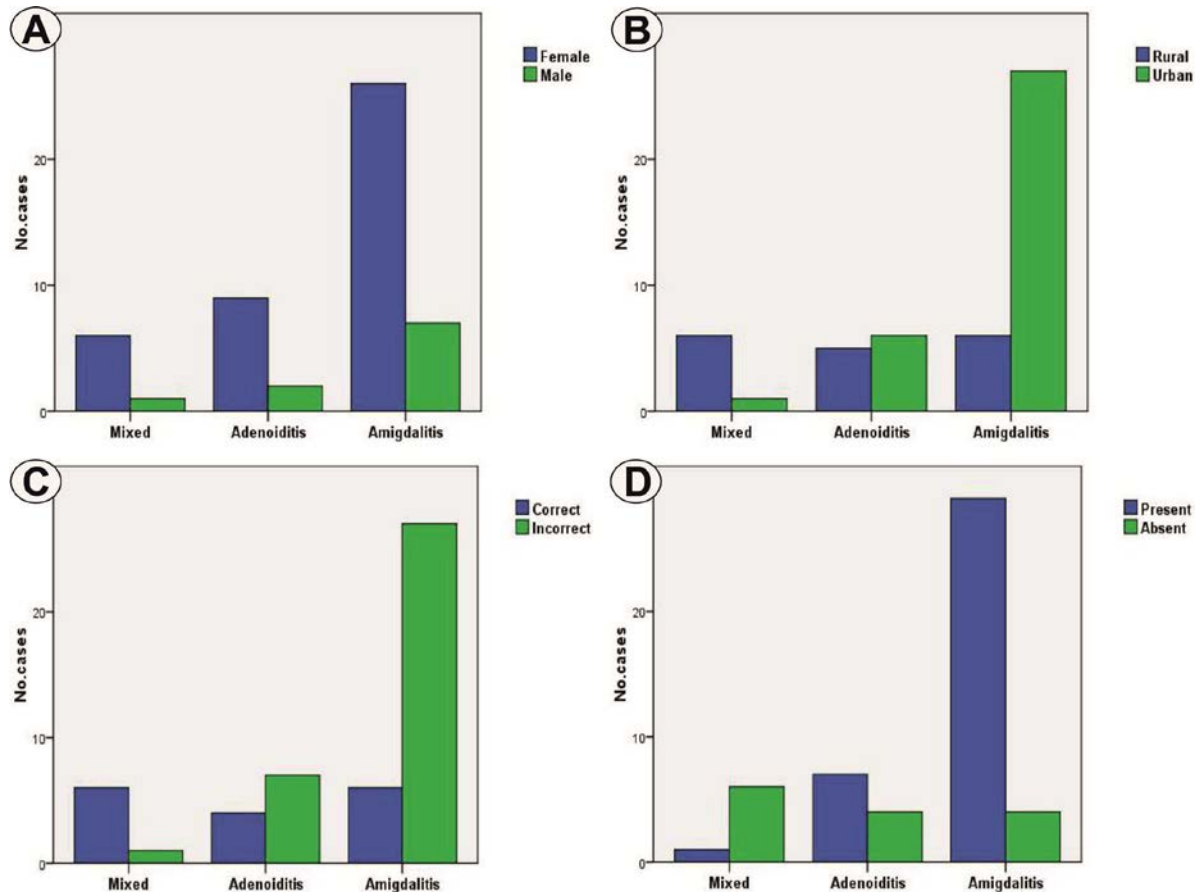
Regarding the risk factors, during patient's anamnesis we have seen an obvious predominance of those with an inadequate or absence administration of vitamin D supplements in 35 cases which accounted 68.6% (Table 1).

The analysis of the vitamin D serum level identified an optimal level in 14 cases (27.5%) and a low level in 37 cases (72.5%).

In relation to serum vitamin D status in this study we found a deficit level of serum vitamin D in 17 cases and an insufficient level in

20 cases, which represented 45.9% and 54.1% of the suboptimal patient group (Fig.1C).

The statistical analysis of the inflammation location in relation to the gender revealed insignificant differences ( $p=0.908$ ,  $\chi^2$  test), while in relation to the environment origin we found the predominance of tonsillitis and adenoiditis in the urban area and the mixed inflammations in the rural area, differences that were significant ( $p=0.002$ ,  $\chi^2$  test) (Table 1, Fig.2A-B).



**Fig.2. Distribution of amigdalites, adenoidites and mixed inflammations related to gender (A), environment origin (B), vitamin D administration (C) and Vitamin D deficiency/ insufficiency (D)**

Analysis of the location of the inflammation in relation to vitamin D administration indicated significant statistical differences ( $p=0.002$ ,  $\chi^2$  test), tonsillitis and adenoids being associated with an incorrect administration (Fig.2C).

At the same time, vitamin D deficiency /insufficiency presented significant statistical association with the tonsillitis and adenoiditis analyzed, while optimum levels were more frequently observed in mixed inflammation ( $p<0.001$ ,  $\chi^2$  test) (Fig.2D).

### Discussions

Inflammatory disorders of the Waldeyer ring are some of the most common reasons for children presenting to a pediatrician or otorhinolaryngologist.

Chronicization of these affections is a process favored by host factors such as tonsils cryptic structure, the amount of lymphatic tissue, allergic status, but also by external factors [7,8,17].

Chronic inflammation with this location affects the child's mental and physical development [7,8,17].

The maximum incidence of chronic tonsillitis is between 5-8 years and for chronic adenoiditis is the school age with the symptomatology onset much earlier [8,18].

School age is a risk factor for maintaining inflammation by entering in the community and implicit contact with a multitude of pathogenic agents.

In this study it was observed that chronic tonsillitis predominated with 64.7%, followed by chronic adenoiditis with 21.6% of cases and chronic adeno-tonsillitis in a percentage of 13.7, the aspects being in concordance with the literature data [8,18].

In this study the female patients predominated regardless the location of the inflammation or the environment origin.

Although the rural area was majority in patients diagnosed with chronic adeno-tonsillitis, the urban area predominated in patients with chronic adenoiditis and tonsillitis.

Pollution reflected by inappropriate concentrations of UV solar radiation from the urban area is a risk factor for insufficient vitamin D levels obtained in the skin level under their influence.

In this way the pathogenic cascade starts from a polluted urban area and is concretized by a low level of vitamin D in the body which implicitly interferes through receptors of the mechanism producing Waldeyer's ring chronic inflammation [19-21].

According to the World Health Organization (WHO) recommendations, vitamin D administration is a necessity for the school age [16,22].

In our study, according to anamnesis the dietary supplementation with vitamin D was performed in most cases incorrectly.

So in 68.6% of cases, they did not benefit by the vitamin D deficiency prophylaxis.

Centers for Disease Control and Prevention draw attention to the fact that 32% of children and adults have vitamin D deficiency below 20ng/ml [16,22-25].

Multiple reports including in Europe indicate that over 50% of the population is predisposed to the risk of vitamin D deficiency, the aspect being a global problem, especially in the context of vitamin D intervention in various diseases with high mortality and morbidity [16,22-25].

The dosage of vitamin D indicated values below 30ng/ml in 72.5% of cases included in the

study, which signified an inadequate status in most patients with chronic inflammation, and of these 45.9% were insufficient in vitamin D with values below 20ng/ml.

Insufficient level of vitamin D is supposed to be a trigger for chronic inflammation and deficiency is a maintenance factor for it [16,22-25].

Considered to be immunomodulatory, the vitamin D inhibits inflammatory reactions, the specific receptors being present on the immune cells involved in the pathogenic mechanism of inflammation [26].

Numerous recent studies identify more pediatric patients with recurrent respiratory tract infections with low levels of vitamin D, having the same pathogenic mechanism as in the case of pharyngeal infections [26-29].

## Conclusions

The study indicated significant associations of low levels of vitamin D and females, urban environment, incorrect prophylaxis, and palatine or Luschka's tonsils location.

Mixed adenotonsillar inflammations presented particular aspects, independent of vitamin D deficiency which may suggest the importance of hypovitaminosis in the initial stages of inflammation or his complementary role.

Prevention of vitamin D deficiency may alleviate the quality of life in school aged children and can simplify the management of chronic inflammation in lymphatic Waldeyer's ring.

## References

1. Handono K, Sidarta YO, Pradana BA, Nugroho RA, Hartono IA, Kalim H, Endharti AT. Vitamin D prevents endothelial damage induced by increased neutrophil extracellular traps formation in patients with systemic lupus erythematosus. *Acta Med Indones*, 2014, 46(3):189-198.
2. Holick MF. Sunlight and vitamin D for bone health and prevention of autoimmune diseases, cancers, and cardiovascular disease. *Am J Clin Nutr*, 2004, 80(6 Suppl):1678S-1688S.
3. Holick MF. Vitamin D: a millennium perspective. *J Cell Biochem*, 2003, 88(2):296-307.
4. Zittermann A, Gummert JF. Nonclassical vitamin D actions. *Nutrients*, 2010, 2(4):408-425.
5. Esposito S, Lelii M. Vitamin D and respiratory tract infections in childhood. *BMC Infect Dis*, 2015, 15:487.
6. Mangin M, Sinha R, Fincher K. Inflammation and vitamin D: the infection connection. *Inflamm Res*, 2014, 63(10):803-819.
7. Ballenger JJ. *Diseases of the Nose, Throat, Ear, Head and Neck*. Thirteenth edition, Lea&Febiger, Philadelphia, 1985.

8. Ioniță E. Elemente de patologie otorinolaringologică. Ed. Medicală Universitară, Craiova, 2013.
9. Wang H, Chen W, Li D, Yin X, Zhang X, Olsen N, Zheng SG. Vitamin D and Chronic Diseases. *Aging Dis*, 2017, 8(3):346-353.
10. Rigby WF, Denome S, Fanger MW. Regulation of lymphokine production and human T lymphocyte activation by 1,25-dihydroxyvitamin D3. Specific inhibition at the level of messenger RNA. *J Clin Invest*, 1987, 79(6):1659-1664.
11. Almerighi C, Sinistro A, Cavazza A, Ciaprini C, Rocchi G, Bergamini A. 1 $\alpha$ ,25-dihydroxyvitamin D3 inhibits CD40L-induced pro-inflammatory and immunomodulatory activity in human monocytes. *Cytokine*, 2009, 45(3):190-197.
12. Chen S, Sims GP, Chen XX, Gu YY, Chen S, Lipsky PE. Modulatory effects of 1,25-dihydroxyvitamin D3 on human B cell differentiation. *J Immunol*, 2007, 179(3):1634-1647.
13. Martineau AR, Wilkinson KA, Newton SM, Floto RA, Norman AW, Skolimowska K, Davidson RN, Sørensen OE, Kampmann B, Griffiths CJ, Wilkinson RJ. IFN- $\gamma$ - and TNF-independent vitamin D-inducible human suppression of mycobacteria: the role of cathelicidin LL-37. *J Immunol*, 2007, 178(11):7190-7198.
14. Taneja MK, Taneja V. Vitamin d deficiency in e.N.T. Patients. *Indian J Otolaryngol Head Neck Surg*, 2013, 65(1):57-60.
15. Dawson-Hughes B, Heaney RP, Holick MF, Lips P, Meunier PJ, Vieth R. Estimates of optimal vitamin D status. *Osteoporos Int*, 2005, 16(7):713-716.
16. Rusińska A, Płudowski P, Walczak M, Borszewska-Kornacka MK, Bossowski A, Chlebna-Sokół D, Czech-Kowalska J, Dobrzańska A, Franek E, Helwich E, Jackowska T, Kalina MA, Konstantynowicz J, Książyk J, Lewiński A, Łukaszkiewicz J, Marcinowska-Suchowierska E, Mazur A, Michałus I, Peregud-Pogorzelski J, Romanowska H, Ruchała M, Socha P, Szalecki M, Wielgoś M, Zwolińska D, Zygmunt A. Vitamin D Supplementation Guidelines for General Population and Groups at Risk of Vitamin D Deficiency in Poland-Recommendations of the Polish Society of Pediatric Endocrinology and Diabetes and the Expert Panel With Participation of National Specialist Consultants and Representatives of Scientific Societies-2018 Update. *Front Endocrinol (Lausanne)*, 2018, 9:246.
17. Hughes DA, Norton R. Vitamin D and respiratory health. *Clin Exp Immunol*, 2009, 158(1):20-25.
18. Middleton DB, D'Amico F, Merenstein JH. Standardized symptomatic treatment vs penicillin as initial therapy Streptococcal pharyngitis. *J Pediatrics*, 1988, 113(6):1089-1094.
19. Tom DT, Bart LC. Vitamin D Insufficiency. *Mayo Clin Proc*, 2011, 86(1):50-60.
20. Hoseinzadeh E, Taha P, Wei C, Godini H, Ashraf GM, Taghavi M, Miri M. The impact of air pollutants, UV exposure and geographic location on vitamin D deficiency. *Food Chem Toxicol*, 2018, 113:241-254.
21. Mousavi SE, Amini H, Heydarpour P, Amini Chermahini F, Godderis L. Air pollution, environmental chemicals, and smoking may trigger vitamin D deficiency: Evidence and potential mechanisms. *Environ Int*, 2019, 122:67-90.
22. Stelter K. Tonsillitis and sore throat in children. *GMS Curr Top Otorhinolaryngol Head Neck Surg*, 2014, 13:Doc07.
23. Holick MF. Vitamin D deficiency. *N Engl J Med*, 2007, 357(3): 266-281.
24. Hossein-nezhad A, Holick MF. Optimize dietary intake of vitamin D: an epigenetic perspective. *Curr Opin Clin Nutr Metab Care*, 2012, 15(6):567-579.
25. Looker AC, Johnson CL, Lacher DA, Pfeiffer CM, Schleicher RL, Sempos CT. Vitamin D status: United States, 2001-2006. *NCHS Data Brief*, 2011, (59):1-8.
26. Jeffery LE, Qureshi OS, Gardner D, Hou TZ, Briggs Z, Soskic B, Baker J, Raza K, Sansom DM. Vitamin D Antagonises the Suppressive Effect of Inflammatory Cytokines on CTLA-4 Expression and Regulatory Function. *PLoS One*, 2015, 10(7):e0131539.
27. Najada AS, Habashneh MS, Khader M. The frequency of nutritional rickets among hospitalized infants and its relation to respiratory diseases. *J Trop Pediatr*, 2004, 50(6):364-368.
28. Aydın S, Aslan I, Yıldız I, Ağaçhan B, Toptaş B, Toprak S, Değer K, Oktay MF, Unüvar E. Vitamin D levels in children with recurrent tonsillitis. *J Pediatr Otorhinolaryngol*, 2011, 75(3):364-367.
29. Yıldız I, Unuvar E, Zeybek U, Toptas B, Caccina C, Toprak S, Kilic A, Aydın S. The role of vitamin D in children with recurrent tonsillopharyngitis. *Ital J Pediatr*, 2012, 38:25.

---

**Corresponding Author: Mioara Desdemona Stepan, Department of Infant Care-Pediatrics-Neonatology Discipline of Paediatrics, University of Medicine and Pharmacy of Craiova, Romania, Petru Rareș Str., no.2, Craiova 200349, Romania, e-mail: dstepan80@yahoo.com**