

Two-stage functional and aesthetic reconstructive surgery in melanoma in situ of the glans penis and urethra

Fabio Campodonico¹, Giacomo Capponi¹, Marco Ennas¹, Cesare Massone², Federico Dotta¹, Carlo Introini¹

¹Department of Abdominal Surgery, Urology Unit and ²Dermatology Unit, Galliera Hospital, Genova, Italy

Citation: Campodonico F, Capponi G, Ennas M, Massone C, Dotta F, Introini C. Two-stage functional and aesthetic reconstructive surgery in melanoma in situ of the glans penis and urethra. Cent European J Urol. 2021; 74: 464-467.

Article history

Submitted: May 28, 2021

Accepted: July 12, 2021

Published online: July 31, 2021

Corresponding author

Fabio Campodonico
Galliera Hospital
Department of Abdominal
Surgery
Urology Unit
8 Via Volta
16128 Genova, Italy
phone: +39 010 563 4897
fabio.campodonico@
galliera.it

Melanoma in situ including glans penis and fossa navicularis is unique and represents a challenging dilemma since surgery should not be very aggressive. We present a case of melanoma in situ treated with a two-stage penile and urethral reconstructive surgery, with emphasis on functional and aesthetic results. At the first-stage surgery an anatomic glansectomy was performed, and combined preputial and full-thickness skin grafts were used to prepare the urethral plate and restore the aesthetic aspect of the corpora cavernosa. After 6 months, the distal urethra was repaired including the configuration of an orthotopic meatus and a neo-glans.

Key Words: glans resurfacing ◊ urethroplasty ◊ melanoma in situ ◊ urethral melanoma

CASE PRESENTATION

A 50-year old healthy man presented with a brown irregular flat lesion surrounding the tip of the glans, involving the urethral meatus (Figure 1). The lesion biopsy showed melanoma in situ. Urethrocystoscopy revealed that the melanoma was spreading into the fossa navicularis with less than 1 cm infiltration. The staging with total-body computed tomography (CT) scan did not reveal distant metastasis. After multidisciplinary discussion, radical surgery was planned including the removal of the glans and distal urethra.

At the first-stage surgery an anatomic total glansectomy was performed, exposing the intact tips of the corpora cavernosa. The distal urethra was excised

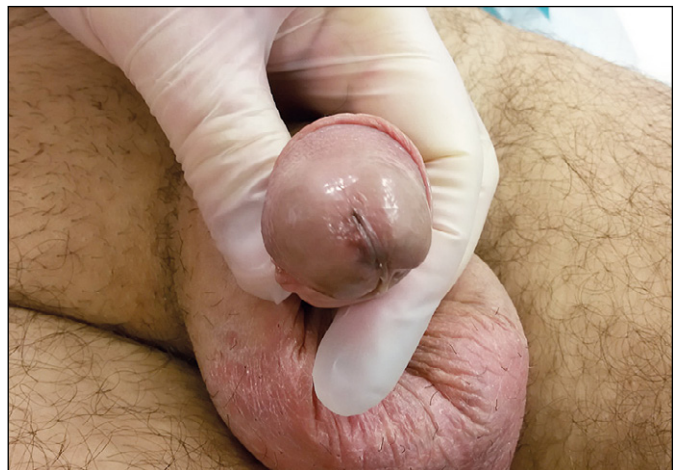

Figure 1. The melanoma of the glans and meatus.

with a 1.5 cm safety margin, confirmed as healthy by a preliminary histological examination (Figure 2A). A dorsal transverse preputial flap was created, and a template-tailored free graft was harvested from the internal leaflet of the foreskin (Figure 2B). The graft was accurately meshed and sutured with 4-zero polyglactin stitches upon the ventral aspect of the corpora cavernosa, laid on the bed where the removed urethra was previously situated. Subsequently, a free full-thickness skin graft of adequate size was harvested from the hairless area of the left groin, being suitable for use as a patch to restore the aesthetic aspect of the dorsal dome of the corpora cavernosa. The skin graft was prepared separately by accurate defatting until achieving a thin thickness, meshed

with scalpel, laid circularly for 180 degrees on the tip of the corpora cavernosa, and sutured with 4-zero polyglactin interrupted stitches (Figure 2C). Medication with embedded gauzes was left inside for 3 days, followed by office medications until complete healing. The final pathology examination confirmed the melanoma in situ with free margins.

The second-stage surgery was planned after 6 months at consolidated first-time reconstruction (Figure 3A). The plate of preputial graft was incised along its edges and tubularized using a running 5-zero polyglycolic suture upon a 14 Fr catheter (Figure 3B). A dartos tail was used to cover the neourethra to protect the suture, and then the shaft was covered with a tension-free penile skin flap (Figure 3C). Urethral

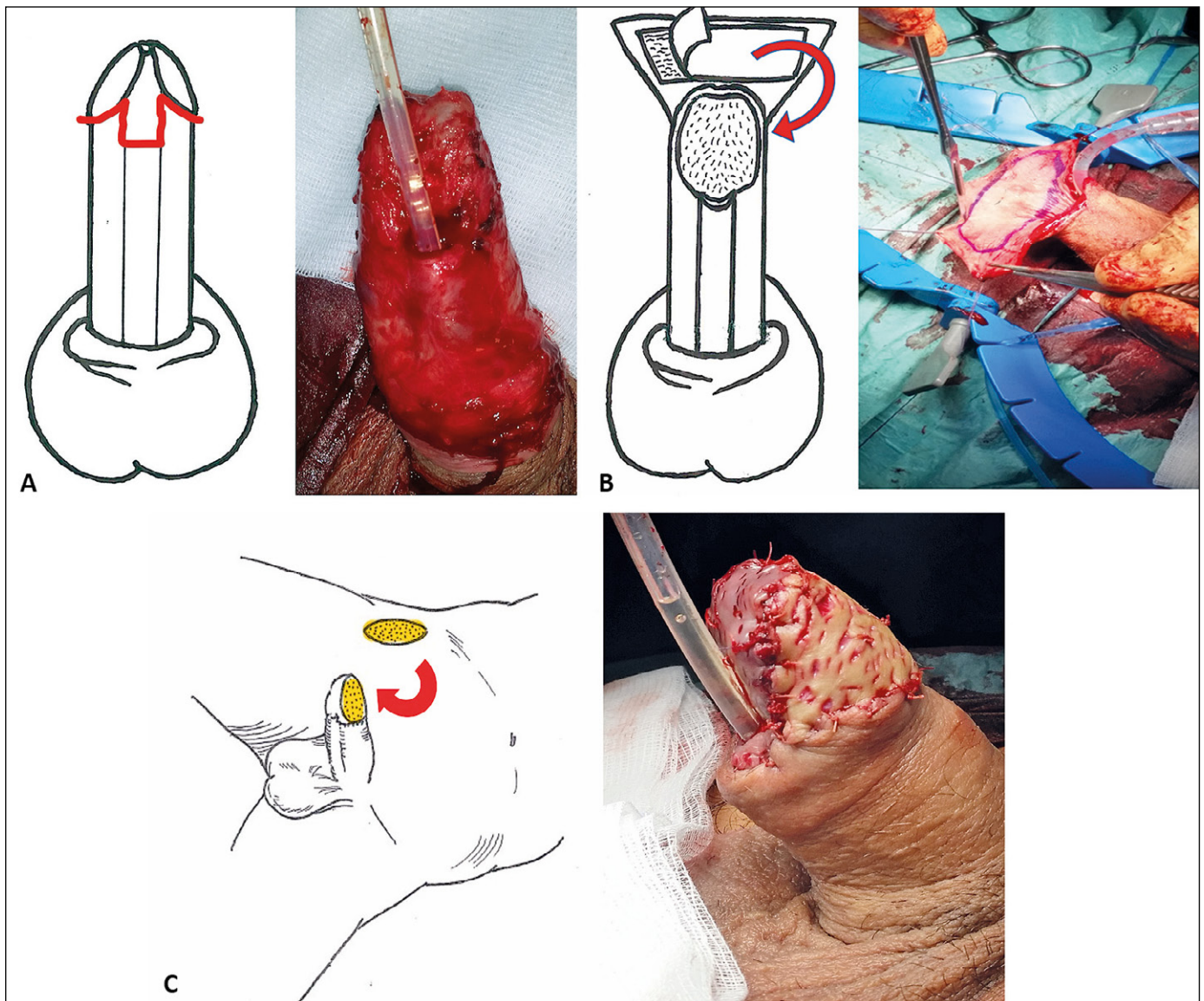


Figure 2. A. Excision of the glans and urethra. B. Harvesting of the internal preputial leaflet graft. C. The skin graft transposed from the flank to the dorsal tip of the corpora cavernosa. End of the first-stage surgery.

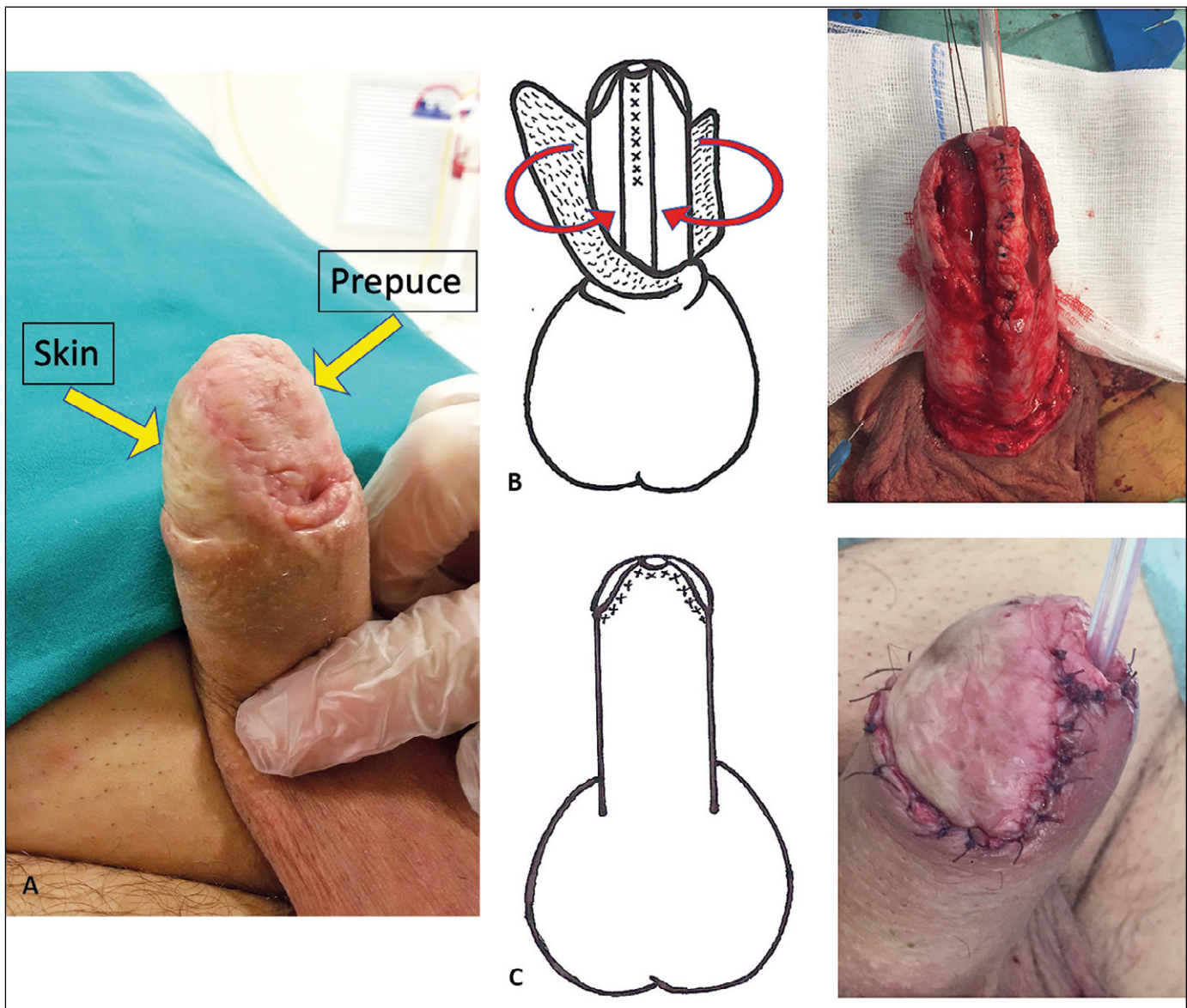


Figure 3. A. The 6 months outcome of first-stage surgery. B. The neo-urethra tubularized using the preputial plate. C. End of the second-stage surgery.

catheter was removed in three weeks, after a para-catheter retrograde urethrography confirming the watertight suture profile.

At 24 months after the second-stage surgery, the urethra was shown to be negotiable by a 16 Fr catheter (Figure 4). Voiding function recorded a normal peak flow, including linear and turbulent micturition. Erectile function was normal. The poor skin sensitivity on the resurfaced area of the corpora cavernosa had significantly improved at the last follow-up visit (the patient self-reported sensitive evaluation was 'good', while 1 year before, it was 'bad'). No local disease recurrence was observed and the whole-body CT scan was negative.

DISCUSSION

Melanomas of the glans and urethra are mucosal lesions unrelated to ultraviolet light exposure. Mucosal melanomas are rare and account for approximately 2% of all melanomas; they affect patients with a median age of 70 years. Urethral melanoma is a very rare tumor, accounting for 1% of urethral cancers [1, 2]. As other melanomas growing into mucosal membranes, urethral melanoma has a poor prognosis [3]. Melanoma in situ including glans penis and fossa navicularis is unique and represents a challenging dilemma since surgery should not be very aggressive, as indicated on the contrary for

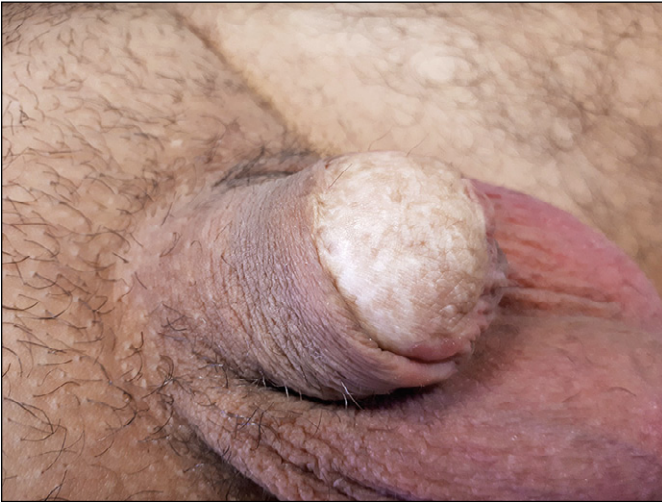

Figure 4. The reconstructed glans and urethra at 24 months.

the invasive stage. In the English literature, very few reports describe surgical reconstruction after urethral melanoma excision. The small case numbers hinders the development of specific guidelines. Moreover, for both early invasive and in situ stages involving the glans and urethra, technical repair options are limited to case-adapted surgical strategies and surgeon's skill [4, 5]. One-stage reconstructive approaches have been reported but without a proper follow-up [6]. Uniformly, it is reported that at least a 5 mm safety margin from the visually apparent disease should be considered adequate and permits a partial glans sparing in most cases, but in the case of irregular and lightly colored flat lesions involving both glans and urethra this conventional limit may be unsafe [7]. Thus, a proper disease re-

section including the glans and urethra should be planned, taking into account the challenging reconstruction. Indeed, considering the curative intent of surgery in non-invasive melanoma, a proper reconstruction focused on the maintenance of function and aesthetics should be pursued. From a technical point-of-view, it is demanded that the most accurate handling of the two free grafts be used. Both grafts, from the preputium and skin, were kept in contact with the corpora cavernosa after accurate hemostasis of the host bed. Then, random stitches ensured maximal adhesion between the opposite surfaces. The tissue adhesion grants a timely engraftment process along two regenerative phases. The first phase is the 'imbibition', consisting of the contact between fluids and cells from the opposite layers, taking about 48 hours. The second phase, called 'inosculation', takes about 3 to 5 days, and includes the migration of vascular cells promoting the angiogenesis of micro-vessels, which move from the host-bed to the deep layer of the graft [8]. The corpora cavernosa resurfacing with the skin graft is mainly related to a cosmetically appealing result. However, the harvesting of a healthy oversized foreskin free graft is essential in building the optimal urethral plate, which is suitable for the second-stage urethral repair [9].

In conclusion, after the most important step of disease resection, a meticulous attention to surgical details is the key to preparing optimal local tissue conditions to achieve satisfactory functional and aesthetic outcomes after repair.

CONFLICTS OF INTEREST

The authors declare no conflicts of interest.

References

- Bermejo CE Jr, Basler JW. Carcinoma of the urethra. In Hamdy FC, Basler JW, Neal DE, Catalona WJ eds., Management of urologic malignancies, 1st edn., Edinburgh: Churchill Livingstone 2002; Chapt. 47, pp. 525-533.
- Katz EE, Suzue K, Wille MA, Krausz T, Rapp DE, Sokoloff MH. Primary malignant melanoma of the urethra. *Urology*. 2005; 65: 389.
- Papěš D, Altarac S, Arslani N, Rajković Z, Antabak A, Čačić M. Melanoma of the glans penis and urethra. *Urology*. 2014; 83: 6-11.
- Kato H, Hayashi K, Saida T, Kontani K, Nishizawa O. Urethral advancement procedure for reconstruction after excision of male parameatal melanoma in situ. *Urol Int*. 2005; 74: 183-184.
- Primus G, Soyer HP, Smolle J, Mertl G, Pummer K, Kerl H. Early 'invasive' malignant melanoma of the glans penis and the male urethra. *Eur Urol*. 1990; 18: 156-159.
- Fahmy O, Scharpf M, Fend F, Stenzl A, Gakis G. Feasibility of penis-preserving surgery for urethral melanoma: proposal for a therapeutic algorithm. *Clin Genitourin Cancer*. 2015; 13: e411-e413.
- Carmignani G, Traverso P, Naselli A, Bertolotto F, Romagnoli A, Corbu C. Primary malignant melanoma of the urethra: reconstructive solution in a rare case. *Eur Urol Suppl*. 2003; 2: 209.
- Jordan GH. Techniques of tissue handling and transfer. *J Urol*. 1999; 162: 1213-1217.
- Armenakas NA, McAninch JW. Management of fossa navicularis strictures. *Urol Clin N Am*. 2002; 29: 477-484. ■