

Received: 2014.02.22
Accepted: 2014.03.11
Published: 2014.03.24

Medical and dental management of Alagille syndrome: A review

Authors' Contribution:

Study Design A
Data Collection B
Statistical Analysis C
Data Interpretation D
Manuscript Preparation E
Literature Search F
Funds Collection G

AEF 1 Adam Berniczai-Royko
AEFG 2 Renata Chałas
AEF 3 Iwona Mitura
EF 4 Katalin Nagy
EF 5 Elżbieta Prussak

1 Department of Orthodontics, University of Szeged, Szeged, Hungary
2 Department of Conservative Dentistry and Endodontics, Medical University of Lublin, Lublin, Poland
3 Orthodontic Clinic, Dental Clinical Center, Medical University of Lublin, Lublin, Poland
4 Department of Oral Surgery, University of Szeged, Szeged, Hungary
5 Department of Management in Health Care, University of Medical Sciences, Poznań, Poland

Corresponding Author: Renata Chałas, e-mail: renata.chalas@gmail.com


Source of support: Self financing

Alagille syndrome is a rare, autosomal, complex, dominant disorder associated with dysfunction of the liver, heart, skeleton, and eyes, as well as characteristic facial appearance. It is associated with the defect in component of the Notch signalling pathway. Here, we review the main features of Alagille syndrome with special focus on oro-facial manifestations like prominent forehead, moderate hypertelorism with deep-set eyes, a saddle or straight nose with a flattened, bulbous tip, and large ears. The article is based on the most recent and significant literature available from the Medline database.

Contrary to healthy children, patients with Alagille syndrome have many problems, depending on several factors like the severity of cholestasis and scarring in the liver, heart or lung problems, presence of infections, or other problems related to poor nutrition that can manifest in their oral cavity in the dental and periodontal tissues, as well as oral mucosa. From the dentist's view, the most important elements are careful observation, accurate diagnosis, and planned management of such patients, especially during the patient's formative years, to prevent complications. Aggressive preventive oral care and consultations with medical specialists before any invasive procedure are obligatory. All this can improve quality of life in patients with Alagille syndrome.

MeSH Keywords: **Alagille Syndrome • Dental Care • Oral Manifestations**

Full-text PDF: <http://www.medscimonit.com/download/index/idArt/890577>



2060



3



32

Background

Alagille syndrome AGS (synonyms: Arteriohepatic Dysplasia AHD, Watson-Alagille syndrome, Syndromic Bile Duct Paucity SBDP, Syndromic Hepatic Ductular Hypoplasia, Syndromic Intrahepatic Biliary Hypoplasia, Cholestasis with Peripheral Pulmonary Stenosis, Intrahepatic Biliary Atresia or Dysgenesis) was initially described by Daniel Alagille et al. in 1969 [1]. This first article in French was written by doctors from the United Hepatologie, Hopital de Bicetre, Paris, France, and focused on the features of Alagille syndrome that distinguish it from liver disorders [1]. It is a rare disease characterized by a reduced number of small bile ducts within the liver, combined with abnormalities in at least 2 other organs, including the heart, eyes, spine, and kidneys [2,3]. The syndrome is accompanied by distinctive facial appearance in many patients. The incidence is approximately 1 in 70 000 to 100 000 live births [4–6]. It is a rare genetic disorder with autosomal dominant transmission. The mutant gene has been localized to chromosome 20p12. Deletions at the locus or mutations of a single copy of the human gene JAGGED1 has been shown to be the underlying genetic defect in the syndrome (AGS type I). The JAG1 gene encodes a ligand for the Notch receptor, a transmembrane protein, of which 4 types have been identified: Notch 1, 2, 3, and 4; it is involved in signaling between adjacent cells during embryonic development. Mutations in JAG1 disrupt the signaling pathway, causing errors in development, especially of the heart, bile ducts in the liver, spinal column, and certain facial features. Mutation in the NOTCH 2 gene at chromosomal location 1p12 occurs in less than 1% of people with Alagille syndrome (AGS type II). The familial nature of the disorder has been recognized from early reports. It is generally inherited from 1 parent and there is a 50% chance that each child will develop the disorder. Each affected adult or child may have all or only a few of the features of the syndrome. JAGGED1 mutations are inherited in 30–50% of cases with AGS, whereas in up to 60% of the patients, the mutations are *de novo* [6–10]. Genetic research is targeted at the actual gene, which will eventually enable physicians to provide prenatal testing for families, better therapy, and better understanding of the abnormalities in this syndrome.

In this paper we review the main features of Alagille syndrome, with special regard to oral manifestations and role of dentists in the management of patient with AS. The article is based on the most recent and significant literature available from the Medline database.

Clinical Picture

The diagnosis of AGS can be difficult, even if it has been evolving over the years. Nowadays it is based upon clinical criteria and genetic testing.

Classic criteria based on the 5 main systems involved were established to recognize Alagille syndrome. Liver, skeletal, renal, eye, and facial abnormalities are expressed. There are major and minor criteria for diagnosis of AGS [11,12].

Liver

Manifestations of hepatic disease range from mild cholestasis and pruritus to progressive liver failure. Jaundice is present in the majority of symptomatic patients and presents as a conjugated hyperbilirubinemia in the neonatal period or first 3 months of life. Chronic cholestasis occurs in a very high proportion of cases. It is manifest by pruritus, increased serum bile acid concentrations, xanthomas, and growth failure. The pruritus observed in Alagille syndrome is among the worst of any chronic liver disease. Liver function laboratory test results, including serum bile acids, conjugated bilirubin, alkaline phosphatase, cholesterol, and gamma-glutamyltranspeptidase, are raised and indicative of a defect in biliary excretion. Liver biopsy shows progressive liver disease, eventually causing cirrhosis and liver failure requiring transplantation, occurs in approximately 15% of cases. A small number of patients with Alagille syndrome have no manifestations of liver disease [6,11,13–16].

Heart

Cardiovascular anomalies are noticed in more than 90% of patients with AGS. The most common defects involve the pulmonary valve, artery, and branches with peripheral pulmonary stenosis. Tetralogy of Fallot is the most-reported complex cardiac malformation in subjects with Alagille syndrome. Other cardiac disorders include ventricular septal defect, atrial septal defect, aortic stenosis, coarctation of the aorta, pulmonary atresia, and hypoplastic left heart syndrome [3,6,15,17].

Eyes

Posterior ocular embryotoxon – prominence of Schwalbe's line that represents the termination of the peripheral Descemet's membrane is an ophthalmic feature reported in 90% of patients with AGS. A wide variety of ophthalmic abnormalities may affect the cornea, iris, retina, and optic disc. Diagnostic criteria also include ectopic pupil, keratotic band, and lens changes. A spectrum of retinal pigmentary changes have been found in Alagille syndrome subjects. In the majority of patients, visual prognosis is rather good, although small decrease in acuity may occur. Less frequent are ophthalmologic findings, including microcornea, congenital macular dystrophy, exotropia, keratoconus, shallow anterior chambers, and choroidal folds [6,14,18].

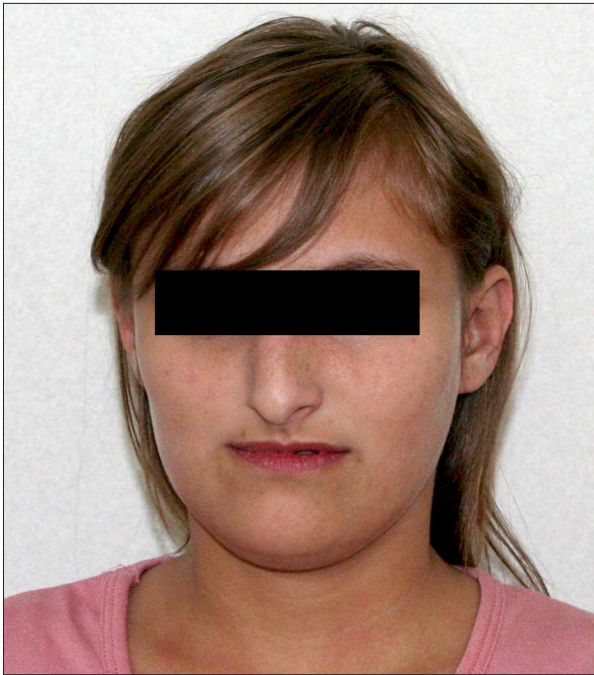

Figure 1. Own case of Alagille syndrome – *en face*.

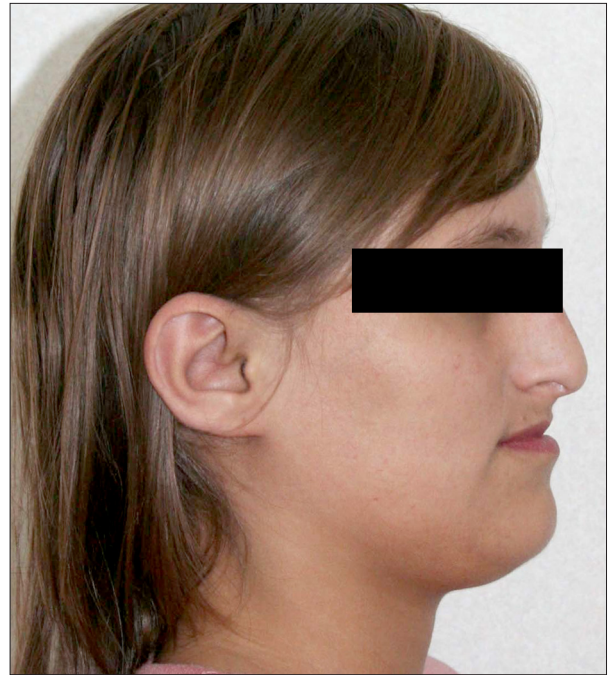

Figure 2. Own case – right profile of AGS.

Skeleton

The most common skeletal anomalies in Alagille syndrome is “butterfly” hemivertebrae, mainly in the thoracic spine. This consists of a sagittal cleft in 1 or more vertebrae, visible on anterior-posterior radiological examination, which is due to failure of fusion of the anterior vertebral arches. The frequency of butterfly vertebrae is 70% in reported cases of Alagille syndrome. Other skeletal abnormalities include narrowing of interpeduncular spaces in the lumbar spine, pointed anterior process of the first cervical vertebra, spina bifida occulta, hemivertebrae, fusion of adjacent vertebrae, absence of the 12th rib, bony connections between ribs, short fingers, radioulnar synostosis, and lower limb long bones [4,6,15,17,19].

Other organs

Renal defects include functional and structural abnormalities such as small, echogenic kidneys, cysts, and ureteropelvic obstruction. Pancreatic insufficiency can appear and some patients have developed insulin-dependent diabetes mellitus. Hypothyroidism has been described in some AGS patients, and delayed puberty can occur. Hearing loss was also reported. Mental retardation and learning difficulties are common [5,6,15,19].

Face

Alagille reported that children with AGS have recognizable prominent forehead, moderate hypertelorism with deep-set

eyes, a saddle or straight nose with a flattened, bulbous tip, and large ears. The line between nose and forehead is almost straight, and flattened midface and pointed chin are common [1,2]. Before age 1 year, there are not so visible characteristic features of that face. Later, the child’s facies typically has a prominent forehead and delicate pointed chin, giving the face an inverted triangular appearance. At about the time of puberty, the chin becomes more prominent, becoming prognathic, and there is less dominance of the forehead [3–6,20–22] (Figures 1 and 2).

In a review of 80 cases, Alagille et al. [11] determined the facial phenotype to be present in 95% of cases. This has been further supported by Emerick et al. [5], who found this frequency to be 96% in a series of 92 patients. Quiros-Tejeira et al. [19] reported a specific phenotype in 98% cases of AGS. In the past, there was debate among clinicians regarding characteristic facial features finding in Alagille syndrome subjects. Sokol et al. [16] argued that the facial dysmorphism seen in AGS is nonspecific and is a result of congenital intrahepatic cholestasis. But Kamath et al. disagreed with this observation. They assessed a panel of 18 photographs of patients with AGS and other forms of congenital intrahepatic cholestasis. The examiners were 79% accurate in correctly distinguishing Alagille patients from other individuals [4].

Human embryo studies show JAG1 expression is detected in the first pharyngeal arch, which gives rise to facial structures, including the maxilla and the mandible. JAG1 is also expressed in several regions in the head and neck, including the

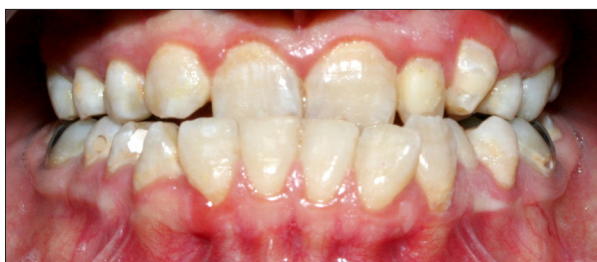

Figure 3. Own case – permanent dentition of AGS.

nasopharynx, the tongue, and the mandible [7,8]. Humphreys et al. [9] reported that JAGGED1 mutations cause the midfacial hypoplasia phenotype observed in Alagille syndrome patients. Cephalometric evaluation shows a decreased mandibular ramus and a wide gonion. Macrocephaly and craniosynostosis are rarely found [6,17,23].

Oral health

Depending on the state of the liver disorders, AGS may also damage teeth, salivary glands, periodontium, and mucous membranes. Dental manifestations are not a primary feature of the syndrome, but they invariably occur as a complication of the long-lasting cholestasis and are linked to hyperbilirubinemia. As a consequence of cholestasis during odontogenesis, enamel opacities, hypomineralization, and hypoplasia of tooth enamel can appear. In children with serum bilirubin level more than 30 mg/dl, biliverdin accumulates in the dental tissues, causing a variable, greenish-brown dyschromia of teeth (Figure 3) [17,18,24–26]. The pigmentation can be modified by the hemal translucency that transmits the dentinal color. Both the primary and permanent dentition can be heavily affected if they develop before the resolution of jaundice. Authors report presence of talon cusps in primary and permanent teeth in patients with AGS [27,28]. Different data show macrodontic maxillary incisor and, in a few cases, taurodontic deciduae teeth with a widened pulpal cavity [17,29]. Extensive decalcification of predentin and interglobular dentin invariably occurs. Ho et al. noticed patients with Alagille syndrome have hypodontia and oral xanthomas [30].

In the case of people with AGS and chronic liver disease, the food deficiency, lack of immunity, and coagulation disorders play an important role in oral condition of such patients. Undernutrition and, as a result, lack of proteins, vitamins A, D, K, E, group B vitamins, macro- and microelements like iron, calcium, phosphorus, zinc, magnesium, cuprum, and manganese may manifest in their oral cavity in the dental and periodontal tissues, as well as oral mucosa [31]. Among children with chronic liver disease were also found delayed tooth eruption and dilated pulp chambers and radicular space, most likely due to vitamin D deficiency. Studies have shown that undernutrition can cause decreased saliva secretion and reduced level

of proteins, immunoglobulins type A, amylase, and lysozyme. All these factors together increase the risk for caries formation. Poor hygiene predisposes to the development of gingivitis and paradontopathies [17,20,24].

Dental Management of Patient with AGS

Many oral/dental changes occur after liver transplantation, which is very often necessary in patients with Alagille syndrome. Graft rejection is a major complication, caused mainly by pre- or post-operative infection from a variety of sources. The oral cavity harbors numerous pathogenic bacteria that can cause acute organ inflammation, such as pneumonia, gastritis, peptic ulcers, and infective endocarditis that are very dangerous for patients after liver transplantation. Dental infections, therefore, may put such subjects at great risk. Accordingly, it is recommended that the patient have a careful dental check-up. Before surgery, all carious cavities should be treated and restored, teeth classified for the extraction should be removed, periodontium has to be healthy, and oral hygiene must be very good. All dental treatment must be performed in collaboration with the physician, who will prescribe proper drug selection, and use of antibiotics as a prophylaxis or in a case of bleeding after extraction control of hemostasis. After surgery, all patients require regular dental control visits because of permanent and continuous immunosuppressive treatment. The prolonged immunosuppression after transplantation can give rise to the suppression of bone marrow, which may result in leucopenia, thrombocytopenia, or anemia. It can predispose patients to excessive bleedings, opportunistic infections like mycosis, herpes superinfection, and development of leucoplakia. Cyclosporine intake is associated with drug-induced gingival hypertrophy, which may lead to gingivitis and periodontal tissue damage. Regular dental care and prophylaxis, appropriate hygiene monitoring, and the cyclosporine replacement in consultation with the physician, can prevent the development of these symptoms [14,21,24].

In AGS patients with less severe general manifestations, it is possible to perform orthodontic treatment combined with esthetic restorative procedures or surgery, but only with careful control [29]. Monitoring of oral hygiene and caries control is mandatory.

Conclusions

Contrary to healthy children, patients with Alagille syndrome have many problems, depending on factors such as the severity of cholestasis and scarring in the liver, heart or lung problems, presence of infections, or other problems related to poor nutrition. But in general, AGS children have better outcome than others with different liver disorders at the same age. Many

adults with Alagille syndrome are leading normal lives and have few problems during dental treatment. Nevertheless, everyday problems may affect psychological and emotional well-being. Dental disorders are not the main problems of people with AGS, but dental surgeons may come across patients with AGS in their practice. The most important points are careful

observation, accurate diagnosis, and planned management of such patients, especially during the patient's formative years, to prevent complications. Aggressive preventive oral care and consultations with medical specialists before any invasive procedure are obligatory. All this can improve quality of life in patients with Alagille syndrome [32].

References:

- Alagille D, Habib EC, Thomassin N: L'atresie des voies biliaires intrahepatiques avec voies biliaires extrahepatiques permeables chez l'enfant. Editions Medicales Flammarion, Paris: 1969; 301-18
- Alagille D, Odievre M, Gautier M, Dommergues JP: Hepatic ductular hypoplasia associated with characteristic facies, vertebral malformations, retarded physical, mental, and sexual development, and cardiac murmur. *J Pediatr*, 1975; 86(1): 63-71
- Subramaniam P, Knisely A, Portmann B et al: Diagnosis of Alagille syndrome – 25 years of experience at King's College Hospital. *J Pediatr Gastroenterol Nutr*, 2011; 52(1): 84-89
- Kamath BM, Loomes KM, Oakey RJ et al: Facial features in Alagille syndrome: specific or cholestasis facies? *Am J Med Genet*, 2002; 112(2): 163-70
- Emerick KM, Rand EB, Goldmuntz E et al: Features of Alagille syndrome in 92 patients: frequency and relation to prognosis. *Hepatology*, 1999; 29(3): 822-29
- Turnpenny PD, Ellard S: Alagille syndrome: pathogenesis, diagnosis and management. *Eur J Hum Genet*, 2012; 20(3): 251-57
- Crosnier C, Attie-Bitach T, Encha-Razavi F et al: JAGGED1 gene expression during human embryogenesis elucidates the wide phenotypic spectrum of Alagille syndrome. *Hepatology*, 2000; 32(3): 574-81
- Jones EA, Clement-Jones M, Wilson DI: JAGGED1 expression in human embryos: correlation with the Alagille syndrome phenotype. *J Med Genet*, 2000; 37(9): 658-62
- Humphreys R, Zheng W, Prince LS et al: Cranial neural crest ablation of Jagged1 recapitulates the craniofacial phenotype of Alagille syndrome patients. *Hum Mol Genet*, 2012; 21(6): 1374-83
- Jurkiewicz D, Popowska E, Gläser C et al: Twelve novel JAG1 gene mutations in Polish Alagille syndrome patients. *Hum Mutat*, 2005; 25: 321
- Alagille D, Estrada A, Hadchouel M et al: Syndromic paucity of interlobular bile ducts (Alagille syndrome or arteriohepatic dysplasia): review of 80 cases. *J Pediatr*, 1987; 110(2): 195-200
- Martinez AM, Cedillos CAM, Zermeño JN et al: Dermatologic manifestations of Alagille syndrome. *Bol Med Hosp Infant Mex*, 2012; 69(2): 132-36
- Cheng KW, Huang JJ, Wang CH et al: Anesthetic management of a patient with Alagille's syndrome undergoing living donor liver transplantation without blood transfusion. *Chang Gung Med J*, 2004; 27(6): 449-53
- Kamath BM, Schwarz KB, Hadžić N: Alagille syndrome and liver transplantation. *J Pediatr Gastroenterol Nutr*, 2010; 50(1): 11-15
- Krantz ID, Piccoli DA, Spinner NB: Alagille syndrome. *J Med Genet*, 1997; 34(2): 152-57
- Sokol RJ, Heubi JE, Balistreri WF: Intrahepatic "cholestasis facies": is it specific for Alagille syndrome? *J Pediatr*, 1983; 103(2): 205-8
- Callea M, Bahsi E, Montanari M et al: Alagille syndrome: a review. *J Int Dent Med Research*, 2013; 6(1): 54-58
- Guadagni MG, Cocchi S, Tagariello T, Piana G: Case report: Alagille syndrome. *Minerva Stomatol*, 2005; 54(10): 593-600
- Quiros-Tejeira RE, Ament ME, Heyman MB et al: Variable morbidity in Alagille syndrome: a review of 43 cases. *J Pediatr Gastroenterol Nutr*, 1999; 29(4): 431-37
- Puja MR: Oro-facial manifestation in Alagille syndrome. *Int J Clin Dent*, 2010; 3(3): 219-24
- Al-Mutawa S, Mathews B, Salako N: Oral findings in Alagille syndrome. A case report. *Med Principles Pract*, 2002; 11(3): 161-63
- Sengupta S, Das JK, Gangopadhyay A: Alagille syndrome with prominent skin manifestations. *Indian J Dermatol Venerol Leprol*, 2005; 71(2): 119-21
- Kamath BM, Stolle C, Bason L et al: Craniosynostosis in Alagille syndrome. *Am J Med Genet*, 2002; 112(2): 176-80
- Olczak-Kowalczyk D, Pawłowska J, Kowalczyk W: Oral health status in children with chronic liver disease. *J Stoma*, 2011; 64(10): 760-74
- Amaral TH, Guerra Cde S, Bombonato-Prado KF et al: Tooth pigmentation caused by bilirubin: a case report and histological evaluation. *Spec Care Dentist*, 2008; 28(6): 254-57
- Guimares LP, Silva TA: Green teeth associated with cholestasis caused by sepsis: a case report and review of the literature. *Oral Surg Oral Med Oral Pathol Oral Radiol Endod*, 2003; 95(4): 446-51
- Praveen P, Anantharaj A, Venkataraghavan K et al: Talon cusp in a primary tooth. *J Dent Sci Res*, 2011; 2(1): 34-40
- Chatterjee M, Mason C: Talon cusps presenting in a child with Alagille's syndrome – a case report. *J Clin Pediatr Dent*, 2007; 32(1): 61-64
- Cozzani M, Fontana M: Macrodonic maxillary incisor in alagille syndrome. *Dent Res J*, 2012; 9(8): S251-54
- Ho NC, Lacbawan F, Francomano CA, Ho V: Severe hypodontia and oral xanthomas in Alagille syndrome. *Am J Med Genet*, 2000; 93(3): 250-52
- Pawłowska J, Socha P, Stolarczyk A et al: Nutrition in pediatric cholestatic liver diseases. *Med Sci Monit*, 2000; 6(1): 51-56
- www.alagille.org